



Contents lists available at ScienceDirect

## International Journal of Surgery Case Reports

journal homepage: [www.casereports.com](http://www.casereports.com)

# Limberg fasciocutaneous transposition flap for the coverage of an exposed hip implant in a patient affected by ewing sarcoma

Mario Faenza<sup>a,c,\*</sup>, Gorizio Pieretti<sup>a</sup>, Rossella Lamberti<sup>a</sup>, Pasquale Di Costanzo<sup>a</sup>, Antonio Napoletano<sup>a</sup>, Martina Di Martino<sup>b</sup>, Fiorina Casale<sup>b</sup>, Giuseppe A. Ferraro<sup>a</sup>, Giovanni F. Nicoletti<sup>a</sup>

<sup>a</sup> Multidisciplinary Department of Medical-Surgical and Dental Specialties, Plastic Surgery Unit, Università degli Studi della Campania "Luigi Vanvitelli", Piazza Luigi Miraglia, 1-80138 Naples, Italy

<sup>b</sup> Department of Women, Child and General and Specialist Surgery, Università degli Studi della Campania "Luigi Vanvitelli", Paediatric Oncology Unit, Vico Luigi De Crecchio, 2-80138 Naples, Italy

<sup>c</sup> Traslational Medicine of Development and Active Aging, Università degli Studi di Salerno, Via Giovanni Paolo II, 132-84084, Fisciano (Salerno), Italy

## ARTICLE INFO

## Article history:

Received 29 September 2017

Received in revised form

22 November 2017

Accepted 23 November 2017

Available online 27 November 2017

## Keywords:

Ewing sarcoma

Hemipelvectomy

Hip implant

Wound healing

Fasciocutaneous flap

Exposed implant

## ABSTRACT

**INTRODUCTION:** Hemipelvectomy with immediate reconstruction with prosthetic devices for the surgical treatment of malignant tumors is an invasive procedure with many possible complications such as wound breakdown, seroma, hematoma and infection.

The treatment of an exposed hip implant in these cluster of patient is extremely challenging and the literature shows how negative pressure wound therapy and myocutaneous, both pedicled and free, flaps are workhorses in these situations.

**CASE REPORT:** In this paper we report a successful coverage of exposed prosthetic hip implant with a local fasciocutaneous flap in a patient in which any other kind of reconstruction was not feasible.

**DISCUSSION:** Fasciocutaneous flaps can be considered as an easily performed and minimally invasive surgical procedure, particularly reliable even in patients in poor general conditions, with preservation of future flap options.

© 2017 The Authors. Published by Elsevier Ltd on behalf of IJS Publishing Group Ltd. This is an open access article under the CC BY-NC-ND license (<http://creativecommons.org/licenses/by-nc-nd/4.0/>).

## 1. Introduction

Hemipelvectomy with immediate reconstruction with prosthetic devices for the surgical treatment of malignant tumors is an invasive procedure.

Even if the hemipelvectomy surgical procedure has changed from a posterior to an anterior approach with a consistent reduction in terms of complications, the complication rate is still high.

There are many variables that could affect the wound morbidity leading to complications such as wound breakdown, seroma, hematoma and infection.

The problem is that in these patients there is always a prosthetic implant under the wound, so every situation causing a wound breakdown put the patient at an high risk of implant exposure.

The treatment of an exposed hip implant in these cluster of patient is extremely challenging and the literature shows how neg-

ative pressure wound therapy and myocutaneous, both pedicled and free, flaps are workhorses in these situations.

In this paper we report a successful coverage of exposed prosthetic hip implant, previously treated with surgical debridement and vacuum-assisted closure therapy, with a local fasciocutaneous Limberg transposition flap in a patient affected by recurrent Ewing Sarcoma, in which any other kind of reconstruction was not feasible.

The patient healed primarily in two weeks and a week after he was put in condition to undergo chemotherapy.

Ten months after the surgical procedure no recurrence of implant exposure nor sign of infection were observed.

The work has been report in line with the SCARE criteria [11].

## 2. Case report

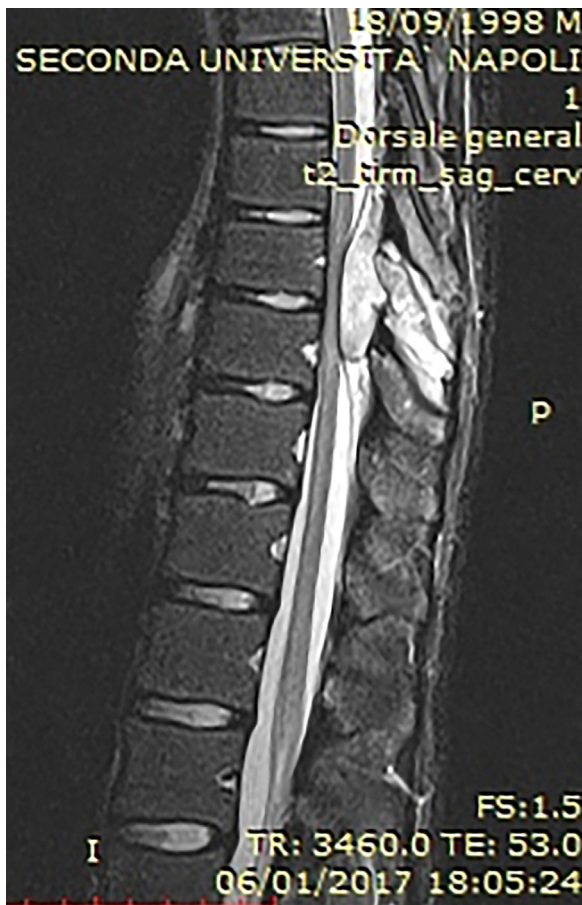An eighteen years-old male patient was diagnosed with Ewing Sarcoma after a biopsy of a painful lump in the right hip.

According to the international staging system for that kind of tumor, the patient was staged as ISG/AIEOP EW-1 non metastatic.

One month after a neoadjuvant chemotherapy comprising vincristine, doxorubicine, cyclophosphamide, ifosphamide and

\* Corresponding author at: Multidisciplinary Department of Medical-Surgical and Dental Specialties, Plastic Surgery Unit, Università degli Studi della Campania "Luigi Vanvitelli", Piazza Luigi Miraglia, 1-80138 Naples, Italy.

E-mail address: [dottmariofaenza@gmail.com](mailto:dottmariofaenza@gmail.com) (M. Faenza).



**Fig. 1.** MRI imaging showing recurrence at level of processus spinosus of ninth and tenth thoracic vertebrae, with intracanalicular extension in the posterior epidural space causing compression of the spinal chord.

etoposide was administered in order to achieve a cytological reduction of the tumor.

The patient underwent a right hemipelvectomy with simultaneous reconstruction with titanium prosthetic hip joint.

One month after the surgery, according to the international protocol, the patient was treated with an autologous stem cells transplant.

At this time the patient was in a disease-free condition and there were no indications for postoperative radiation treatment.

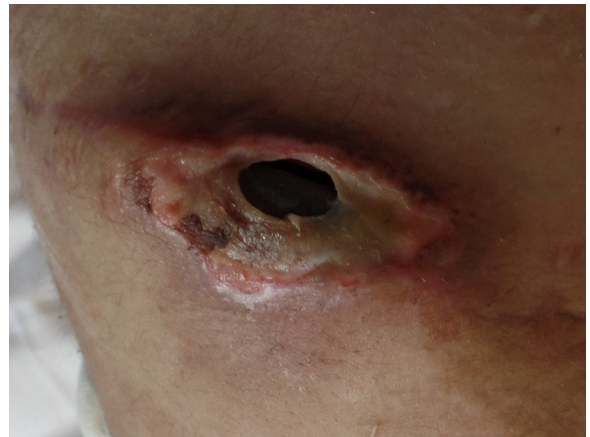Two months later, the patient developed a complete dehiscence of the wound with an exposure of the whole underlying titanium implant, for that reason the orthopedic surgeon performed a surgical revision of the wound with direct closure.

The increased tension on the wound margins after the surgical revision led to a recurrence of the exposure in the central portion of the wound in a 6 weeks time.

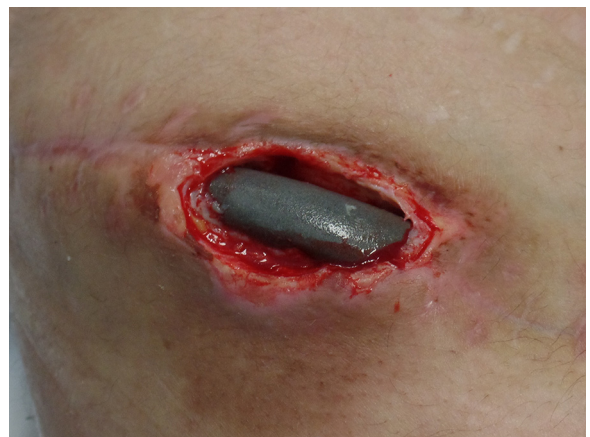At this time a new surgical revision of the wound was planned, but unfortunately the six-month oncological follow-up investigated by PET-TC scan showed a recurrence of the disease at level of left humerus, right scapula, sacroiliac sincondrosis and soft tissues around the hip implant.

In two weeks from this investigation report, the patient developed urinary retention ed paraplegia.

For that reason a MRI was scheduled and came back positive for disease recurrence at level of processus spinosus of ninth and tenth thoracic vertebrae, with intracanalicular extension in the posterior epidural space causing compression of the spinal chord. (Fig. 1)



**Fig. 2.** Dehiscence of the hemipelvectomy wound with exposure of underlying implant.



**Fig. 3.** The wound after a first surgical debridement.

A surgical decompression was planned and adjuvant chemotherapy was administered (Vincristine, Temozolomyde and Irinotecan).

Urinary bladder function was promptly re-established but paraparesis and anesthesia of both the lower limbs showed no improve.

At this time the patient was referred to our unit for consultation the local examination showed a 7 cm × 4 cm wound dehiscence at level of the right iliac crest with exposure of the underlying hip implant (Fig. 2)

A swab was performed on the wound and came back negative for pathogens.

For that reason we decided to perform a first wound debridement followed by application of negative pressure wound therapy with continuous irrigation system (Fig. 3).

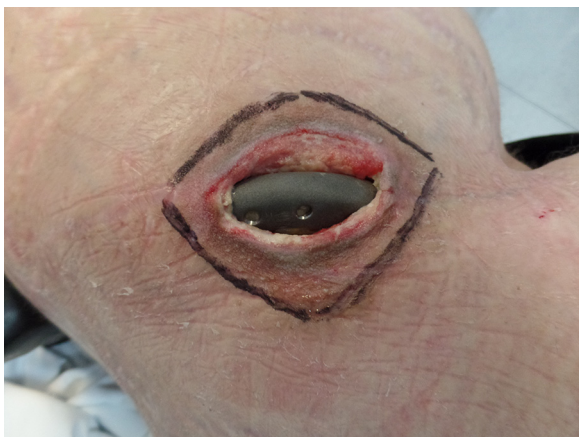Broad spectrum antibiotic regimen was administered and wound dressing was changed every 3–4 days.

The negative pressure wound therapy was performed for four weeks in order to control the risk of infection and to promote the cleaning of the wound bed and to reduce the dead space below the wound margins (Fig. 4).

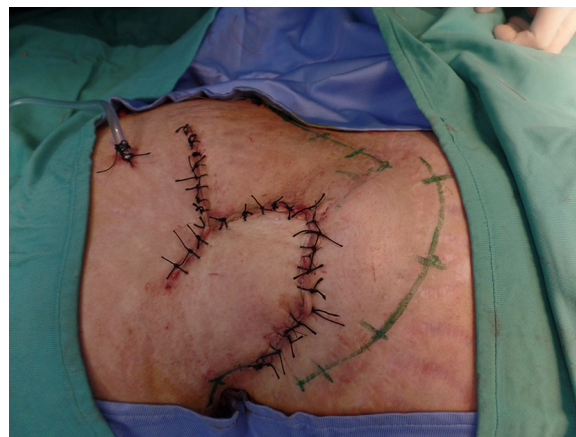After this period of time, the patient was scheduled for a surgical debridement and coverage with a Rectus Femoris Myocutaneous Flap under general anesthesia, because of the supine position could not be tolerated.

Unfortunately the patient developed a pneumonia with a recurrence of the disease at level of cervical vertebrae.

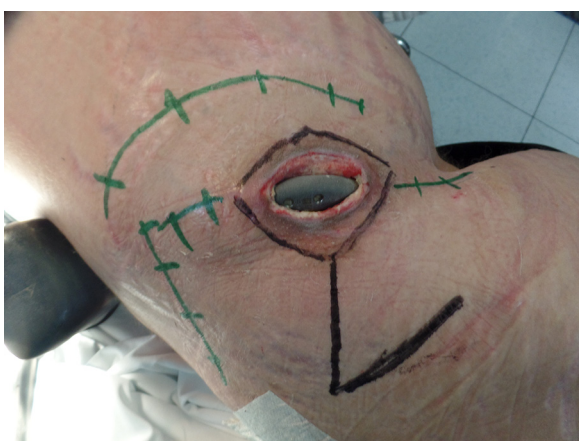
These complications put the patient at high intraoperative risk with no eligibility for general anesthesia.



**Fig. 4.** The wound after 4 weeks of Negative Pressure Therapy.



**Fig. 6.** The wound at the end of the surgical procedure.



**Fig. 5.** Scars of previous surgical procedures are drawn in green, the area of surgical debridement and the Limberg fasciocutaneous flap are drawn in black. (For interpretation of the references to colour in this figure legend, the reader is referred to the web version of this article.)

A targeted antimicrobial therapy was administered for 4 weeks and complete resolution of the infection was achieved, in the meantime the negative pressure wound therapy was continued.

For what concern the recurrence of Ewing Sarcoma, the oncology multidisciplinary team suggested a new chemotherapy regimen (Gemcitabine and Docetaxel) consistently more immunosuppressive than the previous one, putting the patient at high risk of sepsis due to the hip implant exposure.

We decided to perform a less invasive surgical procedure in order to achieve the coverage of the exposed implant with a short operative time and in order to give the patient a chance of undergo the new chemotherapy regimen.

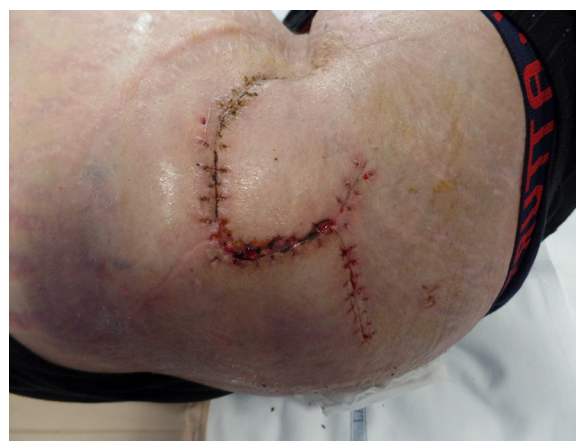The presence of many scars around the area of implant exposure allowed us to design a Limberg flap with an infero-medial pedicle (Fig. 5).

The patient was positioned in a left lateral decubitus, position in which the patient felt very comfortable, and no anesthesia was needed because of the previous damage of the spinal cord.

The flap was harvested including the fascia of the Gluteus Maximus muscle in the dissection in order to give more structural consistency to the flap preventing ischemia due to the compression from the underlying implant.

One hemovac drain was placed in the donor site to prevent fluid collection (Fig. 6).

The whole procedure took 45 min of operative time.



**Fig. 7.** Two months after the surgery, the wound is healed with no signs of infection.

No complications occurred in the postoperative course and stitches were removed in 2 weeks time.

The new chemotherapy regimen had been started three weeks after the surgical procedure.

No infections nor recurrence of hip implant exposure were observed both in short and in long term follow up (Fig. 7).

### 3. Discussion

The employ of local skin to cover a tissue defect by direct suture reduces the time and care otherwise needed for a wound to heal by secondary intention.

The goal should be to reach a rapid wound closure using the simplest technique associated with a low morbidity rate and low costs.

Even if the simplest technique should be chosen, this should take into account the probability of success, in fact choosing the wrong technique, as simple as it may be, will translate into more costs in the long term.

A low tension on wound margins is one of the key points of the reconstructive ladder: if tension is present, wound dehiscence is likely to occur.

Another key point of wound healing is represented by the obliteration of dead spaces by an accurate closure of the subcutaneous layers, this will reduce the risk of fluid collection and infections.

The critical point is when the tissue defect is so large that direct closure of the subcutaneous tissues and the skin is not possible.

In these situations surgeons have to use flaps that have capabilities of both obliterate the dead spaces and get a low-tension wound closure.

Transposition flaps are elevated and rotated across intact skin into defect, one edge of defect is a portion of the flap border.

These flaps are pivoted between 45° and 90° relative to the long axis of the defect into the recipient site.

A 90° transposition flap is aligned parallel to the lines of greatest tension, so its donor site can often be closed primarily.

External hemipelvectomy is a surgical procedure with an high morbidity rate with multifactorial postoperative wound complications, mainly related to the devascularization of the skin flaps leading to infections and implant exposures [1].

Vacuum-assisted closure (V.A.C.) therapy was first developed as an alternative to surgery in frail patients affected by chronic wounds.

Since then this device evolved into a widely accepted treatment of chronic and acute wounds, contaminated wounds, burns, infiltration, envenomations and wound complications from failed surgical procedure [2].

The literature shows that the gold standard in the coverage of exposed prosthetic devices and in the treatment of infected non healing wounds is represented by muscular or myocutaneous flap because is demonstrated how their employ increases blood supply, oxygenation and antibiotics delivery at the wound site [3–5].

In 2009 Kelm et coll. reported a retrospective study on the efficacy of surgical debridement and the vacuum-assisted closure therapy in 28 patients with early hip joint infection. Pathogen organisms could be isolated by swab in 22 out of 28 wounds and eradication of the infection could be achieved in 26 out of 28 cases [6].

In 2011 Yoshida et coll. presented a case report of a patient affected by Ewing Sarcoma and previously treated with hemipelvectomy and reconstruction with an artificial hip joint complicated by hip implant exposure and MRSA infection.

To control the infection they performed a radical debridement of the wound and application of topical negative pressure for 4 weeks in combination with targeted antimicrobial therapy.

Consequently the performed a combination of free latissimus dorsi and serratus anterior muscle flap to cover the defect [7].

Ichioka et coll. in 2004 published a case series on 22 patients affected by ischial ulcers treated with a combination of three different local flaps: two adipofascial turnover flap for the deep layer and one fasciocutaneous Limberg transposition flap for the superficial layer.

Overall, 19 patients out of 22 healed primarily [8].

In 2011 Lin et coll. presented a case series of 15 patients affected by ischial pressure sores treated with double adipofascial turnover flaps for the deep layer and direct closure of the skin after a wide undermining of skin flaps.

Overall, 13 patients out of 15 healed primarily [9].

In conclusion, treatment of ischial ulcers with adipofascial flaps, alone or the combination with a fasciocutaneous flap, can be considered as an easily performed and minimally invasive surgical procedure, particularly reliable even in patients in poor general conditions, with preservation of future flap options.

Furthermore, local fasciocutaneous flaps can be modeled on the size of the defect to be covered, exploiting their rotational, advancing and transposition capabilities [10].

We reported a case of hip implant exposure in a young patient affected by metastatic Ewing Sarcoma.

## Conflicts of interest

No conflicts of interest to declare

## Funding

No sources of funding.

## Ethical approval

Ethical approval has been exempted by our institution because the surgical procedure performed is in line with current guidelines.

## Consent

We have obtained consent from the patient.

## Author contribution

Mario Faenza: writing the paper.  
Gorizio Pieretti: data collection.  
Rossella Lamberti: data collection.  
Pasquale Di Costanzo: data analysis.  
Antonio Napoletano: data analysis.  
Martina Di Martino: oncology team.  
Fiorina Casale: oncology team.  
Giuseppe Andrea Ferraro: study concept.  
Giovanni Francesco Nicoletti: study concept.

## Guarantor

Mario Faenza.

## References

- [1] A. Senchenkov, S.L. Moran, P.M. Petty, J. Knoetgen, R.P. Clay, U. Bite, S.A. Barnes, F.H. Sim, Predictors of complications and outcomes of external hemipelvectomy wounds: account of 160 consecutive cases, *Ann. Surg. Onc.* 15 (1) (2008) 355–363.
- [2] L.C. Argenta, M.J. Morykwas, M.W. Marks, A.J. DeFranzo, J.A. Molnar, L.R. David, Vacuum-Assisted Closure: state of clinic art, *Plast. Reconstr. Surg.* 117 (June (Suppl. 7)) (2006) 127s–142s.
- [3] C. Rubino, M. Faenza, N. Campitiello, G. Fornio, F. Santanelli di Pompeo, G.C. Accarino, VRAM-pedicled island flap for the coverage of an exposed prosthetic vascular graft in the suprapubic area, *Case Rep. Plast. Surg. Hand Surg.* 3 (July (1)) (2016) 59–61.
- [4] N.F. Jones, P. Eadie, P.C. Johnson, D.C. Mears, Treatment of chronic infected hip arthroplasty wounds by radical debridement and obliteration with pedicled and free muscle flaps, *Plast. Reconstr. Surg.* 88 (1) (1991) 95–101.
- [5] K.J. Tan, C.T. Lim, A.Y.T. Lim, The use of muscle flaps in the salvage of infected exposed implants for internal fixation, *J. Bone Joint Surg.* 92-B (2010) 401–405.
- [6] J. Kelm, E. Schmitt, K. Anagnostakos, Vacuum-assisted closure in the treatment of early hip joint infections, *Int. J. Med. Sci.* 6 (September (5)) (2009) 241–246.
- [7] S. Yoshida, R. Yokohama, A. Sakamoto, Treatment of pelvic defect and infection with endoprosthesis exposure by topical negative pressure and irrigation with myocutaneous flap, *Microsurgery* 31 (November (8)) (2011) 655–658.
- [8] S. Ichioka, K. Okabe, S. Tsuji, N. Ohura, T. Nakatsuka, Triple Coverage of ischial ulcers with adipofascial turnover and fasciocutaneous flaps, *Plast. Reconstr. Surg.* 114 (September (4)) (2004) 901–905.
- [9] H. Lin, C. Hou, Z. Xu, A. Chen, Treatment of ischial pressure sores with double adipofascial turnover flaps, *Ann. Plast. Surg.* 64 (January (1)) (2010) 59–61.
- [10] C. Rubino, M. Faenza, B. Di Pace, N. Campitiello, S. Brongo, G. Zingone, A new keystone flap Plus design: case series and analysis of follow-up, *J. Plast Reconstr. Aesthet. Surg.* 70 (July (7)) (2017) 976–979.
- [11] R.A. Agha, A.J. Fowler, A. Saeta, I. Barai, S. Rajmohan, D.P. Orgill, SCARE Group, The SCARE statement: consensus-based surgical case report guidelines, *Int. J. Surg.* 34 (October) (2016) 180–186.

## Open Access

This article is published Open Access at [sciencedirect.com](https://www.sciencedirect.com). It is distributed under the [IJSCR Supplemental terms and conditions](#), which permits unrestricted non commercial use, distribution, and reproduction in any medium, provided the original authors and source are credited.