

The Role of Electron Microscopy for the Diagnosis of Childhood Glomerular Diseases

Isa Jahanzad, MD; Mitra Mehrazma*, MD, and Ahmad Ostadali Makhmalbaf, MD

Oncopathology Research Center, Tehran University of Medical Science, Tehran, Iran

Received: May 07, 2010; Final Revision: Jul 24, 2010; Accepted: Oct 03, 2010

Abstract

Objective: Optimum diagnosis of glomerulopathies requires light microscopy, immunofluorescence and electron microscopy. In fact electron microscopy has a confirmatory role in glomerular diseases. It provides more information for patient management and can rule out other diseases. The goal of the present study is analysis the necessity of electron microscopy for the diagnosis of childhood glomerulopathies.

Methods: 134 cases of renal biopsy with some clinical data retrospectively were reviewed. The contribution of electron microscopy to the final diagnosis was graded as necessary – diagnosis could not be reached without it, supportive – it increased the level of confidence in the final diagnosis and noncontributory – the diagnosis don't need electron microscopy for confirmation.

Findings: The contribution of electron microscopy to the final diagnosis was necessary in 51 cases (38%), supportive in 40 cases (\cong 30%) and noncontributory in 43 cases (32%).

Conclusion: In conclusion the results showed in about 68% of childhood glomerulopathies the ultrastructural study was necessary or supportive, so electron microscopy still remains an important tool in diagnosis of childhood glomerulopathies.

Iranian Journal of Pediatrics, Volume 21(Number 3), September 2011, Pages: 357-361

Key Words: Electron Microscopy; Children; Glomerular Disease; Renal Biopsy

Introduction

Optimum diagnosis of glomerulopathies requires light microscopy, immunofluorescence and electron microscopy. In fact electron microscopy has been used in the pathological diagnosis of glomerular diseases over past few decades and its diagnostic value has been strongly emphasized. It

provides more information for patient management and can rule out other diseases^[1]. Ultrastructural features may enable a diagnosis to be made where the light microscopy is apparently normal, for example minimal change, thin membrane disease, hereditary nephropathy, and fibrillary and immunotactoid glomerulonephritis. In addition, it can provide information to confirm

* Corresponding Author;

Address: Oncopathology research Centre, Tehran University of Medical Sciences (TUMS), Hemmat Highway, Tehran, Iran

E-mail: m-mehrazma@sina.tums.ac.ir

or elucidate a diagnosis, as in immune complex glomerulonephritis, renal amyloidosis, dense deposit disease, and diabetes. The main limitations of use of electron microscopy are cost and time consumption^[2].

However, few recent reports have critically assessed the role of electron microscopy. Its usefulness in other diagnostic areas, such as tumor pathology has declined considerably, and this along with inevitable financial pressure to reduce expensive investigations prompted us to perform this study, so the goal of the present study is analysis the necessity of electron microscopy for the diagnosis of childhood glomerulopathies.

Subjects and Methods

In a retrospective study we examined pediatric renal biopsies that referred to a referral hospital in Tehran between 2004 and 2009 for electron microscopy evaluation. During this 6 – year period 134 patients from birth to 15 years old were investigated. The biopsies were performed by using needle or open surgery. Tissues had been submitted for light microscopy and immunofluorescence and reports of them were reviewed by one pathologist, although some cases didn't have immunofluorescence reports.

Renal biopsy evaluation:

All renal biopsies that previously had been studied by light and immunofluorescent microscopy referred to this referral hospital for electron microscopy evaluation. Tissues were fixed in glutaraldehyde 2.5% then osmium tetroxide 1% and embedded in epoxy resin. At first semi-thin sections provided and reviewed to identify glomeruli, then thin sections prepared with ultramicrotome and stained by uranyl acetate and lead citrate and examined by Zeiss transmission electron microscope. Each case was first analyzed using light microscopy and immunofluorescence findings together with the clinical and laboratory data including serum creatinin, urinalysis and 24h protein excretion, and then electron microscope was used in order to determine ultrastructural changes of tissues. Mesangial hypercellularity, decrease or increase in basement membrane

thickness or irregularity within it, characteristics of endothelial cells, presence of dense deposits within mesangium or along basement membrane were the most important pathologic changes that were evaluated. If necessary the sections were reviewed by second pathologist and the role of electron microscopy for diagnosing the glomerular disease. The contribution was graded into 3 groups as follow:

- 1 – Necessary: If final diagnosis could not have been achieved without electron microscopy.
- 2 – Supportive: If the ultrastructural study didn't alter primary diagnosis, however, did provide important information confirming the primary diagnosis and rule out other diagnoses.
- 3 – Noncontributory: If the electron microscopy was not needed to confirm the diagnosis.

The software used for statistical analysis was SPSS 15 and mostly descriptive statistics were used.

Findings

In our study there were 134 children, 81 boys and 53 girls. Clinical laboratory data are showed in Table 1.

The most important cases which were studied are as below:

- Alport's syndrome was observed in 32 cases (about 24%) and it was the most common diagnosis and composed of 17 boys and 15 girls. The average patient age was 7.6 years; between 2 and 15 years. Electron microscopy (EM) was necessary in all cases.
- Focal segmental glomerulosclerosis (FSGS) was observed in 21 cases (15%) and was the second

Table 1: Clinical information of studied glomerulopathies

Clinical data	Number of cases
Nephrotic protienuria	62
Non-nephrotic proteinuria	57
No protreinuria	15
Gross hematuria	46
Microscopic hematuria	30
No hematuria	58
High serum creatinin	21
Normal serum creatinin	113

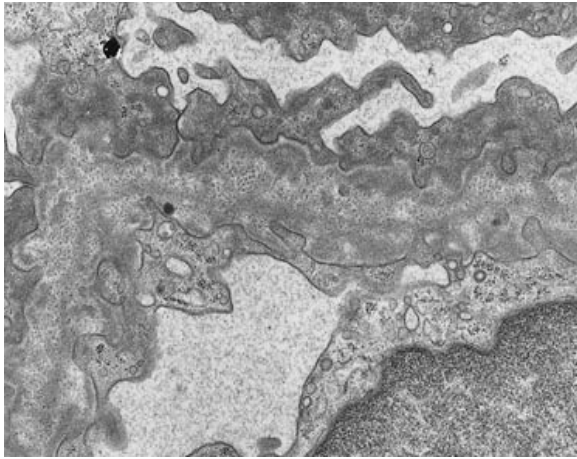


Fig. 1: Alport's Syndrome. Note the thickening and splitting of glomerular basement membrane

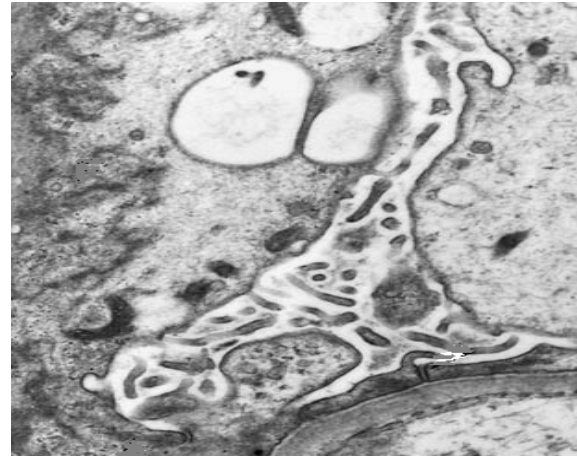


Fig. 2: Microvillous transformation in minimal change disease

most common diagnosis; 13 boys and 8 girls. The average age was 8.8 years varying between 2.5 months and 15 years. The final diagnosis by EM was supportive in 13 cases and noncontributory in 8 cases.

- Minimal change disease (MCD) was observed in 10 cases (7.5%) composed of 7 boys and 3 girls. The average age was 5.2 years; between 2 and 15 years. EM study was necessary in 7 patients and supportive in 3 ones (Fig. 2).

- Lupus nephritis was observed in 6 patients (4%). All of them were female. The average age was 11.8 years. The youngest patient was 4 and the oldest one was 14 years. EM study was necessary in 1 case and noncontributory in 5 cases.

- Chronic interstitial nephritis was seen in 5 patients (3%), 4 boys and 1 girl. The average age was 13.2 years; between 12 and 14 years. EM study was noncontributory in all cases.

The data of all patients are summarized in table 2.

Table 2: Role of electron microscopy in diagnosis of childhood glomerulopathies. GN, glomerulonephritis

Diseases	No. of cases	necessary	supportive	Non contributory
Alport syndrome	32	32 (100%)	0	0
Focal segmental glomerulosclerosis	21	0	13 (62%)	8 (38%)
Mesangial proliferative GN	12	0	4 (66.6%)	8 (33.3%)
Post infectious GN	11	0	4 (36%)	8 (64%)
Minimal change disease	10	7 (70%)	3 (30%)	0
Membranous GN	9	4 (44.4%)	0	5 (55.5%)
IgA nephropathy	8	0	4 (50%)	5 (50%)
IgM nephropathy	8	0	8 (100%)	0
Lupus nephritis	6	1 (16%)	0	5 (84%)
Chronic interstitial nephritis	5	0	0	5 (100%)
Membranoproliferative GN	5	2 (40%)	3 (60%)	0
Henoch-Shoulnlein Purpura	2	1 (50%)	0	1 (50%)
Collagen III nephropathy	1	1 (100%)	0	0
Thin basement membrane disease	1	1 (100%)	0	0
Amyloidosis	1	0	1 (100%)	0
Congenital nephrotic syndrome	1	1 (100%)	0	0
Hemolytic Uremic Syndrome	1	1 (100%)	0	0
Total	134	51 (38%)	40 (30%)	43 (32%)

GN: Glomerulonephritis / Ig: Immunoglobulin

Discussion

In our study EM study was necessary in 51 cases of 134 (38%), supportive in 40 cases (\cong 30%) and noncontributory in 43 (32%).

In Rivera et al. study about value of electron microscopy in the diagnosis of childhood nephrotic syndrome, EM was essential in diagnosis of 73% cases and supportive in a further 27% [3]. Siegel et al. showed that electron microscopy contributed to diagnosis in 48% cases [4], and Sementilli et al. concluded that ultrastructural study is necessary in diagnosis of hereditary nephropathies [5].

Another study by Daouich et al revealed that electron microscopy was essential for diagnosis in 8 cases (40%) and was helpful in 12 cases (60%). In conclusion, the results showed that the ultrastructural study provides essential or helpful information in many cases of glomerular diseases, and therefore electron microscopy should be considered an important tool of diagnostic renal pathology [6].

In our study the highest percentage of cases in necessary category were Alport syndrome [the most common disease in our series: 32 cases (24%)], thin basement membrane disease, congenital nephrotic syndrome Finnish-type, Collagen III nephropathy, IgM nephropathy and HUS.

It is accepted that in hereditary nephropathies electron microscopy is necessary in diagnosis [7], and present study shows the same results.

In Alport syndrome light microscopy can be normal or only shows mesangial hypercellularity and immunofluorescence study is negative for any deposition, so electron microscopy is necessary for diagnosis [9]. Differentiation Alport syndrome from thin basement membrane disease can be difficult because these two diseases are closely related, however the major abnormalities of the glomerular basement membrane are visualized only by electron microscopy [10].

The evaluation of renal biopsy specimens without access to electron microscopy results can lead to missed diagnosis [8]. In our study electron microscopy altered diagnosis in 14% cases and the most common diagnosis that altered by EM evaluation was minimal change disease whereas Skjoten and Halvarsen found that EM altered diagnosis in 34% cases [11].

The most common diseases that electron microscopy was supportive in final diagnosis were IgM nephropathy and amyloidosis, and in any cases of chronic interstitial nephritis ultrastructural study didn't help more.

Conclusion

In conclusion the results showed in about 78% of childhood glomerulopathies the ultrastructural study was necessary or supportive, so electron microscopy still remains an important tool in diagnosis of childhood glomerulopathies; but it has some important limitations such as very few centers which have electron microscopy, low experience for interpreting the results and high cost of the test and because of these limitations especially in our country it is helpful in cases that light and immunofluorescent microscopic examinations had inevitable limitations in diagnosis, such as basement membrane disorders.

Acknowledgment

This study was supported by a research grant from Iran University of medical sciences. The authors would like to thank Miss Vaziri for her sincere cooperation.

Conflict of Interest:

The authors have no conflict of interest.

References

1. Furness PN, Boyd S. Electron microscopy and immunocytochemistry in the assessment of renal biopsy specimens: actual and optimal practice. *J Clin Pathol* 1996;49(3):233-7.
2. Haas M. A reevaluation of routine electron microscopy in the examination of native renal biopsies. *J Am Soc Nephrol* 1996;8(1):70-76.
3. Rivera A, Magliato S, Meleg-Smith S. Value of electron microscopy in the diagnosis of childhood

- nephrotic syndrome. *Ultrastruct Pathol* 2001;25(4): 313-20.
4. Siegel NJ, Spargo BH, Kashgarion M, et al. An evaluation of routine electron microcopy in the examination of renal biopsies. *Nephron* 1973; 10(4):209-15.
 5. Sementilli A, Moura LA, France MF: The role of electron microscopy for the diagnosis of glomerulopathies. *Sao Paulo Med J* 2004;122(3): 104-9.
 6. Darouich S, Goucha RL, Jaafoura MH, et al. Value of electron microscopy in the diagnosis of glomerular diseases. *Ultrastruct Pathol* 2010; 34(2):49-61
 7. Kaukinen A, Kuusniemi AM, Lautenschlager I, et al. Glomerular endothelium in kidneys with congenital nephrotic syndrome of the Finnish type (NPHS1). *Nephrol Dial Transplant* 2008; 23(4):1224-32.
 8. Wagrowska-Danilewicz M, Danilewicz M. Current position of electron microscopy in the diagnosis of glomerular diseases. *Pol J Pathol* 2007;58(2): 87-92.
 9. Dimitrijević J, Todorović V, Aleksić A, et al. Alport's syndrome and benign familial hematuria: light and electron microscopic studies of the kidney. *Srp Arh Celok Lek* 2008;136(Suppl 4):275-81.
 10. Mandache E, Gherghiceanu M. Ultrastructural defects of the glomerular basement membranes associated with primary glomerular nephropathies. *Ultrastruct Pathol* 2004;28(2): 103-8.
 11. Skjotren F, Halvorsen S. A study of the value of resin - embedded semi-thin sections and electron microscopy in the diagnosis of renal biopsies. *Acta Pathol Microbiol Scand* 1981; 89(4):257-62.