



The Brazilian Journal of INFECTIOUS DISEASES

www.elsevier.com/locate/bjid



Original article

Microsporium spp. onychomycosis: disease presentation, risk factors and treatment responses in an urban population [☆]

Erick Martínez^{a,*}, Mahreen Ameen^b, Diana Tejada^a, Roberto Arenas^c

^a Instituto de Dermatología y Cirugía de Piel “Prof. Dr. Fernando A. Cordero C.”, Guatemala City, Guatemala

^b St. John’s Institute of Dermatology, Guy’s and St. Thomas’ Hospitals NHS Trust, London, United Kingdom

^c Mycology Section, “Dr. Manuel Gea González”, General Hospital, México City, Mexico

ARTICLE INFO

Article history:

Received 24 July 2013

Accepted 27 August 2013

Available online 22 November 2013

Keywords:

Onychomycosis

Dermatophytes

Microsporium

ABSTRACT

Background: Dermatophytes are the main causative agent of all onychomycosis, but genus *Microsporium* is infrequent and the risk of acquiring the infection is often associated with exposure to risk factors.

Objectives: To describe clinical characteristics of onychomycosis due to *Microsporium* onychomycosis in an urban population.

Methods: This was a retrospective analysis of the epidemiological and clinical features of 18 *Microsporium* onychomycosis cases of a total of 4220 of onychomycosis cases diagnosed between May 2008 and September 2011 at the tertiary referral center for mycology in Guatemala.

Results: Eighteen cases of *Microsporium* onychomycosis (*M. canis*, n = 10; *M. gypseum*, n = 7; *M. nanum*, n = 1) were identified (prevalence = 0.43%). Infection was limited to nails only and disease duration ranged from 1 month to 20 years (mean = 6.55 years). The toenails were affected in all cases except for a single *M. gypseum* case of fingernail. The most common clinical presentation was distal lateral subungual onychomycosis (12/18) followed by total dystrophic onychomycosis (5/18), and superficial white onychomycosis (1/18). *M. gypseum* presented in 6 cases as distal lateral subungual onychomycosis and in 1 case like total dystrophic onychomycosis. Five cases (27.78%) were associated with hypertension, diabetes, and psoriasis. Treatment with terbinafine or itraconazole was effective. Two cases of *M. canis* distal lateral subungual onychomycosis responded to photodynamic therapy.

Conclusion: This is the largest reported series of *Microsporium* onychomycosis and demonstrates such a disease in an urban population. In 27.78% of the cases risk factors for infection were associated to comorbid states. We also report the first 2 cases of successfully treated *M. canis* onychomycosis with photodynamic therapy and a rare case of *M. canis* associated dermatophytoma.

© 2013 Published by Elsevier Editora Ltda. Este é um artigo Open Access sob a licença de [CC BY-NC-ND](http://creativecommons.org/licenses/by-nc-nd/4.0/)

[☆] This study was realized in the “Unidad de Micología Médica” of the “Instituto de Dermatología y Cirugía de Piel Prof. Dr. Fernando A. Cordero C.” Guatemala City, Guatemala.

* Corresponding author at: Instituto de Dermatología y Cirugía de Piel “Prof. Dr. Fernando A. Cordero C.”, 5 ta. calle 12.62 zona 1, Guatemala CP 01001, Guatemala.

E-mail address: martinezerickh@gmail.com (E. Martínez).

1413-8670 © 2013 Published by Elsevier Editora Ltda. Este é um artigo Open Access sob a licença de [CC BY-NC-ND](http://creativecommons.org/licenses/by-nc-nd/4.0/)

<http://dx.doi.org/10.1016/j.bjid.2013.08.005>

Introduction

Onychomycosis is the commonest nail disease worldwide accounting for 50% of all nail disorders in some studies.^{1,2} Although it is not a fatal infection it can be associated with discomfort and negative self-image³ and can predispose to soft tissue infection, particularly cellulitis.⁴ Toenails are predominantly affected and the major risk factor is occlusive footwear. Consequently, the prevalence of infection is often higher in urbanized populations. Fingernail infection, which is less common, is usually associated with occupational exposure to wet-work. Nail diseases such as psoriasis or damage to the nail plate also predispose to infection as do comorbidities, particularly diabetes mellitus, peripheral arterial disease, and HIV infection. Patients may have more than a single risk factor for infection. The incidence of onychomycosis is rising as a result of increasing exposure to risk factors and predisposing comorbid states.^{5,6}

Onychomycosis is caused by dermatophytes, yeasts, and non-dermatophyte molds. Dermatophytes are the main causative agent in temperate climates and account for 90% of toenail infections and at least 50% of fingernail infections. *Trichophyton rubrum* is the commonest isolated dermatophyte and is responsible for the majority of cases of toenail infection, followed by *T. mentagrophytes* and *Epidermophyton floccosum*. Fingernail onychomycosis is more commonly associated with yeast infection, particularly *Candida*. Epidemiological studies from the Tropics and regions with high humidity sometimes report a higher prevalence of non-dermatophyte infection for both toenail and fingernail onychomycosis. *T. tonsurans* has occasionally been associated with onychomycosis but *M. canis*, *M. gypseum* and *M. nanum* are extremely rare etiological agents and the risk of acquiring *Microsporium* infection is often associated with a history of exposure and presence of risk factors.^{6,7}

We have observed an increasing prevalence of onychomycosis in Guatemala. We presume this is due to urbanization which is associated with risk factors for onychomycosis. We have also noticed several cases of *Microsporium* onychomycosis in a relatively short period of time and the aim of this study was to define the disease characteristics of *Microsporium* nail infection within our cohort, its clinical course, and any risk factors for infection.

Materials and methods

This is a retrospective study conducted at a tertiary referral center for mycology at the "Instituto de Dermatología y Cirugía de Piel Prof. Dr Fernando A. Cordero C." in Guatemala City, Guatemala. Eighteen cases of mycologically proven onychomycosis were identified between May 2008 and September 2011. The diagnosis of onychomycosis was confirmed by direct microscopy using 10% potassium hydroxide and cultured using Sabouraud dextrose agar with chloramphenicol. Following mycological confirmation patients were treated with standard drug therapy regimens. Three-month courses of either daily oral terbinafine (250 mg daily) or pulse itraconazole (200 mg twice daily for one week every month) were most commonly used. Oral fluconazole was sometimes given at a weekly dosage of 300 mg as it is a low cost and more

affordable option for some patients. Two patients with *M. canis* distal lateral subungual onychomycosis (DLSO) aged 66 and 74 years were treated with photodynamic therapy (PDT) using 5-aminolevulinic acid (ALA) as PDT is not known to have any adverse systemic effects. Both patients received a maximum of four PDT sessions given at weekly intervals at a wavelength of 630 nm at 57.6 J/cm² using a light-emitting diode (LED) PDT with red light. Clinical cure was verified by confirming mycological cure. Any atypical cases of onychomycosis were investigated for underlying HIV infection or other causes of immunosuppression, including long-term immunosuppressant drug therapy. A history of medical risk factors and occupational exposure was sought. Epidemiological and clinical data were collected for all cases of *Microsporium* onychomycosis. The study did not require an approval from the Ethics Committee.

Results

A total of 4220 cases of mycologically proven onychomycosis were identified during a period of 41 months between May 2008 and September 2011. Eighteen of these cases were of the genus *Microsporium*, representing 0.43% of the total number of onychomycosis cases (18/4220). The majority of the rest of the cases were due to *T. rubrum*. Table 1 summarizes all characteristics of patients with *Microsporium* onychomycosis.

All the *Microsporium* cases were positive on culture and 17 of 18 of them were also positive on direct microscopy. Interestingly, direct microscopy of a case subsequently confirmed on culture as *M. canis* demonstrated dermatophytoma. Ten of the 18 cases were due to *M. canis* (prevalence 0.24%), the other seven were due to *M. gypseum* (prevalence 0.17%), and the remaining case was due to *M. nanum* (0.024%) (Figs. 1 and 2).

There was no significant difference in gender distribution: eight males and 10 females were affected. *M. canis* affected both men (4/10) and women (6/10) as did *M. gypseum* (four males and three females affected) and *M. nanum*

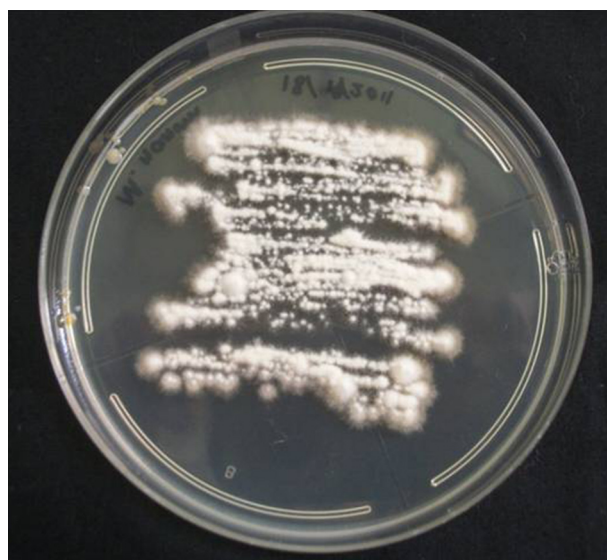

Fig. 1 – Culture of *Microsporium nanum* on Sabouraud dextrose agar with chloramphenicol.

Table 1 – Characteristics of patients with *Microsporium onychomycosis*.

Case	Sex	Age (years)	Clinical subtype	Disease duration (years)	Direct microscopy	Culture	HIV status	Comorbidities	Treatment	Response to treatment
1	F	25	DLSO	1/4	Hyphae	<i>M. gypseum</i>	Neg	No	Itraconazole	No follow-up
2	F	48	DLSO	14	Dermato- phytoma	<i>M. canis</i>	Neg	HT, DM	Fluconazole, itraconazole	Cure
3	M	42	TDO	1	Hyphae	<i>M. canis</i>	Neg	No	Itraconazole	No follow-up
4	M	49	WSO	10	Hyphae	<i>M. canis</i>	Neg	No	Itraconazole	No follow-up
5	M	74	TDO	4	Negative	<i>M. canis</i>	Not tested	HT	Terbinafine	Cure
6	M	24	DLSO	12	Hyphae	<i>M. gypseum</i>	Not tested	No	Itraconazole	No follow-up
7	F	74	DLSO	5	Hyphae	<i>M. canis</i>	Neg	HT	PDT	Cure
8	F	66	DLSO	1/2	Hyphae	<i>M. canis</i>	Neg	HT	PDT	Cure
9	M	32	DLSO	15	Hyphae	<i>M. gypseum</i>	Neg	Psoriasis	Itraconazole	No follow-up
10	F	8	DLSO	1/2	Hyphae	<i>M. canis</i>	No tested	No	Terbinafine	Cure
11	M	61	DLSO	1/12	Spores	<i>M. canis</i>	No tested	No	Itraconazole	No follow-up
12	F	52	DLSO	7	Spores	<i>M. canis</i>	No tested	No	Fluconazole and timole	No follow-up
13	M	29	DLSO	1/2	Hyphae	<i>M. gypseum</i>	No tested	No	Terbinafine	Cure
14	F	49	TDO	20	Hyphae	<i>M. canis</i>	Not tested	No	Terbinafine	Cure
15	M	18	DLSO	3	Hyphae	<i>M. gypseum</i>	Not tested	No	Terbinafine	No follow-up
16	F	61	TDO	10	Hyphae	<i>M. gypseum</i>	No tested	No	Terbinafine	No follow-up
17	F	38	DLSO	10	Hyphae	<i>M. gypseum</i>	No tested	No	Terbinafine	No follow-up
18	F	35	TDO	5	Hyphae and Spores	<i>M. nanum</i>	No tested	No	Itraconazole	Cure

DM, diabetes mellitus; DLSO, distal lateral subungual onychomycosis; F, female; HT, hypertension; M, male; Neg, negative; PDT, photodynamic therapy; TDO, total dystrophic onychomycosis; WSO, white subungual onychomycosis.

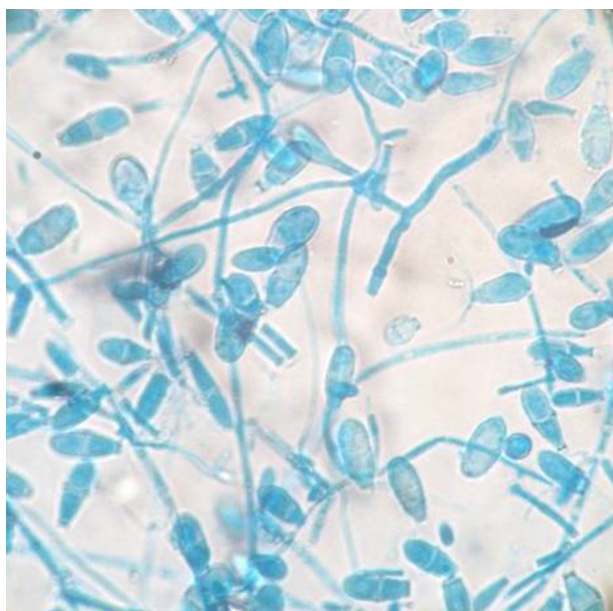


Fig. 2 – *Microsporium nanum* macroconidia on lactophenol blue stain. 40x.

(one female affected). Seventeen cases were adult patients and one case was a boy patient. *M. canis* affected a group of people with an age range of 8–74 years (mean 52.3 years); *M. gypseum*, an age range of 18–61 years (mean 32.43 years), and *M. nanum* affected only one person. All patients had toenail onychomycosis except for one patient with *M. gypseum* onychomycosis affecting a single fingernail, who was a young man with a twelve-year history of nail infection but

with no predisposing risk factors for onychomycosis (case 6 in Table 1). The most common clinical presentation was DLSO (12/18) followed by total dystrophic onychomycosis (TDO, 5/18) and superficial white onychomycosis (SWO, 1/18). *M. gypseum* presented mostly as DLSO (6/7) whereas *M. canis* had varied clinical presentations and *M. nanum* only presented as TDO (1/18) (Fig. 3).

The duration of *Microsporium onychomycosis* prior to presentation at our Institute varied widely, from one month to 20 years (mean 6.55 years). Only three patients sought medical care with disease duration of one year or less, one of them had *M. gypseum* onychomycosis. The others had suffered from onychomycosis for many years. None of the patients had tinea

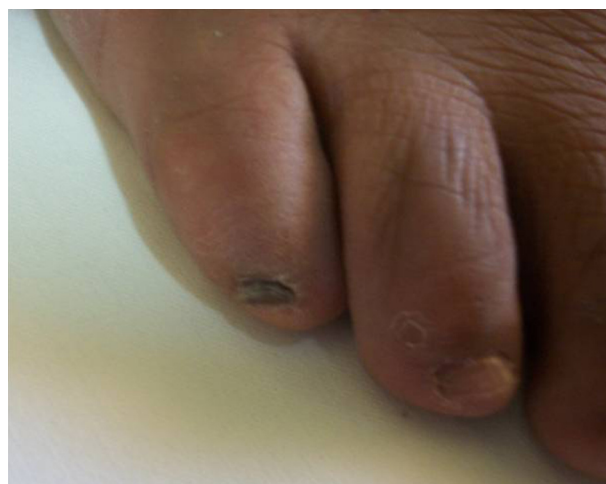

Fig. 3 – Total dystrophic onychomycosis due to *Microsporium nanum*.

affecting other parts of their body such as *tinea corporis* or *tinea capitis*. Seven of the 18 patients were screened for HIV infection and were found to be negative. The 11 patients who were not tested for HIV did not display any signs of immunodeficiency. None of the patients had any other cause of immunodeficiency nor had they been on any immunosuppressant therapy. They did not have current or prior contact with domestic cats and dogs. Although in Guatemala households commonly keep animals close contact with animals is unusual and was not reported by any of our patients. Four patients suffered from hypertension, one of them also had diabetes mellitus. Our patients with hypertension had not been investigated for peripheral arterial disease, which is a significant risk factor for onychomycosis, although both conditions are known to be strongly associated. A single patient suffered from psoriasis, which affects both skin and nails.

Treatment responses were generally good, although we were not able to confirm mycological cure in some patients who failed to return for follow-up. Only a single patient in our cohort with a 14-year history of *M. canis* DLSO and an associated dermatophytoma was treated with oral fluconazole. She failed to respond after six months of weekly fluconazole therapy, but subsequently demonstrated both clinical and mycological cure following three months of pulse itraconazole therapy. Pulse itraconazole was given to seven other patients, including the three patients with *M. gypseum*, three further cases of *M. canis*, and one case of *M. nanum*. Two cases of *M. canis* and one case of *M. gypseum* treated with terbinafine demonstrated clinical and mycological cure as did the two cases of *M. canis* DLSO treated with a total of four sessions of PDT each.

Discussion

Microsporium sp. as an infrequent agent of onychomycosis is. Our study of a Central American urban population demonstrated a prevalence of only 0.43% for *M. canis*, *M. gypseum*, and *M. nanum* nail infection. There are few recent comparative studies describing case series of *Microsporium* onychomycosis. An early study of onychomycosis from Mexico identified a prevalence of 3% of *M. canis* infection (of 733 onychomycosis cases).⁸ In Turkey, *M. canis* onychomycosis was identified in 8% of cases (6/73).⁹ Another study in 375 patients with onychomycosis in Taiwan seven cases of *Microsporium* onychomycosis were found (*M. ferrugineum*, $n=5$; *M. nanum*, $n=2$), representing 1.87% of the causative pathogens in that population. *M. gypseum* as a cause of any dermatophytosis is much less common than *M. canis*. Studies from Spain and Italy have found *M. gypseum* prevalence of 1.5–5.2% among all cases of dermatophytoses.^{10,11} However, a recent study of onychomycosis in rural farmers in Nigeria revealed a prevalence of 11.6% of *M. gypseum* DLSO (eight cases out of a total of 261 cases of onychomycosis) but no cases of *M. canis* infection.¹² This high prevalence of *M. gypseum* onychomycosis in this particular population is probably attributable to occupational exposure to soil as *M. gypseum* is a geophilic dermatophyte. Although these studies appear to demonstrate much higher prevalence for *Microsporium* onychomycosis, their sample sizes were smaller than ours.

The prevalence of onychomycosis varies throughout the world and risk factors for its development include the use of occlusive footwear in urban populations and high levels of environmental humidity. Our patient population fulfills both of these categories and consequently we see large numbers of patients with onychomycosis. In addition, significantly higher levels of onychomycosis have been reported in pediatric populations in both Guatemala as well as in neighboring Mexico compared with other more temperate regions of the world.¹³

The genus *Microsporium* is distributed worldwide and *M. canis* is the most common zoophilic species to affect humans, primarily causing *tinea capitis* in children. Domestic dogs and cats are usually the reservoir of infection and are often healthy carriers of *Microsporium*. In adults, unusual clinical presentations of *M. canis* infection have been described such as severe and inflammatory *tinea barbae* and very atypical *tinea faciei*,¹⁴ and *M. canis* infection in adults has often been associated with immunosuppressive states.¹⁵ Patients with *M. canis* onychomycosis may also report owning domestic cats or dogs and sometimes they have concomitant *M. canis* *tinea corporis* or *tinea capitis* which can occur from autoinoculation.^{16–19} *M. canis* onychomycosis has also been reported in association with HIV infection¹⁵ and long-term immunosuppressant drug therapy.¹⁸ *M. gypseum* is a soil saprophyte and the source of human infection has been traced to soil, dogs and cats.²⁰ Other than occupational exposure as described in the report of high levels of infection among rural Nigerian farmers,¹² the rising incidence of *M. gypseum* infections may be attributable to the domestication of dogs and cats, which causes soil contamination and increases the risk of infection to humans. It has also been suggested that *M. gypseum* may be undergoing phylogenetic evolution from a geophilic saprophyte to a human and animal parasite.²¹ The most frequent clinical presentation of *M. gypseum* infection is *tinea corporis* on exposed areas of the body followed by *tinea capitis*, which is sometimes associated with kerion formation.

The clinical subtypes of onychomycosis seen in our study correlate with previously reported studies of nail infection with *Microsporium* sp. with DLSO being the most common clinical presentation followed by TDO and SWO, and rarely PSO.^{17–19} All our cases of *M. gypseum* infection presented as DLSO. This is the main clinical subtype described in earlier studies^{22,23} although there is also a report of *M. gypseum* infection presenting as TDO²⁴ and a further report of *M. gypseum* PSO in an immunocompetent host.²⁵ Fingernail infection was uncommon in our cohort which included only a single case of fingernail *M. gypseum* DLSO in a young man without apparent risk factors. However, previous studies of *M. gypseum* onychomycosis report fingernails being affected in nearly all cases, and disease was usually reported in young women although no risk factors for infection were suggested.²²

Reported cases of *M. canis* onychomycosis associated with immunosuppressive states have been of the common DLSO clinical presentation,¹⁸ although immunosuppression-associated onychomycosis usually presents with either PSO or WSO.⁵ Paradoxically, there are also reports of *M. canis* onychomycosis in immunocompetent individuals presenting as PSO,^{16,17} and herein we also report a case of *M. canis* WSO in an immunocompetent patient. These observations suggest that

not only is *Microsporium* onychomycosis uncommon but that clinically it may be atypical.

Our study has thrown up further interesting observations. Firstly, direct microscopy demonstrated a dermatophytoma from a single patient whose culture subsequently confirmed to be *M. canis*. This is extremely unusual as *M. canis* producing dermatophytomas has not been previously reported. Furthermore, dermatophytomas are a poor prognostic sign and generally do not respond favorably to drug therapy as they consist of a densely packed clump of dermatophyte hyphae which are thick-walled and therefore resistant to drug penetration.^{26,27} Yet, our patient who had a 14-year history of onychomycosis and also suffered from diabetes mellitus and hypertension demonstrated both clinical and mycological cure after a standard three-month course of pulse itraconazole. She had previously failed to respond satisfactorily to a six-month course of fluconazole 300 mg weekly but higher doses and a longer period of treatment with fluconazole is usually required to achieve cure.²⁸ It is also possible that nail sampling for mycology from this patient physically removed the dermatophytoma which facilitated cure.

Our study also reports the first successfully treated cases of *M. canis* onychomycosis with PDT. In recent years the use of PDT has extended to the field of antimicrobial chemotherapy, *in vitro* studies having demonstrated PDT's antifungal effects.²⁹ PDT is an attractive option as it is minimally invasive and only locally active and therefore does not cause systemic adverse effects or local tissue damage. Furthermore, unlike antimicrobial drugs there is no potential for the development of resistance. However, in an open trial of 30 patients with *T. rubrum* onychomycosis, three sessions of PDT given at two-week intervals produced only a 43.3% cure rate.³⁰ In previous reports of *T. rubrum* onychomycosis being cured with PDT, a greater number of PDT sessions were given at shorter intervals.^{31,32} Our therapy regimen of four treatments given weekly may be the optimal treatment regimen for *M. canis* onychomycosis as it achieved clinical and mycological cure in both patients treated with this modality.

We report only one case of *M. nanun* onychomycosis. This dermatophyte is a rare cause of tinea in humans, but usually is present in pigs, its natural reservoir, and it has also been reported in cats, dogs and rabbits.^{33,34} Tinea corporis can be caused by *M. nanun*, but it is an exceptional cause of onychomycosis. We found a toenail onychomycosis in a 45-year-old woman with unknown source of infection and risk factors.³⁵

We describe the largest case series of *Microsporium* onychomycosis to date. Although the prevalence of *Microsporium* onychomycosis in our study is not significantly higher than in other studies, these cases are notable for the absence of significant risk factors for *Microsporium* nail infection: only 55% (5/9) of our cases had concomitant diseases that could predispose to infection. Otherwise, other well-recognized risk factors associated with *Microsporium* onychomycosis such as underlying immunosuppressive states or contact with dogs and cats were not diagnosed or reported in any of our cases. This significant cluster of cases of these rare etiological agents of onychomycosis seen at our Institute may reflect an increasing incidence of *Microsporium* onychomycosis. The absence of any disease-associated risk factors in almost half of our cases

suggests that *Microsporium* sp. may have greater affinity and pathogenicity for nail keratin than previously thought.

In only 18 cases of onychomycosis caused by *Microsporium* sp. it has been very difficult to point out special clinical characteristics.

Conflicts of interest

The authors declare no conflicts of interest.

Acknowledgements

The authors would like to thank Dary Gálvez, MD for the treatment of two of the patients with PDT and Mónica Hernández, MD for collecting all the data.

REFERENCES

1. Ghannoum MA, Hajjeh RA, Scher R, et al. A large-scale North American study of fungal isolates from nails: the frequency of onychomycosis, fungal distribution, and antifungal susceptibility patterns. *J Am Acad Dermatol.* 2000;43:641–8.
2. Arenas R, Bonifaz A, Padilla MC, et al. Onychomycosis. A Mexican survey. *Eur J Dermatol.* 2010;20:611–4.
3. Drake LA, Patrick DL, Fleckman P, et al. The impact of onychomycosis on quality of life: development of an international onychomycosis-specific questionnaire to measure patient quality of life. *J Am Acad Dermatol.* 1999;41:189–96.
4. Dupuy A, Benchikhi H, Roujeau JC, et al. Risk factors for erysipelas of the leg (cellulitis): case-control study. *BMJ.* 1999;318:1591–4.
5. Faergemann J, Baran R. Epidemiology, clinical presentation and diagnosis of onychomycosis. *Br J Dermatol.* 2003;149:1–4.
6. Havlickova B, Czaika VA, Friedrich M. Epidemiological trends in skin mycoses worldwide. *Mycoses.* 2008;51:2–15.
7. Kaur R, Kashyap B, Bhalla P. Onychomycosis – epidemiology, diagnosis and management. *Indian J Med Microbiol.* 2008;26:108–16.
8. Arenas R. Onychomycosis. Clinico-epidemiological mycological and therapeutic aspects. *Gac Med Mex.* 1990;126:84–9, discussion 90–1.
9. Tünzün Y, Mutlu H, Kotoğyan A. *Microsporium* infections of the nails. *Arch Dermatol.* 1980;116:620.
10. Di Silverio A, Mosca M, Brandozzi G, Gatti M, Ubezio S. Dermatofitoses observed at the Dermatologic Clinic, Pavia University. 2) Pathology of *Microsporium gypseum*. *G Ital Dermatol Venereol.* 1990;125:15–8.
11. Pereiro Miguens M, Pereiro M, Pereiro Jr M. Review of dermatofitoses in Galicia from 1951 to 1987, and comparison with other areas of Spain. *Mycopathologia.* 1991;113:65–78.
12. Efuntoye MO, Sobowale AA, Mabekoje OO, Agu GC. Onychomycosis among rural farmers in southwestern part of Nigeria. *Egyptian Dermatol Online J.* 2011;7:1–9.
13. Gupta AK, Sibbald RG, Lynde CW, et al. Onychomycosis in children: prevalence and treatment strategies. *J Am Acad Dermatol.* 1997;36:395–402.
14. Alteras I, Feuerman EJ. Atypical cases of *Microsporium canis* infection in the adult. *Mycopathologia.* 1981;74:181–5.
15. Bournerias I, De Chauvin MF, Datry A, et al. Unusual *Microsporium canis* infections in adult HIV patients. *J Am Acad Dermatol.* 1996;35:808–10.

16. Crozier WJ, Lavrin LM. An uncommon case of onychomycosis due to *Microsporium canis*. *Australas J Dermatol*. 1979;20:144-6.
17. Piraccini BM, Morelli R, Stinchi C, Tosti A. Proximal subungual onychomycosis due to *Microsporium canis*. *Br J Dermatol*. 1996;134:175-7.
18. Romano C, Paccagnini E, Pelliccia L. Case report. Onychomycosis due to *Microsporium canis*. *Mycoses*. 2001;44:119-20.
19. Hughes JR, Pembroke AC. *Microsporium canis* infection of the thumb-nail. *Clin Exp Dermatol*. 1994;19:281-2.
20. Carmen MG, Rush-Munro FM, Carter ME. Dermatophytes isolated from domestic and feral animals. *N Z Vet J*. 1979;27:136-44.
21. Seeliger HPR, Heimer T. Diagnostik pathogener Pilze des Menschen und seiner Umwelt. Stuttgart: Thieme; 1981.
22. Onsberg P. Human infections with *Microsporium gypseum* in Denmark. *Br J Dermatol*. 1978;99:527-30.
23. Romano C. Onychomycosis due to *Microsporium gypseum*. *Mycoses*. 1998;41:349-51.
24. Romano C, Ghilardi A, Fimiani M. Dystrophic onychomycosis due to *Microsporium gypseum*. *Mycoses*. 2006;49:335-7.
25. Romano C, Massai L. Proximal subungual hyperkeratosis of the big toe due to *Microsporium gypseum*. *Acta Derm Venereol*. 2001;81:371-2.
26. Roberts DT, Evans EG. Subungual dermatophytoma complicating dermatophyte onychomycosis. *Br J Dermatol*. 1998;138:189-90.
27. Scher RK, Tavakkol A, Sigurgeirsson B, et al. Onychomycosis: diagnosis and definition of cure. *J Am Acad Dermatol*. 2007;56:939-44.
28. Ling MR, Swinyer LJ, Jarratt MT, et al. Once-weekly fluconazole (450 mg) for 4, 6, or 9 months of treatment for distal subungual onychomycosis of the toenail. *J Am Acad Dermatol*. 1998;38:S95-102.
29. Smijs TG, Pavel S. The susceptibility of dermatophytes to photodynamic treatment with special focus on *Trichophyton rubrum*. *Photochem Photobiol*. 2011;87:2-13.
30. Sotiriou E, Koussidou-Eremonti T, Chaidemenos G, Apalla Z, Ioannides D. Photodynamic therapy for distal and lateral subungual toenail onychomycosis caused by *Trichophyton rubrum*: preliminary results of a single-centre open trial. *Acta Derm Venereol*. 2010;90:216-7.
31. Piraccini BM, Rech G, Tosti A. Photodynamic therapy of onychomycosis caused *Trichophyton rubrum*. *J Am Acad Dermatol*. 2008;59:S75-6.
32. Watanabe D, Kawamura C, Masuda Y, Akita Y, Tamada Y, Matsumoto Y. Successful treatment of toenail onychomycosis with photodynamic therapy. *Arch Dermatol*. 2008;144:19-21.
33. Lamilla AM, Rodríguez-Navado IM, Fernández-Recio JM, et al. Infección cutánea por *Microsporium nanum*. *Semergen*. 2007;33:159-60.
34. Roller JA, Westblom TU. *Microsporium nanum* infection in hog farmers. *J Am Acad Dermatol*. 1986;15:935-9.
35. Spiewak R, Szostak W. Zoophilic and geophilic dermatophytoses among farmers and non-farmers in Eastern Poland. *Ann Agric Environ Med*. 2000;7:125-9.