

Case Report

First Resection of a Cavoatrial Renal Tumor Thrombus in a Pediatric Patient in Central America Based on a Multistage Surgical Safety Strategy Combining Liver Transplant Techniques and Cardiac Surgery

Edward Castro-Santa^{a, b} Hellen Daniela Siles-Viquez^{a, b}
Karla Castro-Solano^c Javier Brenes-González^c María A. Matamoros^{a, b}

^aCenter for Liver Transplantation and Hepatobiliary Surgery, Mexico Hospital, Caja Costarricense del Seguro Social (CCSS), San José, Costa Rica; ^bPediatric Liver Transplant Unit, National Children Hospital Costa Rica, Caja Costarricense del Seguro Social (CCSS), San José, Costa Rica; ^cDepartment of Pediatric Cardiac Surgery, National Children Hospital Costa Rica, Caja Costarricense del Seguro Social (CCSS), San José, Costa Rica

Keywords

Multistage surgical safety strategy · Cavoatrial renal tumor thrombus · Pediatric patient · Central America · Liver transplant surgery · Cardiac surgery

Abstract

We herein report the challenging evaluation and planning process involved in performing the first successful surgical resection of a renal tumor with extensive inferior vena cava tumor thrombosis reaching the right atrium in a pediatric patient within the Central American region. In November 2018, the Oncology Department of the National Children's Hospital in Costa Rica consulted our Center for Liver Transplantation and Hepatobiliary Surgery for the evaluation of a clinical case involving a 6-year-old female patient with progressive Budd-Chiari syndrome caused by a Wilms' tumor of the right kidney with tumor thrombosis of the inferior vena cava reaching the right atrium. A multistage surgical safety strategy combining liver transplant techniques and cardiac surgery was thereafter designed and implemented, achieving complete excision of the tumor thrombus from the inferior vena cava with right nephrectomy. Postoperatively, the patient exhibited complete clinical resolution of Budd-Chiari syndrome and has remained tumor free with excellent quality of life while pursuing her second grade of primary school education 22 months after the successful implementation of this multistage surgical safety strategy. The combination of liver transplantation techniques and cardiac surgery based on a multistage surgical safety strategy minimized the occurrence of unexpected

Edward Castro-Santa
Center for Liver Transplantation and Hepatobiliary Surgery, Mexico Hospital
Caja Costarricense del Seguro Social, Frente a la Autopista General Cañas
contiguo al puente Juan Pablo II, La Uruca, San José 10107 (Costa Rica)
ecasanta@gmail.com

intraoperative events and allowed for complete renal tumor resection and level IV thrombectomy for the first time in a pediatric patient of a public health system in a developing country within the Central American region.

© 2021 The Author(s).
Published by S. Karger AG, Basel

Introduction

Several studies on both children and adult patients had reported the successful resection of renal tumors that extend to and cause extensive tumor thrombosis within the inferior vena cava (IVC) and the right atrium (RA) in highly specialized centers and with a large body of experience in the planning and surgical performance of such complex cases [1–3].

In the public health care systems of developing countries, such as the Central American and Caribbean region, economic and social conditions greatly determine the likelihood that patients with tumor diseases undergo complex surgical interventions.

Despite essential limitations, Costa Rica has one of the most robust public health care systems within the region and can offer complex surgical treatments, including liver transplantation [4]. Our center has extensive experience in liver transplantation in both living and deceased donors. Studies have shown that the application of liver transplantation surgery techniques is a fundamental component for the successful surgical resection of renal tumors with tumor thrombosis within the retrohepatic and suprahepatic IVC and RA [2, 5–7].

The current report details the challenging evaluation and planning process involved in the safe and successful performance of the first surgical resection of a renal tumor with extensive IVC tumor thrombosis extending to the RA by combining liver transplantation techniques and cardiac surgery in a pediatric patient of a public health system in a developing country within the Central American region.

Case Presentation

In October 2018, a 6-year-old female patient was admitted to the National Children's Hospital for Budd-Chiari syndrome and the presence of a palpable abdominal mass occupying the right hemiabdomen.

Abdominal ultrasound (US) and abdominal and thoracic computed axial tomography (CAT) demonstrated the presence of a large right renal tumor mass with IVC tumor thrombosis reaching the RA and proximal portions of the suprahepatic veins (SHVs) and extending caudally through the confluence of the common iliac veins (CIVs), including the right CIV.

Based on the history and clinical and imaging findings, the diagnosis of a Wilms' tumor was established. Given the extensive tumor thrombus (TT) dissemination within the entire IVC lumen and into the RA, a chemotherapy regimen based on vincristine, actinomycin, and doxorubicin was initiated in hopes of achieving the highest rate of tumor chemo-cytoreduction.

Despite multiple cycles of chemotherapy, no tumor shrinkage had been observed. In fact, quite the opposite had been noted, wherein both abdominal and thoracic CAT revealed increased TT growth within the IVC, major hepatic veins, and RA. Echocardiography (EC) confirmed tumor progression, with an intra-atrial TT size of 5.7 cm × 4.9 cm occupying the entire RA and causing significant pericardial effusion. The patient developed febrile neutropenia secondary to chemotherapy. Moreover, progressive severe hydropic decompensation, characterized by progressive dyspnea, ascites, pleural effusion, and pedal edema, was also

Table 1. The modified Neves-Zincke classification of IVC tumor thrombus according to its level of cephalic extension [8, 9]

Level of IVC TT extension	Definition
Level I	TT is limited to RV
Level II	Superior extent of TT is below the level of the intrahepatic IVC
Level III	
IIIa (intrahepatic)	TT extending into the retrohepatic IVC but below the major HVs
IIIb (hepatic)	TT extending into the retrohepatic IVC, reaching the ostia of the major HVs and perhaps extending into them, causing Budd-Chiari syndrome
IIIc (suprahepatic infradiaphragmatic)	TT extending into the retrohepatic IVC above the major HVs but below the diaphragm
IIId (suprahepatic, supradiaphragmatic and infra-atrial)	TT extending into the supradiaphragmatic intrapericardial IVC but not into the RA
Level IV	TT extending into RA

TT, tumor thrombus; IVC, inferior vena cava; RV, renal vein; HVs, hepatic veins; RA, right atrium.

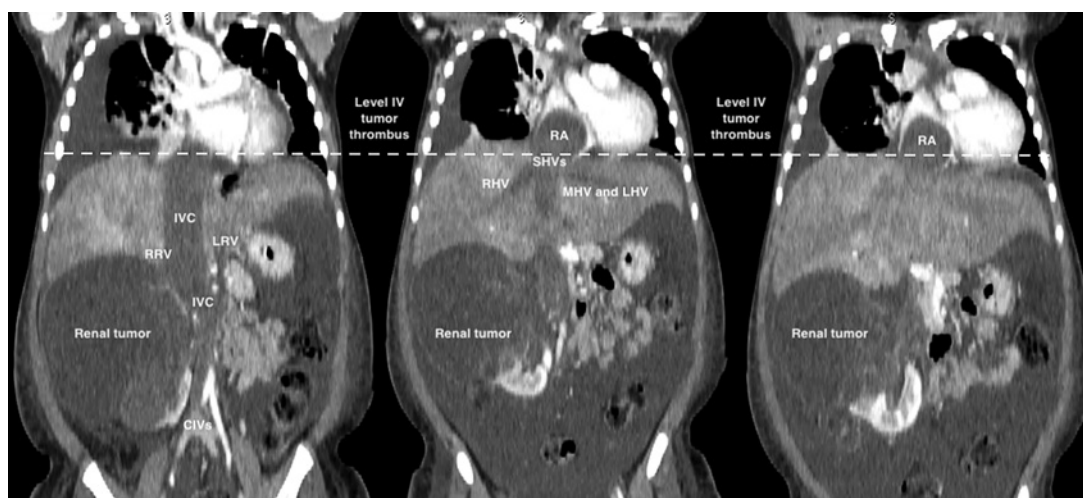


Fig. 1. Cranial extent of the level IV tumor thrombus in coronal planes during thoraco-abdominal computed axial tomography. IVC, inferior vena cava; RRV, right renal vein; LRV, left renal vein; CIVs, common iliac veins; SHVs, suprahepatic veins; RHV, right hepatic vein; MHV, middle hepatic vein; LHV, left hepatic vein; RA, right atrium.

evident. As such, the patient was considered to have a poor prognosis and palliative support treatment was initiated.

By November 2018, our center had been consulted to rule out any last possibility of a life-saving surgical procedure for the patient, who was already in a severely compromised state of health.

Evaluation and surgical planning were then initiated by stratifying and classifying the patient's TT situation according to the modified Neves-Zincke classification [8, 9] (Table 1). This classification system allowed us to stratify the renal tumor based on TT dissemination within the IVC and determine a possible approach involving the application of liver transplant surgery techniques with the support of cardiac surgery. Accordingly, level IV IVC thrombosis had been confirmed given that it extended above the diaphragm and into the RA (Fig. 1).

Based on vast experiences with similar complex cases, a surgical safety checklist had been proposed as the standard in multidisciplinary evaluation and surgical management of

renal tumors with IVC thrombosis in order to optimize the perioperative safety of such patients [10]. Similarly, a multistage surgical safety strategy was designed with the primary purpose of achieving urgent decompression of the IVC and RA from the obstructive effect of the massive TT. The secondary purpose included, if possible, achieving complete excision of both the renal tumor and intraluminal TT from the IVC and RA. The multistage surgical safety strategy consisted of the following components:

(1) Preoperative planning and assessment of possible surgical scenarios.

One of the most important aspects of a successful intervention in this type of tumor is the precise evaluation of the extent of the TT [10]. Once extensive radiological and echocardiographic evaluation of the patient is completed, multiple multidisciplinary meetings were held within the 2 weeks prior to surgery, during which thorough surgical safety planning for liver transplant surgery, pediatric cardiac surgery, and pediatric cardiac anesthesia was performed as a fundamental pillar of safety according to available logistical resources [11]. During these multidisciplinary meetings, several possible intraoperative clinical/surgical scenarios had been assessed:

- (a) Presence of peritoneal carcinomatosis and/or visceral macroscopic metastases.
- (b) Impossibility for en bloc resection of the tumor mass (radical nephrectomy and complete thrombectomy of the IVC and RA).
- (c) Need for early right nephrectomy to ensure a safe surgical space to guarantee safe IVC dissection and exposure and liver mobilization, thereby minimizing the risk of IVC rupture, tumor contamination, or uncontrollable hemorrhage.
- (d) Strong fixation of the TT to the IVC wall and RA, preventing its complete extraction en bloc and requiring partial thrombectomies and tumor fragmentation to decompress the RA, SHVs, and IVC.
- (e) Severe hemodynamic instability during any of the surgical phases that necessitates termination of the procedure.

(2) Planning and implementation of the multistage surgical safety strategy combining liver transplant surgery techniques and cardiac surgery.

The surgical technique used to address renal tumors with TT extending to the IVC and RA has been thoroughly described previously by specialized centers with significant accumulated experience with such complex cases [6, 7, 12–14]. In summary, and fulfilling each of the sequential safety stages determined during preoperative planning, the following surgical procedure was performed in December 2018:

- (a) Exploratory laparotomy and thorough peritoneal cavity evaluation, as well as intraoperative liver ultrasound, to rule out metastasis.
- (b) Evaluation of the surgical “safety space” available for the safe management and exposure of the suprarenal and retrohepatic IVC and mobilization of the liver due to the large size of the renal tumor mass.
- (c) Early nephrectomy before initiating IVC exposure and liver mobilization.
- (d) Complete extensive exposure of the suprarenal, retrohepatic, and suprahepatic IVC, as well as the supradiaphragmatic and intrapericardial IVC, with the respective, and complete mobilization of the whole liver from the IVC.
- (e) Performing vascular control using vascular rubbers surrounding the confluence of the CIVs, the right renal vein (RV), the confluence of the SHVs, and the infradiaphragmatic IVC for vascular clamp placement, if necessary.
- (f) Preparation of the hepatic hilum for eventual application of the Pringle maneuver.
- (g) Initiation of sternotomy and entry into hypothermic cardiopulmonary bypass with cardiac arrest.
- (h) Right atriotomy and assessment of thrombus mobility within the atrium and ability to displace the TT from the RA to the suprahepatic IVC.

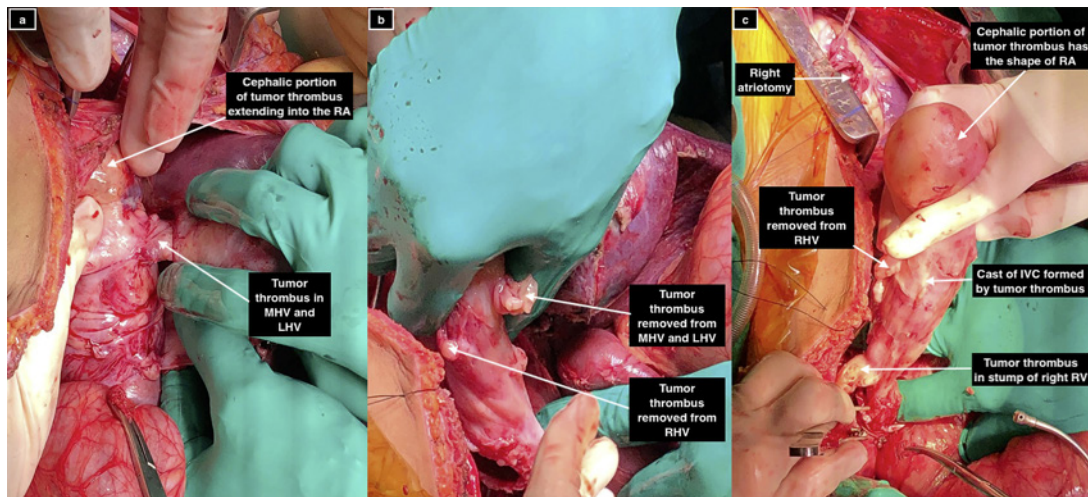


Fig. 2. Intraoperative view of the complete and sequential en bloc removal of the tumor thrombus cast out of the RA and IVC. **a** Image showing the detachment of the cephalic portion of the tumor thrombus outside the RA and TT extending into the MHV and LHV. **b** Image showing the detachment of TT out of the RHV, MHV, and LHV. **c** Image showing the complete mobilization of TT out of RA and IVC. RA, right atrium; MHV, middle hepatic vein; LHV, left hepatic vein; RHV, right hepatic vein; IVC, inferior vena cava; RV, renal vein.

- (i) Manual pushing and displacement of the TT from the RA through the atriotomy to the infradiaphragmatic IVC until complete intra-abdominal sliding of the tumor into the abdominal IVC was achieved, completely releasing the RA (Fig. 2a, b).
- (j) Performance of a longitudinal cavotomy from the inferior infradiaphragmatic IVC to the confluence of the CIVs to achieve complete extraction of the TT using the Pringle maneuver.
- (k) Complete en bloc removal the entire cast of the TT, meticulously dissecting the tumor from the endothelium of the IVC and sequentially from the suprahepatic IVC, right hepatic vein, middle hepatic vein, and left hepatic vein, retrohepatic IVC, left RV, right RV stump, and the confluence of the CIVs and the right CIV (Fig. 2c).
- (l) After removing the entire TT, we verified that no tumor was detached and checked the integrity of the TT by referencing the cast formed with the intact shape of the tumor-thrombosed vessels (Fig. 3).
- (m) Macroscopic and ultrasonographic verification of complete TT removal, with restoration of vascular patency of the CIV, abdominal IVC, right RV, left RV, SHVs, thoracic IVC, and RA.
- (n) Cavotomy closure with simultaneous atriotomy closure and exit from cardiopulmonary bypass support with the extracorporeal circulation system.
- (o) Performance of surgical hemostasis and placement of two Jackson-Pratt drains in the right hemiabdomen and pelvis, and mediastinal drain with sternotomy and laparotomy closure
- (p) Transfer of the patient to the intensive care unit (ICU), hemodynamically stable, sedated, and under mechanical ventilation

Outcomes and Follow-Up

Intraoperatively, the patient exhibited no episode of hypoxemia or severe hemodynamic instability and required minimal inotropic support, which was discontinued early after admission to the ICU. Table 2 summarizes the intraoperative clinical and surgical character-

Fig. 3. Cast formed by the tumor thrombus with reference to the intact shape of the tumor-thrombosed branches of IVC and RA. RA, right atrium; MHV, middle hepatic vein; LHV, left hepatic vein; RHV, right hepatic vein; LRV, left renal vein; RRV, right renal vein; CIVs, common iliac veins.

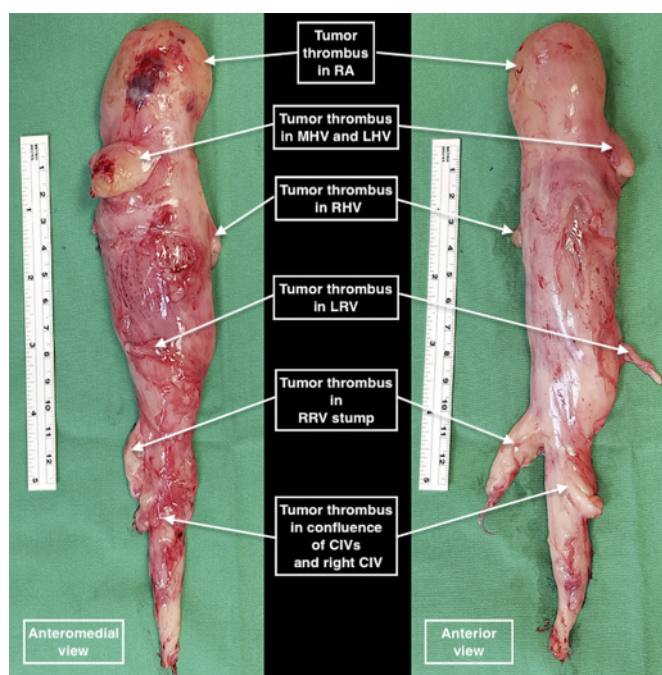


Table 2. Intraoperative clinical and surgical characteristics

Duration of surgery	480 min
Intraoperative drainage of ascites	4,600 mL
Duration of extracorporeal circulation	80 min
Duration of cardiac arrest time	51 min
Pringle's maneuver duration	10 min
Maximal inotropic support and dose	Epinephrine from 0.05 to 0.2 µg/kg/min IV
Central venous pressure before tumor thrombectomy	32 mm Hg
Central venous pressure after tumor thrombectomy	19 mm Hg
Blood loss	300 mL
Packed red blood cells transfused	3 units
Frozen fresh plasma transfused	400 mL
Pool of platelets transfused	1
Intraoperative diuresis before thrombectomy	0.2 mL/kg/h
Diuresis after thrombectomy	0.9 mL/kg/h

istics. The patient was extubated within the first 12 h after surgery, following EC showing the absence of tumor thrombi in SHV, suprahepatic IVC, or RA and no pulmonary hypertension. The patient remained in the ICU for 5 days and exhibited rapid recovery from her Budd-Chiari syndrome, with dyspnea resolution, gradual reduction in edema and ascites, normalization of urinary output, adequate tolerance of oral feeding, and continued resumption of physical activity.

The patient had no surgical complications, except for persistence of preoperative febrile neutropenia during the second postoperative week. Subsequent abdominal US and CAT documented two small collections (total volume of 91 mL) in the right subdiaphragmatic space and right renal fossa, probably related to a hematoma in resolution. Considering the extensive surgery and neutropenia, broad-spectrum antibiotics were initiated. Notably, blood cultures and inflammatory markers were negative.

Before hospital discharge, serial EC and intra-abdominal Doppler US studies showed complete patency of the RA and IVC, as well as its branches. The patient was discharged 28 days after surgery with the resolution of intra-abdominal collections, Budd-Chiari syndrome, and fever.

Histopathological analysis of the tumor specimen showed a Wilms' tumor with a favorable histology, with a greater diameter of 12 cm × 10 cm and approximately 15% of necrosis and diffuse rhabdomyoblastic differentiation. Moreover, findings showed tumor infiltration into the renal sinus and invasion into the right RV with a TT diameter of 2.5 cm and a positive margin at the division and ligation site. Both ureteral and arterial margins were tumor free, while the Gerota fascia and renal capsule showed no evidence of neoplasia. Inter-aorto-caval and perirenal lymph nodes were negative for neoplastic infiltration. The TT consisted of an irregular mass of hard elastic tissue that weighed 132 g and measured 18.0 cm × 5.5 cm × 3.0 cm, which appeared to be complete without rupture at its ends labeled as the RA, SHVs, left RV, and confluence of the CIVs, except for the site of division in the right RV.

Adjuvant chemotherapy consisting of actinomycin D, vincristine, and doxorubicin, as well as thoraco-abdominal radiotherapy (total dose of 10 Gy), was thereafter provided until February 2019. The latest clinical and radiological evaluation showed no persistent or recurrent tumors, with complete permeability of the RA and vena cava, as well as its branches. Approximately 22 months after surgery, the patient remained tumor free with excellent quality of life while pursuing her second grade of primary school education.

Discussion

Despite several studies by specialized centers mainly in developed countries reporting the successful surgical excision of renal tumors with level IV IVC thrombosis [2, 11, 13, 15], the presentation of such complex cases in patients within developing countries represents a considerable challenge in terms of access to and opportunity for treatment and health system capacity and logistics in countries with severe socioeconomic and health resource limitations.

Costa Rica has one of the strongest health care systems within the region, which has allowed for the development of specialized health care programs. As such, the country was able to develop the first successful liver transplant program within the region and one of the first successful liver transplant program with live donors throughout Latin America.

The application of transplant surgery techniques with the support of cardiac surgery has allowed for curative resections in this particular type of tumor. Unfortunately, patients with such complex tumors who cannot be evaluated by a surgical team with extensive experience with liver transplantation or are under a health care system that cannot offer this category of complex surgical techniques can only be candidates for palliative management, as would have been the case in our patient.

As previously reported, the evaluation and comprehensive management of patients with renal and level III/IV IVC TT by a multidisciplinary surgical team is a key component in achieving favorable oncological results [10–12]. The most important aspect emphasized herein is that despite our center having extensive experience in liver transplant surgery, the fundamental factor for the successful surgical resection of the current patient's tumor in a developing country was the methodical application of an integral evaluation of the tumor extension together with a sequential safety planning for all possible surgical scenarios and stages.

Indeed, reports have shown that adequate and comprehensive evaluation of tumor extension and surgical planning were fundamental requirements needed to obtain minimum morbidity and medium and long-term survival during the treatment of such patients [10].

The combination of liver transplantation techniques and cardiac surgery, supported by meticulous multistage planning, certainly minimized the occurrence of unexpected intraoperative events and allowed, for the first time, complete tumor resection in a pediatric patient with level IV renal TT who showed minimal morbidity and favorable medium-term disease-free survival and quality of life in the public health care system of a developing country within the Central American region.

Conclusion

Although successful, this first experience demonstrates the need for a regional cooperation program for pediatric and adult patients with renal tumor and level III and IV IVC thrombosis in Central America, which would allow evaluation by a surgical team experienced with liver transplantation and cardiac surgery and promote access to treatment opportunities that lead to tumor-free survival and quality of life.

Statement of Ethics

Written informed consent for publication was obtained from the patient's parents for publication of this case report and any accompanying images.

Conflict of Interest Statement

The authors have no conflicts of interest to declare.

Funding Sources

The authors received no financial support for this study.

Author Contributions

Edward Castro-Santa has made substantial contributions to the conception, design and planning, data collection, drafting, and review of the work and participated in the final approval of the work. Dr. Castro-Santa has edited and designed Figures 1–3. Hellen Daniela Siles-Viquez has made substantial contributions to the design and planning, data collection, drafting, and review of the work and participated in the final approval of the work. Dr. Siles-Viquez has made a substantial contribution equivalent to that of the first author of the work. Karla Castro-Solano has made substantial contributions to design and planning, data collection, drafting, and review of the work and participated in the final approval of the work. Javier Brenes-González has made substantial contributions to design and planning, data collection, drafting, and review of the work and participated in the final approval of the work. María A. Matamoros has made substantial contributions to the design and planning, drafting, and review of the work and participated in the final approval of the work. All authors were involved in the evaluation and planning of the surgical strategy, performed the surgical procedure, and have taken care of the patient. All authors have read and approved the final manuscript.

References

- 1 Kaag MG, Toyen C, Russo P, Cronin A, Thompson RH, Schiff J, et al. Radical nephrectomy with vena caval thrombectomy: A contemporary experience. *BJU Int*. 2011 May;107(9):1386–93.
- 2 Gonzalez J, Gaynor JJ, Martinez-Salamanca JI, Capitanio U, Tilki D, Carballido JA, et al. Association of an organ transplant-based approach with a dramatic reduction in postoperative complications following radical nephrectomy and tumor thrombectomy in renal cell carcinoma. *Eur J Surg Oncol*. 2019 Oct;45(10):1983–92.
- 3 Ciancio G, Gonzalez J, Shirodkar SP, Angulo JC, Soloway MS. Liver transplantation techniques for the surgical management of renal cell carcinoma with tumor thrombus in the inferior vena cava: Step-by-step description. *Eur Urol*. 2011 Mar;59(3):401–6.
- 4 Matamoros MA, Castro-Santa E. Organ transplantation in Costa Rica. *Transplantation*. 2019 Feb;103(2):220–2.
- 5 Delis S, Dervenis C, Lytras D, Avgerinos C, Soloway M, Ciancio G. Liver transplantation techniques with preservation of the natural venovenous bypass: Effect on surgical resection of renal cell carcinoma invading the inferior vena cava. *World J Surg*. 2004 Jun;28(6):614–9.
- 6 Gorin MA, González J, Garcia-Roig M, Ciancio G. Transplantation techniques for the resection of renal cell carcinoma with tumor thrombus: A technical description and review. *Urol Oncol*. 2013 Nov;31(8):1780–7.
- 7 Ji ZG, Xue C, Li HZ, Wang HJ, Xie Y, Liu GH. Piggyback liver transplant techniques in the surgical management of urological tumors with inferior vena cava tumor thrombus. *Chin Med J*. 2009 Sep;122(18):2155–8.
- 8 Neves RJ, Zincke H. Surgical treatment of renal cancer with vena cava extension. *Br J Urol*. 1987 May;59(5):390–5.
- 9 Ciancio G, Vaidya A, Savoie M, Soloway M. Management of renal cell carcinoma with level III thrombus in the inferior vena cava. *J Urol*. 2002 Aug;168(4 Pt 1):1374–7.
- 10 Joshi S, Gorin MA, Ayyathurai R, Ciancio G. Development of a surgical safety checklist for the performance of radical nephrectomy and tumor thrombectomy. *Patient Saf Surg*. 2012 Dec;6(1):27.
- 11 Fukazawa K, Gologorsky E, Naguit K, Pretto EA Jr., Salerno TA, Arianayagam M, et al. Invasive renal cell carcinoma with inferior vena cava tumor thrombus: cardiac anesthesia in liver transplant settings. *J Cardiothorac Vasc Anesth*. 2014 Jun;28(3):640–6.
- 12 Jibiki M, Iwai T, Inoue Y, Sugano N, Kihara K, Hyochi N, et al. Surgical strategy for treating renal cell carcinoma with thrombus extending into the inferior vena cava. *J Vasc Surg*. 2004 Dec;39(4):829–35.
- 13 Hevia V, Ciancio G, Gómez V, Álvarez S, Díez-Nicolás V, Burgos FJ. Surgical technique for the treatment of renal cell carcinoma with inferior vena cava tumor thrombus: Tips, tricks and oncological results. *Springerplus*. 2016 Feb;5:132.
- 14 Dellaportas D, Arkadopoulos N, Tzanoglou I, Bairamidis E, Gemenetzis G, Xanthakos P, et al. Technical intra-operative maneuvers for the management of inferior vena cava thrombus in renal cell carcinoma. *Front Surg*. 2017 Sept;4:48.
- 15 Verghe DC, Loeser A, Kocot A, Spahn M, Riedmiller H. Tumor thrombus of inferior vena cava in patients with renal cell carcinoma – clinical and oncological outcome of 50 patients after surgery. *BMC Res Notes*. 2012 Jun;5:5.