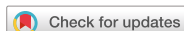

Review Article



OPEN ACCESS

Received: Sep 5, 2018

Revised: Oct 31, 2018

Accepted: Nov 4, 2018

Correspondence to

Byung-Ho Choe

Department of Pediatrics, School of Medicine,
Kyungpook National University, 130
Dongdeok-ro, Jung-gu, Daegu 41944, Korea.
E-mail: bhchoe@knu.ac.kr

Copyright © 2019 by The Korean Society of
Pediatric Gastroenterology, Hepatology and
Nutrition

This is an open-access article distributed
under the terms of the Creative Commons
Attribution Non-Commercial License (<https://creativecommons.org/licenses/by-nc/4.0/>)
which permits unrestricted non-commercial
use, distribution, and reproduction in any
medium, provided the original work is properly
cited.

Informed consent statement

For this report, we have gained consent from
the family of the patient as the attached image
file for the publication of this mini review.

Conflict of Interest

The authors have no financial conflicts of
interest.

Foreign Body Removal in Children Using Foley Catheter or Magnet Tube from Gastrointestinal Tract

Jae Young Choe¹ and Byung-Ho Choe²

¹Department of Emergency Medicine, School of Medicine, Kyungpook National University, Daegu, Korea

²Department of Pediatrics, School of Medicine, Kyungpook National University, Daegu, Korea

ABSTRACT

Foreign body (FB) ingestion of children is a common pediatric emergency requiring medical attention. Pediatric emergency physicians and gastroenterologists often encounter nervous and distressed situations, because of children presenting with this condition in the common clinical practice. When determining the appropriate timing and indications for intervention, physicians should consider multiple patient- and FB-related factors. The utilization of a flexible endoscopy is considered safe and effective to use in these cases, with a high success rate, for the effective extraction of FBs from the gastrointestinal tract of a child. Additionally, a Foley catheter and a magnet-attached Levin tube have been used for decades in the case of FB removal. Although their use has decreased significantly in recent times, these instruments continue to be used for several indications. Using a Foley catheter for this purpose does not require special training and does not necessarily require sedation of the patient or fluoroscopy, which serve as advantages of utilizing this method for foreign object retrieval. An ingested magnet or iron-containing FB can be retrieved using a magnet-attached tube, and can be effective to retrieve an object from any section of the upper gastrointestinal tract that can be reached. Simple and inexpensive devices such as Foley catheters and magnet-attached tubes can be used in emergencies such as with the esophageal impaction of disk batteries if endoscopy cannot be performed immediately (e.g., in rural areas and/or in patients presenting at midnight in a facility, especially in those without access to endoscopes or emergency services, or in any situation that warrants urgent removal of a foreign object).

Keywords: Foreign bodies; Foley catheterization; Magnets; Endoscopy; Esophagus; Children

INTRODUCTION

In the 21st century, pediatric endoscopy is being commonly performed, and by using this tool foreign bodies (FBs) can be removed without difficulty, even in newborns, if indicated [1,2].

The American Association of Poison Control Centers documented that 46% of the >2,159,000 FB ingestions reported occurred in children aged ≤5 years [3]. In children, 98% of FB ingestions are unintentional and occurred in the home environment. The FBs commonly ingested by children in these cases are coins, batteries, and magnets, as well as other small objects including pills and small toys [4].

The European Society of Gastrointestinal Endoscopy and the European Society for Paediatric Gastroenterology Hepatology and Nutrition recommend flexible endoscopy using rat-tooth forceps, polypectomy snares, and retrieval nets as a safe and effective procedure (with a high success rate) for the removal of FBs from the gastrointestinal (GI) tract of children who have ingested FBs [5].

Endoscopic FB removal in infants and toddlers is difficult especially for an inexperienced endoscopist, and for one who has to manage the removal of a FB without the proper equipment. General anesthesia is required to ensure that the procedure is performed safely, and an endotracheal intubation is the preferred procedure, particularly in many Western countries [5]. In some countries, preparing the endoscopic equipment including forceps and securing and maintaining operating rooms 24 hours a day, 7 days a week, 365 days a year for FB removal is considered an expensive endeavor [6]. Nevertheless, pediatric endoscopy is widely performed in clinical practice, and endoscopic FB removal is a recent trend and gold standard in pediatric endoscopy [7].

Historically, a Foley catheter and magnet-attached tube have been used for FB removal over the past few decades, and although their use has decreased significantly in recent times, they continue to be used for several cases and indications [8]. In this article, we have summarized the indications and advantages of continuing to utilize these devices for the removal of FBs in children.

THE REMOVE VS. OBSERVE DILEMMA

Most swallowed FBs appear in the stool of the child after 3–4 days; however, endoscopic removal or surgery is required in a few children or with extreme cases. Anatomically, the upper esophagus is the narrowest segment of the pediatric GI tract; therefore, this is the most common site of FB impaction. Considering a FB such as a coin, the possibility of spontaneous passage of the coin is the greatest when it is present in the lower third of the esophagus [7]. In such cases, the ingestion of food or drink can be tried as a means of coaxing or helping the process of propelling the object downward, or it may be allowed to spontaneously move ahead through the GI tract [9].

Connors et al. [10] suggested a specific principle for the elimination of blunt FBs in the esophagus. They recommend that FBs in the upper and the middle esophagus require removal instead of waiting for the object to pass through the GI tract on its own. However, patients with FBs lodged in the lower esophagus could be observed over 24 hours because in approximately 60% of such cases, the FB will be spontaneously eliminated, and these patients can be discharged after observation and review. If the FB is not easily eliminated, confirmatory radiological examination is required, after which it is usually determined that the FB will subsequently then need to be removed. This waiting process helps to determine the cases where waiting or action are appropriate, and helps to avoid unnecessary invasive procedures and can reduce medical costs and the use of resources.

OPTIMAL TIMING FOR FB REMOVAL

Optimal indications and/or the timing of intervention should consider the patient's general condition, the size, the location, and the type of the FB, as well as the time interval since the

initial ingestion of the object. The appropriate method and timing should be determined on the basis of these factors. A few FBs need removal within 2 hours, regardless of the patient's food intake (fasting vs. non-fasting status). However, a few FBs do not require immediate removal, and patients can be safely observed while awaiting elimination at home.

When the FB itself is expected to cause or has already caused injury to the GI tract, the timing of removal is important in that case. Prolonged retention of disk batteries in the GI tract may cause pressure necrosis of the GI mucous membrane, heavy metal poisoning, and corrosion secondary to the battery solution [11]. Notably, esophageal FBs may cause complications including ulcers, perforations, and fistulas in that region of the body (**Figs. 1 and 2**). Symptomatic FBs require emergency removal within 2 hours if excessive oral secretions are not controlled, regardless of the location. In asymptomatic cases such as coin impaction, urgent removal is required within 24 hours [12]. We use an orogastric Levin tube in special situations for the removal of disk batteries lodged in the mid-to-lower esophagus, if endoscopic removal is not possible to use immediately in that case.

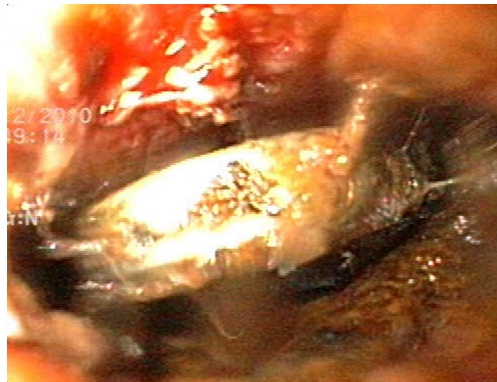

Fig. 1. The image shows disk battery impaction in the upper esophagus of a 23-month-old infant, causing adjacent ulcers and surrounding mucosal edema in the patient. The battery could not be removed despite several trials using various devices including a rigid esophagoscope, a flexible pediatric endoscope with a pediatric rat-tooth grasping forceps, a larger adult-size endoscope with pelican type grasping forceps, as well as the prior unsuccessful attempts to push it further into the stomach. The outer cap of the device used for endoscopic variceal ligation was applied at the end of an adult endoscope, which was used concomitantly with the pelican-type grasping forceps, to successfully extract the disk battery from the infant.

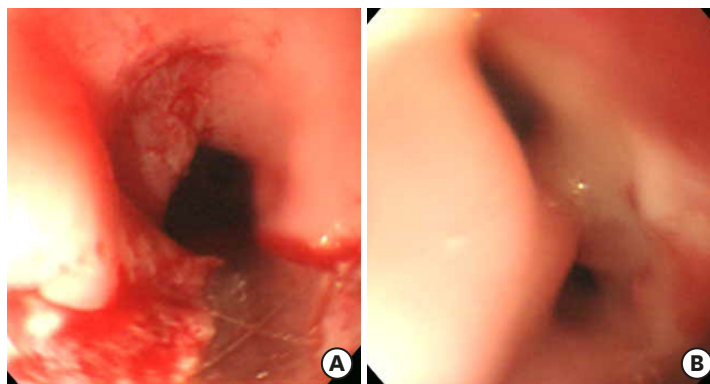


Fig. 2. (A) Disk battery impacted at mid esophagus in 24 months-old infant. It could not be grasped by forcep because it was partially embedded under the esophageal wall. It could be removed out of esophageal wall by repetitive rubbing of endoscope with disk battery and removed using retrieval net. (B) After removal of the impacted battery, this boy was admitted to intensive care unit to treat mediastinitis. The follow-up endoscopy revealed trachea-esophageal fistula.

OPTIMAL REMOVAL TECHNIQUE

Endoscopic FB removal is the conventional and safest method to use to remove a FB, with a success rate of approximately 95% [13]. Technological advances have led to the development of newer endoscopic instruments with various functions; thus, the incidence of using endoscopic FB removal is now an easier process and procedure, and guidelines have been updated accordingly on the best techniques to achieve success in this regard [5,12]. A retrieval net is used to remove disk batteries measuring 2 cm in diameter, because the action of grasping a disk battery with the use of pediatric grasping forceps is difficult. However, retrieval nets of varying sizes for use with pediatric endoscopes may not be easily available for all healthcare professionals who may not have access to these resources. Furthermore, access to and the use of disposable retrieval nets are not covered by medical insurance in a few countries, including our own. A practical difficulty in real-world clinical settings is that pediatric endoscopes with the accompanying equipment (forceps, and nets, among other such items), a pediatric endoscopist, an anesthesiologist, as well as an appropriate operating room may not always be available at all times and at all places for the management of infants and young children who present with the need for a FB removal.

FOLEY CATHETER METHOD FOR FB REMOVAL

In 1966, Bigler [14] first reported the use of a Foley catheter for the successful extraction of smooth esophageal FBs from 2 children. The Foley catheter method remains a useful technique to remove upper esophageal FBs. Usually, plain radiography can confirm the location of the FB and the distance between the child's oral cavity and the FB. The diameter of the FB determines the balloon size to be used in the procedure. The catheter is inserted into the esophagus through the child's mouth, and its tip is positioned distal to the end of the FB. After careful placement, the balloon is inflated, and the catheter is carefully pulled out to retrieve the FB. Previous studies have reported the use of air or normal saline to inflate the catheter balloon (the amount of saline varied from 5 mL–30 mL) [15].

Indications for the removal of FBs using a Foley catheter are radiopaque blunt FBs which are seen to be lodged in the upper and middle esophagus, if removal is attempted within 48 hours of swallowing the FB. Removal of disk batteries may be attempted using a Foley catheter to prevent esophageal wall necrosis, and perforation in patients in whom endoscopic FB removal cannot be performed in specific cases. This blind removal method may be attempted if the disk battery is lodged in the esophagus for <2 hours. However, if endoscopic removal is not possible at the center/location, the Foley catheter method may be attempted even beyond 4 hours post ingestion of the disk batteries; however, before this is suggested an endoscopic confirmation is essential to rule out a post-procedural injury.

The advantages of FB removal using a Foley catheter are that the operator does not require special training, and that the procedure need not necessarily be performed under sedation or fluoroscopic guidance. Additionally, a Foley catheter is readily available and can be used for an emergency procedure by a clinician who is familiar with the principles of the procedure. In these instances, even the YouTube platform of videos could offer useful lessons in this context. Fluoroscopy was used extensively in the past, and many clinicians will be familiar with these types of procedures. However, Agarwala et al. [16] reported that 93.7% of the successful FB removals using a Foley catheter in 302 patients were achieved without the use of fluoroscopic

guidance. We used a Foley catheter for FB removal in 30 children, without fluoroscopic guidance with a success rate of 86.7%. No statistically significant difference was observed in the success or complication rate between the sedation and the non-sedation group, which suggests that unnecessary radiation and sedatives can be avoided in such cases [8].

Reports in the literature have described a success rate of $\geq 85\%$, and the procedure is associated with a few adverse effects [17-19]. The catheter should be inserted slowly to prevent its entry into the airway, and careful monitoring is required for symptoms of airway irritation, including cough or dyspnea; however, minor adverse events could occur. For example, an overexpansion of the balloon of the Foley catheter may cause esophageal injury or a laryngospasm, whereas insufficient inflation of the balloon may not successfully retrieve the FB, necessitating a repeat procedure to gain a successful result. In some cases, the catheter insertion may be difficult without sedation because the patient might bite the catheter; however, using an airway or mouthpiece for endoscopy might be useful in such cases. Insertion through the nasal cavity may cause epistaxis and trauma; therefore, at our hospital, we prefer the oral route for the use of catheter insertion in these cases.

Successful removal of an esophageal FB using a Foley catheter is determined by the time interval between swallowing the FB and the retrieval procedure, and the patient's age. Connors [20] suggested removal of a FB within 24 hours to avoid esophageal inflammation that develops thereafter, if the removal is postponed after that time. Schunk et al. [21] reported that the success rate was 96% if the FB is removed before 3 days, and 50% if it is removed after 4 days. Towbin et al. [22] reported that infants aged <18 months and those with an widened tracheoesophageal interface associated with focal tracheal narrowing, show a high risk of esophageal edema and failure of FB retrieval using a Foley catheter.

Suspected total esophageal obstruction with an inability to manage excessive oral secretions, suspected esophageal perforation, multiple FBs, and a sharp FB are contraindications to the use of a Foley catheter. Notably, the patients with symptoms of airway obstruction such as dyspnea should not try to this procedure to removal of the FB, to avoid the risk of developing an airway stenosis [21].

Two large-scale studies analyzed the usefulness of a Foley catheter for FB removal, prior to the widespread availability and use of pediatric video endoscopes. A study performed by McGuirt [23] reported that there were no serious complications or mortality in the 1,512 cases studied. Among the $>2,500$ patients included in the study performed by the Society for Pediatric Radiology, potentially serious but reversible hypoxia occurred during the procedure in only 1 child with congenital heart disease [17].

MAGNET-ATTACHED LEVIN TUBE METHOD FOR FB REMOVAL

The use of a magnet for removal of FBs from the upper GI tract was first reported in 1945 and has been used since that time for the removal of FBs [24,25]. In this procedure, a magnet is inserted into the end of an orogastric tube to locate a magnetic object or one that is made of iron, which is removed through the mouth during the procedure to successfully lift the FB [26-28]. If the object ingested is a magnetic object or one that is made of iron, it can be safely removed from any segment of the upper GI tract that can be accessed by the magnet-attached tube.

Magnets are the fourth most common type of FBs ingested by children aged <5 years [29]. In the reports by Talvard et al. [30] and Waters et al. [31], among all children who swallowed magnets and needed treatment, 60% and 65% of them swallowed more than one magnet, 33% and 32% of them were treated with endoscopic intervention, and 58% and 74% of them needed surgery, respectively. The prevailing discipline notes with caution that the newly developed magnets containing neodymium, boron, and iron are approximately 10-fold stronger than the common used conventional magnets. In the late 2000s, several reports indicated an increase in the ingestion of neodymium magnets [32]. Ingestion of these types of magnets causes serious complications to the patient, because of the fact that these metallic elements can attract each other across multiple bowel loops [33].

The use of neodymium magnets (which are stronger than earth magnets), inserted into a Levin tube with its ends cut off, in order that the magnets can be placed in a fixed position (**Fig. 3**), is recommended for FB removal. A thicker Levin tube enables the introduction of a stronger neodymium magnet to assist with the FB removal procedure. Regardless of age, a tube with a larger diameter is preferred if the child can swallow the tube safely. To initiate this procedure, the tube with the attached magnet is inserted through the mouth and maneuvered to the site at which the FB is expected to be present. Air is injected using a 50 mL syringe to enable gastric distention via the side hole of the tube. The patient is placed in both the supine and the prone positions to ensure that the magnet is attached to the FB, which is confirmed radiographically, after which the tube is gradually withdrawn from the mouth and extracts the FB from the patient.

A Foley catheter is useful for removal of FBs only from the upper and the mid esophagus. The Levin tube scores over the Foley catheter, in that it facilitates the safe removal of a FB even from the lower esophagus and/or the upper proximal duodenum. However, the Levin tube is not useful for non-magnetic or non-iron-containing objects in that case. Radiography or fluoroscopy procedures may be necessary to be performed before the FB removal, to confirm that the magnet is attached to the FB. During retrieval, there is a risk of separation of the FB and the magnet, at the 3 areas of anatomical constriction along the vertical course of the esophagus.

The success rate of this procedure is higher if a stronger magnet is attached to the tube, a smaller FB is being removed, and if the FB is of a magnetic material rather than iron-containing FB. Older age and better cooperation from the patient may be factors that could also improve the success rate. Therefore, sedation may improve the success rate, particularly in extremely young or highly apprehensive patients. In several cases, the administration of sedatives relaxes the esophageal sphincter and spontaneously expels the FB. The success rate



Fig. 3. Magnetic tip Levin tube.

of a fluoroscopically guided procedure is higher than that of a blind procedure; however, the radiation hazards associated with the former suggested intervention should be considered. In cases where the magnet-attached tube and the FB tend to repeatedly get separated in the upper esophagus, a Foley catheter can be used for FB removal from that location. The magnet-attached tube and the Foley catheter can be used as complementary methods to facilitate easier removal of FBs, because each method overcomes the limitations of the other type of method that could be utilized in these cases.

Arana et al. [34] attempted to extract batteries with a magnet probe, but the method failed in 4 of 36 patients. It is emphasized that all needles and pins can be removed from the stomach with a magnet probe except open safety pins. Volle et al. [35,36] reported that hospitalization, anesthesia, surgery, or subsequent radiography was not required and that all patients remained asymptomatic in those cases.

ADVANTAGE OVER ENDOSCOPIC REMOVAL

Although endoscopic FB removal is the gold standard for most cases, alternative methods using a Foley catheter or a magnet-attached Levin tube could be considered in specific situations. It should be noted that FB removal using a Foley catheter requires a shorter waiting time in order to start the procedure to removal of the object. Thus, patients are subjected to pain and anxiety for a shorter time, and it brings sooner relief to caregivers. Moreover, it reduces the risk of complications such as esophageal mucosal injury. Kang et al. [8] reported that the waiting time for an endoscopy was 18.1 ± 13.7 hours and that for the Foley catheter method was 2.0 ± 1.1 hours. Kim et al. [37] reported that the mean difference in waiting times between the aforementioned procedures (performed using rigid scopes) was 265 and 38 minutes, respectively.

A magnet-tipped orogastric tube was observed to be the most rapid method for disk battery removal, associated with a high success rate compared with balloon extraction, flexible endoscopy, and rigid esophagoscopy [38].

Endoscopic removal requires the patient to be fasting for a minimum of 4–8 hours, depending on the patient's age. The magnet-attached Levin tube technique is effective even in patients in the non-fasting state.

In terms of cost-effectiveness, there exists a considerably large difference between the Foley catheter and the endoscopic removal methods in regards to the costs of using these interventions. Kang et al. [8] reported a cost of \$428 for an endoscopy and \$113 for the Foley catheter method. Kim et al. [39] reported costs of \$558 and \$61, respectively for the aforementioned procedures, whereas Little et al. [17] reported costs of \$2,440 and \$995, respectively. Dokler et al. [40] reported that the hospital costs associated with endoscopic removal were 300%–800% higher than those associated with Foley catheter extraction. In terms of medical personnel and equipment, FB removal using a Foley catheter and magnet-tipped tube can be performed, even with the assistance of a single caregiver to hold the patient and keep the patient comfortable during the procedure. In contrast, endoscopic FB removal requires a specialized medical team and equipment to be able to safely perform the procedure. Endoscopic removal requires the establishment of intravenous access to inject sedatives, which are required for this procedure. Additionally, adverse drug reactions

Table 1. Indications for foreign body removal using a Foley catheter and a magnet-attached Levin tube

Indication/procedure	Foley catheter	Mag net-attached Levin tube
Location of the foreign body	Esophagus (higher than the mid-esophagus)	Esophagus, stomach, proximal duodenum
Characteristics of foreign bodies	Ideal for coins and other blunt radiopaque objects	Disk batteries, needles, pins, magnets (neodymium, iron-containing foreign body), among other such items
Timing of procedure	<24–72 hours	Can be performed at any time
Indicated for	Disk batteries lodged in the esophagus for <2 hours (may be performed even if the FB is lodged for >2 hours if emergency endoscopy cannot be attempted)	When multiple magnets (or a magnet+metallic object) are ingested (to prevent fistula formation)
Common indication	When an intravenous line cannot be established for endoscopic access When the risk of infusion with sedatives is high (infants with cyanotic congenital heart disease)	

could occur when performing this procedure, and continuous monitoring is needed during all stages of the procedure up and until the patient is awake. A few patients need general anesthesia in an operating room to safely perform this intervention. However, removal using a Foley catheter and/or a magnet-attached tube does not require routine sedation of the patient. Moreover, even beginners can easily perform the procedure by following appropriate principles. No significant difference was observed in the success rate of this procedure between junior and senior residents at our hospital, although the success rate was better in procedures performed by experienced physicians. However, endoscopic techniques typically require pediatric endoscopists with expertise in handling a variety of equipment including a transparent cap, retrieval devices, polypectomy snares, and forceps.

Table 1 shows the comparison between the indications for FB removal using a Foley catheter vs. a magnet-attached Levin tube. In patients with FBs identified in the upper GI tract, the most important determinant of the removal method is monitoring and maintaining the patient's safety. In the absence of definite contraindications to their use, a Foley catheter and/or a magnet-attached tube can be used for FB removal in specific situations.

CONCLUSION

A Foley catheter or magnet-attached Levin tube can be used promptly (and without significant complications) in emergencies including the removal of esophageal disk batteries or several magnets, or metallic objects in the upper GI tract, if the use of an immediate endoscopic intervention is not possible. This method is also useful in situations where an endoscopist may not be easily available, or in areas where endoscopic equipment is unavailable.

Even in the 21st century, a Foley catheter and a magnet-attached Levin tube are useful for the removal of FBs from the upper GI tract, particularly in pediatric emergencies.

REFERENCES

1. Seo JK, Choe BH. Endoscopic removal of gastrointestinal foreign bodies in 3 newborn infants immediately after birth. *Korean J Gastrointest Endosc* 1998;18:87-91.
2. Choe BH, Park GS, Hwang JB. Endoscopic removal of foreign bodies from the upper gastrointestinal tract in children: management of 78 cases in Taegu, Korea. *Korean J Gastrointest Endosc* 2000;20:6-13.

3. Gummin DD, Mowry JB, Spyker DA, Brooks DE, Fraser MO, Banner W. 2016 Annual Report of the American Association of Poison Control Centers' National Poison Data System (NPDS): 34th annual report. *Clin Toxicol (Phila)* 2017;55:1072-252.
[PUBMED](#) | [CROSSREF](#)
4. Choe BH, Nho US. Rescue of child with accidental overingestion of iron tablets by gastroscopy. *Korean J Gastrointest Endosc* 1997;17:801-5.
5. Tringali A, Thomson M, Dumonceau JM, Tavares M, Tabbers MM, Furlano R, et al. Pediatric gastrointestinal endoscopy: European Society of Gastrointestinal Endoscopy (ESGE) and European Society for Paediatric Gastroenterology Hepatology and Nutrition (ESPGHAN) Guideline executive summary. *Endoscopy* 2017;49:83-91.
[PUBMED](#)
6. Kim JO, Hong EH, Choe BH, Cho MH, Seo HE, Lim HR, et al. Comparison of endoscopic removal of disk batteries in children. *Korean J Pediatr Gastroenterol Nutr* 2007;10:147-56.
[CROSSREF](#)
7. Seo JK. Endoscopic management of gastrointestinal foreign bodies in children: a clinical practice guideline. *Korean J Pediatr Gastroenterol Nutr* 2007;10:64-9.
8. Kang JH, Jung HJ, Suh JK, Park JS, Park HJ, Chu MA, et al. Feasibility of foley catheter prior to endoscopy for the removal of esophageal coin in children. *Korean J Pediatr Gastroenterol Nutr* 2011;14:251-7.
[CROSSREF](#)
9. Joyamaha D, Connors GP. Managing pediatric foreign body ingestions. *Mo Med* 2015;112:181-6.
[PUBMED](#)
10. Connors GP, Chamberlain JM, Ochsenschlager DW. Foley catheter and esophageal foreign bodies. *Pediatrics* 1995;96:791.
[PUBMED](#)
11. Lee JH, Lee JH, Shim JO, Lee JH, Eun BL, Yoo KH. Foreign body ingestion in children: should button batteries in the stomach be urgently removed? *Pediatr Gastroenterol Hepatol Nutr* 2016;19:20-8.
[PUBMED](#) | [CROSSREF](#)
12. Kramer RE, Lerner DG, Lin T, Manfredi M, Shah M, Stephen TC, et al. Management of ingested foreign bodies in children: a clinical report of the NASPGHAN Endoscopy Committee. *J Pediatr Gastroenterol Nutr* 2015;60:562-74.
[PUBMED](#) | [CROSSREF](#)
13. Magalhães-Costa P, Carvalho L, Rodrigues JP, Túlio MA, Marques S, Carmo J, et al. Endoscopic management of foreign bodies in the upper gastrointestinal tract: an evidence-based review article. *GE Port J Gastroenterol* 2015;23:142-52.
[PUBMED](#) | [CROSSREF](#)
14. Bigler FC. The use of a Foley catheter for removal of blunt foreign bodies from the esophagus. *J Thorac Cardiovasc Surg* 1966;51:759-60.
[PUBMED](#)
15. Macpherson RI, Hill JG, Othersen HB, Tagge EP, Smith CD. Esophageal foreign bodies in children: diagnosis, treatment, and complications. *AJR Am J Roentgenol* 1996;166:919-24.
[PUBMED](#) | [CROSSREF](#)
16. Agarwala S, Bhatnagar V, Mitra DK. Coins can be safely removed from the esophagus by Foley's catheter without fluoroscopic control. *Indian Pediatr* 1996;33:109-11.
[PUBMED](#)
17. Little DC, Shah SR, St Peter SD, Calkins CM, Morrow SE, Murphy JP, et al. Esophageal foreign bodies in the pediatric population: our first 500 cases. *J Pediatr Surg* 2006;41:914-8.
[PUBMED](#) | [CROSSREF](#)
18. Mariani PJ, Wagner DK. Foley catheter extraction of blunt esophageal foreign bodies. *J Emerg Med* 1986;4:301-6.
[PUBMED](#) | [CROSSREF](#)
19. Stack LB, Munter DW. Foreign bodies in the gastrointestinal tract. *Emerg Med Clin North Am* 1996;14:493-521.
[PUBMED](#) | [CROSSREF](#)
20. Connors GP. A literature-based comparison of three methods of pediatric esophageal coin removal. *Pediatr Emerg Care* 1997;13:154-7.
[PUBMED](#) | [CROSSREF](#)
21. Schunk JE, Harrison AM, Corneli HM, Nixon GW. Fluoroscopic foley catheter removal of esophageal foreign bodies in children: experience with 415 episodes. *Pediatrics* 1994;94:709-14.
[PUBMED](#)

22. Towbin R, Lederman HM, Dunbar JS, Ball WS, Strife JL. Esophageal edema as a predictor of unsuccessful balloon extraction of esophageal foreign body. *Pediatr Radiol* 1989;19:359-60.
[PUBMED](#) | [CROSSREF](#)
23. McGuirt WF. Use of Foley catheter for removal of esophageal foreign bodies. A survey. *Ann Otol Rhinol Laryngol* 1982;91:599-601.
[PUBMED](#) | [CROSSREF](#)
24. Equen M. A new magnet for foreign bodies in the food and air passages. *JAMA* 1945;127:87-8.
[CROSSREF](#)
25. Silber S, Epstein BS. The peroral removal of certain swallowed foreign bodies without endoscopy; introducing a new device utilizing the alnico magnet. *N Y State J Med* 1947;47:1122-4.
[PUBMED](#)
26. Kuhns DW, Dire DJ. Button battery ingestions. *Ann Emerg Med* 1989;18:293-300.
[PUBMED](#) | [CROSSREF](#)
27. McDermott VG, Taylor T, Wyatt JP, MacKenzie S, Hendry GM. Orogastric magnet removal of ingested disc batteries. *J Pediatr Surg* 1995;30:29-32.
[PUBMED](#) | [CROSSREF](#)
28. Volle E, Beyer P, Kaufmann HJ. Therapeutic approach to ingested button-type batteries. Magnetic removal of ingested button-type batteries. *Pediatr Radiol* 1989;19:114-8.
[PUBMED](#) | [CROSSREF](#)
29. Mowry JB, Spyker DA, Brooks DE, McMillan N, Schauben JL. 2014 Annual Report of the American Association of Poison Control Centers' National Poison Data System (NPDS): 32nd annual report. *Clin Toxicol (Phila)* 2015;53:962-1147.
[PUBMED](#) | [CROSSREF](#)
30. Talvard M, Mouttalib S, Flaum V, Viala J, Galinier P, Olives JP, et al. Magnet ingestions in children: a French multicenter study. *Arch Pediatr* 2015;22:32-8.
[PUBMED](#) | [CROSSREF](#)
31. Waters AM, Teitelbaum DH, Thorne V, Bousvaros A, Noel RA, Beierle EA. Surgical management and morbidity of pediatric magnet ingestions. *J Surg Res* 2015;199:137-40.
[PUBMED](#) | [CROSSREF](#)
32. Agbo C, Lee L, Chiang V, Landscahft A, Kimia T, Monuteaux MC, et al. Magnet-related injury rates in children: a single hospital experience. *J Pediatr Gastroenterol Nutr* 2013;57:14-7.
[PUBMED](#) | [CROSSREF](#)
33. Strickland M, Rosenfield D, Fecteau A. Magnetic foreign body injuries: a large pediatric hospital experience. *J Pediatr* 2014;165:332-5.
[PUBMED](#) | [CROSSREF](#)
34. Arana A, Hauser B, Hachimi-Idrissi S, Vandenplas Y. Management of ingested foreign bodies in childhood and review of the literature. *Eur J Pediatr* 2001;160:468-72.
[PUBMED](#) | [CROSSREF](#)
35. Volle E, Beyer P, Kaufmann HJ, Hanel D. Removal of swallowed metallic foreign bodies by orogastric magnetic intubation. *Z Kinderchir* 1987;42:346-9.
[PUBMED](#)
36. Volle E, Hanel D, Beyer P, Kaufmann HJ. Ingested foreign bodies: removal by magnet. *Radiology* 1986;160:407-9.
[PUBMED](#) | [CROSSREF](#)
37. Kim MK, Kim SW, Sungwoo JC, Park HS. Clinical evaluation of foley catheter technique for removal of blunt esophageal foreign bodies. *Korean J Otolaryngol-Head Neck Surg* 1985;28:793-5.
38. Ham PB 3rd, Ellis MA, Simmerman EL, Walsh NJ, Lalani A, Young M, et al. Analysis of 334 cases of pediatric esophageal foreign body removal suggests that traditional methods have similar outcomes whereas a magnetic tip orogastric tube appears to be an effective, efficient, and safe technique for disc battery removal. *Am Surg* 2018;84:1152-8.
[PUBMED](#)
39. Kim GW, Kim SY, Lee CC, Kim C, Jung YS. Removal of esophageal blunt foreign bodies by using a foley balloon catheter in the emergency department. *J Korean Soc Emerg Med* 2001;12:359-68.
40. Dokler ML, Bradshaw J, Mollitt DL, Tepas JJ 3rd. Selective management of pediatric esophageal foreign bodies. *Am Surg* 1995;61:132-4.
[PUBMED](#)