

was the congenital bifid septum separated by a wide layer of tissue.

In our opinion, the importance of this case involves the intraoperative detection of the isolated congenital nasal bifid septum, which has not been previously described, and the aesthetic repair of this congenital anomaly with a case-specific junctional surgical technique.

References

1. Hartikainen-Sorri AL, Sorri M, Vainio-Mattila J, et al. Aetiology and detection of congenital nasal deformities. *Int J Pediatr Otorhinolaryngol* 1983;6:83-8.
2. Neskey D, Eloy JA, Casiano RR. Nasal, septal, and turbinate anatomy and embryology. *Otolaryngol Clin North Am* 2009;42:193-205.
3. Losey JE, Kirschner RE, Whitaker LA, et al. Congenital nasal anomalies: a classification scheme. *Plast Reconstr Surg* 2004;113:676-89.
4. Rawat SS, Gupta HK. Congenital double columella. *Br J Plast Surg* 1975;28:153-4.

botulinum toxin injections are used to reduce the volume of hypertrophic calf muscles, and at the other end, silicone implants or autologous fat may be used to add volume. The shape of the calf is determined by a number of factors: the soleus and gastrocnemius musculature, the length and orientation of the bones, and the distribution of subcutaneous fat. Since Carlsen first performed calf augmentation with carved silastic foam implants inserted beneath the deep fascia of the calf in 1972, various methods of inserting silicone gel-filled implants and silicone rubber implants have been reported [1]. Inserting silicone implants into the calf has disadvantages; early postoperative complications include hematoma, seroma, wound disruption and infection, and later complications include capsular contracture, extrusion, rupture, and palpability. However, it is generally a safe procedure with a low incidence of complications [2]. Given the infrequent occurrence of complications, it is not surprising that few reports containing radiological or pathological images documenting capsular contracture have been published [3].

A 50-year-old female presented with a palpable hard implant in her left calf (Fig. 1). She complained of discomfort during walking. She had undergone calf

Capsular Contracture after Calf Augmentation with Silicone Implant Insertion

Bommie Florence Seo, Jong Yun Choi, Jimin Kim, Deuk Young Oh

Department of Plastic and Reconstructive Surgery, College of Medicine, The Catholic University of Korea, Seoul, Korea

Correspondence: Deuk Young Oh
Department of Plastic and Reconstructive Surgery, College of Medicine, The Catholic University of Korea, 222 Banpo-daero, Seocho-gu, Seoul 06591, Korea
Tel: +82-2-2258-2842, Fax: +82-2-594-7230
E-mail: ohdeuk1234@hanmail.net

No potential conflict of interest relevant to this article was reported.

Received: 11 Mar 2015 • Revised: 27 May 2015 • Accepted: 9 Jun 2015
pISSN: 2234-6163 • eISSN: 2234-6171
<http://dx.doi.org/10.5999/aps.2015.42.5.642> • Arch Plast Surg 2015;42:642-645

Copyright © 2015 The Korean Society of Plastic and Reconstructive Surgeons
This is an Open Access article distributed under the terms of the Creative Commons Attribution Non-Commercial License (<http://creativecommons.org/licenses/by-nc/3.0/>) which permits unrestricted non-commercial use, distribution, and reproduction in any medium, provided the original work is properly cited.

The legs are an aesthetically important part of the body, and an increasing number of patients desire calf-contouring procedures to improve the overall appearance of their legs. At one end of the spectrum,

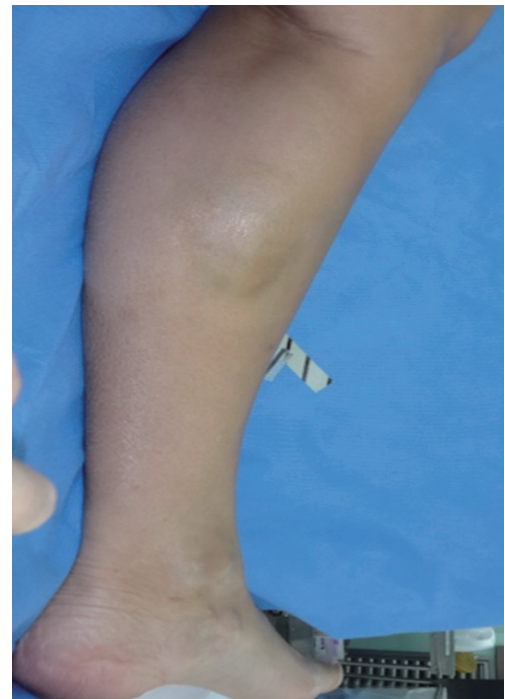

Fig. 1. Preoperative view of the left lower leg. The implant and its capsule are visible in the medial aspect of the calf.

augmentation surgery 20 years previously in the United Kingdom. No information was available about the type of implant or the plane of insertion. Physical examination revealed a firm, visible, and immobile implant in the posteromedial aspect of the left calf. No signs of inflammation were noted. A horizontal scar 4 cm in length was observed in the popliteal crease. Magnetic resonance imaging (MRI) was performed to assess the plane of insertion and to check for rupture. The implant was located beneath the deep fascia of the lower leg, at the medial aspect of the medial gastrocnemius muscle. High signal intensity in T2-weighted images and low signal intensity in T1-weighted images were observed. The implant was surrounded by a 3-mm layer of fibrotic or calcified tissue with low intensity in both T1- and T2-weighted images (Fig. 2).

The patient did not desire reinsertion, and preferred to leave her right calf implant inserted. Therefore, we planned to remove the left implant with simultaneous capsulotomy or capsulectomy. Under general anesthesia, a 4-cm incision was made along the scar from the previous operation. Dissection was performed through the subcutaneous adipose tissue until the deep fascia was reached. An incision was made in the fascia to expose a thick, calcified capsule. This capsule was incised and an intact, lenticular-shaped, solid silicone implant 5 cm

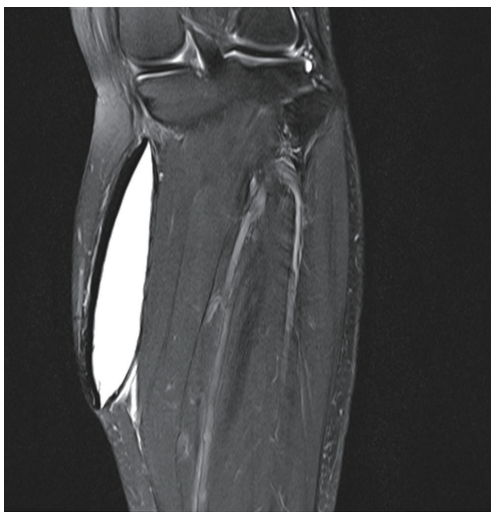

Fig. 2. Magnetic resonance imaging of the left lower leg revealed a 5.0 × 2.1 × 11.8-cm foreign body in the medial aspect of the left medial gastrocnemius muscle, displacing the muscle laterally. The foreign body was well marginated, with a high signal intensity in the T2-weighted image. The fibrotic capsule with low signal intensity was approximately 3 mm thick.

in width and 13 cm in length was exposed. No signs of extracapsular rupture were noted, and the implant was extracted. Since the capsule was very thick and severely calcified, we performed a capsulectomy (Fig. 3). The capsule was 3.2 mm thick on average and had multiple calcified nodules. Histopathological analysis revealed a thick layer of wavy collagen bundles with focal calcifications (Fig. 4). An additional incision was made at the distal end of the capsule to facilitate removal. A negative suction drain was inserted into the subfascial space, and the incision was closed layer by layer. The drain was removed two days after surgery, and the patient's leg healed well without any incidence of hematoma, seroma, infection, or sensory loss (Fig. 5). Ambulation was restricted to minimal movement for one week.

Calf augmentation using silicone implants is a relatively safe, reproducible procedure with a low reported incidence of complications. However, as with silicone implants inserted into the breast, implant palpability, asymmetry, rupture, extrusion, infection, or capsular contracture may occur [4]. Capsular contracture in the calf has been reported to have an incidence of approximately 3% to 4% [2].

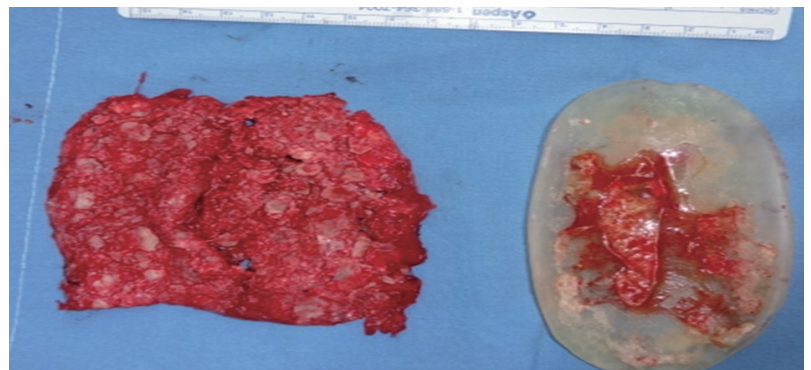


Fig. 3. The capsulectomy specimen and silicone implant. Multiple nodular calcifications are seen along the outer surface of the capsule.

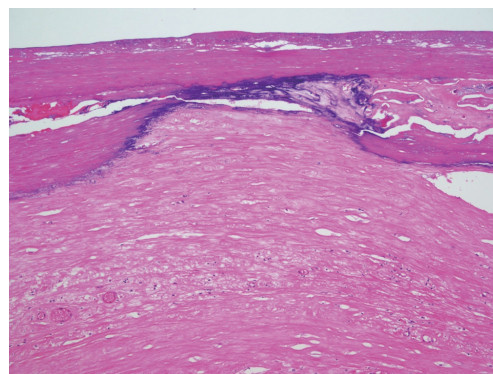


Fig. 4. Histopathological findings show a thick layer of wavy collagen bundles (H&E, ×200).

The contracture rates are higher when implants are placed in subcutaneous pockets compared to subfascial pockets, submuscular pockets, or suprapariosteal pockets [2]. While a diverse range of implant types, including silastic foam, gel-filled silicone, solid silicone, and cohesive silicone gel with soft silicone rubber have been used, no studies have compared the risk of capsular contracture depending on the implant type [2].

The mechanism of capsular contracture in breast augmentation has been the focus of much attention, but has yet to be fully elucidated. The subclinical infection hypothesis has led surgeons to use caution when manipulating any implant, and some recommend povidone-iodine irrigation of the pocket. Others have proposed that capsular contracture is a result of cystic fibrosis, or a form of hypertrophic scar tissue [5]. Smoking has been found to be a major risk factor, and is a relative contraindication to augmentation. Capsular contracture in calf augmentation may differ from contracture in breast augmentation because calf implants are not exposed to any ductal tissue or endogenous flora; however,

further studies are necessary to evaluate this possibility.

While capsular contracture may be estimated in a clinical evaluation, imaging modalities may aid in the diagnosis. The radiological findings associated with silicone implants and subsequent complications have been extensively described for breast augmentation [3]. Plain X-rays may reveal the calcified outline of the capsule but are otherwise unrevealing. Ultrasonography, computed tomography, or MRI may show a thickened fibrous capsule. Zahavi et al. [5] have reported that greater capsule thickness observed in ultrasonography or MRI findings of the breast correlates with more severe capsular contracture. Capsule thickness averaging 1.39 mm on MRI correlates with a low degree of contracture severity, corresponding to a clinical Baker score of I or II, while capsules averaging 2.62 mm in thickness correlate with a higher degree of contracture, corresponding to a clinical Baker score of III or IV. The same correlation was found in ultrasonography at the thickness levels of 1.14 mm and 2.39 mm, respectively. They suggested a cutoff value of 2 mm to discriminate between thin and thick capsules.

Treatment consists of removing the implant, capsulectomy or capsulotomy, and drain placement. As in capsular contracture of the breast, a new pocket may be formed and implants may be inserted into this neopocket. However, no grading system exists for capsular contracture of the calf, and no standardized indications exist for surgery. Of course, any clinical signs of infection, pain, discomfort, malposition, or implant extrusion will inevitably require surgical removal. Otherwise, the surgeon and patient must contemplate the benefits and disadvantages before deciding on whether and when to intervene.

References

1. Niechajev I. Calf augmentation and restoration. *Plast Reconstr Surg* 2005;116:295-305.
2. Flores-Lima G, Eppley BL. Body contouring with solid silicone implants. *Aesthetic Plast Surg* 2009;33:140-6.
3. Duryea D, Petscavage-Thomas J, Frauenhoffer EE, et al. Linguine sign in musculoskeletal imaging: calf silicone implant rupture. *Skeletal Radiol* 2015;44:1157-60.
4. de la Pena-Salcedo JA, Soto-Miranda MA, Lopez-Salguero JF. Calf implants: a 25-year experience and an anatomical review. *Aesthetic Plast Surg* 2012;36:261-70.
5. Zahavi A, Sklair ML, Ad-El DD. Capsular contracture

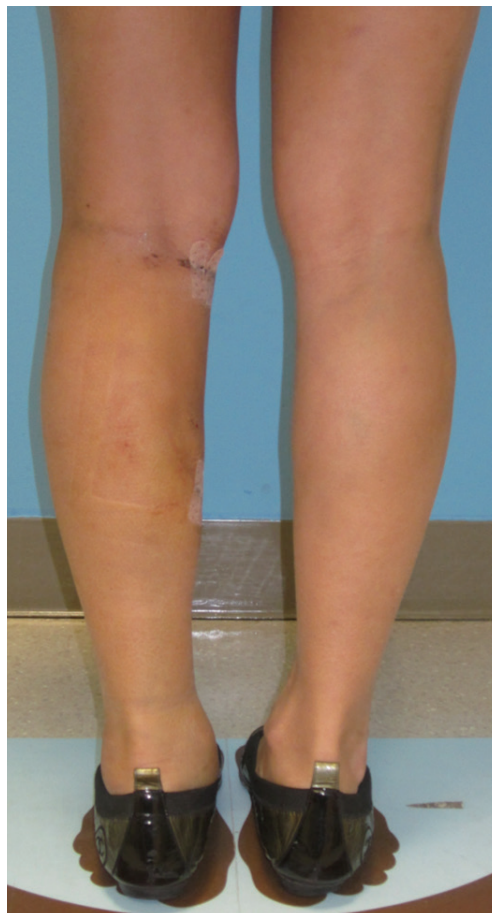

Fig. 5.

The patient standing at three weeks postoperatively. The cranial and caudal incisions had healed well, and the asymmetry between the legs was not prominent.

of the breast: working towards a better classification using clinical and radiologic assessment. *Ann Plast Surg* 2006;57:248-51.

The Modified Trap Door Flap for Reconstruction of Posterior Pinna and Concha Defects

Cormac W Joyce¹, Shazarina Sharahan¹,
Padraic J Regan^{1,2}

¹Department of Plastic Surgery, University Hospital Galway, Galway; ²Department of Surgery, National University of Ireland, Galway, Ireland

Correspondence: Cormac W Joyce
Department of Plastic Surgery, Saint Vincent's University Hospital,
27 Rowanbyrn, Blackrock, County Dublin, Ireland
Tel: +353-876815514, Fax: +353-876815514, E-mail: cjoyce78@hotmail.com

No potential conflict of interest relevant to this article was reported.

Received: 17 Dec 2014 • Revised: 12 Jun 2015 • Accepted: 15 Jun 2015
pISSN: 2234-6163 • eISSN: 2234-6171
<http://dx.doi.org/10.5999/aps.2015.42.5.645> • *Arch Plast Surg* 2015;42:645-647

Copyright © 2015 The Korean Society of Plastic and Reconstructive Surgeons
This is an Open Access article distributed under the terms of the Creative Commons Attribution Non-Commercial License (<http://creativecommons.org/licenses/by-nc/3.0/>) which permits unrestricted non-commercial use, distribution, and reproduction in any medium, provided the original work is properly cited.

The trap door flap is an excellent option for reconstruction of anterior pinna and conchal defects. It was first described by the senior author of this paper and it has been carried with excellent results on more than 50 patients in our institution. The flap is a simple one-stage procedure with very little donor site morbidity. Long-term aesthetic outcome is excellent with high patient satisfaction. We report on a modification of this procedure in order reconstruct a defect following excision of a lesion on the posterior aspect of the pinna.

A 90-year-old man was referred to the plastic surgery service with a lesion on the posterior aspect of his left pinna. It had grown significantly since he first noticed it 12 months before. The ulcerated lesion measured 2 cm in diameter (Fig. 1). Clinically, it resembled a squamous cell carcinoma clinically and there was no cervical lymphadenopathy. Under local anaesthetic the lesion was excised with a 4 mm margin and reconstructed with a trap door flap. In this case, we used a modification of the trap door flap

to reconstruct the full thickness defect (Figs. 2–4). The lesion to be excised was marked out with a 4 mm margin. The post-auricular flap was drawn with a diameter equal to the lesion and its margin (Fig. 2). The posterior pinna lesion was excised with underlying cartilage along with skin from the anterior surface of the ear (Fig. 5). This left a full thickness circular defect of the pinna necessitating reconstruction. In the traditional trapdoor flap, the lesion is excised with underlying cartilage but the posterior pinna skin is preserved. A small circular posterior pinna incision is made to accommodate the flap. In our modified trapdoor, a uniform circular excision of cartilage and posterior and anterior pinna skin is made, thus creating a full-thickness defect of the pinna. The flap was subsequently raised and undermined leaving a centrally-based vascular pedicle (Fig. 3). The anterior portion of the flap was first inset to the most medial aspect of the defect so it was then possible to identify where the flap needed further mobilization. The posterior aspect of the flap was

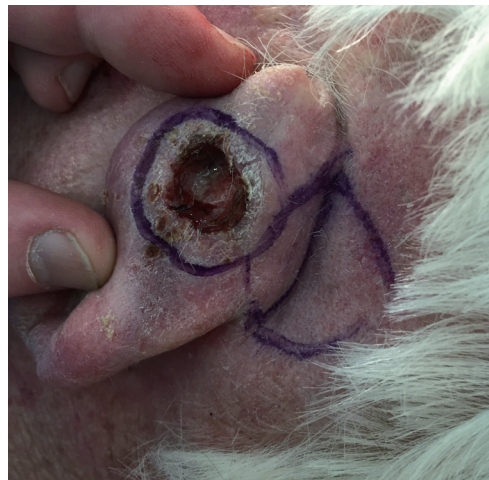

Fig. 1. The lesion on the posterior pinna with the post auricular trap door flap marked out.

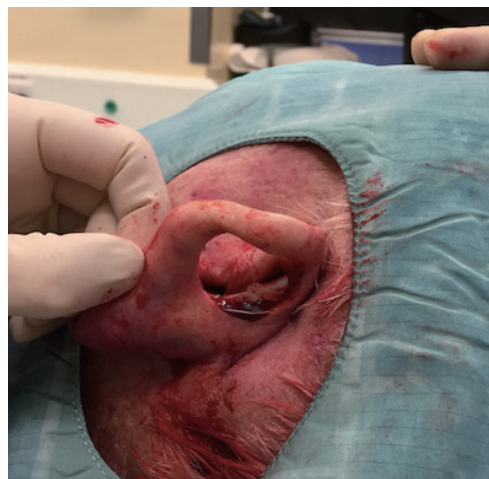


Fig. 2. The circular full-thickness uniform defect of the pinna.