



Contents lists available at ScienceDirect

## International Journal of Surgery Case Reports

journal homepage: [www.casereports.com](http://www.casereports.com)

# Unusual combination of femoral head dislocation associated acetabular fracture with multipart femoral fractures: Case report<sup>☆</sup>



Erdal Uzun<sup>a,\*</sup>, Ali Eray Günay<sup>b</sup>, İbrahim Karaman<sup>b</sup>, Abdülhamit Mısır<sup>c</sup>,  
Turan Bilge Kızıkan<sup>c</sup>, Mustafa Özçamdallı<sup>d</sup>

<sup>a</sup> Department of Orthopedics and Traumatology, Kayseri Training and Research Hospital, Kayseri, Turkey

<sup>b</sup> Department of Orthopaedics and Traumatology, Faculty of Medicine, Erciyes University, Kayseri, Turkey

<sup>c</sup> Department of Orthopedics and Traumatology, Metin Sabancı Baltalimani Bone Diseases Training and Research Hospital, İstanbul, Turkey

<sup>d</sup> Department of Orthopedic and Traumatology, Ahi Evran University, Kırşehir, Turkey

## ARTICLE INFO

### Article history:

Received 15 October 2016

Received in revised form 21 February 2017

Accepted 22 February 2017

Available online 27 February 2017

### Keywords:

Multiple  
Hip fracture  
Hip dislocation  
Ipsilateral  
Case report

## ABSTRACT

**INTRODUCTION:** Traumatic hip dislocation associated with femur intertrochanteric fracture is a rare and severe injury and it frequently occurs following a high energy trauma. Associated acetabular fractures with this injury are even more rare and potentially cause devastating consequences including avascular necrosis of the femoral head and subsequent early secondary osteoarthritis of the hip joint.

**PRESENTATION OF CASE:** In this case report, we present a 20 year old polytraumatized patient with traumatic hip dislocation associated with ipsilateral acetabulum fracture and simultaneous fractures of the ipsilateral femur.

**DISCUSSION:** Traumatic hip dislocation associated with femur intertrochanteric fracture is a rare and severe injury and it frequently occurs following a high energy trauma. In polytraumatized patients, musculoskeletal injuries are the most common lesions requiring surgical intervention frequently presenting challenging scenarios in terms of functional outcome and quality of life. Osteonecrosis of the femoral head is a serious and unpredictable complication that may occur after displaced femoral neck fracture and traumatic hip dislocation due to the disturbed blood supply of the femoral head.

**CONCLUSION:** A staged treatment strategy may be useful managing an unstable polytraumatized patient or a patient who requires prolonged transfer to receive definitive care.

© 2017 Published by Elsevier Ltd on behalf of IJS Publishing Group Ltd. This is an open access article under the CC BY-NC-ND license (<http://creativecommons.org/licenses/by-nc-nd/4.0/>).

## 1. Introduction

Dislocations of the hip joint frequently occur following a high energy trauma. Also there must be a very high energy requirement to make the hip joint dislocated [1]. Associated acetabular fractures or fractures of the head, neck or shaft of femur are rare but potentially cause devastating consequences including avascular necrosis (AVN) and subsequent early secondary osteoarthritis [2]. In managing an unstable polytraumatized patient the surgeons must propose a staged treatment strategy [3]. We present a 20 year old polytraumatized patient with hip dislocation associated with ipsilateral acetabulum, femur intertrochanteric, greater trochanter, and lateral condyle fractures.

<sup>☆</sup> This study is accepted as a poster presentation at the Turkish National Orthopaedics and Traumatology Congress in 2016.

\* Corresponding author at: Kayseri Eğitim ve Araştırma Hastanesi, Ortopedi ve Travmatoloji Bölümü, Kayseri, Turkey.

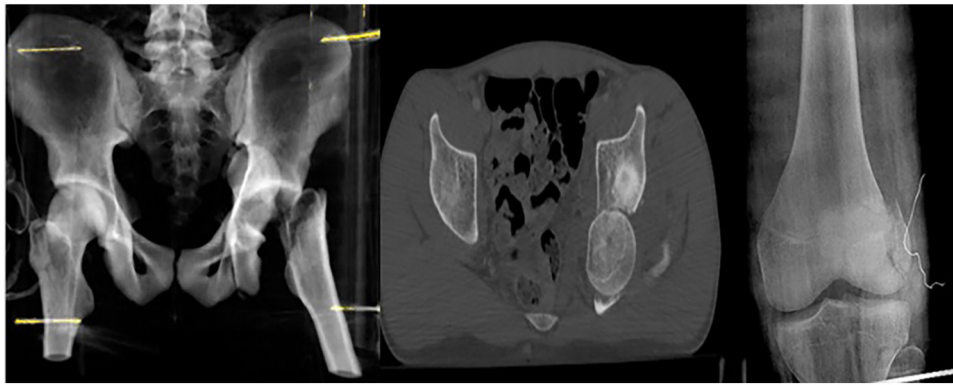
E-mail address: [nuzuladre@gmail.com](mailto:nuzuladre@gmail.com) (E. Uzun).

<http://dx.doi.org/10.1016/j.ijscr.2017.02.043>

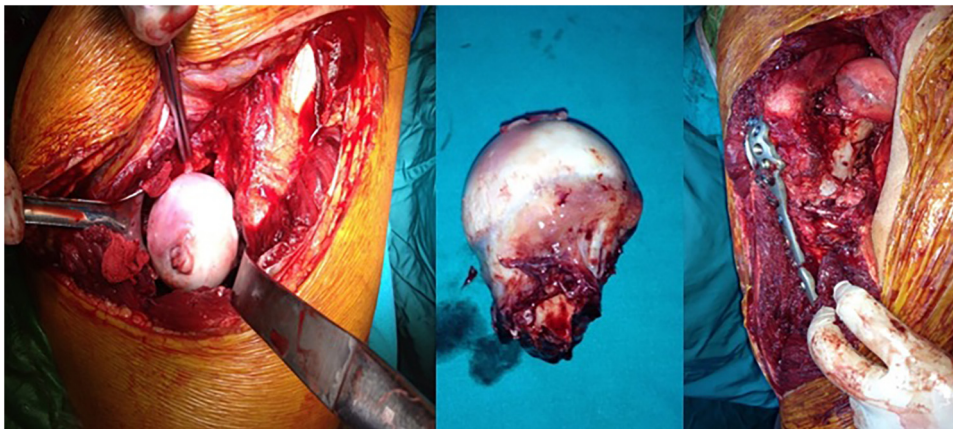
2210-2612/© 2017 Published by Elsevier Ltd on behalf of IJS Publishing Group Ltd. This is an open access article under the CC BY-NC-ND license (<http://creativecommons.org/licenses/by-nc-nd/4.0/>).

## 2. Case report

A 20-year-old man was admitted to the Emergency Room immediately after traffic accident. The patient's Glasgow Coma Score (GCS) was 5, Injury Severity Score was 45. The patient was unconscious and hemodynamically unstable, he had head injury with cranial hematoma and also had hemo-pneumothorax. His left lower extremity revealed a deformed appearance as adducted, internally rotated and it was 3 cm shorter than the other side with swelling in the left knee. His extremities had no vascular deficits, distal pulses were palpable. An X-ray examination of the pelvis and left femur and a computerised tomography (CT) scan of the hip are performed and they confirm the diagnosis posterior hip dislocation associated with ipsilateral acetabular fracture (Type B1 transverse and posterior wall according to the AO classification) [4], displaced intertrochanteric fracture of the femur, greater trochanter and lateral condyle fracture. (Fig. 1). The patient was hypotensive in the emergency room and intensive care unit and he was administered blood transfusions to gain hemodynamic stability. Because of the unstable condition of this polytraumatized patient we propose a staged treatment strategy consisting of skeletal traction from the



**Fig. 1.** Preoperative X-ray and Computed tomography images of the patient demonstrating ipsilateral femur intertrochanteric, lateral condyle and acetabulum fractures with posterior dislocation of the femoral head.



**Fig. 2.** Intraoperative photograph of the femoral head lying free between muscle fibers and fixation of the femoral head.

tibia in intensive care unit allowing initial resuscitation and stabilization of vital organ functions, osteosynthesis of acetabular and femoral fractures were addressed.

The patient was taken to the operating room 3 days after the crash. Lateral condyle fracture of the femur was fixed using 2 cannulated screws with closed reduction. Then with posterolateral approach after opening the fascia of the gluteus maximus muscle, the femoral head was found lying free between the muscle fibers (Fig. 2). There was a transverse and posterior wall acetabular fracture. Acetabular fracture was anatomically reduced and fixed with a reconstruction plate and screws (Fig. 3). Because there was a greater trochanter fracture in addition to the intertrochanteric femoral neck fracture, a proximal anatomic femoral plate and cannulated screws were used for fixation of the proximal femur. The femoral head was reduced and two cannulated screws were used to compress the fractured sides. The screws positions were confirmed with an image intensifier. Then the greater trochanter reduced and fixed. Postoperatively, the patient was followed for 4 weeks with skeletal traction in intensive care unit then skeletal traction was ended and he was admitted to the intensive rehabilitation program. 6 weeks after the surgery he was able to walk with crutches, nonweight bearing to the left lower limb. He remained nonweight bearing for 12 weeks. He followed home instructions for physiotherapy to strengthen his muscles and gain joint motions after discharge. Radiographic examination was performed 3 months (Fig. 3) and 12 months (Fig. 4) after the operation.

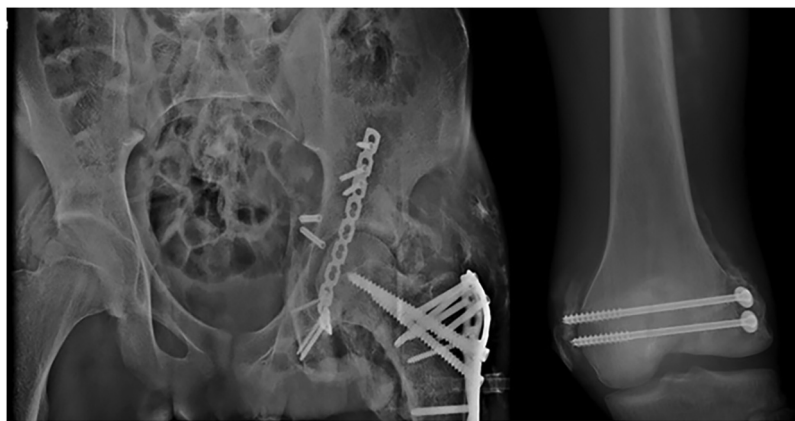
Although we used indomethacin prophylaxis in the follow up period as seen on the radiographs we were unable to prevent the

formation of heterotopic ossification probably associated with prolonged intensive care. His range of hip motion is 90° in flexion and 10° in extension but there were mild limitation in internal and external rotation at the last time follow up. No arthritic changes were detected radiographically. Although some limitations occurred in the motions of hip joint, proximal femur and all the other fractures were fully healed. Bone healing was assessed radiologically and clinically using conventional X-ray studies, as well as by evaluating clinical symptoms including pain with full weight bearing. 6 months after the crash the patient was able to walk and make his daily activities without any support. Written informed consent was obtained from the patient for publishing this case report.

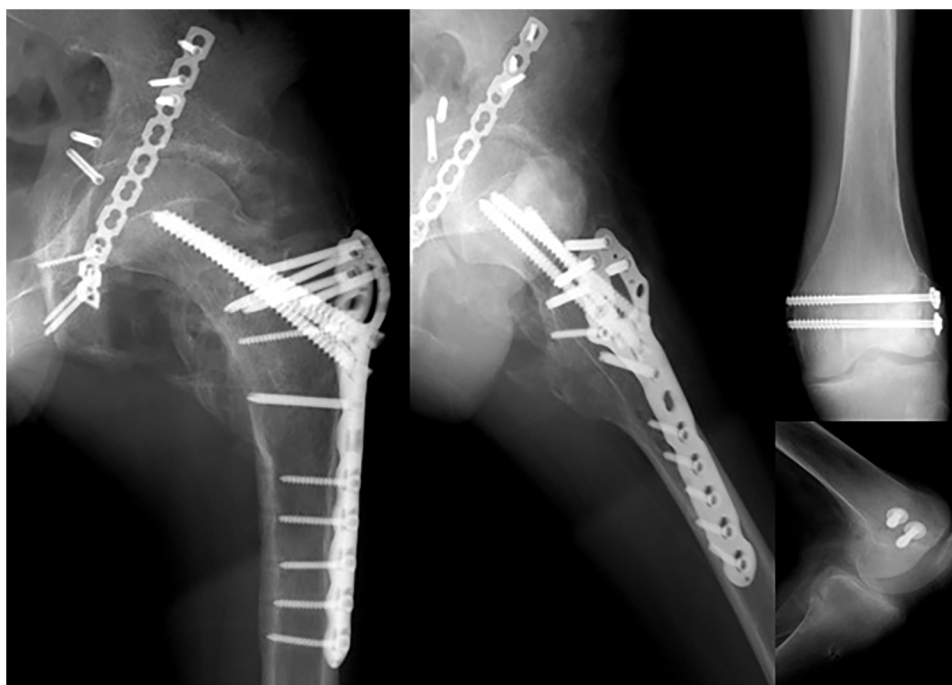
### 3. Discussion

Traumatic hip dislocation associated with femur intertrochanteric fracture is a rare and severe injury and it usually occurs following a high energy trauma. In this case report we learnt from the accident report that the patient had been involved in a head on motor vehicle collision with a tree.

In patients with multiple trauma, musculoskeletal injuries are the most common lesions requiring surgical intervention with survivors frequently presenting challenging scenarios in terms of functional outcome and quality of life [4,5]. In managing an unstable polytraumatized patient the surgeons must propose a staged treatment strategy [3]. Treatment options for intertrochanteric femoral fracture with dislocation of the hip include either osteosynthesis or primary arthroplasty [6,7]. In this study because of



**Fig. 3.** Postoperative radiography demonstrating reduction of the femoral head and stabilization of all fracture 3 month after the surgery.



**Fig. 4.** Anteroposterior radiograph of the hip joint and femur at the end of 12 months.

patient's younger age we preferred fixation of the femoral head to arthroplasty although the delay due to the patient's coexisting pathologies. Ipsilateral acetabular, greater trochanter and lateral condyle fracture were fixed at the same seance.

Osteonecrosis of the head of the femur (ONFH) is a serious and unpredictable complication which can occur after displaced femoral neck fractures due to disturbed blood supply of the femoral head. It is also thought that ONFH is more likely to occur with delayed time to surgical fixation [8,9]. Femoral head collapse and the development of osteoarthritis are the findings of ONFH which often necessitates further surgeries.

No arthritic changes, collapse or lysis of the femoral head was detected radiographically. Although some limitations occurred in the motions of hip joint we could manage to heal proximal femur and all the other fractures. 6 months after the crash the patient was able to walk and make his daily activities without any support. We propose a staged treatment strategy that may be useful in managing an unstable polytraumatized patient or a patient who requires prolonged transfer to receive definitive care.

#### 4. Conclusion

In patients with multiple trauma, musculoskeletal injuries are the most common lesions requiring surgical intervention with survivors frequently presenting challenging scenarios in terms of functional outcome and quality of life. In managing an unstable polytraumatized patient the surgeons must propose a staged treatment strategy. This study has been reported in line with the SCARE criteria [10].

#### Conflicts of interest

There is no conflict of interest.

#### Funding

This research did not receive any specific grant from funding agencies in the public, commercial, or not-for-profit sectors.

**Ethical approval**

No.

**Consent**

Written informed consent was obtained from the patient for publication of this case report and accompanying images.

**Authors contribution**

Erdal uzun – all steps.

Ali Eray Günay – data analysis or interpretation, writing the paper.

İbrahim Karaman – all steps.

**Guarantor**

All the authors of the study.

**References**

- [1] T. Canale, J.H. Beaty, Acute dislocations Campbell's Operative Orthopaedics, Vol. III, 12th ed., 2013, Chap. 60.
- [2] G. Sharma, M. Chadha, A. Pankaj, Hip dislocation associated with ipsilateral femoral neck and shaft fractures: an unusual combination and dilemma regarding head preservation, *Acta Orthop. Traumatol. Turc.* 48 (6) (2014) 698–702.
- [3] K.M. Kuhn, J.A. Boudreau, J.T. Watson, Rare combination of ipsilateral acetabular fracture–dislocation and petrochanteric fracture, *Am. J. Orthop. (Belle Mead NJ)* 42 (8) (2013) 372–375.
- [4] M. Tile, Fractures of the acetabulum, in: C.A. Rockwood Jr., D.P. Green, R.W. Bucholz, J.D. Heckman (Eds.), *Fractures in Adults*, Vol. 2, 4th ed., Lippincott-Raven, Philadelphia, PA, 1996, pp. 1617–1658.
- [5] Z.J. Balogh, M.K. Reumann, R.L. Gruen, P. Mayer-Kuckuk, M.A. Schuetz, I.A. Harris, et al., Advances and future directions for management of trauma patients with musculoskeletal injuries, *Lancet* 380 (9847) (2012) 1109–1119.
- [6] M. Banerjee, B. Bouillon, S. Shafizadeh, T. Paffrath, R. Lefering, A. Wafaisade, Epidemiology of extremity injuries in multiple trauma patients, *Injury* 44 (8) (2013) 1015–1021.
- [7] I. Esenkaya, M. Görgeç, Traumatic anterior dislocation of the hip associated with ipsilateral femoral neck fracture: a case report, *Acta Orthop. Traumatol. Turc.* 36 (2002) 366–368.
- [8] F. Duygulu, M. Calis, M. Argun, A. Guney, Unusual combination of femoral head dislocation associated acetabular fracture with ipsilateral neck and shaft fractures: a case report, *J. Trauma* 61 (2006) 1545–1548, Cross ref.
- [9] G.J. Haidukewych, W.S. Rothwell, D.J. Jacofsky, M.E. Torchia, D.J. Berry, Operative treatment of femoral neck fractures in patients between the ages of fifteen and fifty years, *J. Bone Jt. Surg. Am.* 86 (2004) 1711–1716.
- [10] R.A. Agha, A.J. Fowler, A. Saetta, I. Barai, S. Rajmohan, D.P. Orgill, for the SCARE Group, The SCARE statement: consensus-based surgical case report guidelines, *Int. J. Surg.* 34 (2016) 180–186.

**Open Access**

This article is published Open Access at [sciencedirect.com](https://www.sciencedirect.com). It is distributed under the [IJSCR Supplemental terms and conditions](#), which permits unrestricted non commercial use, distribution, and reproduction in any medium, provided the original authors and source are credited.