

Lemierre Syndrome

Yun Yi Bang, R.N.*, Jung-Tae Kim, M.D.*, Woon-Ha Chang, M.D.*,
Tae Yun Oh, M.D.*, Joon-Hyuk Kong, M.D.*

Lemierre syndrome is caused by acute oropharyngeal infections with secondary septic thrombophlebitis of the internal jugular vein and is characterized by frequent metastatic infections. A 56-year-old man presented with severe reddish inflammatory swelling of the right cervical soft tissue. Thrombophlebitis in the right internal jugular vein and multiple pulmonary embolisms were identified on neck and chest computed tomography (CT). He was treated with antibiotics and heparin for 4 weeks and then discharged without other complications.

Key words: 1. Thrombosis
2. Jugular veins
3. Pulmonary embolism

CASE REPORT

A 56-year-old man visited a local clinic with a mild fever and sore throat that had persisted for one week. He was treated for pharyngitis, with only limited improvement. Within 7 days, he was referred to our department with a persistent fever, neck swelling, and neck pain. On examination, his neck was tender and edematous with cellulitis. His white blood cell (WBC) count was $14,800 \times 10^3/\text{mm}^3$ and CRP was 13.70 mg/dL. A neck CT showed occlusive thrombophlebitis of the right internal jugular vein and jugular bulb and swelling of the adjacent muscle (Fig. 1). The patient received emergency treatment with an angioplasty with urokinase, but the treatment did not result in improvement. To identify other possible abnormal conditions such as pulmonary embolism or thrombus in the right heart, a lung perfusion scan, chest CT, and echocardiography were performed. The lung perfusion scan showed multiple perfusion defects of the right lung field

that suggested pulmonary embolism. The chest CT revealed multiple enlarged lymph nodes and embolism of the right pulmonary artery (Fig. 2). The echocardiography revealed no intracardiac thrombus. Blood cultures revealed no other organisms. Suspecting Lemierre syndrome, we treated the patient with clindamycin, cephalosporin for phlebitis, and heparin for pulmonary embolism. On the third day, his fever settled and neck pain decreased. Four weeks later, his WBC count was $9,050 \times 10^3/\text{mm}^3$, CRP was 3.47 mg/dL, and his condition had improved with no pain or swelling of the neck. The patient was discharged 4 weeks later, and was followed-up for 2 years with no recurrences.

DISCUSSION

In 1936, French microbiologist Andre Lemierre described a syndrome characterized by anaerobic septicemia, internal jugular vein thrombophlebitis, and septic emboli that typically

*Department of Thoracic and Cardiovascular Surgery, Kangbuk Samsung Hospital, Sungkyunkwan University College of Medicine

Received: May 20, 2011, Revised: June 30, 2011, Accepted: August 24, 2011

Corresponding author: Jung-Tae Kim, Department of Thoracic and Cardiovascular Surgery, Kangbuk Samsung Hospital, Sungkyunkwan University College of Medicine, Seoul 110-746, Korea

(Tel) 82-2-2001-2149 (Fax) 82-2-2001-2148 (E-mail) csm7@hanmail.net

© The Korean Society for Thoracic and Cardiovascular Surgery. 2011. All rights reserved.

© This is an open access article distributed under the terms of the Creative Commons Attribution Non-Commercial License (<http://creativecommons.org/licenses/by-nc/3.0>) which permits unrestricted non-commercial use, distribution, and reproduction in any medium, provided the original work is properly cited.

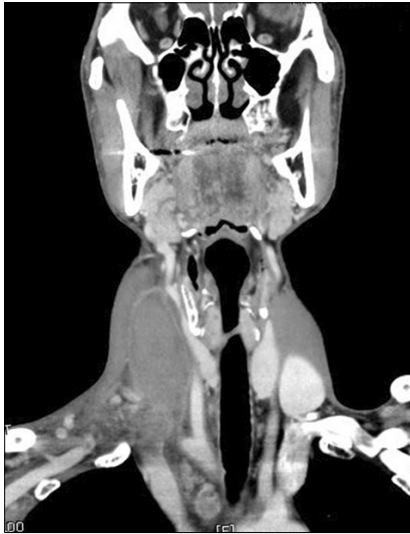

Fig. 1. Neck CT showing thrombosis of the right internal jugular vein and swelling of the right neck.

arose secondary to infections of the head and neck. His initial report described 20 cases, 18 of whom died [1]. Lemierre syndrome is caused by oropharyngeal infections, which cause septic thrombophlebitis of the internal jugular vein and metastatic infections. It was a very common disease with a high mortality rate in the preantibiotic era, but the incidence and mortality rate decreased after the introduction of antibiotics. Lemierre syndrome is therefore often referred to as the “forgotten disease”. Today, this syndrome is typically seen in healthy adolescents. *Fusobacterium necrophorum* is a bacterium usually found in the oropharynx, female genital tract, and gastrointestinal tract, and is the etiologic agent of Lemierre syndrome in 81% of modern reports. In our case, we were unable to identify the organism that caused the phlebitis because antibiotics were previously administered by a local clinic [2]. The first phase of the disease is typically pharyngeal infection. In most cases, patients complain of odynophagia and pharyngeal inflammation. Fevers are observed in 82.5% of patients, but fever is not necessarily the first clinical symptom. The second phase of the disease is the invasion of the lateral pharyngeal wall and thrombophlebitis of the internal jugular vein. These symptoms occur after vital structures are affected. Bacteremia appears when the infection invades the internal jugular vein. The most common first sign of complications is fever. Septic pulmonary emboli occur in

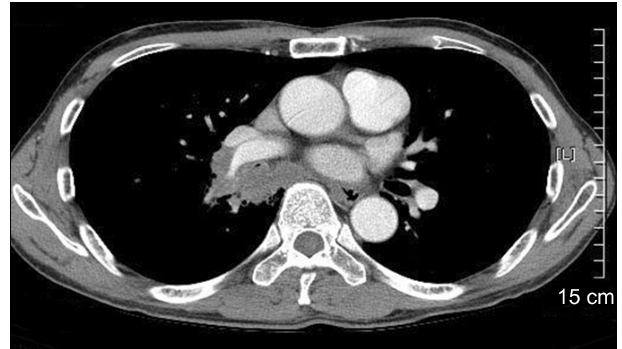


Fig. 2. Chest CT showing a pulmonary embolism of the right pulmonary artery and multiple enlarged lymph nodes.

up to 97% of the cases and manifest as chest pain and dyspnea [3]. Chest radiographs may show nodules, cavitation, or effusion and should be followed by a chest CT. Vogel and Boyer [4] described two cases with the most common locations of metastasis, the lungs and joints, which required long term antibiotics to resolve infections.

The key diagnostic points of Lemierre syndrome are symptoms, followed secondarily by diagnostic imaging methods. According to a report by Lai et al. [5], contrast CT is the preferred procedure for demonstrating the defects of the internal jugular vein caused by thrombosis.

Fusobacteria are usually sensitive to penicillin G and antibiotics with good anaerobic coverage (i.e. metronidazole, clindamycin, and chloramphenicol) [3]. Antibiotic therapy is usually administered for a period of 3 to 6 weeks due to the nature of the endovascular infection. If the patient decompensates or fails to improve, surgical therapy should be considered. This therapy may include abscess drainage, venous ligation, or venous resection [6]. Ligation of the internal jugular vein is probably only indicated in patients with persistent septic embolization despite the administration of antibiotics.

The use of anticoagulation to treat Lemierre syndrome is a topic of debate. There are some reports that anticoagulation is beneficial for the management of septic pulmonary embolism with antibiotics [7].

Although Lemierre syndrome is not as common a diagnosis as it was in the past, it should always be suspected in previously healthy adolescents with fever and neck pain after mi-

nor oropharyngeal infections [8]. Persons suspected of having Lemierre syndrome should be treated aggressively because the disease is characterized by high morbidity and mortality, even if blood cultures remain negative.

REFERENCES

1. Lemierre A. *On certain septicaemias due to anaerobic organisms*. Lancet 1936;1:701-3.
2. Yoo DG, Kim CW, Park CB, Lee GD, Ahn JH. *Lemierre syndrome with septic pulmonary embolism: a case report*. Korean J Thorac Cardiovasc Surg 2007;40:782-5.
3. Sinave CP, Hardy GJ, Fardy PW. *The Lemierre syndrome: suppurative thrombophlebitis of the internal jugular vein secondary to oropharyngeal infection*. Medicine (Baltimore) 1989;68:85-94.
4. Vogel LC, Boyer KM. *Metastatic complications of Fusobacterium necrophorum sepsis. Two cases of Lemierre's post-anginal septicemia*. Am J Dis Child 1980;134:356-8.
5. Lai YJ, Lirng JF, Chang FC, Luo CB, Teng MM, Chang CY. *Computed tomographic findings in Lemierre syndrome*. J Chin Med Assoc 2004;67:419-21.
6. Shadowen RD, Trevor RP. *Lemierre's postanginal septicemia: internal jugular vein thrombosis related to pharyngeal infection*. South Med J 1989;82:1583-4.
7. Oh JH, Lee JC, Lee DH, Lee JH, Jung TE, Han SS. *Surgical treatment of Lemierre's syndrome: a case report*. Korean J Thorac Cardiovasc Surg 2001;34:644-7.
8. Figueras Nadal C, Creus A, Beatobe S, Moraga F, Pujol M, Vazquez E. *Lemierre syndrome in a previously healthy young girl*. Acta Paediatr 2003;92:631-3.