

Early Hepatocellular Carcinoma: Three-Phase Helical CT Features of 16 Patients

Jongmee Lee, MD^{1,3}
Won Jae Lee, MD¹
Hyo Keun Lim, MD¹
Jae Hoon Lim, MD¹
Nami Choi, MD^{1,4}
Mi-hyun Park, MD¹
Sang Won Kim, MD¹
Cheol Keun Park, MD²

Index terms:

Hepatocellular carcinoma
Liver neoplasms
Computed tomography (CT)

DOI:10.3348/kjr.2008.9.4.325

Korean J Radiol 2008;9:325-332

Received March 21, 2007; accepted after revision December 11, 2007.

¹Department of Radiology and Center of Imaging Science, ²Department of Pathology, Samsung Medical Center, Sungkyunkwan University School of Medicine, Seoul 135-710, Korea; ³Department of Radiology, Korea University Guro Hospital, Seoul 152-703, Korea; ⁴Department of Radiology, Bucheon Hospital, Soonchunhyang University School of Medicine, Gyeonggi-do 420-767, Korea

Address reprint requests to:

Won Jae Lee, MD, Department of Radiology and Center for Imaging Science, Samsung Medical Center, Sungkyunkwan University School of Medicine, 50 Ilwon-dong, Gangnam-gu, Seoul 135-710, Korea.
Tel. (822) 3410-0512
Fax. (822) 3410-2559
e-mail: wjlee@skku.edu

Objective: To evaluate the three-phase helical CT features of early hepatocellular carcinomas, based on the new Japanese classification.

Materials and Methods: Over the course of an eight-year period, we collected 16 pathologically proven early hepatocellular carcinomas from 16 patients having undergone a three-phase helical CT prior to surgery. The three-phase CT images were acquired at 20–35 sec (arterial phase), 70 sec (portal phase), and 180 sec (equilibrium phase) from the beginning of intravenous injection of contrast material. All the CT images were retrospectively analyzed by two radiologists in consensus, based on their description of morphologic (size, margin, fibrous capsule and mosaic pattern) and enhancement patterns of tumors.

Results: Only seven (44%) of the 16 early hepatocellular carcinomas having undergone a CT were described (mean diameter, 1.2 cm; range, 0.4–2.5 cm). All the tumors had an ill-defined margin with no fibrous capsule. The mosaic pattern was found in only one tumor. Only three (43%) of the seven tumors detected on CT were hyperattenuating during the arterial phase. The four remaining tumors (25%) were hypoattenuating throughout the three phases.

Conclusion: Despite the higher resolution provided by the three phase scans, the contrast-enhanced CT provides only limited detection of the variable morphologic and enhancement features of early hepatocellular carcinomas.

The term, early hepatocellular carcinoma, was introduced by Japanese investigators to explain the multi-step hepatocarcinogenesis process, and as a result, was subsequently used to encompass the various early stages of hepatocellular carcinomas, ranging from the dysplastic nodules with small foci of well-differentiated hepatocellular carcinomas, to the well-differentiated hepatocellular carcinomas with small foci of moderately differentiated hepatocellular carcinomas (1).

Among the Japanese investigators, Kanai et al. (2) demonstrated that some hepatocellular carcinomas are well differentiated and do not destroy the underlying liver structure. Consequently, these tumors were categorized as early hepatocellular carcinoma. Some studies have reported that the clinical outcome of early hepatocellular carcinomas, based on this concept, is more favorable than the small advanced hepatocellular carcinoma. As a result, early hepatocellular carcinomas can be identified as a distinct clinical entity which has a high chance for surgical cure (3–5).

Recently, the above-mentioned concept of early hepatocellular carcinomas has been revised by the Liver Cancer Study Group of Japan (6, 7). According to this new classification system, the primary category of the early hepatocellular carcinoma could be summarized as “a tumor composed of well-differentiated hepatocellular carcinoma with an indistinct margin” due to replacement growth (Fig. 1). Consequently, this interpreta-

tion was histologically more limiting compared with the conventional category, in which the distinctness of tumor margins was not clearly defined. In addition, early hepatocellular carcinomas were allowed to have a small component of moderately differentiated cancer in the center, termed “early advanced hepatocellular carcinoma”, and usually retained a portal tract in the tumor (6, 7).

Several reports have described the CT findings of early hepatocellular carcinomas based on the conventional categorization of early hepatocellular carcinomas (8–10). To the best of our knowledge, however, no clinical or radiological reports describing early hepatocellular carcinomas exist based on the new Japanese classification. Therefore, we evaluated the CT findings of early hepatocellular carcinomas, based on this new classification system, with an emphasis on the morphologic and enhancement patterns of the three-phase helical CT.

MATERIALS AND METHODS

Patients

Our institutional review board waived patient approval. Thus, informed consent was not required for this retrospective study. From June 1997 to June 2005, 30 consecutive patients, who had surgically proven early hepatocellular carcinoma, were identified after a computerized search of the pathologic database at our institution. Next, a pathologist of our institution with 27 years of experience as a gastrointestinal pathologist reviewed the pathologic specimens of patients having undergone surgery before 2000 in order to exclude cases which did not meet the new

classification of early hepatocellular carcinoma. As a result, eight patients were excluded due to histologically incomplete replacement growth. Of the eight excluded patients, six were excluded because a three-phase helical CT scan was not available at the time of their testing. Finally, 16 patients (13 men and 3 women; mean age, 55 years; age range, 36 to 62 years), having undergone a three-phase helical CT, were included in the study population. Their underlying diseases included cirrhosis ($n = 12$) and chronic hepatitis ($n = 4$), which were caused by a hepatitis B infection ($n = 13$) or an unknown etiology ($n = 3$). A surgical intervention was performed within seven weeks of CT evaluation (mean, 21 days; range, 1–47 days). The types of surgical methods included a segmentectomy ($n = 6$), a lobectomy ($n = 4$), a tumorectomy ($n = 4$), and a total hepatectomy for liver transplantations ($n = 2$).

Pathologic Diagnosis

The above-mentioned pathologist reviewed all the surgical specimens. Furthermore, early hepatocellular carcinomas were diagnosed in all the observed patients based on the new Japanese classification published by the Liver Cancer Study Group of Japan in 2000 (6). In addition, the presence of advanced hepatocellular carcinomas was recorded. As well, the size and number of tumors, in addition to the presence and extent of various histologic findings (e.g., fibrous capsule, fatty metamorphosis, and so on) were recorded for each tumor.

CT Technique

All three-phase helical CT evaluations were performed

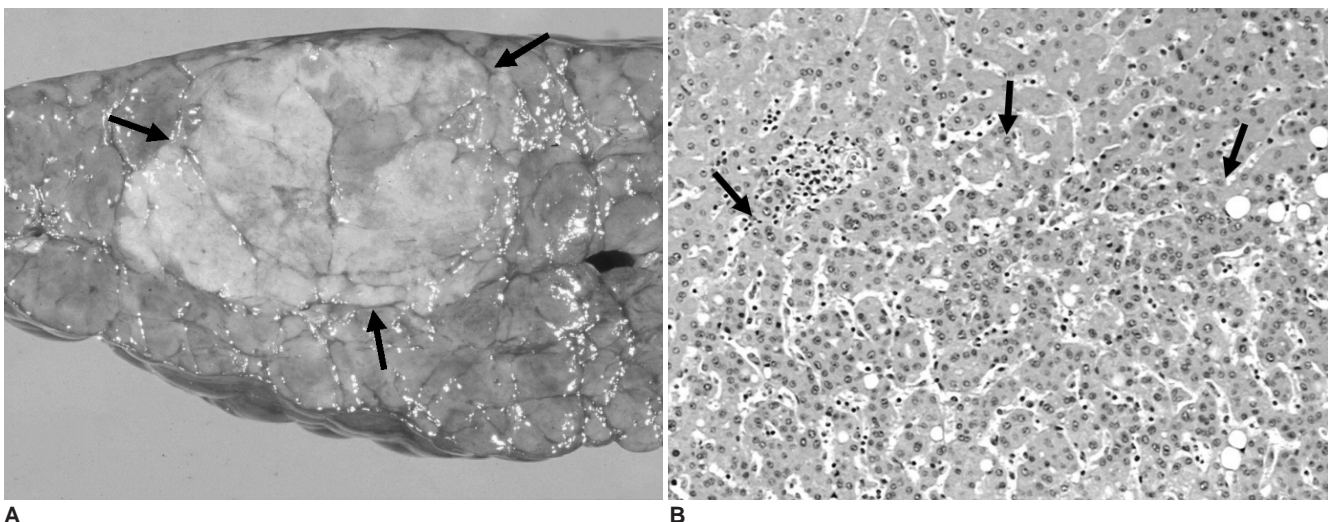


Fig. 1. 62-year-old man with early hepatocellular carcinoma located in right hepatic lobe. **A.** Photograph of resected gross specimen shows 2.2-cm, slightly yellowish nodule (arrows) with indistinct margin. **B.** Photomicrograph of same specimen shows tumor cells of well-differentiated hepatocellular carcinoma in lower half of field (below arrows). Note that tumor cells appear to replace normal hepatocytes without clear demarcation (i.e. replacement growth - Hematoxylin & Eosin staining, $\times 100$).

Early Hepatocellular Carcinoma and 3-Phase Helical CT Findings

with a single detector CT scanner (HiSpeed; GE Medical Systems, Milwaukee, WI) (n = 7), or a 4-detector CT scanner (LightSpeed QX/i, GE Medical Systems) (n = 3), 8-detector CT scanner (LightSpeed Ultra, GE Medical Systems) (n = 2) and a 16-detector CT scanner (LightSpeed 16, GE Medical Systems) (n = 4). The scanning parameters included a 120 kVp, 170–200 mAs, 5-mm or 7-mm slice thickness, and a 5-mm or 7-mm/sec table speed (pitch of 1.0) for the single-detector row CT scanner or the multi-detector row CT scanner with 4-detectors during a one-breath-hold helical acquisition of 25–30 sec, and either a 17.5-mm/sec table speed (pitch of 0.875) for multi-detector row CT scanner with 8-detectors or an 18.75-mm/sec table speed (pitch of 0.938) for a multi-detector row CT scanner with 16-detectors during a one-breath-hold helical acquisition of 6.7–11.2 seconds (depending on liver size). All the CT images were obtained in the craniocaudal direction spanning the entire liver, and were reconstructed at 5-mm intervals in order to provide contiguous sections.

Each patient received 120 mL of non-ionic contrast material (Ultravist 300 [iopromide]; Shering AG, Berlin, Germany) at a flow rate of 3 mL/sec, using an automatic power injector. Using the bolus-triggered technique, the arterial phase images were acquired 15 sec after the attenuation number of the abdominal aorta increased by 100 HU above the attenuation number of non-contrast CT. This corresponded to a 20–35 sec period beyond the onset of the contrast material intravenous injection. Furthermore, the portal and equilibrium phases were acquired 70 sec and 180 sec after the onset of contrast material injection, respectively.

Image Analysis

All CT images were analyzed retrospectively by two abdominal radiologists (each with 17 and four years of experience) with consensus, for the presence of a tumor as well as the morphologic and enhancement patterns of the tumors when detected on CT. All CT images were

interpreted on a 2,000 × 2,000 Picture Archiving and Communication System (PACS) (Pacspeed; GE Medical Systems Integrated Imaging Solutions, Mt Prospect, IL) monitor with adjustment of the optimal window settings.

For the morphologic patterns, maximum tumor size, tumor margin, presence of fibrous capsule, fatty metamorphosis, and mosaic pattern (nodule-in-nodule pattern) were recorded. The tumor margin was categorized as having a well-defined or ill-defined margin. A fibrous capsule was defined as a thin curvilinear border of the tumor, which was hypoattenuating at the arterial phase and became hyperattenuating during the later phases. Fatty metamorphosis was defined as a hypoattenuating area within a tumor, which had a Hounsfield unit below -10 (11). A mosaic pattern within a tumor was defined as two or more well-demarcated nodules, with differences in attenuation (12).

The enhancement pattern was analyzed by comparing the tumor attenuation (e.g., hyper-, iso-, and hypoattenuation), against the attenuation of the background liver throughout the three phases.

This retrospective analysis was performed with knowledge of the surgical and histopathologic findings (size and number of the hepatocellular carcinomas), and comparing them with CT findings on a segment-by-segment basis. The tumors which were not detected at CT were categorized as having isoattenuation throughout the three phases. The detection rate of early hepatocellular carcinoma on CT was also compared between the single detector and multi-detector CT scanners to attempt to exclude the lack of standardized detection instrumentation. Finally, the detection rate of hepatocellular carcinoma on CT was evaluated in the eight patients who were excluded from the study population due to incomplete replacement growth.

Table 1. Main Enhancement Pattern of 16 Early Hepatocellular Carcinomas on Three-phase Helical CT Images

Tumor Size (cm)	Enhancement Pattern								
	Arterial Phase			Portal Phase			Equilibrium Phase		
	Hypo	Iso	Hyper	Hypo	Iso	Hyper	Hypo	Iso	Hyper
< 1 cm (n = 5)	0 (0)	4 (80)	1 (20)	0 (0)	5 (100)	0 (0)	0 (0)	5 (100)	0 (0)
1 – 2 cm (n = 10)	3 (30)	5 (50)	2 (20)	4 (40)	5 (50)	1 (10)	5 (50)	5 (50)	0 (0)
> 2 cm (n = 1)	1 (100)	0 (0)	0 (0)	1 (100)	0 (0)	0 (0)	1 (100)	0 (0)	0 (0)
Total (n = 16)	4 (25)	9 (56)	3 (19)	5 (31)	10 (63)	1 (6)	6 (38)	10 (62)	0 (0)

Note.—Data represent tumor numbers of early hepatocellular carcinoma. Numbers in parentheses are percentages. Hypo = hypoattenuation, Iso = isoattenuation, Hyper = hyperattenuation

RESULTS

Pathologic Findings

The total number of hepatocellular carcinomas detected during the pathologic examinations was 29 for the 16 patients. Of these 16 patients, six had a single tumor, eight had two tumors, one had three tumors, and one had four tumors. Each of the 16 patients had at least one early hepatocellular carcinoma. The remaining 13 tumors were identified as advanced hepatocellular carcinomas.

The mean maximum diameter of the 16 early hepatocellular carcinomas was 1.2 cm (range, 0.4 to 2.5 cm). Moreover, the number of tumors with maximum diameters

smaller than 1 cm, between 1 cm and 2 cm, and greater than 2 cm was five, ten, and one, respectively. The histologic grade of all the tumors was "well-differentiated hepatocellular carcinoma", except for one which was identified as having a small portion of moderately differentiated hepatocellular carcinoma within the tumor. All the tumors demonstrated histologic characteristics of replacement growth. Conversely, none of them had fibrous capsules. Lastly, eight (50%) of the 16 tumors had fatty metamorphosis, ranging from 5 to 50%.

CT Findings

A total of 20 tumors were detected on CT in the 16 patients. Of these patients, ten had one tumor, three had

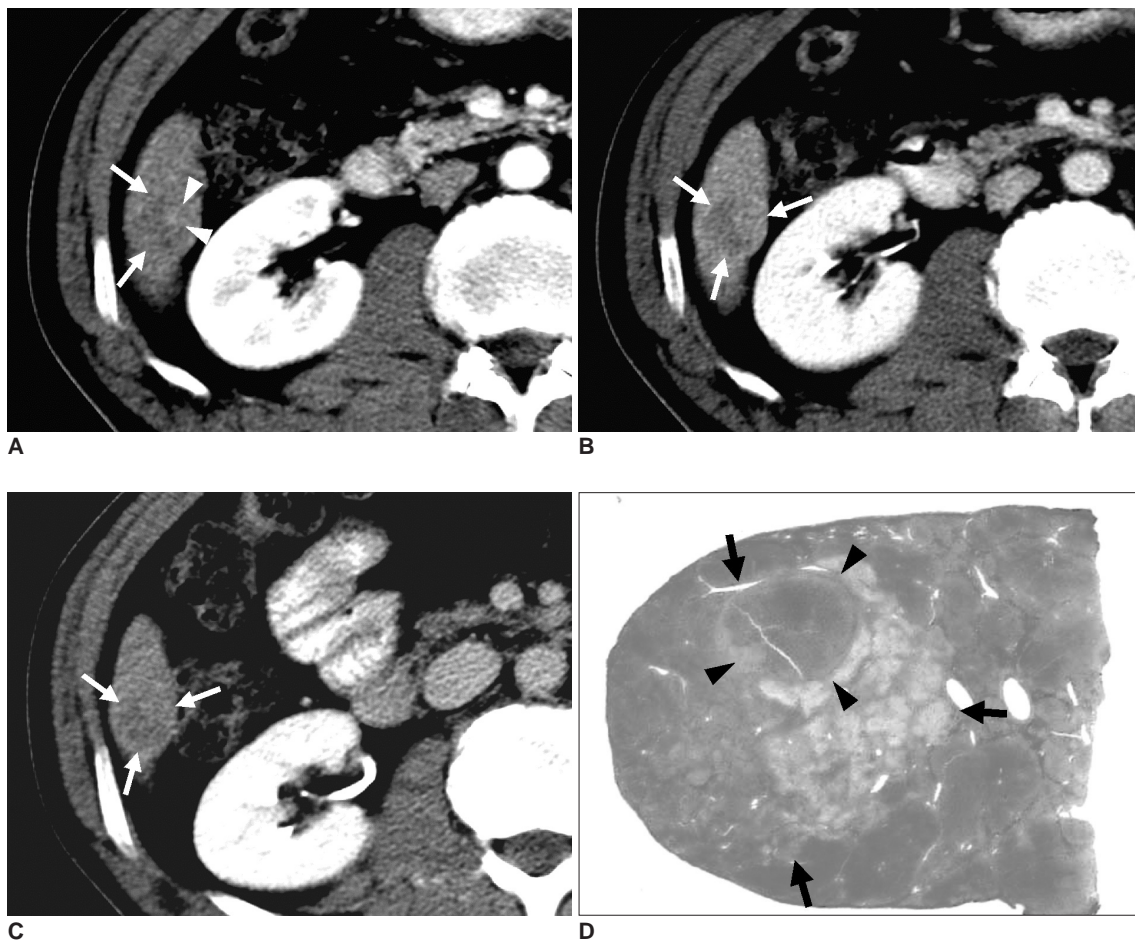


Fig. 2. 48-year-old man with early hepatocellular carcinoma of so called "nodule in nodule lesion" (i.e. early advanced hepatocellular carcinoma) located in right hepatic lobe.

A. Axial helical CT scan of liver during arterial phase shows 1.8-cm, hypoattenuating nodule with indistinct margin (arrows) located in segment VI of right hepatic lobe. Note faintly enhancing portion (arrowheads) within hypoattenuating nodule, representing mosaic pattern (nodule-in-nodule pattern).

B, C. Corresponding portal (**B**) and equilibrium (**C**) phase CT scans show same hypoattenuating nodule (arrows). Faintly enhancing portion observed in arterial phase image becomes isoattenuating during later phases.

D. Photograph of Hematoxylin and Eosin stained resected specimen shows same nodule (arrows) with indistinct margin and uneven fatty change. Note small nodule (arrowheads) in its upper part (i.e. mosaic pattern - nodule-in-nodule pattern), which corresponds to faintly enhancing portion observed in arterial phase CT image. Histopathologic findings revealed that whole nodule was composed of tumor cells of well-differentiated hepatocellular carcinoma, while small nodule was composed of moderately differentiated hepatocellular carcinoma.

Early Hepatocellular Carcinoma and 3-Phase Helical CT Findings

two tumors, and one had four tumors. The two remaining patients underwent a liver transplantation due to liver cirrhosis and showed no tumors on CT, but ultimately were diagnosed with a single early hepatocellular carcinoma from pathologic findings. Of the 10 patients with a single tumor on CT, four had an early hepatocellular carcinoma, whereas the other six had an advanced hepatocellular carcinoma. Of the four patients with multiple tumors on CT, two of the three patients with two hepatocellular carcinomas and the one patient with four hepatocellular carcinomas each had an early hepatocellular carcinoma, whereas the remaining seven tumors were identified as advanced hepatocellular carcinomas. Therefore, only seven (44%) of the 16 early hepatocellular carcinomas were detected on CT. Furthermore, 10 patients showed only one or more advanced hepatocellular carcinoma on CT. Of these seven tumors, five had a maximum diameter between 1 and 2 cm, one was smaller than 1 cm, and one was greater than 2 cm. Therefore, the detection rate was 20% for tumors with maximum diameters smaller than 1 cm, 50% for tumors between 1 and 2 cm, and 100% for tumors greater than 2 cm. All seven of the early hepatocellular carcinomas demonstrated

an ill-defined margin with no evidence of a fibrous capsule or fatty metamorphosis on CT. A mosaic pattern was observed in one tumor with a small portion of its composition being identified as having moderately differentiated hepatocellular carcinoma in the background of the well-differentiated hepatocellular carcinoma (Fig. 2).

The enhancement patterns of all the early hepatocellular carcinomas are tabulated in Table 1. The nine tumors which were not detected by CT were regarded as being isoattenuating throughout all three phases (i.e. iso-iso-iso). Of the seven tumors that were detected by CT, only three (43%) appeared to be faintly hyperattenuating during the arterial phase, and subsequently became isoattenuating in one patient (high-iso-iso), and hypoattenuating in two patients (high-high-low and high-low-low) during the equilibrium phase (Fig. 3). The four remaining tumors were hypoattenuating throughout all three CT phases (low-low-low). Moreover, these four tumors were histologically revealed as having fatty metamorphosis ranging from 20 to 50% (Fig. 4). Therefore, of the 16 tumors, attenuation during the arterial phase was hyperattenuating, isoattenuating, and hypoattenuating in 19%, 56%, and 25%, respectively.

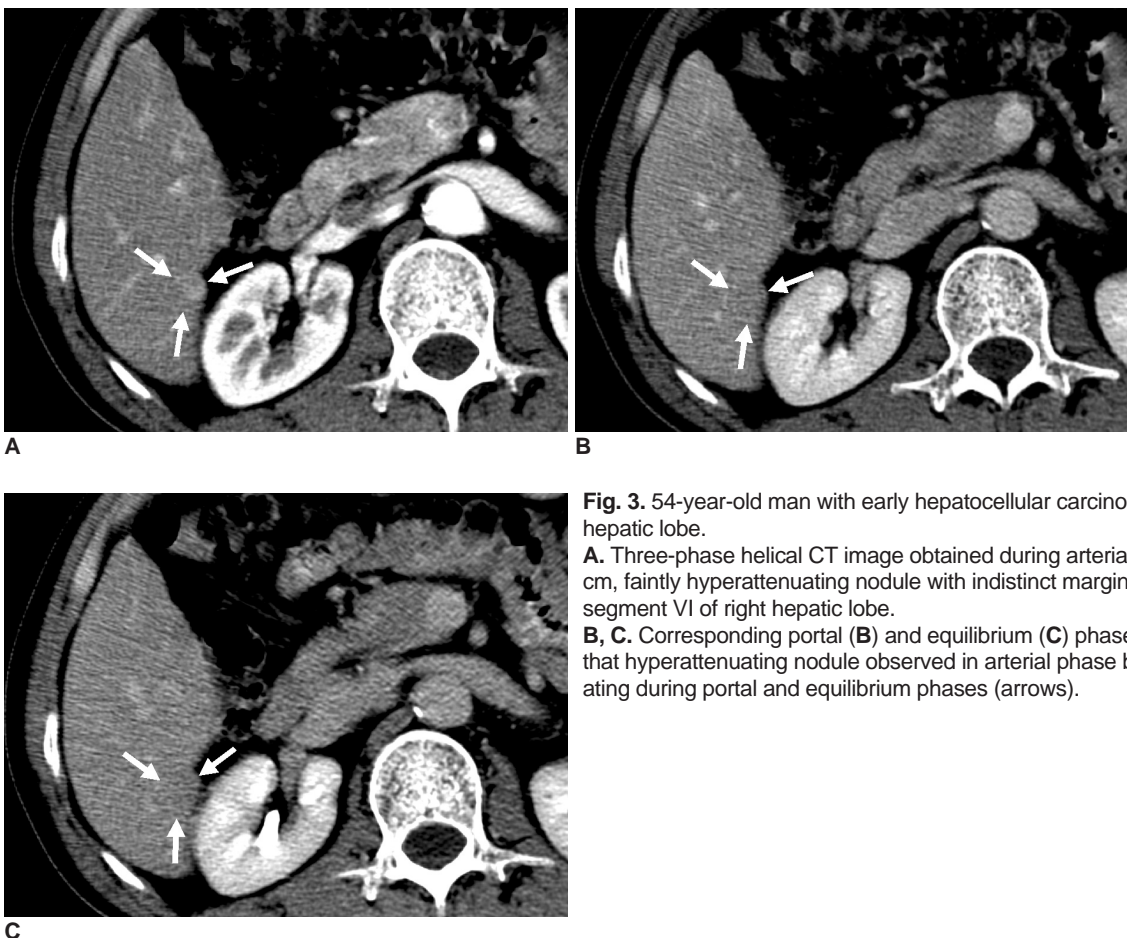


Fig. 3. 54-year-old man with early hepatocellular carcinoma located in right hepatic lobe.
A. Three-phase helical CT image obtained during arterial phase shows 0.8-cm, faintly hyperattenuating nodule with indistinct margin (arrows) in segment VI of right hepatic lobe.
B, C. Corresponding portal (**B**) and equilibrium (**C**) phase CT scans show that hyperattenuating nodule observed in arterial phase becomes isoattenuating during portal and equilibrium phases (arrows).

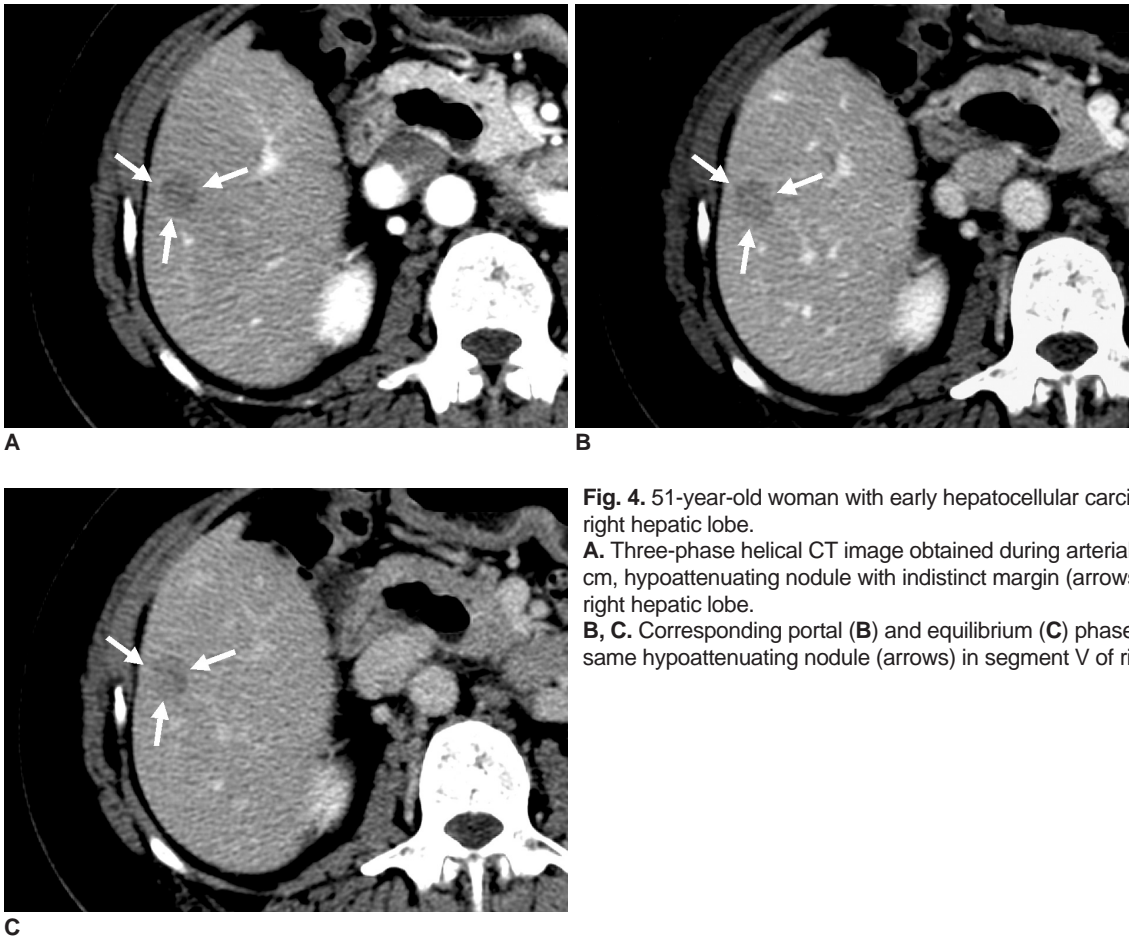


Fig. 4. 51-year-old woman with early hepatocellular carcinoma located in right hepatic lobe.
A. Three-phase helical CT image obtained during arterial phase shows 1.3-cm, hypoattenuating nodule with indistinct margin (arrows) in segment V of right hepatic lobe.
B, C. Corresponding portal (**B**) and equilibrium (**C**) phase CT scans show same hypoattenuating nodule (arrows) in segment V of right hepatic lobe.

Of the seven early hepatocellular carcinomas detected by CT, five were detected by a single detector and two were detected by multi-detector CT scanners, with a detection rate of 71% (5/7) and 22% (2/9), respectively. Of the eight patients excluded from this study due to incomplete replacement growth, five hepatocellular carcinomas were detected by CT, with a detection rate of 63%.

DISCUSSION

The conventional use of early hepatocellular carcinomas has been to designate hepatocellular carcinomas in the early stages of multi-step hepatocarcinogenesis, as mentioned above (1). However, a group of Japanese investigators found that some of the well-differentiated hepatocellular carcinomas demonstrated indistinct margins due to replacement growth of the various hepatocellular nodules. Moreover, this was considered to be a distinct pathologic entity, which ultimately led to the redefining of the histologic categories (6). The results from these findings were published in English three years later (7), which reads as follows:

Well-differentiated hepatocellular carcinoma with

indistinct tumor margin and the color of the tumor does not differ greatly from that of the background cirrhosis. Most early hepatocellular carcinomas are 1.0-1.6 cm in diameter and usually retain portal tract in the tumor. The tumor is composed almost exclusively of well-differentiated cancer tissue, but a small component of moderately differentiated cancer may be found in the center, so called "nodule in nodule lesion" (early advanced hepatocellular carcinoma). At the tumor-non-tumor boundary, cancer cells proliferate as if they are replacing normal hepatocytes in the surrounding liver cell cords.

The term "early advanced hepatocellular carcinoma" was seldom used by Japanese investigators and was initially introduced by Rim et al. (13), as a hepatocellular carcinoma consisting of a definite cancerous nodule (i.e., advanced hepatocellular carcinoma), which was surrounded by early hepatocellular carcinomas (i.e., very-well-differentiated and well-differentiated hepatocellular carcinomas). Since then, radiologic studies have integrated this terminology for definite cancerous nodules (Edmonson grade II or higher) that are large enough to be detected by gross examination, and are surrounded by a rim of early hepatocellular carcinoma (Edmonson grade I) (14). On the

other hand, according to the new Japanese classification of early hepatocellular carcinoma, early advanced hepatocellular carcinomas, containing a small component of its composition as moderately differentiated hepatocellular carcinoma, is included in the category of early hepatocellular carcinoma. However, no size criterion was precisely defined by the Japanese investigators for the above-mentioned descriptions termed "a definite cancerous nodule" or "a small component". Nevertheless, it is expected that some of the previously defined early advanced hepatocellular carcinomas will be included in the early hepatocellular carcinomas under this new classification system, while others will be included with advanced hepatocellular carcinomas.

Due to the complexity of the terminology associated with nodular hepatocellular lesions, pathologists tried to integrate them internationally and published a new classification of the terminology in 1995 (15). Among these terms, "dysplastic nodule with subfocus of hepatocellular carcinoma" was categorized as an early stage hepatocellular carcinoma during the multi-step hepatocarcinogenesis. However, this differs quite a bit from the early hepatocellular carcinoma categorization of the new Japanese classification, such that, a well-differentiated hepatocellular carcinoma surrounded by dysplastic nodule cannot be included under the early hepatocellular carcinoma category of the new Japanese classification, even though it has an indistinct margin. This supports that early hepatocellular carcinomas were categorized differently under the new Japanese classification system, though it could be developed during the multi-step hepatocarcinogenesis.

Radiologically, several reports described the CT findings of conventionally defined early hepatocellular carcinomas (8–10). Based on these reports, the sensitivity of CT in detecting early hepatocellular carcinomas has been unsatisfactory, (only 56%), even with the three-phase CT (8). Moreover, the sensitivity did not significantly improve with the use of CT hepatic arteriography (55%) and CT during arterial portography (66%) (9, 10). In our study, the detection rate of early hepatocellular carcinomas was only 44%, which was even lower than the previous reports (8). It is interesting to note that the hepatocellular carcinoma detection rates of the eight patients excluded from the study, due to incomplete replacement growth, was 63% (5/8). Also, early hepatocellular carcinomas were detected more frequently with a single detector CT scanner than multi-detector CT scanners in our study, thus suggesting that advances in CT technology do not seem to ameliorate the detection rate. Considering these results, our low detection rate is due in part to the new classification system of early hepatocellular carcinomas. Furthermore,

based on the new Japanese classification, well-differentiated hepatocellular carcinomas with distinct margins, which are considered to be advanced hepatocellular carcinomas, were thus excluded from our study population and are considered to be better detected with imaging studies than those with indistinct margins.

Only 5 to 15% of the early hepatocellular carcinomas are presented as hyperattenuating tumors (i.e., hypervascular tumors) during the arterial phase, according to the previously reported literature (8–10). Similarly, only three (19%) of 16 early hepatocellular carcinomas showed hyperattenuation during the arterial phase. The most common tumor attenuation during the arterial phase was isoattenuation ($n = 9$) (i.e. normovascular). This finding could be explained by the reports which determined that the total number of arteries (including normal and abnormal arteries) in the early phases of hepatocellular carcinomas proved to be equal to or greater than the surrounding liver (16). The four remaining tumors were hypoattenuating (i.e. hypovascular), which could be attributed to immature neovascularization of the arterial tumor vessels and incomplete vascularization of the sinusoid-like blood spaces of the tumor (17).

During the equilibrium phase, six (38%) and 10 (62%) of the 16 tumors were hypoattenuating and isoattenuating, respectively. The high frequency of isoattenuation during this phase made it difficult to accurately diagnose early hepatocellular carcinomas. Some hyperattenuating tumors during the arterial phase mimicked arteriportal shunts. On the other hand, hypoattenuating tumors could resemble dysplastic nodules during the equilibrium phase. In summary, we realized that the enhancement patterns of the early hepatocellular carcinomas in our study did not seem to have characteristic features and furthermore, mimicked the various focal hepatic lesions in liver cirrhosis.

Of the 16 identified early hepatocellular carcinomas, eight (50%) demonstrated fatty metamorphosis ranging from 5 to 50% at pathology. Based on previous reports (18, 19), fatty metamorphosis was a prominent pathologic feature of early hepatocellular carcinomas, ranging in incidence from 45 to 53%. However, no evidence of fatty metamorphosis was observed by CT evaluation in the early hepatocellular carcinomas identified in our study. This could be related with the negligible extent of fatty metamorphosis or explained by the partial volume effect related to their small size. Nevertheless, it is believed that fatty metamorphosis lowered the tumor attenuation in our cases.

The mosaic pattern in hepatocellular carcinomas has traditionally suggested an advanced hepatocellular

carcinoma (12, 20). In our study, one tumor was found to have a mosaic pattern (Fig. 2) and it proved to have a small component of moderately differentiated hepatocellular carcinoma, which in turn suggested that early hepatocellular carcinomas could be seen as having a mosaic pattern under the new classification system.

Despite the findings, our study has some shortcomings. First, the ubiquity of the results would require the study of more patients to sufficiently demonstrate the CT features of early hepatocellular carcinomas under the new Japanese classification system. However, this tumor is rarely found and has only recently been introduced. Second, since this study was performed retrospectively, the type of CT scanners and scanning techniques was not standardized. Therefore, the degree of enhancement could be variable, particularly at the arterial phase. Third, only patients having undergone a surgical resection were included in our study. Therefore, a selection bias could be expected, even though, it is recognized that early hepatocellular carcinomas can currently only be diagnosed with surgical specimens.

In conclusion, we found that even the three-phase CT was not sensitive enough to properly detect early hepatocellular carcinomas under the new Japanese classification. The CT features of early hepatocellular carcinomas were summarized as small, ill-defined lesions with variable enhancement patterns. Although they are non-specific, knowledge of the CT findings identifying early hepatocellular carcinomas is necessary to understand and differentiate hepatocellular nodules which develop during multi-step hepatocarcinogenesis.

References

1. Sakamoto M, Hirohashi S, Shimosato Y. Early stages of multistep hepatocarcinogenesis: adenomatous hyperplasia and early hepatocellular carcinoma. *Hum Pathol* 1991;22:172-178
2. Kanai T, Hirohashi S, Upton MP, Noguchi M, Kishi K, Makuuchi M, et al. Pathology of small hepatocellular carcinoma. A proposal for new gross classification. *Cancer* 1987;60:810-819
3. Inoue K, Takayama T, Higaki T, Watanabe Y, Makuuchi M. Clinical significance of early hepatocellular carcinoma. *Liver Transpl* 2004;10:S16-S19
4. Yamamoto M, Takasaki K, Otsubo T, Katsuragawa H, Kataqiri S, Yoshitoshi K, et al. Favorable surgical outcomes in patients with early hepatocellular carcinoma. *Ann Surg* 2004;239:395-399
5. Takayama T, Makuuchi M, Hirohashi S, Sakamoto M, Yamamoto J, Shimada K, et al. Early hepatocellular carcinoma as an entity with a high rate of surgical cure. *Hepatology* 1998;28:1241-1246
6. The Liver Cancer Study Group of Japan. *The general rules for the clinical and pathological study of primary liver cancer*, 4th ed. Tokyo: Kanehara, 2000:13 [in Japanese]
7. The Liver Cancer Study Group of Japan. *The general rules for the clinical and pathological study of primary liver cancer*, 2th ed. Tokyo: Kanehara, 2003:15
8. Takayasu K, Furukawa H, Wakao F, Muramatsu Y, Abe H, Terauchi T, et al. CT diagnosis of early hepatocellular carcinoma: sensitivity, findings, and CT-pathologic correlation. *AJR Am J Roentgenol* 1995;164:885-890
9. Takayasu K, Muramatsu Y, Furukawa H, Wakao F, Moriyama N, Takayama T, et al. Early hepatocellular carcinoma: appearance at CT during arterial portography and CT arteriography with pathologic correlation. *Radiology* 1995;194:101-105
10. Takayasu K, Muramatsu Y, Mizuguchi Y, Moriyama N, Ojima H. Imaging of early hepatocellular carcinoma and adenomatous hyperplasia (dysplastic nodules) with dynamic CT and a combination of CT and angiography: experience with resected liver specimens. *Intervirology* 2004;47:199-208
11. Yoshikawa J, Matsui O, Takashima T, Ida M, Takanaka T, Kawamura I, et al. Fatty metamorphosis in hepatocellular carcinoma: radiologic features in 10 cases. *AJR Am J Roentgenol* 1988;151:717-720
12. Stevens WR, Gulino SP, Batts KP, Stephens DH, Johnson CD. Mosaic pattern of hepatocellular carcinoma: histologic basis for a characteristic CT appearance. *J Comput Assist Tomogr* 1996;20:337-342
13. Rim KS, Sakamoto M, Watanabe H, Matsuno Y, Nakanishi Y, Mukai K, et al. Pathology and DNA cytophotometry of small hepatocellular carcinoma with a nodule-in-nodule appearance -- evidence for stepwise progression of hepatocellular carcinoma. *Jpn J Clin Oncol* 1993;23:26-33
14. Winter TC 3rd, Takayasu K, Muramatsu Y, Furukawa H, Wakao F, Koga H, et al. Early advanced hepatocellular carcinoma: evaluation of CT and MR appearance with pathologic correlation. *Radiology* 1994;192:379-387
15. International Working Party. Terminology of nodular hepatocellular lesions. *Hepatology* 1995;22:983-993
16. Ueda K, Terada T, Nakanuma Y, Matsui O. Vascular supply in adenomatous hyperplasia of the liver and hepatocellular carcinoma: a morphometric study. *Hum Pathol* 1992;23:619-626
17. Kojiro M. Focus on dysplastic nodules and early hepatocellular carcinoma: an Eastern point of view. *Liver Transpl* 2004;10:S3-S8
18. Kutami R, Nakashima Y, Nakashima O, Shiota K, Kojiro M. Pathomorphologic study on the mechanism of fatty change in small hepatocellular carcinoma of humans. *J Hepatol* 2000;33:282-289
19. Kojiro M, Sugihara S, Nakashima O. *Pathomorphologic characteristics of early hepatocellular carcinoma*. In: Okuda K, Tobe T, Kitagawa T, eds. *Early detection and treatment of liver cancer*. (Gann monograph on cancer research, vol.38.) Tokyo: Japan Scientific Societies Press, 1991:29-37
20. Stevens WR, Johnson CD, Stephens DH, Batts KP. CT findings in hepatocellular carcinoma: correlation of tumor characteristics with causative factors, tumor size, and histologic tumor grade. *Radiology* 1994;191:531-537