



Original Article

Intraoperative imaging and navigation for C1-C2 posterior fusion

Ran Harel¹, Maya Nulman², Nachshon Knoller¹

¹Department of Neurosurgery, Spine Surgery Division, Sheba Medical Center, Ramat-Gan, Affiliated to Sackler Medical School, Tel-Aviv University, ²Sackler Faculty of Medicine, Tel-Aviv University, Tel-Aviv, Israel.

E-mail: *Ran Harel - harelran@gmail.com; Maya Nulman - mayanulman@gmail.com; Nachshon Knoller - nachshon.knoller@sheba.health.gov.il



***Corresponding author:**

Ran Harel,
Department of Neurosurgery,
Sheba Medical Center at Tel
Hashomer, Tel Hashomer
45373, N/A, Israel.

harelran@gmail.com

Received : 03 June 19

Accepted : 16 June 19

Published : 26 July 19

DOI

10.25259/SNI_340_2019

Quick Response Code:



ABSTRACT

Background: Cervical axial spine fusion is challenging as the anatomy is extremely variable, and screw misplacement can lead to severe complications. C1 lateral mass screws and C2 pedicle screws are routinely placed under either fluoroscopic guidance or imaging-assisted navigation. Here, we compared the two for axial screw placement.

Methods: We retrospectively evaluated patients' treated from 2011–2016 utilizing the Harms's procedure for C1-C2 screw fixation performed under either fluoroscopic guidance (nine patients) or image-assisted O-arm navigation (five patients). The groups had similar demographic and risk factors. Variables studied included operative time, estimated blood loss (EBL), accuracy of screw placement, screw reposition rates, and reoperation rates.

Results: The mean EBL was 555CC and 260CC, respectively (not a significant difference) utilizing fluoroscopic versus O-arm navigation. Of interest, the mean surgical duration was 27 min longer in the O-arm versus fluoroscopy group ($P = 0.03$). Ten C2 pedicle screws were performed using O-arm navigation. Alternatively, as 9 of 18 C2 pedicles were considered "risky" for the placement of fluoroscopic-guided pedicle screws, laminar screws were utilized. Although the accuracy rate of C1 and C2 screw placement was higher for the navigated group, this finding was not significant. Similarly, despite complications involving two unacceptably placed screws from the fluoroscopic guidance group, there were no neurological sequelae.

Conclusion: Axial cervical spine instrumentation is challenging. Utilization of Imaging-assisted navigation increases the accuracy and safety of screw placement.

Keywords: Axial spine, Intraoperative imaging, Posterior cervical approach, Spine instability, Spine navigation

INTRODUCTION

On 1994, Goel and Laheri first described a C1-C2 fusion utilizing C1 lateral mass screws, C2 pedicle screws, and a metal plate.^[4] The introduction of polyaxial cervical screws allowed the modification of technique introduced by Harms and Melcher on 2001.^[6] The surgical technique includes screw insertion utilizing anatomical landmarks and fluoroscopy. Intraoperative imaging and navigation systems were introduced to spine surgery to allow for more accurate screw insertion, while minimizing the surgical team exposure to radiation.^[1,5,8] Several studies have previously examined screw insertion with navigation in complex craniocervical cases;^[9] however, the results did not encompass complications, screw insertion accuracy, and estimated blood loss

This is an open-access article distributed under the terms of the Creative Commons Attribution-Non Commercial-Share Alike 4.0 License, which allows others to remix, tweak, and build upon the work non-commercially, as long as the author is credited and the new creations are licensed under the identical terms.

©2019 Published by Scientific Scholar on behalf of Surgical Neurology International

(EBL). Here, we compared the accuracy of screw placement using fluoroscopy versus O-arm navigation-guided C1-C2 instrumentation, along with an assessment of the attendant risks/complications and other variables.

METHODS

With IRB approval, we performed a retrospective review (2011–2016) utilizing the Harm's procedure for C1-C2 screw fixation performed under either fluoroscopic guidance (nine patients) or image-assisted O-arm navigation (five patients).

Surgical technique

The surgical technique for the fluoroscopic-guided group was previously described in multiple papers. As for the navigation-guided group, the O-arm was introduced; a lateral and AP views were taken to determine scan position. Following exposure, a scan was performed and transferred to the navigation unit. The lateral mass of C1 and C2 pedicle was drilled utilizing a navigated drill guide. The screwdriver was fitted with a Universal Tracker Instrument (Suretrak, Medtronic, Louisville, CO, USA), and screws were inserted into the drilled holes. O-arm scan confirmed screw positions. At the senior surgeon discretion, screw positions were adjusted during surgery. We

reviewed patient's demographics and statistical analysis was performed using the Student's *t*-test and Chi-squared test. *P* = 0.05 was considered statistically significant.

RESULTS

Before 2015, nine consecutive patients had fluoroscopic guidance for C1-C2 fusions, while between 2015 and 2016, five consecutive patients utilized O-arm navigation [Table 1]. Both groups exhibited comparable demographics and risk factors. For the fluoroscopy group, the EBL was doubled and mean surgical and anesthesia durations were shorter (27 and 18 min, respectively). Proved not statistically significant.

Assessment of the accuracy of screw placement with fluoroscopy versus O-arm

All the screws in the navigated group were graded as either optimal position (90% and 80%) or acceptable position (10% and 20%) [Table 2].

In the fluoroscopy group, only one of nine patients showed an unacceptably placed C1 screw (e.g., 1 Grade II (>2 mm, <4 mm) C2 screw). The fluoroscopic C1 accuracy rate was ideal (83%) and C2 Grade 0 (no deviation; 56%).

Table 1: Demographics, surgical specifications, and outcomes comparing the study group to the control group.

	O-arm navigation group	Fluoroscopy group	P-value
Patients	5	9	
Age	39.6	44.5	0.71
Gender (% males)	40%	67%	0.58
Risk factors	0	0	
Smoking	0	0	
Diabetes mellitus	0	0	
IHD	0	3 (33%)	
HTN			
Pathology	3 (60%)	5 (55.6%)	
Trauma	2 (40%)	4 (44.4%)	
Instability			
EBL (cc)	260	556	0.16
Surgery duration (min)	128	101	0.032
Anesthesia-surgical time (min)	92	74	0.17
Length of stay (days)	3.2	3.9	0.52
Length of follow-up (months)	1.8	2.4	0.64
Intraoperative screw reposition	1 (20%)	0 (0%)	
Screw malposition	0 (0%)	2 (22%)	
Revision of surgery	0	0	
Neurologic change	5 (100%)	5 (56%)	0.13
Improve	0 (0%)	4 (44%)	
Stable	0 (0%)	0 (0%)	
Deteriorate			
Discharge destination	6 (100%)	7 (78%)	0.51
Home	0 (0%)	2 (22%)	
Rehabilitation			
Total complications	0 (0%)	2 (22%)	0.64

In 9 of 18 C2 screws in the fluoroscopy group, the surgeon decided to perform laminar screw rather than pedicle screw due to anatomical variations including narrow pedicle or hypertrophied vertebral artery.

Complications involving O-arm navigation and fluoroscopic C1-C2 screw placement

All of the O-arm navigated cases were treated with C2 pedicle screws. One intraoperative scan demonstrated medial C1 screw position requiring repositioning during surgery (e.g., confirmed with a secondary scan) [Figure 1].

Table 2: C1 lateral mass screw and C2 pedicle screw accuracy.

	O-arm navigation group	Fluoroscopy group
C1 screws total	10	18
Type I: Ideal placement	9 (90%)	15 (83%)
Type II: Acceptable placement	1 (10%)	2 (11%)
Type III: Unacceptable placement	0 (0%)	1 (6%)
C2 screws total	10	9
Grade 0 (no deviation)	8 (80%)	5 (56%)
Grade 1 (<2 mm)	2 (20%)	3 (33%)
Grade 2 (>2 and <4 mm)	0 (0%)	1 (11%)
Grade 3 (>4 mm)	0 (0%)	0 (0%)

Using 2D fluoroscopy, there was one malpositioned C2 screw. This was picked up on the post-operative CT scan that demonstrated a lateral and inferior screw breach [Grade 2, Figure 2]. Of interest, both groups demonstrated comparable clinical and neurological outcomes, with only one misplaced screw being found in each group.

DISCUSSION

The subaxial cervical spine demonstrates high anatomical variability that increases surgical risks and suboptimal screw position. Utilization of navigation systems reportedly increases screw placement accuracy. Costa *et al.*^[3] reported 92.6% accuracy rate at C1-2 traumatic fractures operated with intraoperative 3D imaging-based navigation. Smith *et al.*^[9] used the O-arm in seven patients; of four patients undergoing C1-C2 stabilization, 75% of C2 screws were graded as medial pedicle breaches ranging 0.8–2.9 mm, but these caused no complications. Attia *et al.*^[2] reported using the O-arm for C1-C2 fusions and reported all screws to be in the desired trajectory without complications. In the current study, C2 screws were aborted for anatomical variations in the fluoroscopic group only, but all the C2 screws were inserted in the navigated group as navigation allows for more precise trajectory planning.

When Hitti *et al.*^[7] used the Harm's procedure in 20 navigated versus 25 fluoroscopy cases over a 9 years period,

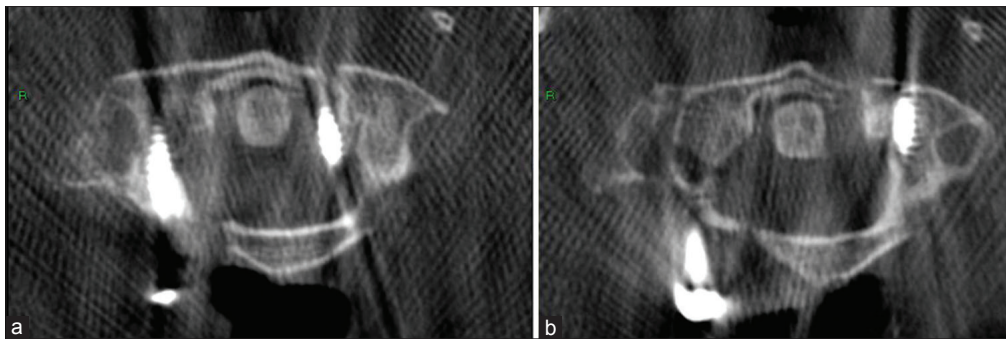


Figure 1: After screw placement, O-arm scan reveals left C1 screw medially displaced (a), the screw was repositioned and a later scan reveals ideal position (b).

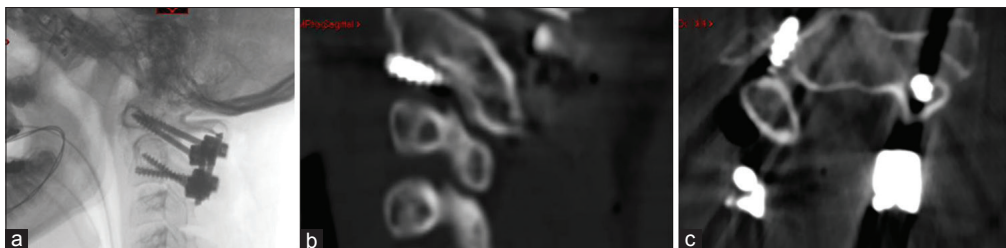

Figure 2: A patient undergoing C1-2 fluoroscopic-guided procedure for Os odontoid. (a) Demonstrates lateral fluoroscopic view. Post-operative CT scan reveals a malpositioned right C2 screw that was not evident on 2D fluoroscopy. Post-operative sagittal (b) and axial (c) scans demonstrate lateral and inferior screw breach (Grade 2).

they documented a major reduction of EBL (by over 50%) and a significantly longer procedure (157 vs. 198 min) time in the navigated group. In both Hitti's study and the current study, the EBL was reduced by 50% as a result of navigation utilization. We assume that navigated screw insertion reduces the need for anatomical dissection in the C1-C2 region, thus reducing intraoperative blood loss as we did not alter our surgical technique with navigation.

Fluoroscopic-guided Harm's procedure exposes the surgeons and the operating room team to ionizing radiation, forcing the team to work with lead aprons, thyroid shields, and protective eye covers. The surgeons need to customize their standing posture as the C-arm is partially obstructing access to the surgical site. Imaging-assisted navigation minimizes the surgical team radiation exposure, eliminates the need for radiation shields, and allows for comfortable access to the surgical site. This in term may reduce potential complication and personal health issues.^[1,5]

CONCLUSION

The anatomical properties of C1-C2 stabilization procedure necessitate accurate and safe screw insertion. Imaging-assisted navigation reduces surgical team radiation exposure and seems to allow for higher screw accuracy rates and reduces EBL.

Financial support and sponsorship

Nil.

Conflicts of interest

There are no conflicts of interest.

REFERENCES

1. Abdullah KG, Bishop FS, Lubelski D, Steinmetz MP, Benzel EC, Mroz TE, *et al.* Radiation exposure to the spine surgeon in lumbar and thoracolumbar fusions with the use of an intraoperative computed tomographic 3-dimensional imaging system. *Spine (Phila Pa 1976)* 2012;37:E1074-8.
2. Attia W, Orief T, Almusrea K, Alfawareh M, Soualmi L, Orz Y, *et al.* Role of the O-arm and computer-assisted navigation of safe screw fixation in children with traumatic rotatory atlantoaxial subluxation. *Asian Spine J* 2012;6:266-73.
3. Costa F, Ortolina A, Attuati L, Cardia A, Tomei M, Riva M, *et al.* Management of C1-2 traumatic fractures using an intraoperative 3D imaging-based navigation system. *J Neurosurg Spine* 2015;22:128-33.
4. Goel A, Laheri V. Plate and screw fixation for atlanto-axial subluxation. *Acta Neurochir (Wien)* 1994;129:47-53.
5. Hadelsberg UP, Harel R. Hazards of ionizing radiation and its impact on spine surgery. *World Neurosurg* 2016;92:353-9.
6. Harms J, Melcher RP. Posterior C1-C2 fusion with polyaxial screw and rod fixation. *Spine (Phila Pa 1976)* 2001;26:2467-71.
7. Hitti FL, Hudgins ED, Chen HI, Malhotra NR, Zager EL, Schuster JM, *et al.* Intraoperative navigation is associated with reduced blood loss during C1-C2 posterior cervical fixation. *World Neurosurg* 2017;107:574-8.
8. Mason A, Paulsen R, Babuska JM, Rajpal S, Burneikiene S, Nelson EL, *et al.* The accuracy of pedicle screw placement using intraoperative image guidance systems. *J Neurosurg Spine* 2014;20:196-203.
9. Smith JD, Jack MM, Harn NR, Bertsch JR, Arnold PM. Screw placement accuracy and outcomes following o-arm-navigated atlantoaxial fusion: A feasibility study. *Glob Spine J* 2016;6:344-9.

How to cite this article: Harel R, Nulman M, Knoller N. Intraoperative imaging and navigation for C1-C2 posterior fusion. *Surg Neurol Int* 2019;10:149.