

Chondrosarcoma of the Rib: Atypical Presentation and Management

Abstract

Chondrosarcoma is an uncommon malignant tumor of the rib and can have an atypical presentation based on age, gender, and clinical manifestation with differential diagnosis of intrathoracic mass. Management is surgical as the tumor is resistant to chemoradiation. Access to chest wall reconstruction is limited in many low-income countries and forms a barrier to patient compliance. We report an atypical presentation and describe a simple, easy, and cost-effective chest wall reconstruction method for chondrosarcoma of the rib in any resource-constrained setting.

Keywords: *Chondrosarcoma rib, intrathoracic mass, polypropylene mesh, surgery*

Résumé

Le chondrosarcome est une tumeur maligne peu commune de la côte et peut avoir une présentation atypique en fonction de l'âge, du sexe et de la manifestation clinique avec un diagnostic différentiel de masse intrathoracique. La prise en charge est chirurgicale car la tumeur est résistante à la chimioradiation. L'accès à la reconstruction de la paroi thoracique est limité dans de nombreux pays à faible revenu et constitue un obstacle à l'adhésion des patients. Nous rapportons une présentation atypique et décrivons une méthode de reconstruction de la paroi thoracique simple, facile et rentable pour le chondrosarcome de la côte dans un contexte de ressources limitées.

Mots-clés: *Chondrosarcome de la côte, chirurgie, maille de polypropylène, masse intrathoracique*

Introduction

Chondrosarcoma is a common malignant tumor that arises in the pelvis or long bones, but its presence in the ribs is uncommon, with an incidence of 0.5 per million person-years.^[1] They represent 20% of all chest wall neoplasms.^[2] Contrast-enhanced computed tomography is the gold standard investigation of choice for appropriate diagnosis and operative planning.^[3] They have significant potential for metastasis and are relatively resistant to chemoradiotherapy. Surgical excision with negative microscopic margins is the treatment of choice. This case report depicts an atypical presentation of primary chest wall mass resembling an intrathoracic tumor diagnosed to be chondrosarcoma managed by surgical excision and reconstruction.

Case Report

A 37-year-old woman who presented with mild chest pain had a chest X-ray done, which showed an opacity in the right lower zone

[Figure 1A]. She was referred to the Department of Cardiothoracic Surgery in October 2020. She was hemodynamically stable and afebrile. Her chest and abdominal examinations did not reveal any masses on palpation. Contrast-enhanced computed tomography scan (CECT) [Figure 1B] revealed an exophytic lesion measuring 4.9 cm × 4.9 cm × 8.6 cm, with calcification, arising from the right sixth rib and involving the seventh rib partially. The lesion showed mild post-contrast enhancement with no infiltration of adjacent structures. A CT-guided biopsy of the lesion was inconclusive. Under general anesthesia, she had surgical excision of the lesion, with wide excision margins, and chest wall reconstruction. An oblique incision was placed over the area of the lesion [Figure 2A] after localization with ultrasonography in the operating room. A reddish-white, hard mass measuring about 8 cm × 5 cm was found arising from the sixth rib and infiltrating a small segment of the seventh rib, abutting the diaphragm. The lesion was considered malignant. The lesion was excised, together with adjacent ribs, one above and one below, with excision margins of 4 cm [Figure 2B] without much difficulty.

How to cite this article: Dantis K, Kashyap NK, Thakur S, Hussain N, Singha SK. Chondrosarcoma of the rib: Atypical presentation and management. *J West Afr Coll Surg* 2021;11:25-7.

**Klein Dantis¹,
Nitin Kumar
Kashyap¹, Shiva
Thakur¹,
Nighat Hussain²,
Subrata Kumar
Singha³**

¹Department of Cardiothoracic Surgery, All India Institute of Medical Sciences, Raipur; ²Department of Pathology, All India Institute of Medical Sciences, Raipur; ³Department of Anesthesiology, All India Institute of Medical Sciences, Raipur, India

Received: 26-May-2021

Accepted: 21-Jan-2022

Published: 12-Jul-2022

Address for correspondence:

Dr. Klein Dantis,
Department of Cardiothoracic
Surgery, All India Institute
of Medical Sciences
(AIIMS), Raipur 492099,
Chhattisgarh, India.
E-mail: drkleindantis86@gmail.
com

Access this article online

Website:

www.jwacs-jcoac.org

DOI: 10.4103/jwas.jwas_12_21

Quick Response Code:



This is an open access journal, and articles are distributed under the terms of the Creative Commons Attribution-NonCommercial-ShareAlike 4.0 License, which allows others to remix, tweak, and build upon the work non-commercially, as long as appropriate credit is given and the new creations are licensed under the identical terms.

For reprints contact: reprints@medknow.com

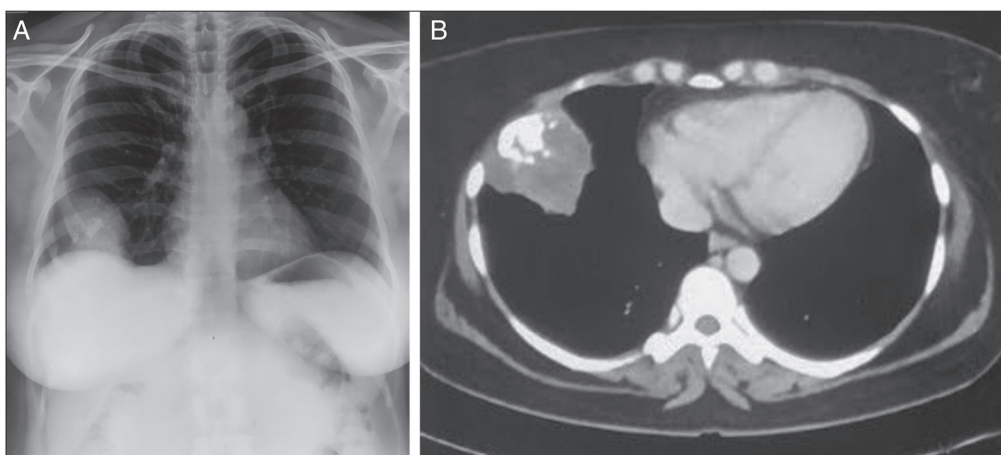


Figure 1: (A) Chest X-ray PA view showing homogenous opacity in the right lower zone. (B) CECT thorax showing mass arising from the sixth rib with intra-tumoral calcification resembling intrathoracic mass

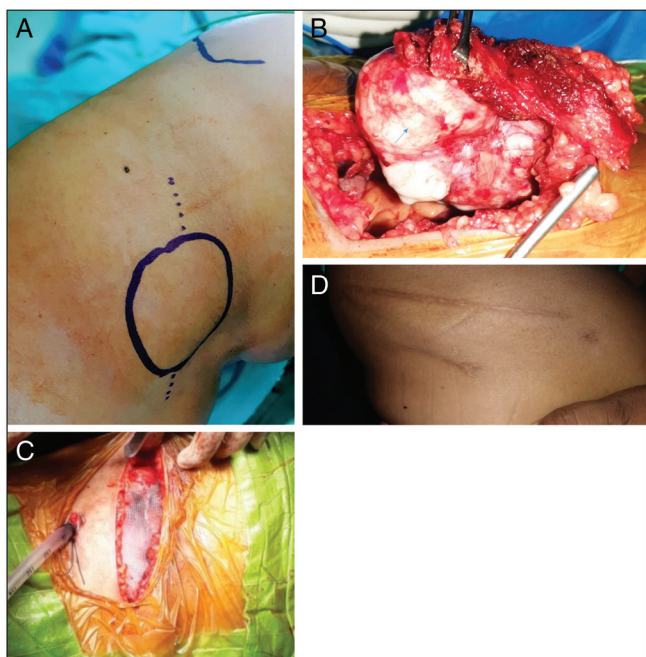


Figure 2: (A) Site of incision (dotted lines representing line of incision passing obliquely over the mass.). (B) Reddish-white hard mass arising from the sixth rib. (C) Placement of mesh. (D) Postoperative surgical scar healed by primary intension

A single chest drain was placed in a dependent position just above the diaphragm. The chest wall defect, measuring 12 cm × 8 cm was repaired with polypropylene mesh. As the defect was large, two meshes were joined adjacently and folded into two layers. Multiple prolene 2-0 stay sutures were placed in the defect connecting adjacent ribs. The mesh was placed over the defect and sutured with interrupted prolene 3-0 to the intercostal muscles [Figure 2C]. This provided better stability to the chest wall and prevented paradoxical chest wall movement. The wound was closed in layers. The postoperative course was uneventful, with the drain removed on the third postoperative day (POD). She was discharged on the seventh POD and the wound had healed by primary intention at

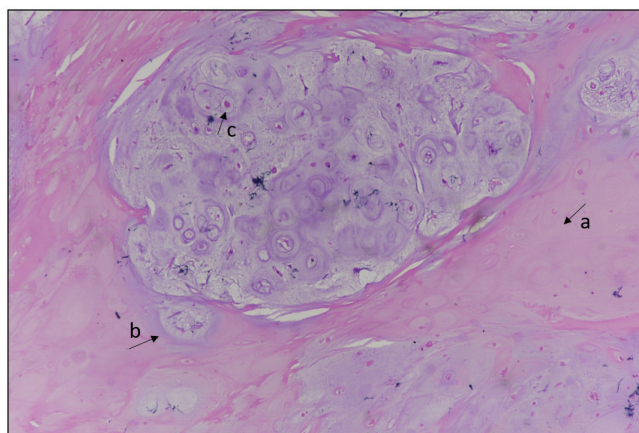


Figure 3: Histopathology (hematoxylin and eosin stain with 10x magnification) cartilaginous neoplasm showing increased cellularity (A), nodular growth (B) with binucleate nuclei (C) marked with arrows

two weeks follow-up [Figure 2C]. Histopathology showed chondroid neoplasm comprising of lobules of pleomorphic chondrocytes in binucleate forms with occasional mitosis and uninvolved bony resection margins, suggestive of grade 1 chondrosarcoma [Figure 3]. Her follow-up visits in the third and sixth months with a CT scan did not detect any recurrence.

Discussion

Chest wall chondrosarcoma is a slow-growing tumor presenting as painful swelling, especially in the fifth decade of life with the male gender being predominantly affected.^[3,4] They usually have an anterior location arising from the costochondral junction or sternum.^[3] Primary chondrosarcomas arise without an underlying etiology, whereas secondary chondrosarcomas arise from pre-existing enchondromas or osteochondromas.^[5] The patient in the present case study was a female in the fourth decade of life presenting with mild chest pain and in whom a chest X-ray detected a lesion. This is an unusual presentation seen in 6.5% of individuals who have what looks like an intrathoracic mass without a pre-existing lesion, suggesting a primary etiology in origin.^[1,6]

Intratumoral calcification on CT in the form of a “flocculent or popcorn” pattern has been described as the hallmark of chondrosarcoma, similarly was present in our case. They can also have associated bony destruction and soft tissue invasion; however, these were not present in the case presented.

A positron emission tomography (PET) scan can detect extrapulmonary metastases and provide better insight into the tumor grade as well as predict postoperative surgical outcomes.^[4] Magnetic resonance imaging is not routinely performed but can be used to assess extraosseous extension. As per the Surveillance, Epidemiology, and End Results (SEER) cancer registry database, tumor grade histologically is classified into four grades: well differentiated (grade 1), moderately differentiated (grade 2), poorly differentiated (grade 3), and undifferentiated (grade 4).^[7] Tumor grades have a definite role as a predictor for local recurrence, systemic metastasis, and survival.

Surgical excision with microscopically negative margins is the treatment of choice irrespective of the tumor grade, and chest wall reconstruction is recommended for full-thickness defect of more than 5 cm or anterior resection involving more than three ribs.^[8] Various techniques have been used in the reconstruction of the chest wall including meshes, methyl methacrylate cement, flaps, titanium plates, and the creation of neo-rib. However, we preferred using double-layered polypropylene mesh because of its inert property, ease of processing, and versatility for conversion into various shapes; it is also inexpensive, readily available, and produces promising results in extensive chest wall reconstruction.^[9] The role of Doxorubicin-based adjuvant therapy in grade 2 and 3 mesenchymal tumors has been described, but the available data is non-randomized and small.^[5] The role of radiotherapy in high-grade tumors is still unclear and it has failed to achieve better overall survival or cancer-specific survival.^[7]

Immune checkpoint blockade therapy is an emerging strategy in the management of chondrosarcoma. However, clinical trial outcomes are still expected, and the role of predictive biomarkers to determine efficacy is an essential step in the future.^[10] Post-operative surveillance consists of physical examination and thoracic imaging with chest X-rays or CT scans every six months for the first five years and thereafter annually for a minimum of ten years.

Conclusion

Chondrosarcoma of the rib is a rare tumor and can have an unusual presentation. Surgical management with negative margins is necessary to obtain beneficial results.

Informed consent was obtained from the patient for the purpose of this publication

Financial support and sponsorship

Nil.

Conflicts of interest

There are no conflicts of interest.

References

1. Brito ÍM, Teixeira S, Paupério G, Choupina M, Ribeiro M. Giant chondrosarcoma of the chest wall: A rare surgical challenge. *Autops Case Rep* 2020;10:e2020166.
2. Hann MC, Pettiford B, Babycos C. Novel chest wall reconstruction following excision of an xiphisternal chondrosarcoma. *Ochsner J* 2018;18:180-2.
3. Sangma MM, Dasiah S. Chondrosarcoma of a rib. *Int J Surg Case Rep* 2015;10:126-8.
4. Rascoe PA, Reznik SI, Smythe WR. Chondrosarcoma of the thorax. *Sarcoma* 2011;2011:342879.
5. Gelderblom H, Hogendoorn PC, Dijkstra SD, van Rijswijk CS, Krol AD, Taminiau AH, *et al.* The clinical approach towards chondrosarcoma. *Oncologist* 2008;13:320-9.
6. McAfee MK, Pairolero PC, Bergstralh EJ, Piehler JM, Unni KK, McLeod RA, *et al.* Chondrosarcoma of the chest wall: Factors affecting survival. *Ann Thorac Surg* 1985;40:535-41.
7. Gao Z, Lu T, Song H, Gao Z, Ren F, Ouyang P, *et al.* Prognostic factors and treatment options for patients with high-grade chondrosarcoma. *Med Sci Monit* 2019;25:8952-67.
8. Dantis K, Kashyap Y, Raju A, Bhardwaj S. Intercostal muscle cavernous haemangioma: A chest wall pandora's box. *Eur J Case Rep Intern Med* 2021;8:002248.
9. Dantis K, Brahmachari S, Raju A, Shankari S. An innovative technique of chest wall stabilization and reconstruction in traumatic flail chest: The figure-of-eight suture with polypropylene mesh and musculofascial flap. *Chin J Traumatol* 2022;25:122-4.
10. Thanindratan P, Dean DC, Nelson SD, Hornicek FJ, Duan Z. Advances in immune checkpoint inhibitors for bone sarcoma therapy. *J Bone Oncol* 2019;15:100221.