

Case Report

Ectopic prolactinoma within the sphenoidal sinus associated with empty sella

Pablo Ajler, Damián Bendersky, Santiago Hem, Alvaro Campero¹Department of Neurosurgery, Hospital Italiano de Buenos Aires, Buenos Aires, ¹Department of Neurosurgery, Hospital Padilla, Tucumán, ArgentinaE-mail: *Pablo Ajler - pablo.ajler@gmail.com; Damián Bendersky - damian.bendersky@hospitalitaliano.org.ar; Santiago Hem - Santiago.hem@hospitalitaliano.org.ar; Alvaro Campero - alvarocampero@yahoo.com.ar

*Corresponding author

Received: 22 February 12

Accepted: 09 April 12

Published: 14 May 12

This article may be cited as:Ajler P, Bendersky D, Hem S, Campero A. Ectopic prolactinoma within the sphenoidal sinus associated with empty sella. *Surg Neurol Int* 2012;3:47.Available FREE in open access from: <http://www.surgicalneurologyint.com/text.asp?2012/3/1/47/96066>

Copyright: © 2012 Ajler P. This is an open-access article distributed under the terms of the Creative Commons Attribution License, which permits unrestricted use, distribution, and reproduction in any medium, provided the original author and source are credited.

Abstract

Background: Pituitary adenomas are a common cause of endocrinal dysfunction, which comprise 10–20% of all intracranial tumors. Although almost all of them arise within the sella turcica, there are some rare cases in which a pituitary adenoma is located outside the intrasellar region, so it is defined as an ectopic pituitary adenoma (EPA).

Case Description: We described a case of a 31-year-old male with a serum prolactin (PRL) value of 240 ng/ml. Magnetic resonance imaging (MRI) showed a space-occupying mass within the sphenoid sinus (SS) which partially enhanced by gadolinium. MRI did not reveal any sellar floor defect and an empty sella was detected. As dopamine agonist treatment had failed in lowering the serum PRL level, he underwent surgical treatment. A transsphenoidal approach without opening the sellar floor was performed using an operating microscope and the lesion within the SS was completely removed.

Conclusion: Although intrasphenoidal EPAs are rare findings, the presence of an endocrine disorder related to pituitary hormones, and a space-occupying mass within the SS associated with either a normal sellar pituitary gland or an empty sella must lead us to suspect this diagnosis.

Key Words: Ectopic pituitary adenoma, empty sella, prolactinoma, sphenoid sinus

Access this article online**Website:**
www.surgicalneurologyint.com**DOI:**
10.4103/2152-7806.96066**Quick Response Code:**

INTRODUCTION

Pituitary adenomas are a common cause of endocrinal dysfunction, which comprise 10–20% of all intracranial tumors.^[2,15,18] Although almost all of them arise within the sella turcica, there are some rare cases in which a pituitary adenoma is located outside the intrasellar region, and if there is an empty sella too, it is an even more rare finding. If this is placed outside the sella and it is not in continuity with an intrasellar normal pituitary gland or an empty sella, it is defined as an ectopic pituitary adenoma

(EPA), which may be intra or extracranial.^[1,6,11,14,16] Most of the EPAs are situated outside the blood–brain barrier and approximately 40% are located in the sphenoid sinus (SS).^[1,2,14,17] We present a case of EPA within the SS associated with empty sella which was confirmed with the surgical proof of an intact dura of the sellar floor.

CASE REPORT

A 31-year-old male with a 4-month history of sexual dysfunction was referred to the endocrinological

department. His past medical history was negative and he was not taking any medication. Psychogenic impotence was ruled out by a psychiatric examination. He had a serum prolactin (PRL) value of 240 ng/ml. Laboratory examinations, including other pituitary hormones, did not reveal other abnormalities. Magnetic resonance imaging (MRI) showed a space-occupying mass within the SS, which partially enhanced by gadolinium. MRI did not reveal any sellar floor defect and an empty sella was detected [Figures 1 and 2]. These findings suggested the presence of an ectopic prolactinoma within the SS. The patient was put on bromocriptine at a dose of 1.25 mg once a day for 1 week, which was then increased to 1.25 mg twice a day for 2 months. However, he continued to present sexual dysfunction and his serum PRL level did not decrease sufficiently. Thus, bromocriptine was changed to cabergoline administered at a dose of 0.25 mg twice a week and then it was increased gradually until reaching a dose of 1.5 mg three times a week. Three months later, the patient still had sexual dysfunction and his serum PRL value was 195 ng/ml. Thereupon, he was referred to the neurosurgical department. Surgical treatment was proposed because of three reasons. First, dopamine agonist treatment administered thus far had failed in lowering the serum PRL level. Second, clinical manifestations due to hyperprolactinemia persisted in spite of medical treatment; and third, he told the physicians that he wanted to get his wife pregnant, as they had been planning for a long time. So, he underwent surgical treatment. A transsphenoidal approach without opening the sellar floor was performed using an operating microscope and the lesion within the SS was completely removed. An intact sellar floor was confirmed during surgery. The postoperative course was uneventful. Histological examination including

immunohistochemical study of the resected specimen report showed prolactinoma. The serum PRL level decreased until reaching normal values. Fourteen months later, his wife became pregnant.

DISCUSSION

Whereas EPAs are not in continuity with an intrasellar normal pituitary gland by definition, they must be distinguished from invasive pituitary adenomas, which are connected with the sellar pituitary gland through a sellar floor defect. The difference between these two types of pituitary adenomas is based on the state, intact or damaged, of the dura of the sellar floor, and it may be seen accurately on MRI. Also, empty sella may be associated with EPAs.^[3,7,9,14,22] However, surgical proof of an intact dura of the sellar floor is the gold standard for evaluation of this distinguishing feature.^[3,16] In our patient, the final diagnosis of EPA was made after its surgical confirmation.

As we have already referred, EPAs may be intra or extracranial. Intracranial EPAs are found in the hypothalamic region, cavernous sinus, third ventricle, pituitary stalk, and suprasellar region, while extracranial ones are usually located at the SS or the sphenoid bone, and rarely at the nasopharynx or clivus.^[1,2,11,14,17,19,22]

During development, primitive pituitary gland separates into pharyngeal and distal parts in the 8th gestational week. Last ones constitute the Rathke's pouch, which migrates upward to develop the sellar pituitary gland. Its route is known as craniopharyngeal canal.^[4,8,14,18,21] The pharyngeal pituitary exists in every individual, sometimes for a long time, and it is also a common autopsy finding. Although its function is doubtful because of its extreme

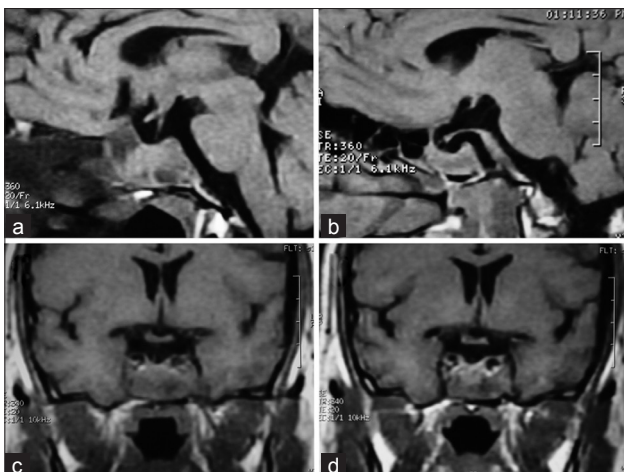


Figure 1: (a, c) Sagittal and coronal T1-weighted MRI brain scan showing a sphenoidal sinus tumor. (b, d) Sagittal and coronal contrast-enhanced T1-weighted MRI showing a sphenoidal sinus tumor with heterogeneous contrast enhancement

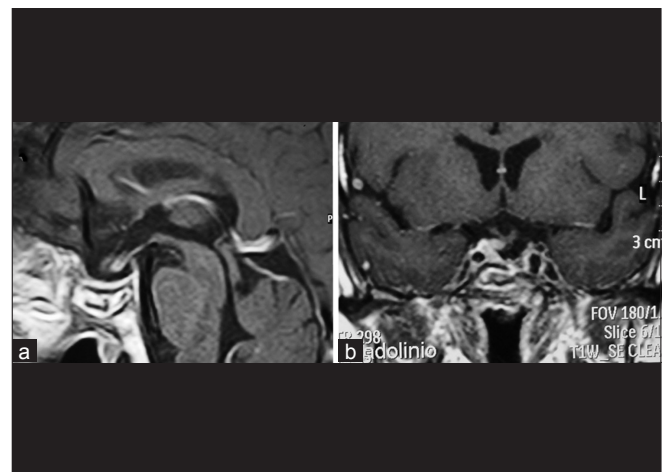


Figure 2: (a, b) Sagittal and coronal contrast-enhanced T1-weighted postoperative MRI showing complete resection of the tumor

small volume and its lacking of a portal system or any connection with the hypothalamus, it may produce the anterior pituitary hormones. In spite of these doubts, pharyngeal pituitary cells are similar to sellar pituitary cells and it may react in some altered hormonal states such as in hypophysectomized patients. Thus, pharyngeal pituitary may be thought as a physiological tissue and not as a pathological embryonic remnant.^[2,6,8,14] Extracranial EPAs may arise from orthotopic pharyngeal pituitary tissue in the nasopharyngeal region which then can reach the SS through its opening, or it may originate from remnant pituitary tissue in the craniopharyngeal canal which might be retained during the cephalic invagination of Rathke's pouch.^[2,4,6-8,10,11,14,16,20-22] Intracranial extrasellar adenomas, also known as intracranial ectopy, arise from cell remnants of the sellar pituitary gland, which were likely retained during development.^[14] EPAs are classified into three types: type 1 EPAs develop from remnant pituitary cells along Rathke's pouch migration pathway, type 2 are derived from cells of the supradiaphragmatic portion of the pars tuberalis located in the suprasellar region; and type 3 are actually invasive pituitary adenomas.^[1,17]

In case of an ectopic pituitary mass associated with an empty sella, the speculation is that during development of the anterior pituitary gland, most of the precursors remained in the SS and only a small number of cells constituted the anterior pituitary, leading to the empty sella, which is shown by MRI scans.^[3,6,9,16]

Although between one-third and one-half of EPAs are non-functioning tumors, these may secrete any anterior pituitary hormone, such as sellar pituitary adenomas. Thus, it may cause several endocrine disorders such as Cushing's disease, acromegaly, or hyperprolactinemia.^[11,19] Adrenocorticotrophin-secreting adenomas represent approximately 50% of all endocrine active EPAs. Hence, prolactinomas are not the most frequent type of EPA as would be expected because of its altered vascular supply and its likely lacking of connections with the hypothalamus which inhibits PRL secretion. Otherwise, intrasphenoidal ectopic prolactinomas are rare findings. Furthermore, majority of patients who had an EPA were men, while prolactinomas are more frequent in women.^[2,10,12,19]

Because of its low frequency, there is not any accurate guideline for the treatment of ectopic prolactinomas. Regarding sellar prolactinomas, medical treatment is almost always the first choice and surgical treatment is indicated in those patients who fail to normalize serum PRL level in spite of using dopamine agonists, are intolerant for these medications, or whose tumors compress the optic nerves, as also in the presence of a macroprolactinoma, or in patients who present with neurological deficits, cerebrospinal fluid leakage due to

tumor shrinkage after dopamine agonists or pituitary apoplexy.^[12,13,15] A man who has a prolactinoma which causes sexual dysfunction has a clear indication for therapy. Therefore, in these men who wish their wives to get pregnant, the risks and benefits of surgical and medical treatment should be explained in detail to each patient.^[5] Either microscopic transsphenoidal or transnasal endoscopic surgery may be performed to treat EPAs within the SS and decision making of which one to use is based on each neurosurgeon's experience.^[1,4,6,9,10,14,17,18,20]

CONCLUSION

Although intrasphenoidal EPAs are rare findings, the presence of an endocrine disorder related to pituitary hormones and a space-occupying mass within the SS associated with either a normal sellar pituitary gland or an empty sella must lead us to suspect this diagnosis. It must be distinguished from an invasive pituitary adenoma which is a different entity, and thus it has not the same physiopathology.

REFERENCES

1. Ali R, Noma U, Jansen M, Smyth D. Ectopic pituitary adenoma presenting as midline nasopharyngeal mass. *Ir J Med Sci* 2010;179:593-5.
2. Ballaux D, Verhelst J, Pickut B, De Deyn PP, Mahler C. Ectopic macroprolactinoma mimicking a chordoma: A case report. *Endocr Relat Cancer* 1999;6:117-22.
3. Das CJ, Seith A, Gamanagatti S, Goswami R. Ectopic pituitary adenoma with an empty sella. *AJR Am J Roentgenol* 2006;186:1468-9.
4. Esteban F, Ruiz-Avila I, Vilchez R, Gamero C, Gomez M, Mochon A. Ectopic pituitary adenoma in the sphenoid causing Nelson's syndrome. *J Laryngol Otol* 1997;111:565-7.
5. Gilliam MP, Molitch ME, Lombardi G, Colao A. Advances in the treatment of prolactinomas. *Endocr Rev* 2006;27:485-534.
6. Gondim JA, Schops M, Ferreira E, Bulcão T, Mota JJ, Silveira C. Acromegaly due to an ectopic pituitary adenoma in the sphenoid sinus. *Acta Radiol* 2004;45:689-91.
7. Heitzmann A, Jan M, Lecomte P, Ruchoux MM, Lhuin Y, Tillet Y. Ectopic prolactinoma within the sphenoid sinus. *Neurosurgery* 1989;24:279-82.
8. Hori A, Schmidt D, Rickels E. Pharyngeal pituitary: Development, malformation, and tumorigenesis. *Acta Neuropathol* 1999;98:262-72.
9. Hori E, Akai T, Kurimoto M, Hirashima Y, Endo S. Growth hormone-secreting pituitary adenoma confined to the sphenoid sinus associated with a normal-sized empty sella. *J Clin Neurosci* 2002;9:196-9.
10. Horiuchi T, Tanaka Y, Kobayashi S, Unoki T, Yokoh A. Rapidly-growing ectopic pituitary adenoma within the sphenoid sinus--Case report. *Neurol Med Chir (Tokyo)* 1997;37:399-402.
11. Ibarra-de la Torre A, Trujillo-Ojeda HM, Silva-Morales F, Ceballos-Arellano I, Acha-Herrera RE, Rivera-Salgado I, et al. Invasive adenoma in sphenoid sinus and clivus. *Arch Neurocienc (Mex)* 2005;10:191-5.
12. Jane JA Jr, Laws ER Jr. Surgical management of pituitary adenomas. *Singapore Med J* 2002;43:318-23.
13. Kreutzer J, Buslei R, Wallaschofski H, Hofmann B, Nimsky C, Fahlbusch R, et al. Operative treatment of prolactinomas: Indications and results in a current consecutive series of 212 patients. *Eur J Endocrinol* 2008;158:11-8.
14. Kurowska M, Tarach JS, Zgliczyński W, Malicka J, Zieliński G, Janczarek M. Acromegaly in a patient with normal pituitary gland and somatotrophic adenoma located in the sphenoid sinus. *Endokrynol Pol* 2008;59:348-51.
15. López-Arbolay O, Morales-Sabina O, González-González JL, Valdés-Lorenzo N. Transsphenoidal approach to prolactinomas. *Neurocirugia (Astur)* 2006;17:226-31.

16. Matsuno A, Katayama H, Okazaki R, Toriumi M, Tanaka H, Akashi M, et al. Ectopic pituitary adenoma in the sphenoid sinus causing acromegaly associated with empty sella. *ANZ J Surg* 2001;71:495-8.
17. Pasquini E, Faustini-Fustini M, Sciarretta V, Saggese D, Roncaroli F, Serra D, et al. Ectopic TSH-secreting pituitary adenoma of the vomerosphenoidal junction. *Eur J Endocrinol* 2003;148:253-7.
18. Quitral R, Contreras JM. Ectopic hypophysial adenoma: Case report and literature review. *Rev Otorrinolaringol Cir Cabeza Cuello* 2008;68:295-300.
19. Siegert B, vz Mühlen A, Brabant G, Saeger W, Vogt-Hohenlinde C. Ectopic nonfunctioning pituitary adenoma in the sphenoid sinus. *J Clin Endocrinol Metab* 1996;81:430-1.
20. Trulea M, Patey M, Chaufour-Higel B, Bouquigny F, Longuebray A, Rousseaux P, et al. An unusual case of ectopic adrenocorticotropin secretion. *J Clin Endocrinol Metab* 2009;94:384-5.
21. Wang H, Yu W, Zhang Z, Xu W, Zhang F, Bao W. Ectopic pituitary adenoma in the spheno-orbital region. *J Neuroophthalmol* 2010;30:135-7.
22. Yang BT, Chong VF, Wang ZC, Xian JF, Chen QH. Sphenoid sinus ectopic pituitary adenomas: CT and MRI findings. *Br J Radiol* 2010;83:218-24.