

Thyroidectomy via unilateral axillo-breast approach (UABA) with gas insufflation: prospective multicentre European study

David Saavedra-Perez^{1*}, Marti Manyalich¹, Paula Dominguez¹, Jaime Vilaça², Julio Jordan³, Miguel A. Lopez-Boado¹, Ramon Rull¹ and Oscar Vidal¹

¹Unit of Medical and Surgical Endocrinology, Endocrine Surgery, Department of General and Digestive Surgery, Hospital Clinic of Barcelona, University of Barcelona, Barcelona, Spain

²Endocrine Surgery, Department of General and Digestive Surgery, Hospital da Luz Arrábida, Universidade do Minho, Porto, Portugal

³Endocrine Surgery, Department of General and Digestive Surgery, University Hospital Nuestra Señora de la Candelaria, La Laguna University, Tenerife, Spain

*Correspondence to: David Saavedra-Perez, Unit of Medical and Surgical Endocrinology, Endocrine Surgery, Department of General and Digestive Surgery, Institute of Digestive and Metabolic Diseases, Hospital Clinic of Barcelona, University of Barcelona, C/Villarroel 170, E-08036 Barcelona, Spain (e-mail: dsaavedr@clinic.cat)

Abstract

Background: Extracervical approaches for thyroidectomy are seldom explored in the western population. The objective of this study was to evaluate the outcomes of hemithyroidectomy via endoscopic unilateral axillo-breast approach (UABA) with gas insufflation.

Method: Consecutive patients undergoing UABA hemithyroidectomy for symptomatic benign or cytologically indeterminate nodules (Bethesda III lesions) of less than 5 cm from July 2015 to December 2020 at three European institutions were included. Patients were excluded if presenting with a BMI more than 25 kg/m², had previous neck surgery and/or radiation, had bilateral thyroid lesions, retrosternal goitre, Hashimoto thyroiditis or Graves' disease. Follow-up was carried out at 2 weeks, 3 months and 1 year. Outcomes of interest were surgical (including operating time, mean duration of hospital stay and complications) and self-assessed cosmetic outcomes.

Results: Out of 984 patients treated with hemithyroidectomy during the study interval, 253 were selected, including 214 women and 39 men. Patients' mean age was of 46.6 years with a mean BMI of 22.57. Mean operating time was 72.9 minutes. A transient recurrent laryngeal nerve injury was reported in 3.6 per cent of the patients, but none was persistent. Transient pectoral/cervical hypoesthesia was noted in 24.1 per cent of patients, with no permanent hypoesthesia. Skin burns and subcutaneous hematoma developed in 2.4 per cent and 2 per cent of patients but resolved within the third month after surgery. There was no tracheal/oesophageal perforation, conversion to open surgery or reoperation. The final pathology revealed 241 benign nodules, nine underlying papillary thyroid carcinomas, and three cases of follicular carcinoma. Hospital discharge was achieved on the first in 68.8 per cent of the patients and on the second postoperative day in 31.2 per cent of the cases. All patients were satisfied with the cosmetic aspect.

Conclusion: In selected patients, UABA with gas insufflation for hemithyroidectomy could be performed for the treatment of unilateral thyroid pathologies.

Introduction

Thyroid nodules are significantly more common in young women than in men¹. Large nodules give a visible cosmetic defect and compressive neck symptoms, requiring surgical intervention^{1,2}. Conventional open thyroidectomy, through the classic Kocher incision, leaves a noticeable scar in the lower neck that can turn into keloids or hypertrophic scars and lead to paraesthesia or hyperaemia^{2,3}. Neck scar has been shown to significantly affect quality of life⁴⁻⁶. As minimally invasive techniques evolve, different methods have been developed to apply it in thyroid gland surgery^{7,8}. The potential benefits are to limit external scarring, improve cosmesis, and reduce postoperative pain and recovery time after surgery without compromising treatment efficacy⁷⁻⁹.

Minimally invasive approaches for thyroidectomy can be classified as cervical or extracervical approaches^{7,8}. Cervical approaches, which include minimally invasive video-assisted thyroidectomy (MIVAT) and anterior and lateral cervical

options, have the drawback of keeping scar(s) in the neck^{7,8}. Extracervical techniques are defined by the incision site such as breast, transaxillary, anterior chest wall, unilateral axillo-breast approach (UABA), axillo-bilateral breast, bilateral axillary-breast, postauricular, and the transoral approach (TOETVA)^{7,8}. These techniques are also classified according to the use of gas (carbon dioxide) insufflation and the assistance of a surgical robot^{7,8}. Although several studies have compared the different minimally invasive approaches in terms of feasibility, invasiveness, and cosmesis, there is still no consensus on which approach is the best⁷⁻⁹; however, UABA and TOETVA are currently the most popular and accepted extracervical approaches⁷⁻¹². Each of these two approaches has its own pros and cons based on its degree of invasiveness, ease, and its related cosmetic, surgical and oncological outcomes⁷⁻¹².

UABA thyroidectomy was first reported in 2013, with gas insufflation as a modification of the techniques without gas

Received: 18 August 2021. Revised: 05 May 2022. Accepted: 20 May 2022

© The Author(s) 2022. Published by Oxford University Press on behalf of BJS Society Ltd.

This is an Open Access article distributed under the terms of the Creative Commons Attribution License (<https://creativecommons.org/licenses/by-nc/4.0/>), which permits unrestricted reuse, distribution, and reproduction in any medium, provided the original work is properly cited.

insufflation previously described^{13–15}. Both UABA and TOETVA are cosmetically good and surgically efficient but too invasive by the skin flap dissection to introduce the skin retractor to maintain the surgical workspace^{14–16}. UABA with gas insufflation is theoretically less invasive with the preservation of cosmetic outcomes by keeping the scars outside the neck^{10,13}. Of note, most reported studies evaluating minimally invasive extracervical approaches for thyroidectomy come from Asian countries where they are widely accepted^{7,8}. However, in American and European countries, these minimally invasive surgical approaches are adopted with caution due to different issues, such as differences in population, technical complexity and relative costs^{2,9}. Currently, there are few European reports on the extracervical approaches for thyroidectomy and no European studies evaluating the thyroidectomy via UABA with gas insufflation^{8,9}. The objective of this study was therefore to evaluate the surgical and cosmetic outcomes of endoscopic thyroidectomy via UABA with gas insufflation to a one-sided thyroid nodule performed at three different European centres.

Methods

This was a prospective cohort study investigating patients undergoing hemithyroidectomy at three European university-affiliated hospitals (Hospital Clinic of Barcelona, Hospital da Luz Arrábida and University Hospital Nuestra Señora de la Candelaria) with recognized endocrine and minimally invasive surgical units, between July 2015 to December 2020.

The study was approved by the Clinical Research Ethics Committees of the participating hospitals, and all patients were fully informed about the procedure before giving their written consent. Data were entered in a database in SPSS® (IBM, Armonk, New York, USA). This study was designed, developed, analysed and reported in accordance with the STROBE statement recommendations¹⁷.

Patients

Selection criteria

Inclusion criteria were uniform among the three institutions and included the following: patient desire to avoid a cervical scar, BMI less than 25 kg/m², and symptomatic benign or cytologically indeterminate nodules (Bethesda III lesions) less than 5 cm. Patients were excluded if they were unable to tolerate

anaesthesia, had previous neck surgery and/or radiation to the lower neck or upper chest, had bilateral thyroid lesions requiring total thyroidectomy, retrosternal goitre, Hashimoto thyroiditis or Graves' disease.

Procedures

A neck and breast physical examination, laboratory tests, ultrasonographic evaluation, and fine needle aspiration cytology were performed before the operation, according to international guidelines^{1,18}.

All operations were performed by experienced minimally invasive endocrine surgeons. One surgeon at each enrolled hospital performed the UABA procedures. These surgeons completed their learning curve before patient enrolment for this study (more than 30 endoscopic thyroidectomies have been suggested as the cutoff number for a complete learning curve for this type of procedure)^{7,8}. Antibiotics were not used prophylactically. For the purpose of this study, a 'hemithyroidectomy' was defined as a unilateral thyroid lobectomy plus isthmusectomy. Based on the previously described technique, patients were in a supine position with the lesion-side arm abducted and the neck extended^{10,13,19}. *Figure 1* shows the cervical skin landmarks and the trocar position. Subcutaneous dissection through the first 10 mm skin incision was started with a vascular tunneller for insertion of a 10 mm trocar and a 10 mm 30 degree fiberoptic endoscope, the other two 5 mm trocars were inserted under direct vision. The carbon dioxide gas insufflation pressure was maintained between 5 and 8 mmHg throughout the surgery. The skin/subcutaneous flap up to the sternal head of the sternocleidomastoid muscle and the clavicular head was dissected with an electrothermal device (a 5 mm Ligasure laparoscopic sealer/divider with a blunt and dolphin tip measuring 37 cm (Medtronic, Minnesota, USA) and/or 5 mm Harmonic Scalpel ACE laparoscopic shears measuring 36 cm (Ethicon, California, USA)). The working field was created by dissecting the subplatysmal plane to the midline and upper border of the sternum, leaving access between the sternocleidomastoid and the strap muscles and, dissecting between the internal jugular vein and the sternothyroid muscle the thyroid lobe was revealed. As shown in *Fig. 2*, after dissection of the trachea and inferior pole of the gland, the thyroid lobe should be retracted superiorly and medially to identify the recurrent laryngeal nerve and parathyroid glands. Identification of the inferior laryngeal nerve could be made

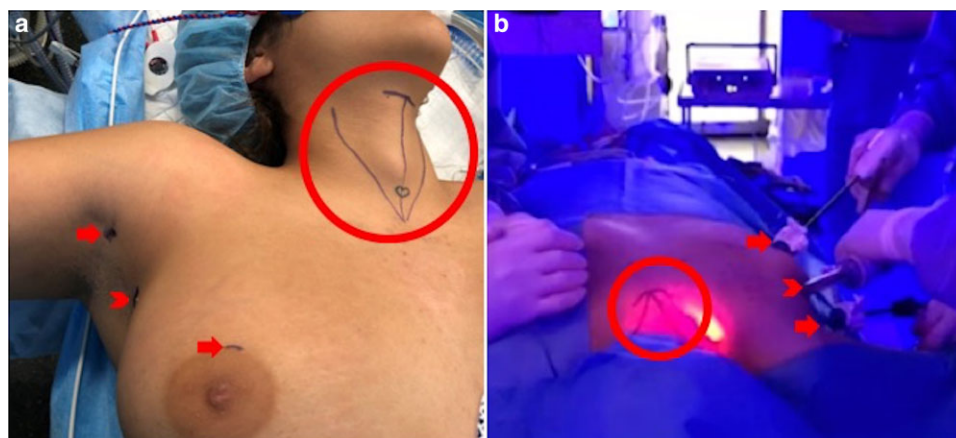


Fig. 1 a Patient position and cervical skin landmarks (circle: cricoid cartilage, bilateral internal borders of sternocleidomastoid muscle and the sternal notch). b Trocar position (arrow, 5 mm trocar; arrowhead, 10/12 mm trocar).

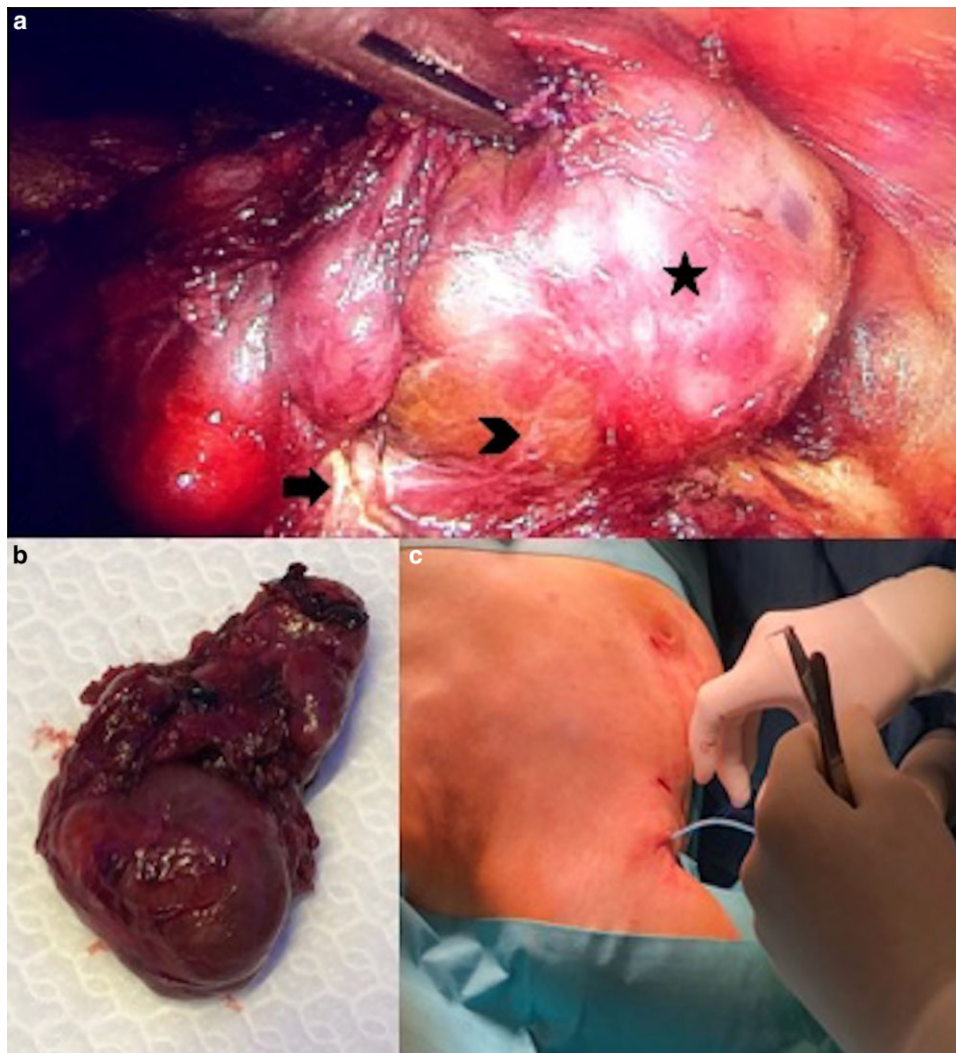


Fig. 2 a Intraoperative workspace and visualization of right RLN (arrow), right inferior parathyroid gland (arrowhead) and thyroid nodule (asterisk). b Specimen extraction. c Surgical drain insertion.

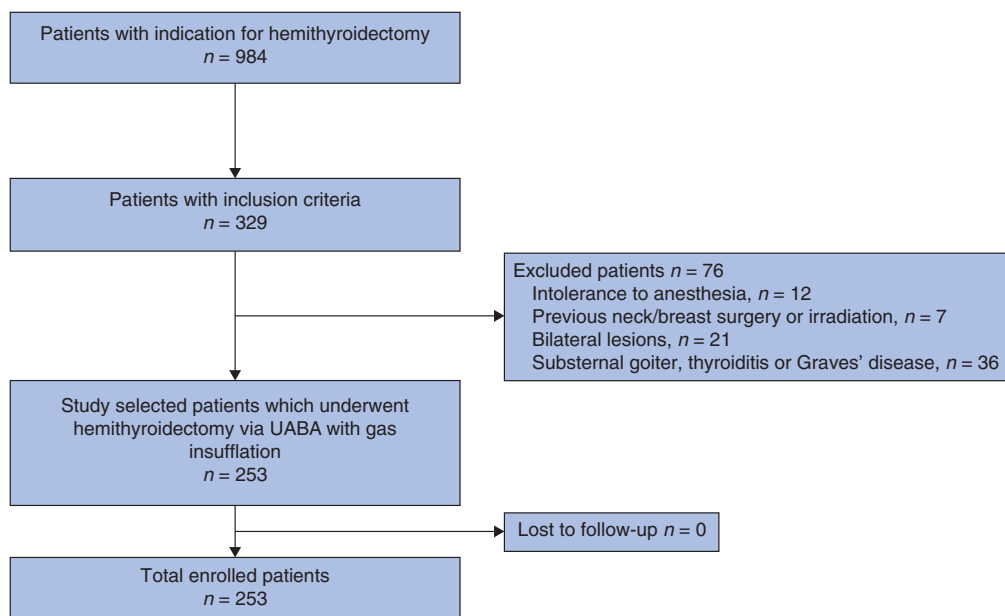


Fig. 3 Selection of patients for hemithyroidectomy via unilateral axillo-breast approach (UABA) with gas insufflation.

Table 1 Demographic data and characteristics of patients undergoing hemithyroidectomy via unilateral axillo-breast approach with gas insufflation

Variables	Number of patients, n = 253
Sex ratio (M:F)	214/39 (84.6/15.4)
Age (years), mean (range)	46.6 (21–71)
BMI, kg/m ² , mean(s.d.)	22.57(3.2)
ASA score	
I	146 (57.7)
II	95 (37.6)
III	12 (4.7)
IV	0
Symptoms	
Asymptomatic	129 (51)
Swelling	95 (37.5)
Compression	5 (2)
Swelling and compression	2 (0.8)
Pain	5 (2)
Other	17 (6.7)
Thyroid function	
Normal	241 (95.3)
Hyperthyroidism	7 (2.7)
Hypothyroidism	5 (2)
Nodule size, mean (range), mm	29.6 (14–48)
Affected location	
Right lobe	140 (55.3)
Left lobe	113 (44.7)

Values are n (%) unless otherwise indicated.

before dissection of inferior gland pole. Intraoperative nerve monitoring with the NeuroSign 100 system (Inomed, Teningen, Germany) was performed for all interventions. After these safety steps, dissection and transection of the superior lobe pole, superior thyroid arteries, Berry's ligament and isthmus were performed with the electrothermal device. Surgical specimen was retrieved inside an endoscopic bag through the 10 mm axillary port and a surgical drain was placed (Fig. 2). Skin and the subcutaneous flap were compressed with a dressing.

Outcomes of interest

Primary endpoint was the determination of overall complication rate (temporary or permanent vocal cord paralysis, wound infection, seroma, postoperative haemorrhage/hematoma, skin burns, subcutaneous emphysema, neck or chest wall paraesthesia, and difficult swallowing). To assess vocal cord function, a laryngoscopy examination was performed before surgery and 1 day after surgery. Vocal cord paralysis was considered permanent when no evidence of recovery was observed within 6 months after surgery. Secondary endpoints were mean operating time (the time from skin incision to closure, measured in minutes), intraoperative blood loss (measures in millilitres), postoperative pain (assessed by visual analogue scale (VAS)), surgical drain output (measured daily until the surgical drain was removed if amount was less than 20 ml/day), mean time to surgical drain removal (measured in days), mean duration of hospital stay (measured in days), and cosmetic satisfaction using a simple self-assessed scoring system (1, extremely dissatisfied; 2, dissatisfied; 3, acceptable; 4, satisfied; and 5, extremely satisfied). Furthermore, sex, age, BMI, ASA score, symptoms, thyroid function, affected location, and pathological results and tumour size were recorded. Outpatient follow-up was conducted at 2 weeks and 3 and 12 months after surgery.

Table 2 Surgical outcomes

Variable	Follow-up			
	2 weeks	3 months	12 months	
Subcutaneous dissection, (min) mean (s.d.)	27.5(5.8)			
Hemithyroidectomy, (min) mean (s.d.)	45.4(7)			
Total surgical time, (min) mean (s.d.)	72.9(12.8)			
Intraoperative bleeding				
<10 ml	253 (100)			
>10 ml	0 (0)			
Complications				
Minor	65 (25.7)	34 (13.4)	0 (0)	0 (0)
Pectoral hypoesthesia	57 (22.5)	29 (11.5)	0 (0)	0 (0)
Cervical hypoesthesia	39 (15.4)	18 (7.1)	0 (0)	0 (0)
Subcutaneous emphysema	9 (3.6)	0 (0)	0 (0)	0 (0)
Major	17 (6.7)	12 (4.7)	6 (2.4)	0 (0)
Vocal cord paralysis	9 (3.6)	6 (2.4)	6 (2.4)	0 (0)
Pain ≥ 3 VAS	7 (2.8)	5 (2)	0 (0)	0 (0)
Skin burns	6 (2.4)	3 (1.2)	0 (0)	0 (0)
Subcutaneous haematoma	5 (2)	0 (0)	0 (0)	0 (0)
Upper extremity paraesthesia	0 (0)	0 (0)	0 (0)	0 (0)
Others	0 (0)	0 (0)	0 (0)	0 (0)
Duration of hospital stay				
1 day	174 (68.8)			
2 days	79 (31.2)			

Values are n (%) unless otherwise indicated. VAS, visual analogue scale.

Table 3 Pathological characteristics

Variable	n
Benign	241 (95.3)
Follicular adenoma	108 (42.7)
Nodular hyperplasia	96 (37.9)
Multinodular goitre	29 (11.5)
Other	8 (3.2)
Papillary carcinoma	9 (3.5)
pT1a	6 (2.4)
pT1b	2 (0.8)
pT2	1 (0.4)
Follicular carcinoma	3 (1.2)
pT1a	3 (1.2)

Values are n (%).

Table 4 Cosmetic results

Variable	n	Follow-up		
		2 weeks	3 months	12 months
Extremely satisfied	192 (75.9)	209 (82.6)	227 (89.7)	241 (95.3)
Satisfied	61 (24.1)	44 (17.4)	26 (10.3)	12 (4.7)
Acceptable	0 (0)	0 (0)	0 (0)	0 (0)
Dissatisfied	0 (0)	0 (0)	0 (0)	0 (0)
Extremely dissatisfied	0 (0)	0 (0)	0 (0)	0 (0)

Values are n (%).

Statistical analysis

Categorical variables were expressed as frequencies and percentages, and continuous variables as mean(s.d.) or median and interquartile range (i.q.r.) (25–75th percentile). The distribution of the variables was evaluated with Kolmogorov–

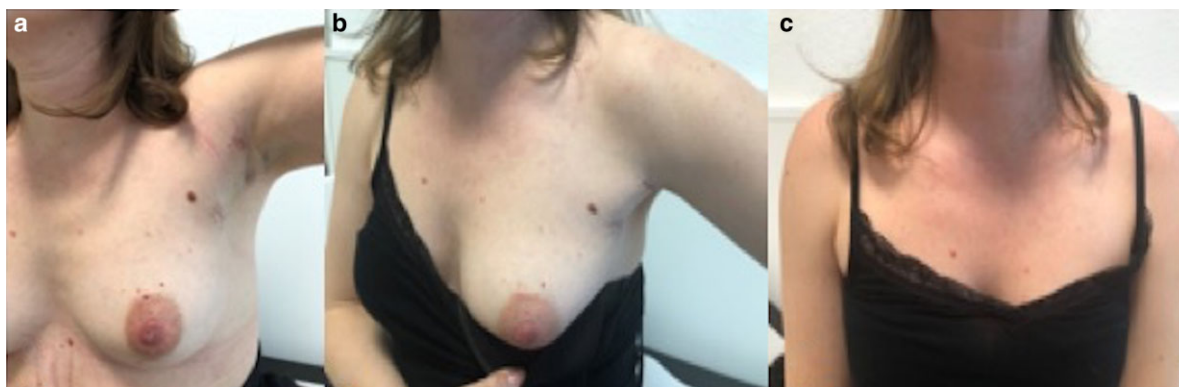


Fig. 4 Appearance of scars during follow-up

a Three months after surgery. **b** One year after surgery. **c** External appearance.

Smirnov test. Data were evaluated with SPSS® for Windows version 21.0 (IBM, Armonk, New York, USA).

Results

A total of 984 lobectomies were performed in the three centres during the study interval. Overall, 253 (25.7 per cent) patients were selected to undergo endoscopic hemithyroidectomy via UABA with gas insufflation (Fig. 3). The mean age of these 253 patients at surgery was 46.6 (range 21–71) years, and 214 (84.6 per cent) patients were women. Thyroid nodule mean size was 29.6 (range 14–48) mm and the right thyroid lobe was affected in 55.3 per cent of patients (Table 1).

Surgical outcomes are present in Table 2. Mean(s.d.) total surgical time was 72.9(12.8) min, with a mean(s.d.) subcutaneous dissection time of 27.5(5.8)mm. There was no intraoperative bleeding or inadvertent injury to adjacent structures, including the trachea and the oesophagus. Recurrent laryngeal nerve was identified in all patients. Conversion to open surgery was not necessary for any procedure. Minor postoperative complications occurred in 27.5 per cent (65) of patients, such as subcutaneous emphysema or pectoral/cervical hypoesthesia, which resolved spontaneously by the evaluation of the second postoperative week and the third month after surgery respectively. Major immediate complications were present in 17 (6.7 per cent) patients. Nine patients (3.6 per cent) experienced transient unilateral recurrent laryngeal nerve palsy, seven (2.8 per cent) pain of 3 or higher on the VAS, six (2.4 per cent) skin burns, and five (2 per cent) subcutaneous hematoma. At the third month after surgery, all these complications were resolved, except for six (2.4 per cent) patients with dysphonia who normalized by fourth month. There was no postoperative bleeding, seroma formation or permanent recurrent laryngeal nerve paralysis. No reoperation was necessary in any patient. Duration of hospital stay after surgery was 1 day in 174 patients (68.8 per cent) and 2 days in 79 (31.2 per cent) (Table 2). Surgical drains were removed in 84.2 per cent (213 of 253) and 15.8 per cent (40 of 253) of patients, 1 day and 2 days after surgery respectively.

Postoperative pathological results are given in Table 3. Pathological examinations revealed 241 (95.3 per cent) benign lesions, nine (3.5 per cent) papillary carcinomas, and three (1.2 per cent) follicular carcinomas. The subsequent treatment for these 12 patients with definitive pathology of differentiated thyroid carcinoma was open contralateral hemithyroidectomy to complete the total thyroidectomy, formally re-explore the operated side and perform prophylactic sentinel node biopsy with subsequent administration

of radioactive iodine, as recommended by the European Society for Medical Oncology (ESMO) Guidelines¹⁸. Satisfaction with cosmetic results is summarized in Table 4. No scar contracture or internal scarring was reported. All 253 patients were either satisfied or extremely satisfied with their cosmetic results (Fig. 4).

Discussion

This is a large multicentre European cohort study evaluating a minimally invasive endoscopic approach for thyroidectomy, specifically the UABA approach with gas insufflation^{7–9}. This approach is an accepted endoscopic techniques for removal of the thyroid gland^{7,8,10,12}. Studies from South Korea and Vietnam have shown that UABA with gas insufflation can be performed safely^{10,12,13,15}; however, there are several factors limiting its widespread applicability, particularly the countries of America and Europe, such as differences in patient characteristics (such as obesity), advanced surgical skills in endocrine and minimally invasive surgery (learning curve), and most importantly, the need to confirm the surgical outcomes in relation to the conventional open cervical approach^{2,8,9}.

Minimally invasive endoscopic approaches for thyroidectomy are technically demanding procedures that require experience in conventional thyroid surgery, laparoscopic and endoscopic procedures, as prerequisites for safe introduction^{7,8}; however, UABA with gas insufflation for thyroidectomy was developed to overcome some of technical difficulties encountered in other endoscopic approaches¹³. The axillo-bilateral breast approach (ABBA), UABA without gas insufflation and BABA were described before UABA with gas insufflation but, their invasiveness due to an extensive skin flap dissection to create the operative field poses significant drawbacks regarding seroma formation, postoperative pain and skin sensory loss^{13,20,21}. Lee was the first author who described and assessed the feasibility and outcomes of UABA with gas insufflation¹³. Trocar position in this approach allows the surgeon to manipulate the instruments easily and safely, with incision placement in invisible sites (axillar and circumareolar areas) and, with a minimal dissection area, as working space is on the thyroid lesion side^{13,19}. In addition, the lateral view of the thyroid gland, similar to the open approach, confers comfort to the surgical team¹⁹. These characteristics could be the reason for shorter operating times and lower morbidity with UABA with gas insufflation compared with other endoscopic approaches^{10,13,19}.

In the present study, conversion to open surgery was not necessary in any case and intraoperative bleeding was less than

10 ml for all patients, which is significantly less than in other types of endoscopic approaches and in open surgery^{11,15,22–24}. The mean(s.d.) total operating time required for hemithyroidectomy was 72.9(12.8) minutes, similar to the conventional open approach and shorter than other endoscopic techniques in previously published reports^{11,15,22–24}. Studies show that the duration of surgery via the UABA approach for hemithyroidectomy is generally the same as for open surgery, MIVAT, and endoscopic procedures via the breast approach, and shorter than for endoscopic procedures via the axillary approach^{11,15,22–24}. A previous author reported mean(s.d.) operating times for hemithyroidectomies of 119.23(31.47) minutes, whereas another experience reported a mean(s.d.) operating time of 165.3(43.5) minutes^{15,22}. The limited flap elevation could be the reason for the shorter mean operating time^{10,16}.

Total minor complications were present in 25.7 per cent of patients, predominantly pectoral and cervical hypoesthesia (22.5 per cent and 15.4 per cent of the patients respectively). This sensory disturbance recovered in all affected patients by the third month after surgery. In addition, the most frequent major complication was transient vocal cord paralysis in 3.6 per cent of the cases. The recurrent laryngeal nerve was identified and preserved in all patients; therefore, the transient vocal cord paralysis was probably caused by an injury during dissection between the recurrent laryngeal nerve and thyroid gland; however, this incidence is even slightly lower than for some open thyroidectomy series, and it could be due to better visualization and gentle manipulation of the thyroid gland and recurrent laryngeal nerve in endoscopic procedures. In this cohort, the vast majority of the patients, reported very mild or mild pain. Even if few patients reported moderate pain in the days immediately and at 2 weeks after surgery, the VAS scores here reported were slightly lower than those reported in a study of UABA without gas insufflation in which 48.3 per cent of patients complained of moderate or severe neck pain, and are consistent with previous reports of UABA with gas insufflation^{10,13,15}. This difference could be associated with the limited flap elevation and the absence of the long vertical axillary incision present in other endoscopic approaches.

In the present study too, there was no seroma formation in more than 80 per cent of the cases with surgical drain removal in all patients on the first and second day after the procedure. One author reported a 2.9 per cent seroma rate, whereas this complication was reported up to 9.6 per cent in another series of UABA without gas insufflation^{13,15}. Extensive subcutaneous dissection for flap creation is related to seroma development, which could explain the low rate after UABA with gas insufflation. Furthermore, complications related to carbon dioxide insufflation, such as gas embolism or alteration of any anaesthetic intraoperative ventilatory parameter requiring conversion to open surgery, were absent in this study, consistent with previous experiences^{10,13}. The common feature in all these studies is the recommended low pressure of endoscopic carbon dioxide insufflation (5–8 mmHg) during the procedure. In addition, the mean duration of hospital stay was similar or slightly lower than previous reports for open and endoscopic thyroidectomy series^{10,11,13,15,22–25}.

Thyroid nodules are found mainly in young women¹. A past study focusing on cosmetic issues, reported that the quality of life (QoL) of patients with keloid and hypertrophic neck scars is impaired as much as in patients with psoriasis²⁶. Patients interviewed for the purpose of the present investigation were also satisfied with the scare appearance 1 year after surgery;

however, prospective studies on QoL of thyroidectomized patients via UABA with gas insufflation are warranted.

This study has, however, a few limitations as the patient selection criteria were restrictive to evaluate the surgical outcomes in the subgroup of patients who could obtain the greatest benefit from UABA with gas insufflation for hemithyroidectomy: patients with thyroid unilateral less than 5 cm, benign or indeterminate thyroid surgical disease, and a demand for excellent cosmetic results; however, the evaluation of patients with other surgical indications such as total thyroidectomy or diagnosed cancer was beyond the aims of this report. In addition, UABA with gas insufflation approach for thyroidectomy minimizes the size and visibility of skin scars by hiding them in the axilla, which is completely covered by the patient arm; however, this approach still leaves skin scars such as the circumareolar scar. For this reason, the development of the transoral techniques as the sublingual, periosteal or oral vestibular approach (TOETVA), in which it is demonstrated that sublingual and periosteal approaches cause severe tissue damage as well as high complications^{27,28}. Recently, excellent promising cosmetic results and low complication rates after TOETVA were reported²³. Since then, international experience and evidence on safety and efficacy have been accumulating with advantage in bilateral surgical thyroid disease, as it provided the operative view and workspace for total thyroidectomy and central compartment neck dissection^{11,23,29,30}; however, TOETVA still has controversies, as a complex technique (inverted visual anatomical view, reduced distance between endoscopic instrument in an already small surgical space) with previously reported associated serious complications (tracheal or oesophageal perforation and surgical site infection), in contrast with open or other endoscopic approaches such as UABA^{11,31}. TOETVA and UABA with gas insufflation were also compared¹². The authors concluded that these two techniques had comparable surgical results, including blood loss, duration of hospital stay, and that both were safe treatment options, as well as gave high cosmetic satisfaction¹²; however, UABA had a significantly shorter operating time, no seroma formation, and a tendency towards less paraesthesia and haematoma formation although with no significant differences¹². Perhaps, both techniques could represent valid options in the treatment of surgical thyroid disease; however, the results here reported suggest that in selected patients and with experienced teams of minimally invasive endocrine surgery, UABA with gas insufflation for hemithyroidectomy could be a safe option for the treatment of unilateral thyroid pathologies.

Funding

No direct or indirect financial support by extramural sources was received.

Disclosure

D.S.-P., M.M., P.D., J.V., J.J., M.A.L.-B., R.R. and O.V. declare no conflicts of interest.

Data availability

The data generated and analysed during this study are available from the corresponding author on reasonable request.

References

- Durante C, Grani G, Lamartina L, Filetti S, Mandel SJ, Cooper DS. The diagnosis and management of thyroid nodules: a review. *JAMA* 2018;**319**:919–924
- Berber E, Bernet V, Fahey TJ 3rd, Kebebew E, Shaha A, Stack BC Jr, et al. American thyroid association statement on remote-access thyroid surgery. *Thyroid* 2016;**26**:331–337
- Dordea M, Aspinall S. Short and long-term cosmesis of cervical thyroidectomy scars. *Ann R Coll Surg Engl* 2016;**98**:11
- Choi Y, Lee JH, Kim YH, Lee YS, Chang H-S, Park CS et al. Impact of postthyroidectomy scar on the quality of life of thyroid cancer patients. *Ann Dermatol* 2014;**26**:693
- Best AR, Shipchandler TZ, Cordes SR. Midcervical scar satisfaction in thyroidectomy patients. *Laryngoscope* 2017;**127**:1247–1252
- Arora A, Swords C, Garas G, Chaidas K, Prichard A, Budge J, et al. The perception of scar cosmesis following thyroid and parathyroid surgery: a prospective cohort study. *Int J Surg* 2016;**25**:38–43
- Tae K, Ji YB, Song CM, Ryu J. Robotic and endoscopic thyroid surgery: evolution and advances. *Clin Exp Otorhinolaryngol* 2019;**12**:1–11
- Vidal O, Saavedra-Perez D, Vilaça J, Pantoja JP, Delgado-Oliver E, Lopez-Boado MA, et al. Minimally-invasive endocrine neck surgery. *Cirugía Española (English Edition)* 2019;**97**:305–313
- Vidal Ó, Saavedra-Perez D. Remote-access thyroid surgery: controversies. *Cirugía Espanola* 2020;**98**:1–3
- Nguyen XH, Nguyen XH, Mai TKN, Nguyen TTN, Tran NL, Le VQ. Feasibility and safety of endoscopic thyroidectomy via a unilateral axillobreast approach for unilateral benign thyroid tumor in Vietnam. *Surg Laparosc Endosc Percutan Tech* 2019;**29**:447–450
- Fernandez Ranvier G, Meknat A, Guevara DE, Llorente PM, Vidal Fortuny J, Sneider M, et al. International multi-institutional experience with the transoral endoscopic thyroidectomy vestibular approach. *J Laparoendosc Adv Surg Tech A* 2020;**30**:278–283
- Nguyen HX, Nguyen LT, Nguyen HV, Nguyen HX, Trinh HL, Nguyen TX, et al. Comparison of transoral thyroidectomy vestibular approach and unilateral axillobreast approach for endoscopic thyroidectomy: a prospective cohort study. *J Laparoendosc Adv Surg Tech A* 2021;**31**:11–17
- Lee M-C, Mo J-A, Joon Choi I, Lee B-C, Lee G-H. New endoscopic thyroidectomy via a unilateral axillo-breast approach with gas insufflation: preliminary report. *Head Neck* 2013;**35**:471–476
- Choe J-H, Kim SW, Chung K-W, Park KS, Han W, Noh D-Y, et al. Endoscopic thyroidectomy using a new bilateral axillo-breast approach. *World J Surg* 2007;**31**:601–606
- Koh YW, Kim JW, Lee SW, Choi EC. Endoscopic thyroidectomy via a unilateral axillo-breast approach without gas insufflation for unilateral benign thyroid lesions. *Surg Endosc* 2009;**23**:2053–2060
- Lee M-C, Mo J-A, Joon Choi I, Lee B-C, Lee G-H. New endoscopic thyroidectomy via a unilateral axillo-breast approach with gas insufflation: preliminary report. *Head Neck* 2013;**35**:471–476
- von Elm E, Altman DG, Egger M, Pocock SJ, Gøtzsche PC, Vandenbroucke JP. The Strengthening the Reporting of Observational Studies in Epidemiology (STROBE) statement: guidelines for reporting observational studies. *J Clin Epidemiol* 2008;**61**:344–349
- Filetti S, Durante C, Hartl D, Leboulleux S, Locati LD, Newbold K, et al. Thyroid cancer: ESMO clinical practice guidelines for diagnosis, treatment and follow-up. *Ann Oncol Off J Eur Soc Med Oncol* 2019;**30**:1856–1883
- Vidal O, Delgado-Oliver E, Pino V, Vilaça J. Tiroidectomía endoscópica transaxilar: un abordaje más que ofrecer a nuestros pacientes. *Cirugía Española* 2018;**96**:586
- Fan Y, Wu S-D, Kong J. Single-port access transaxillary totally endoscopic thyroidectomy: a new approach for minimally invasive thyroid operation. *J Laparoendosc Adv Surg Tech A* 2011;**21**:243–247
- Duh QY. Robot-assisted endoscopic thyroidectomy: has the time come to abandon neck incisions? *Ann Surg* 2011;**253**:1067–1068
- Shimazu K, Shiba E, Tamaki Y, Takiguchi S, Taniguchi E, Ohashi S, et al. Endoscopic thyroid surgery through the axillo-bilateral-breast approach. *Surg Laparosc Endosc Percutan Tech* 2003;**13**:196–201
- Anuwong A, Ketwong K, Jitpratoom P, Sasanakietkul T, Duh Q-Y. Safety and outcomes of the transoral endoscopic thyroidectomy vestibular approach. *JAMA Surg* 2018;**153**:21
- Park KN, Jung C-H, Mok JO, Kwak JJ, Lee SW. Prospective comparative study of endoscopic via unilateral axillobreast approach versus open conventional total thyroidectomy in patients with papillary thyroid carcinoma. *Surg Endosc* 2015;**30**:3797–3801
- Vidal O, Saavedra-Perez D, Valentini M, Astudillo E, Fernández-Cruz L, García-Valdecasas JC. Surgical outcomes of total thyroidectomy using the LigaSure™ Small Jaw versus LigaSure Precise™: a retrospective study of 2000 consecutive patients. *Int J Surg* 2017;**37**:8–12
- Balci DD, Inandı T, Dogramaci CA, Celik E. DLQI scores in patients with keloids and hypertrophic scars: a prospective case control study. *JDDG J der Dtsch Dermatologischen Gesellschaft* 2009;**7**:688–691
- Benhidjeb T, Witzel K, Stark M, Mann O. Transoral thyroid and parathyroid surgery: still experimental! *Surg Endosc* 2011;**25**:2411–2413
- Lee HY, You JY, Woo SU, Son GS, Lee JB, Bae JW, et al. Transoral periosteal thyroidectomy: cadaver to human. *Surg Endosc* 2014;**29**:898–904
- Jitpratoom P, Ketwong K, Sasanakietkul T, Anuwong A. Transoral endoscopic thyroidectomy vestibular approach (TOETVA) for Graves' disease: a comparison of surgical results with open thyroidectomy. *Gland Surg* 2016;**5**:546–552
- Sun H, Zheng H, Wang X, Zeng Q, Wang P, Wang Y. Comparison of transoral endoscopic thyroidectomy vestibular approach, total endoscopic thyroidectomy via areola approach, and conventional open thyroidectomy: a retrospective analysis of safety, trauma, and feasibility of central neck dissection in the treatment of papillary thyroid carcinoma. *Surg Endosc* 2019;**34**:268–274
- Menderico GM, Weissenberg AL, Borba CM, Sallani GM, Poy JO. Complications of transoral endoscopic thyroidectomy vestibular approach (TOETVA). *Rev Col Bras Cir* 2021;**48**:1–7