

# Pelvic Fistulas Complicating Pelvic Surgery or Diseases: Spectrum of Imaging Findings

Sung Gyu Moon, MD  
Seung Hyup Kim, MD  
Hak Jong Lee, MD  
Min Hoan Moon, MD  
Jae Sung Myung, MD

Pelvic fistulas may result from obstetric complications, inflammatory bowel disease, pelvic malignancy, pelvic radiation therapy, pelvic surgery, or other traumatic causes, and their symptoms may be distressing. In our experience, various types of pelvic fistulas are identified after pelvic disease or pelvic surgery. Because of its close proximity, the majority of such fistulas occur in the pelvic cavity and include the vesicovaginal, vesicouterine, vesicoenteric, ureterovaginal, ureteroenteric and enterovaginal type. The purpose of this article is to illustrate the spectrum of imaging features of pelvic fistulas.

## Index terms :

Fistula, pelvic  
Ureteroenteric, enterovaginal  
Vesicovaginal, vesicouterine,  
Vesicoenteric, ureterovaginal,

## *Korean J Radiol 2001;2:97-104*

Received October 27, 2000; accepted  
after revision February 7, 2001.

All authors: Department of Radiology,  
Seoul National University College of  
Medicine, The Institute of Radiation  
Medicine, SNUMRC (Seoul National  
University Medical Research Center), and  
The Clinical Research Institute, Seoul  
National University Hospital.

## Address reprint requests to:

Seung Hyup Kim, MD, Department of  
Radiology and the Institute of Radiation  
Medicine, Seoul National University  
College of Medicine, 28 Yongon-dong,  
Chongno-gu, Seoul 110-744, Korea.  
Telephone: (822) 760-2584  
Fax: (822) 743-6385  
e-mail: kimsh@radcom.snu.ac.kr

**T**he etiology of intrapelvic fistulas may be related to obstetrical complications, pelvic malignancy, radiation therapy, inflammatory bowel disease, or iatrogenic or traumatic causes (1, 2). The symptoms of fistulization are dramatic and disconcerting to the patient. Although a history of passing urine, feces, or foul smelling air or discharge through an unfamiliar orifice usually indicates the presence of an intrapelvic fistula, actual demonstration of the fistulous tract and identification of its underlying cause is quite difficult.

A variety of examinations and radiographic studies have attempted to identify fistulous communications. Intravenous urography, cystography, barium enema, vaginography or colpography may demonstrate the presence of contrast medium outside the appropriate organs, but the fistulous tract frequently fails to fill, in part because many fistulas are small, tortuous and obliquely oriented (1). Some authors have claimed that ultrasonography (US) is a valuable alternative noninvasive study for the diagnosis of fistula. It has been reported that the modality is able to visualize vesicouterine fistulas, permitting correct diagnosis and obviating the need for further examination (3, 4). Computed tomography (CT) has proved superior in detecting a fistulous tract, and it also provides additional information regarding the etiology of the fistula and the extent of extraluminal disease. Such information has important implications for patient management and is particularly useful when planning surgical repair. Magnetic resonance imaging (MRI) may also be useful in the evaluation of fistulas (5), but its usefulness is limited by artifacts secondary to physiological motion, such as respiration, cardiac pulsation and bowel peristalsis, which commonly lead to image degradation. It has been reported that rapid, heavily T2-weighted MR imaging was successfully utilized in the diagnosis of an occult vesicouterine fistula (6). Various types of intrapelvic fistulas are identified after pelvic disease or pelvic surgery. Because of its close proximity, the majority of such fistulas occur in the pelvic cavity and include the vesicovaginal, vesicouterine, vesicoenteric, ureterovaginal, ureteroenteric and enterovaginal type. The purpose of this article is to illustrate and discuss the imaging features of various types of intrapelvic fistulous communication.

### Vesicovaginal Fistulas

Vesicovaginal fistulas occur mostly after pelvic irradiation or following gynecologic surgery with or without irradiation. Their most frequent predisposing factor in patients with gynecological malignancy is cervical cancer treated with irradiation therapy, and they are reported to develop in 1-10% of such patients (1).

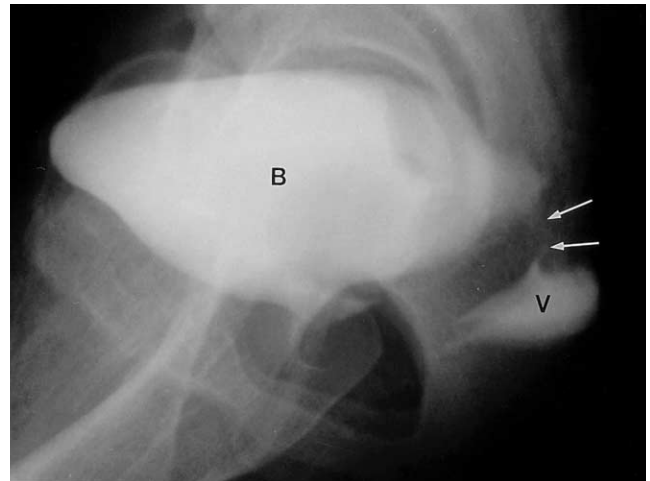
Patients with vesicovaginal fistulas usually present with typical symptoms, in particular, urinary leakage through the vagina, menouria and perineal dermatitis. Even so, demonstration of the fistulous tract and its cause using conventional modalities such as intravenous urography and cystography is often difficult, and the supplementary use of vaginography, colpography, CT or MRI has been advocated (Figs. 1, 2).

Post-irradiation vesicovaginal fistulas are often accompanied by rectovaginal or ileovaginal fistulas. Rectovaginal fistulas following irradiation or the presence of a neoplasm can be asymptomatic, but the fistula is usually palpable or demonstrated by vaginal cytology (5) (Fig. 3).

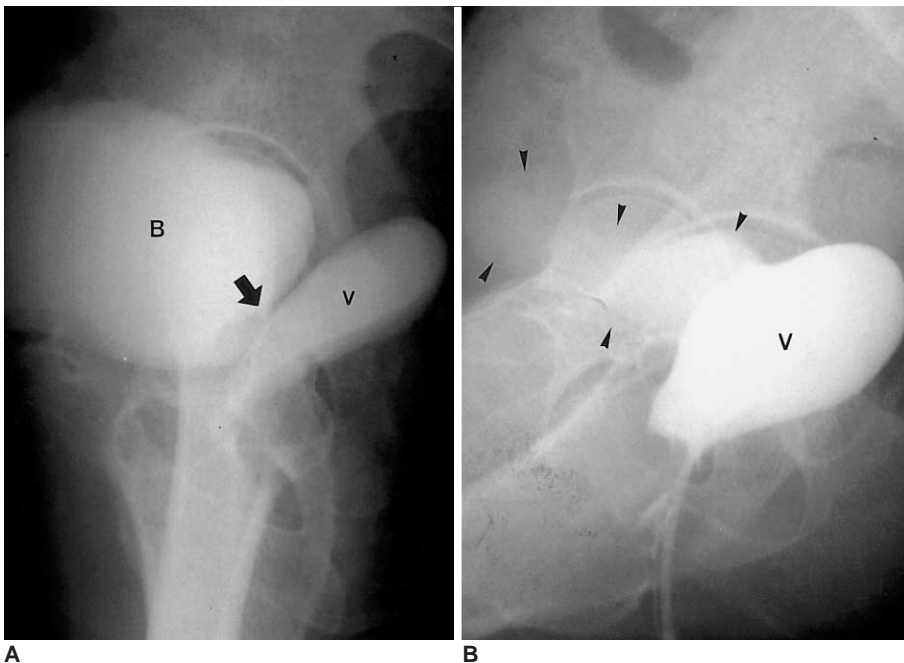
### Vesicouterine Fistulas

Vesicouterine fistulas occur under various conditions, including cesarean section, forceps-aided delivery, external cephalic version, curettage for manual removal of the placenta, myoma adherent to the bladder, and perforation of an intrauterine device. Cesarean section is currently the single most common cause of vesicouterine fistula, and re-

peated incisions of this kind increase the risk of bladder injury and resultant fistulas (3). Vesicouterine fistulas usually occur after lower-segment cesarean section. Bladder injury during the procedure may arise as a result of blunt or sharp dissection between the bladder wall and lower uterine segment, or the inclusion of the bladder wall in sutures placed when closing the lower uterine segment (7). The main symptom of a vesicouterine fistula is urinary incontinence; others are cyclic hematuria (menouria), amenorrhea, and urinary tract infection. The combination of a history of cesarean section, amenorrhea, and cyclic hematuria without



**Fig. 2.** Vesicovaginal fistula in a patient who underwent hysterectomy one month earlier due to uterine myoma. Cystogram shows contrast leakage from the urinary bladder into the vagina (B, bladder; V, vagina; arrows, fistula).



**Fig. 1.** Vesicovaginal fistula in a patient who underwent hysterectomy due to cervical cancer.

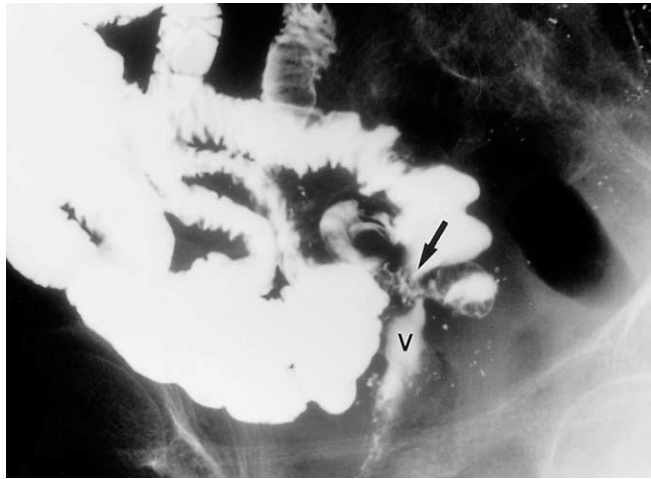
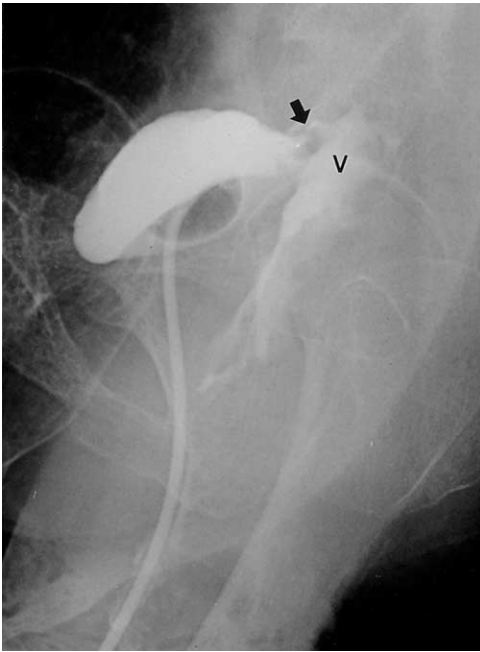**A.** Cystogram demonstrates the presence of a short fistulous tract (arrow) between the bladder neck and vaginal stump.  
**B.** Vaginogram reveals sac-forming vagina and contrast leakage into the bladder (arrowheads) (B, bladder; V, vagina).

### Imaging Findings of Pelvic Fistulas Complicating Pelvic Surgery or Diseases

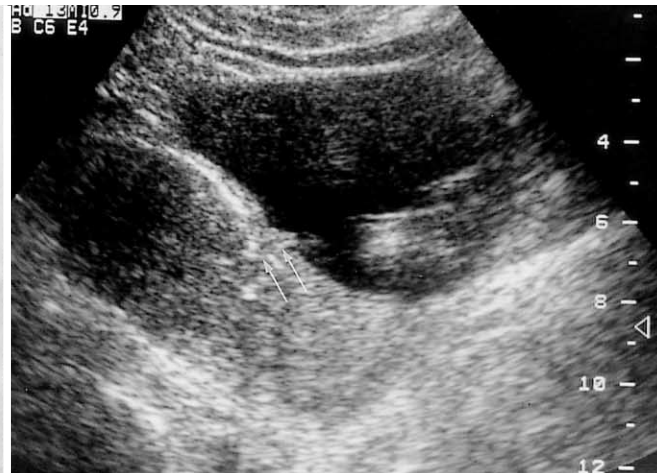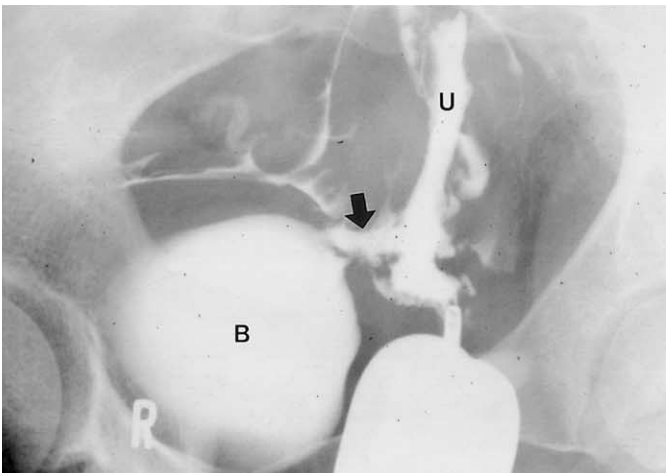
urinary incontinence has been described as pathognomic of a vesicouterine fistula. Because a functional sphincter is present at the internal uterine orifice, the presence or absence of urinary incontinence is related to the level of injury. If the level of the vesicouterine fistula is below the internal os, urinary incontinence results (3, 6).

Radiographically, both cystography and hystero-graphy have been successfully used to demonstrate the presence of vesicouterine fistulas. In his review of published reports, Tancer found that hystero-graphy was the most reliable di-

agnostic technique (7). Intravenous urography has been reported to demonstrate contrast medium entering the vagina but found to be of no value in distinguishing vesicovaginal and vesicouterine fistulas (8). Although fistulas are difficult to diagnose sonographically, the literature contains several reports on their ultrasonographic diagnosis. Park et al. reported that sonography can demonstrate the fistulous tract as double echogenic lines between the endometrium of the anterior wall of the uterine body and the mucosal layer of the posterior wall of the bladder (3) (Figs. 4, 5).



**Fig. 3.** Vesicovaginoileal fistulas in a patient with recurrent cervical cancer who underwent hysterectomy and irradiation (arrow).  
**A.** Cystogram shows contrast leakage from the urinary bladder into the vaginal stump.  
**B.** Small bowel series indicates irregular fistulous communication (arrow) between the distal ileum and vaginal stump (V, vagina).

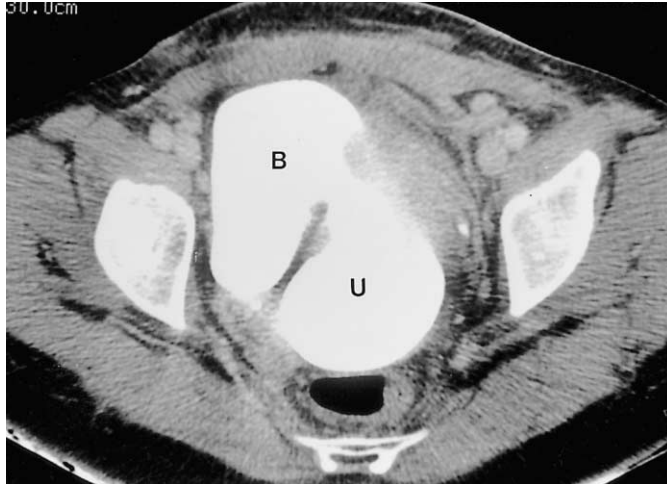
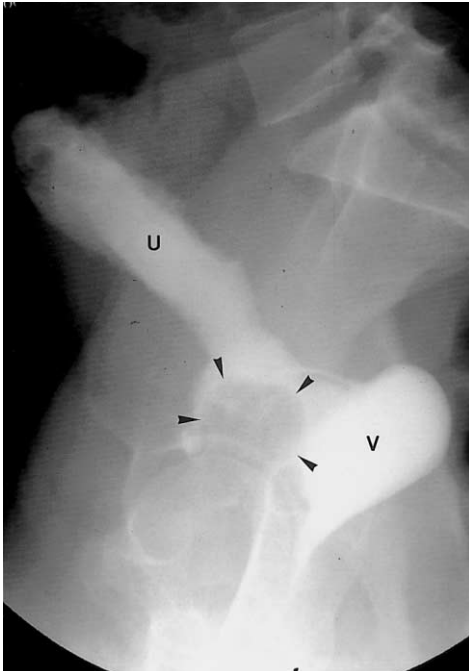


**Fig. 4.** Vesicouterine fistula in a patient with urinary incontinence after a cesarean section.  
**A.** Hysterosalpingogram shows a fistulous tract (arrow) and contrast leakage from the uterine cavity into the bladder.  
**B.** Longitudinal ultrasonographic scan of the pelvis demonstrates hyperechoic line in continuity with the endometrium of the uterus and bladder (Reprinted, with permission, from reference 3) (B, bladder; U, uterus; arrows, fistula).

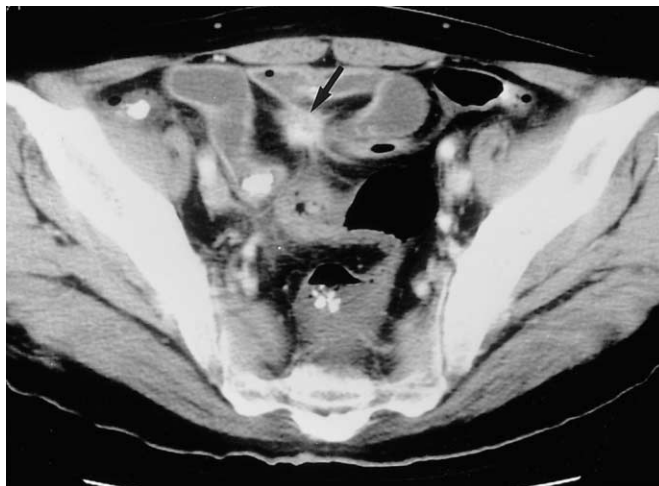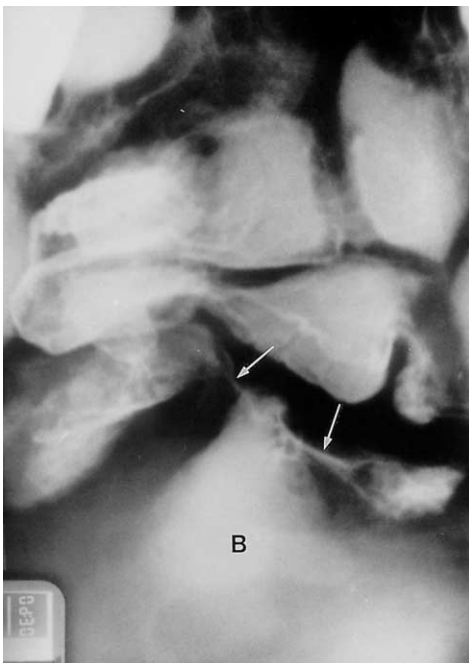
**Vesicoenteric Fistulas**

Colonic diverticulitis is the most common etiology of vesicoenteric fistula, while colorectal adenocarcinoma, Crohn's disease, Meckel's diverticulum, and bladder or urachal carcinoma are less common causes. Multiple fistula formation with mesenteric change is often characteristic of Crohn's

disease. Pneumaturia, abdominal pain and dysuria are the most common symptoms of vesicoenteric fistula, and cystography has proven to be more accurate than barium enema, upper gastrointestinal series and intravenous urography in demonstrating its presence. Other imaging techniques, though less effective for diagnosis, may be useful in assessing the status of the gastrointestinal tract and, at times, in

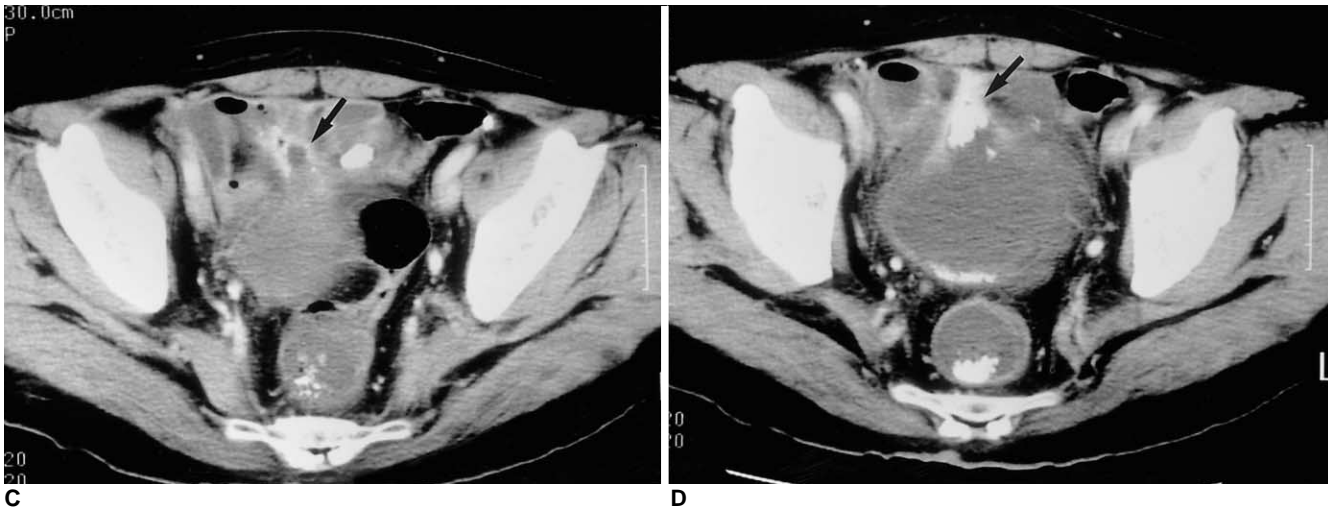

**B**  
**Fig. 5.** Vesicouterine fistula in a patient with urinary incontinence and hematuria after a cesarean section.  
**A.** Post-voiding cystogram shows air-balloon (arrowheads) of a Foley catheter in contracted bladder and contrast filling of the uterus and vagina via the vesicouterine fistulous tract.  
**B.** CT of the pelvis performed immediately after cystography shows extensive communication between the bladder and lower body of the uterus (B, bladder; U, uterus; V, vagina).

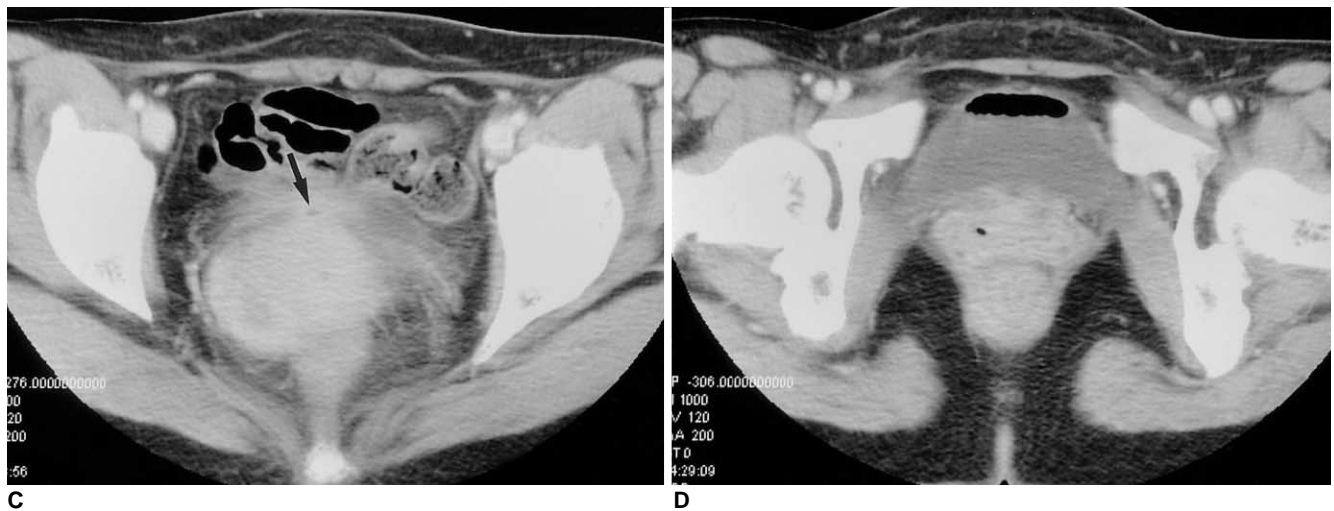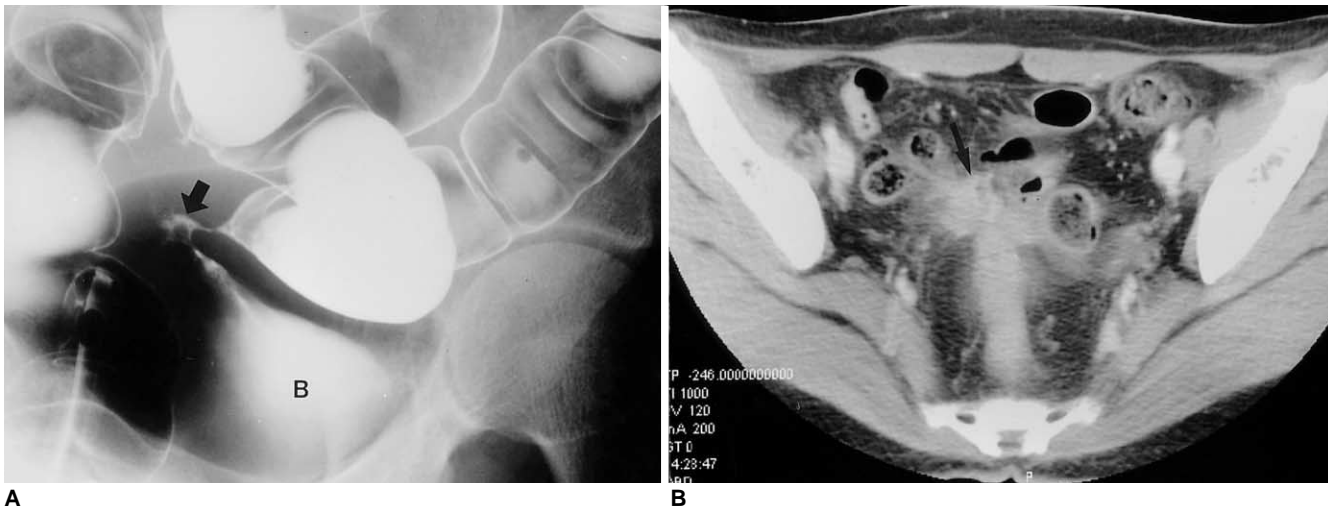


**B**  
**Fig. 6.** Vesicoileal fistula in a patient who had undergone irradiation on account of bladder cancer.  
**A.** Small bowel series shows two fistulous tracts (arrows) between the ileal loop and bladder.

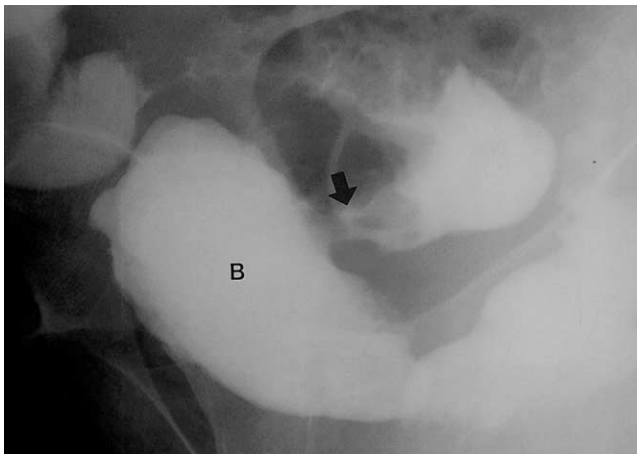
Imaging Findings of Pelvic Fistulas Complicating Pelvic Surgery or Diseases



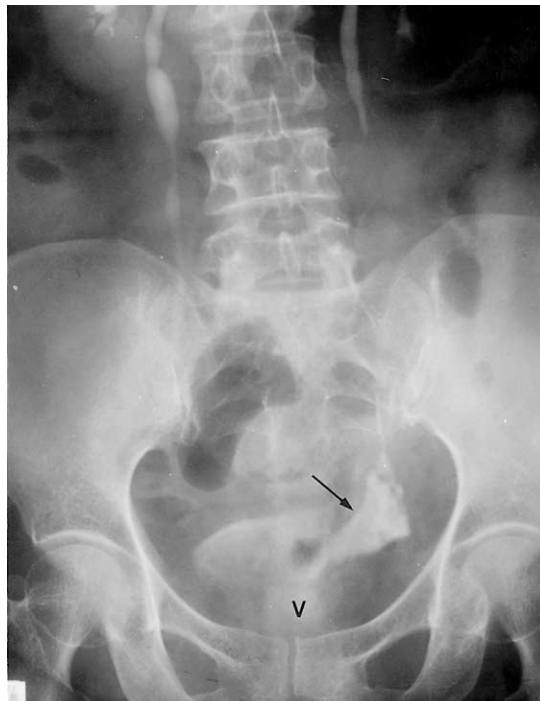**Fig. 6. B-D.** Serial CT sections obtained after a small bowel series reveal an irregular enhancing fistulous tract (arrow) and the retention of leaked contrast medium in the bladder (B, bladder).



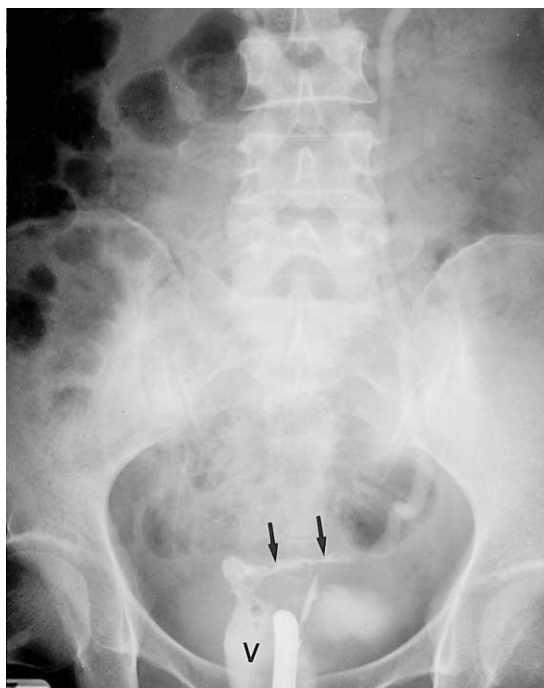
**Fig. 7.** Vesicocolic fistula in a patient with Crohn's disease.  
**A.** Colon study reveals four fistulous tracts between the rectosigmoid colon and bladder.  
**B-D.** Serial CT sections of the pelvis show irregular infiltration of the sigmoid mesocolon around the fistulous tracts and air collection in the bladder (B, bladder; arrow, fistula).



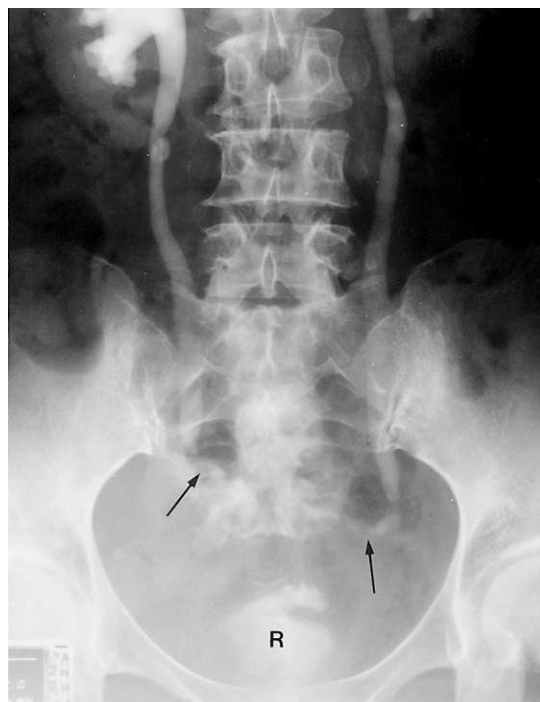
**Fig. 8.** Vesicocolic fistula in a patient who underwent palliative radiation therapy due to recurrent bladder cancer. Cystogram shows trabeculated bladder deformity and immediately opacified sigmoid colon. The presence of a fistulous tract between the bladder and sigmoid colon may be observed (B, bladder; arrow, fistula).



**Fig. 10.** Ureterovaginal fistula in a patient with watery vaginal discharge after hysterectomy due to cervical cancer. Intravenous urogram shows leakage of contrast medium from the left ureter, resulting in a triangular-shaped collection of contrast medium and continuous leakage of this through the vaginal canal (V, vagina; arrow, fistula).



**Fig. 9.** Ureterovaginal fistula in a patient who underwent hysterectomy due to uterine myoma. Retrograde urogram shows contrast leakage from the left ureter to the vagina (V, vagina; arrows, fistula).



**Fig. 11.** Ureterorectal fistula in a patient who underwent hysterectomy due to cervical cancer. Intravenous urogram shows bilateral hydronephrosis and the irregular leakage of contrast medium from the bilateral distal ureter to the rectum (R, rectum; arrows, fistula).

determining the etiology of these fistulas (9-11) (Figs. 6-8).

### Ureterovaginal and Ureteroenteric Fistulas

#### Ureterovaginal fistulas

Ureterovaginal fistulas are a serious sequela of unrecognized ureteral injuries. Obstetrical and gynecological operations are responsible for producing the majority of these fistulas and the risk of their occurrence has been found to be greater following radiation therapy. At presentation, a ureterovaginal fistula usually involves vaginal drainage of urine, concurrent with abdominal and flank pain, fever and paralytic ileus (12).

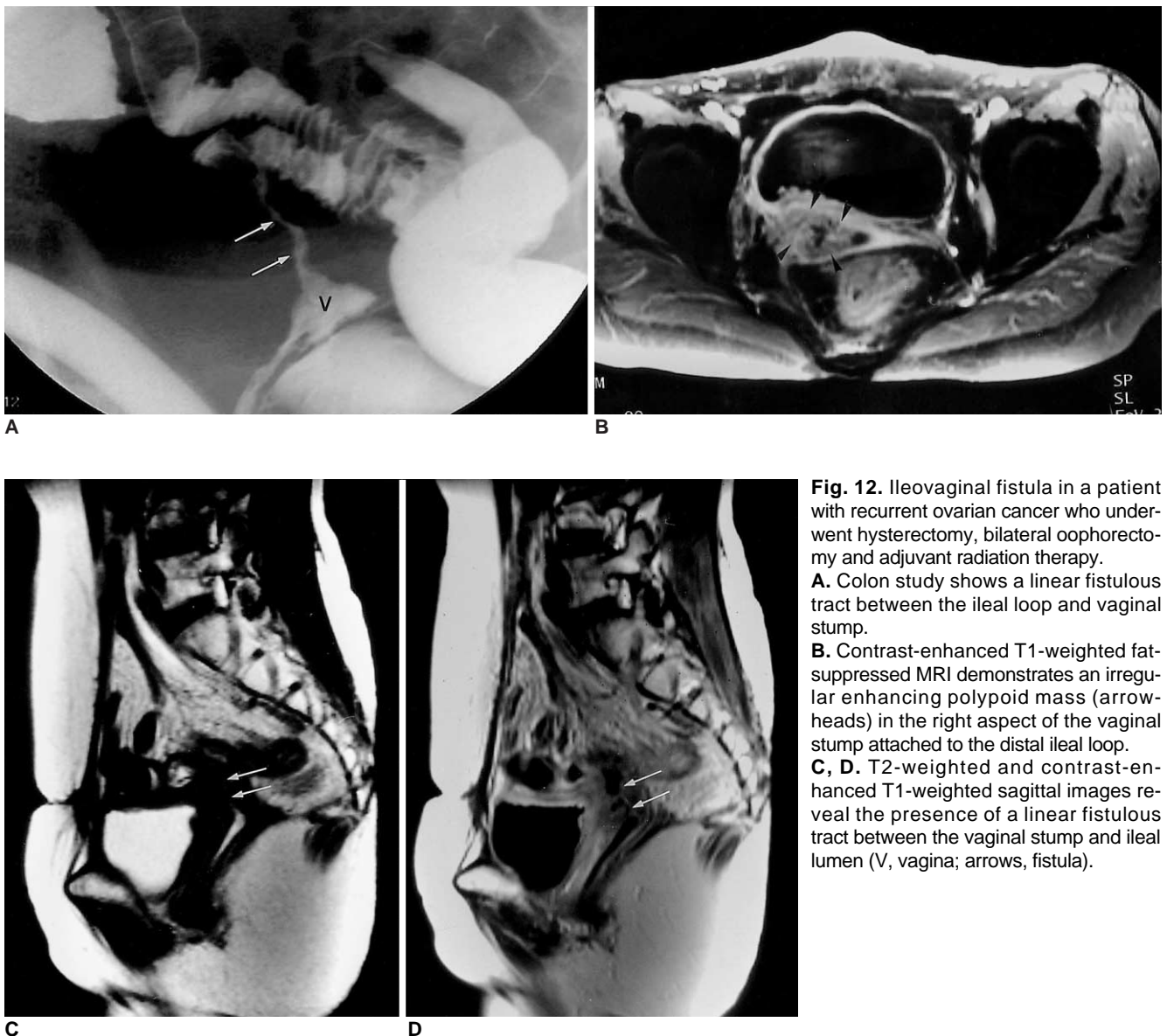
Intravenous urography may demonstrate hydronephrosis, while in some cases there is either a fistulous tract or contrast medium in the vagina. The pres-

ence of a vesicovaginal fistula can be ruled out by filling the bladder with a vital dye solution (Figs. 9, 10).

#### Ureteroenteric fistulas

Spontaneous ureteroenteric fistula is rare and usually caused by urinary calculi or, in some cases, by diverticular disease of the colon. In cases due to this latter cause, a fistula is typically not spontaneous, but related to surgical intervention. Other predisposing factors include Crohn's disease, colorectal malignancy, previous pelvic surgery or irradiation, and trauma (13). As in cases of vesicenteric fistula, patients with ureteroenteric fistula typically present with urologic symptoms, especially urinary tract infection, fecaluria, and abdominal or flank pain.

As has been noted in nephrocolic fistulas, mean pressure in the gastrointestinal tract is higher than in the urinary



**Fig. 12.** Ileovaginal fistula in a patient with recurrent ovarian cancer who underwent hysterectomy, bilateral oophorectomy and adjuvant radiation therapy.  
**A.** Colon study shows a linear fistulous tract between the ileal loop and vaginal stump.  
**B.** Contrast-enhanced T1-weighted fat-suppressed MRI demonstrates an irregular enhancing polypoid mass (arrowheads) in the right aspect of the vaginal stump attached to the distal ileal loop.  
**C, D.** T2-weighted and contrast-enhanced T1-weighted sagittal images reveal the presence of a linear fistulous tract between the vaginal stump and ileal lumen (V, vagina; arrows, fistula).

tract, and contrast medium thus tends to flow from the colon into the urinary system (14). For demonstration of this fistula, barium enema is therefore the most helpful diagnostic test. Some authors have claimed that the reported increase in this type of internal fistula could be caused by increases in lifespan and the established increase in the incidence of colonic diverticular disease with advancing age (11) (Fig. 11).

### Enterovaginal Fistulas

Enterovaginal fistula may result from obstetric complications, inflammatory bowel disease, pelvic malignancy, pelvic irradiation, pelvic surgery, or other traumatic causes. It may cause distressing symptoms, including vaginal discharge with vaginitis, continual leakage of flatus and feces through the vagina, severe skin excoriation, incontinence and dyspareunia. According to some reports, inflammatory bowel diseases account for 24-25% of all reported rectovaginal fistulas. The prevalence of radiation-induced rectovaginal fistula is relatively low; the risk of fistula formation after radiotherapy for carcinoma of the cervix depends on the dose and the method of application. Most rectovaginal fistulas develop at the lower one-third of the vagina and respond well to surgery. The location of radiation-induced rectovaginal fistulas is characteristically higher, however, and communication is from the posterior fornix of the vagina to the middle third of the rectum (15) (Fig. 12).

### References

1. Kuhlman JE, Fishman EK. CT evaluation of enterovaginal and

- vesicovaginal fistulas. *J Comput Assist Tomogr* 1990;14:390-394
2. Nagy V, Valansky L, Milichovsky I. Urologic complications of gynecologic surgery and their treatment in our clinical data. *Ceska Gynecol* 1998;63:192-195
3. Park BK, Kim SH, Cho JY, Sim JS, Seong CK. Vesicouterine fistula after cesarean section: ultrasonographic findings in two cases. *J Ultrasound Med* 1999;18:441-443
4. Adetiloye VA, FMCR, FWACS, et al. Obstetric Fistula: evaluation with ultrasonography. *J Ultrasound Med* 2000;19:243-249
5. Emmert C, Kohler U. Management of genital fistula in patients with cervical cancer. *Arch Gynecol Obstet* 1996;259:19-24
6. Murphy JM, Lee G, Sharma SD, Doble A, Lomas DJ. Vesicouterine fistula: MRI diagnosis. *Eur Radiol* 1999;9:1876-1878
7. Tancer ML. Vesicouterine fistula: a review. *Obstet Gynecol Surv* 1986;41:743-753
8. Iloabachie GC, Njoku O. Vesico-uterine fistula. *Br J Urol* 1985;57:438-439
9. Alapont Perez FM, Gil Salom M, Esclapez Valero JP, et al. Acquired enterovesical fistulas. *Arch Esp Urol* 1994;47:973-979
10. Hwang JC, Ha HK, Weon YC, et al. CT findings of enteric fistula. *J Korean Radiol Soc* 1997;37:1091-1096
11. Bennett JK, Trulock TS, Finnerty DP. Urachal adenocarcinoma presenting as vesicoenteric fistula. *Urology* 1985;25:297-299
12. Selzman AA, Patrick Spirnak J, Kursh ED. The changing management of ureterovaginal fistulas. *J Urol* 1995;153:626-628
13. Cirocco WC, Priolo SR, Golub RW. Spontaneous ureterocolic fistula; a rare complication of colonic diverticular disease. *Am Surg* 1994;60:832-835
14. Husted JW. An unusual case of pyelonephritis: Nephrocolic fistula owing to a ruptured colonic diverticulum. *J Urol* 1974;111:724-726
15. Lee BH, Choe DH, Lee JH, et al. Device for occlusion of rectovaginal fistula: clinical trials. *Radiology* 1997;203:65-69