

Advanced Cardiac MR Imaging for Myocardial Characterization and Quantification: T1 Mapping

Sung Ho Hwang, MD and Byoung Wook Choi, MD

Department of Radiology, Yonsei University College of Medicine, Seoul, Korea

Magnetic resonance as an imaging modality provides an excellent soft tissue differentiation, which is an ideal choice for cardiac imaging. Cardiac magnetic resonance (CMR) allows myocardial tissue characterization, as well as comprehensive evaluation of the structures. Although late gadolinium enhancement after injection of the gadolinium extracellular contrast agent has further extended our ability to characterize the myocardial tissue, it also has limitations in the quantification of enhanced myocardial tissue pathology, and the detection of diffuse myocardial disease, which is not easily recognized by enhancement contrast. Recently, the remarkable advances in CMR technique, such as T1 mapping, which can quantitatively evaluate myocardial status, showed potentials to overcome limitations of existing CMR sequences and to expand the application of CMR. This article will review the technical and clinical points to be considered in the practical use of pre- and post-contrast T1 mapping. (Korean Circ J 2013;43:1-6)

KEY WORDS: Magnetic resonance imaging; Myocardium; Gadolinium; Fibrosis; Myocardial infarction.

Introduction

In magnetic resonance imaging, the signal intensity is dependent on the relaxation of protons in the magnetic field.¹⁾ The relaxation of the hydrogen nucleus proton is divided into the T1 (spin-lattice relaxation) and T2 (spin-spin relaxation) time.¹⁾²⁾ Both T1 and T2 values are determined by the molecular status of the water molecules in the tissue, and consequently, characterize the specific pathologic status of the tissue. Acute myocardial ischemia usually accompanies with prolongation of T1 and T2 values because of unbound water molecules after release of water from intracellular proteins.³⁻⁵⁾ Intramyocardial hemorrhage induces oxidation of hemoglobin and produces methemoglobin after extravasation of red blood cells into the interstitium, which may cause T1 and T2 value fluctuation.⁶⁾

Specific cardiac magnetic resonance (CMR) imaging sequences as

Correspondence: Byoung Wook Choi, MD, Department of Cardiovascular Radiology, Severance Hospital, Yonsei University College of Medicine, 50 Yonsei-ro, Seodaemun-gu, Seoul 120-752, Korea
Tel: 82-2-2228-7400, Fax: 82-2-393-3035
E-mail: bchoi@yuhs.ac

• The authors have no financial conflicts of interest.

This is an Open Access article distributed under the terms of the Creative Commons Attribution Non-Commercial License (<http://creativecommons.org/licenses/by-nc/3.0>) which permits unrestricted non-commercial use, distribution, and reproduction in any medium, provided the original work is properly cited.

T1-weighted image with an administration of the gadolinium, an extracellular contrast agent, can be performed to characterize specific molecular environments within the target tissue. Distinction between environments surrounding myocardial tissue is further enhanced, depending on the amount of gadolinium, which reduces T1 values of adjacent tissue.⁷⁾⁸⁾ According to specific properties of different tissues, shortening of T1 after administration of the T1 contrast agent leads specific differences in T1-weighted signal intensity. Therefore, late gadolinium enhancement (LGE) CMR can provide a superior evaluation of myocardial tissue with an excellent tissue contrast and is a well-established technique to evaluate myocardium.²⁾⁷⁾⁸⁾

Although the qualitative evaluation of myocardium by existing CMR sequence has been a robust technique to characterize the myocardium, the relative signal intensity changes due to variation in CMR acquisition parameter may limit the evaluation of full spectrum of myocardial disease.⁹⁾¹⁰⁾ Up-to-date advance in MR techniques can allow a rapid quantitative assessment of T1 values, "T1 mapping" as a promising method to characterize the myocardium (Fig. 1). In addition, post-contrast T1 mapping with using of the gadolinium can quantify the myocardial extracellular volume fraction (ECV) correlated with histologic evidence of myocardial fibrosis.¹⁰⁻¹²⁾

To achieve the clinical prevalence of "T1 mapping" for myocardial assessment, however, it is essential to prescribe the cutoff between "normal" and "abnormal" in the delineation of myocardial disease through the understanding the principles of T1 mapping. So, the authors

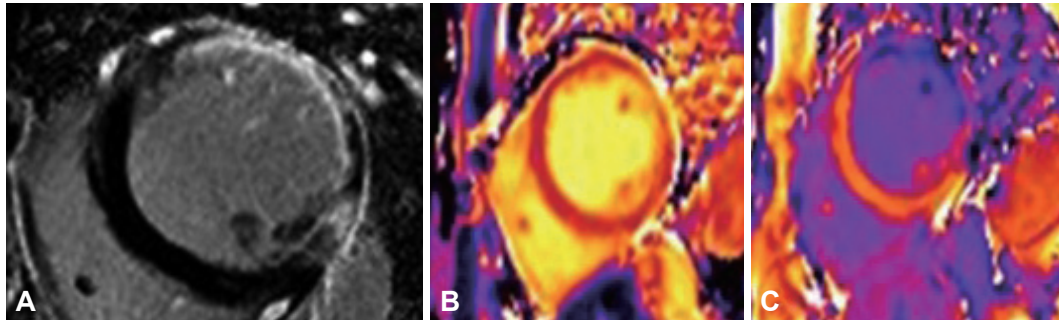


Fig. 1. Late gadolinium enhancement (LGE) (A), pre- and post-contrast (B and C) T1 map images using 3-T MR system in a patient with prior myocardial infarction in the lateral wall. LGE-MR image shows strong subendocardial enhancement and diffuse wall thinning from chronic infarction in the left anterior descending artery territory of the middle left ventricle level. Post-contrast T1 map image shows a marked T1 shortening in the peri-infarct region, which is not grossly enhanced on LGE image, when compared to the remote zone.

will present a variety of technical and clinical points to be considered for practical interpretation of pre- and post-contrast T1 mapping.

Rapid Sequence for T1 Mapping

T1 mapping is a parametric map, in which the individual voxel's intensity represents the T1 value of the corresponding voxel. T1 value of a certain tissue is defined as the specific time when the longitudinal magnetization of proton recovers approximately 63% of its equilibrium value. To obtain accurate T1 value from a curve-fitting procedure, measurements of at least 6 to 10 time points are required.¹³⁾ Because time constraints or misregistration effects from cardiac and respiratory motion are severe, T1 quantification for the myocardium has been considered a challenge.

To overcome the limitation of T1 mapping due to physiologic motion, Messroghli et al.¹⁴⁾ proposed a modified Look and Locker inversion recovery (MOLLI) sequence, which was based on two principles; 1) selective data acquisition at a given time of the cardiac cycle over successive heart beats, and 2) merging of the image sets from multiple Look and Locker experiments with three consecutive inversion times (TIs) into one data set. Within a breath-hold, multiple Look Locker experiments with different TIs allow multiple sampling from the data on the T1 relaxation curve of the myocardium. MOLLI sequence for T1 mapping uses a balanced steady-state free precession (SSFP) readout because SSFP has a higher signal to noise ratio (SNR) and less modulation of the relaxation curve.¹⁵⁾ Furthermore, to achieve motion-free images, the image acquisition period is narrowed to less than 200 msec in end-diastole phase of the cardiac cycle. Although MOLLI sequence can be affected by heart rate and has a tendency to underestimate the true cardiac T1 value, it provides fast and highly reproducible data for T1 mapping with excellent intra- and inter-observer agreement.¹⁶⁾

To achieve a faster acquisition speed over the MOLLI sequence, Piechnik et al.¹⁷⁾ presented a shortened MOLLI (ShMOLLI) sequence

as a MOLLI variant for T1 mapping, which could be performed with a short breath-hold during only nine cardiac beats. Compared to MOLLI sequence, ShMOLLI uses a similar TI scheme, but does not use fully recovered magnetization on the next sequential inversion pulse in a short breath-hold.¹⁷⁾ Messroghli et al.¹⁸⁾ also reported that T1 value accuracy from ShMOLLI is superior to that of MOLLI sequence. In addition, heart rate dependency is minimal in ShMOLLI sequence, which may contribute to higher accuracy. Although a shorter data sampling time may cause the *in vivo* noise penalty and slight reduction in precision, achieving fast imaging during single comfortable breath hold should be considered as an advantage to obtain the accurate and clinically acceptable T1 mapping with MOLLI sequence.¹¹⁾¹⁷⁾¹⁸⁾

MR Technical Factors for T1 Mapping

Although T1 mapping appears to be promising for myocardial characterization, its accuracy is affected by various confounding technical factors, including gadolinium characteristics and time delay of post-contrast T1 mapping after an administration of gadolinium, magnetic field strength, image acquisition phase in cardiac cycle (systolic phase and diastolic phase) and location.

Post-contrast T1 mapping

Although the gadolinium as extracellular contrast agent is not a specific marker, the distribution concentration and dynamic kinetics of contrast agent into extracellular space can be used to describe myocardial fibrosis, inflammation, and edema related to an increase in the extracellular volume. Therefore, some helpful patterns of late gadolinium enhancement have been identified in different myocardial diseases; therefore, LGE CMR is now routinely used as a first-line examination to evaluate the etiology of newly identified heart failure.¹⁹⁻²¹⁾

However, measurement of signal intensity of enhancement by LGE

is arbitrary and unsuitable for quantification in inter-individual comparison or longitudinal comparison in an individual. No universally accepted cut-off value of signal intensity has been reported to differentiate between normal and affected myocardium in the area of heterogeneity within the myocardial infarct periphery. In addition, the sensitivity of LGE is quite limited for detecting diffuse myocardial pathology because image contrast by LGE depends on the difference between normal and abnormal myocardium, and such difference may not be detected in the absence of normal myocardium if the myocardial disease involves diffusely.⁹⁾¹⁰⁾

In contrast with LGE, T1 mapping with MOLLI sequence directly measures the specific T1 value with a standardized scale. Although post-contrast T1 mapping with the gadolinium appears to be promising for myocardial assessment, its accuracy can be affected by various confounding characteristics of the gadolinium. The physical properties of gadolinium (dose, concentration, and water exchange rate) are all closely related to measuring an accurate T1 value of the myocardium. Because T1 value is exponentially correlated with the concentration of gadolinium, considering consistent wash-out of gadolinium from the myocardium after an administration of gadolinium, the waiting time for imaging acquisition is a significant parameter, changing the measured T1 value.¹⁶⁾ Therefore, in clinical practice of post-contrast T1 mapping, the acquisition time of T1 map image should be carefully monitored and considered for correction before further analyses.²²⁾

Extracellular volume fraction by post-contrast T1 mapping

To resolve the problem due to the dynamic kinetics of gadolinium in myocardium, the standardization to non-cardiac tissue or measurement of myocardial T1 value has been studied. Maceira et al.²³⁾ proposed a model for the correction of myocardial T1 value compared to the blood T1 value. ECV is another useful and stable index that is related to the myocardial interstitial status or fibrosis. It can be calculated with myocardial R1 (1/T1 value) change, blood R1 change, and hematocrit.¹⁰⁾²⁴⁾²⁵⁾ Ugander et al.¹⁰⁾ showed that ECV by pre- and post-T1 mapping could characterize and quantify infarcted myocardium, diffuse fibrosis, and mild myocardial abnormalities, which were not obvious on LGE images.

To achieve accurate ECV, equilibrium state of gadolinium between the blood and myocardium must be secured during imaging acquisition. Although gadolinium is continuously excreted via renal clearance, the ratio of contrast agent concentrations between myocardial tissue and plasma usually reach a dynamic equilibrium state over a certain period of time after contrast administration.²⁶⁾ Lee et al.¹¹⁾ suggested that the gadolinium concentration could achieve dynamic equilibrium between blood and myocardial tissue, as early as 8.5 minutes after injection of the gadolinium, and between 8.5 to

23.5 minutes, the ECV differences at 3.0T between consecutive time points were not significant.

Magnetic field strength for T1 mapping

In clinical practice, CMR imaging is performed typically with the use of 1.5T or 3.0T scanners. Although CMR imaging with 3.0T scanner has some obstacles to overcome, with recent technological developments²⁷⁾ 3.0T scanners are getting used more in cardiac imaging mainly for benefit of increased SNR.

At a given magnetic field strength, a tissue has a certain range for T1 value.¹⁾ When the same T1 mapping sequences are used, pre-contrast T1 value is longer at 3.0T than at 1.5T, which requires more time to fully recover. Kawel et al.¹²⁾ also reported that myocardial ECV is similar at field strengths of 1.5T and 3.0T. In contrast, Lee et al.¹¹⁾ showed that myocardial ECV of normal volunteers at 3.0T slightly higher than that at 1.5T because of an effect of relatively stronger shortening of the longer pre-contrast blood T1 at 3.0T, as compared to that at 1.5T.

Image acquisition phase and location of T1 mapping

Since the myocardium is thicker during systolic phase of the cardiac cycle and can be visualized with a good image quality, it may be advantageous to measure myocardial T1 value at systolic phase.¹²⁾ Myocardial T1 value and ECV vary significantly during a cardiac cycle depending on the changes in the myocardial blood volume.¹²⁾ In the left ventricular free wall of rat hearts, Judd and Levy²⁸⁾ demonstrated a decrease in myocardial blood volume by 42% from diastole to systole. Wansapura et al.²⁹⁾ described a decrease in T1 time from diastole to systole of 70% in the septum, and 43% in the lateral wall. Although myocardial blood volume changes significantly depending on the cardiac cycle, in the animal study, the blood volume accounts for a small fraction of the entire myocardial volume.²⁸⁾ In addition, although absolute variation of myocardial T1 value and ECV in human subjects over the cardiac cycle was significant, absolute changes were small (<2%) and might not be clinically relevant.¹²⁾ In contrary to the general option and despite the acquisition window of about 200 msec of the MOLLI sequence, images acquired at the early systole may result in a constantly good image quality.¹²⁾ The regional differences in myocardial motion or perfusion might cause variation in T1 value by post-contrast T1 mapping.¹²⁾²⁹⁾ Messroghli et al.¹⁶⁾ compared pre-contrast T1 values of the base, middle, and apical level of the left ventricle (LV) and did not find regional differences.

For practical reasons, most previous studies reported the post-contrast T1 mapping results only at a single location of the LV, commonly at the middle ventricle level. However, even if T1 values are the same between basal, middle, and apical myocardium of the LV, it is not clear whether all locations of the LV are equally affected by

diffuse fibrosis. Assessment of post-contrast T1 value and ECV is a sensitive method that requires rigorous conditions, such as considering the target region and cardiac cycle in order to enhance its accuracy to characterize the myocardium.

Clinical Application of T1 Mapping

Acute myocardial injury

The presence of myocardial edema can be a useful finding to differentiate acute from chronic myocardial infarction (Fig. 1),³⁰⁾ assessment of the area-at-risk,³¹⁾ myocarditis³²⁾ and increasingly as a surrogate end-point in clinical trial.³³⁾ T1 and T2 values track closely together such myocardial edema, which prolongs T1 and T2 reflecting free water contents in ischemic tissue.³³⁾ Especially, following prolonged ischemia, T1 values may increase above the expected increase in water content because of release of intracellular contents into the extracellular interstitium, according to the severity of cellular injury.³⁴⁾

In the study of patients with acute myocardial infarction, T1 value by pre-contrast T1 mapping showed a significantly lower variability

than T2-weighted image (T2WI) and accurately detected acutely injured myocardium.³⁵⁾ Ferreira et al.³⁶⁾ suggested that pre-contrast T1 mapping at 1.5T may be a more sensitive technique in detecting acute myocardial changes in both global and regional pathologies by using the diagnostic criteria of greater than 990 msec T1 value, with a sensitivity and specificity of 92%. In addition, Dall'Armellina et al.³⁵⁾ reported the likelihood of improvement of myocardial function at 6 months after injury decreased progressively with incremental increase of myocardial T1 values.

Myocardial fibrosis

Although the pathophysiological mechanisms of myocardial fibrosis are various, myocardial fibrosis, an increase of the collagen composition has been reported as an independent predictor of major adverse cardiac events.³⁷⁻³⁹⁾

Post-contrast T1 values in myocardial fibrosis are much smaller than those of normal myocardium due to the retention of more gadolinium in the expanded extracellular space in the fibrotic tissue. Messroghli et al.⁴⁰⁾ reported that post-contrast T1 values were approximately 390 msec in chronic infarction scar and 483 msec in

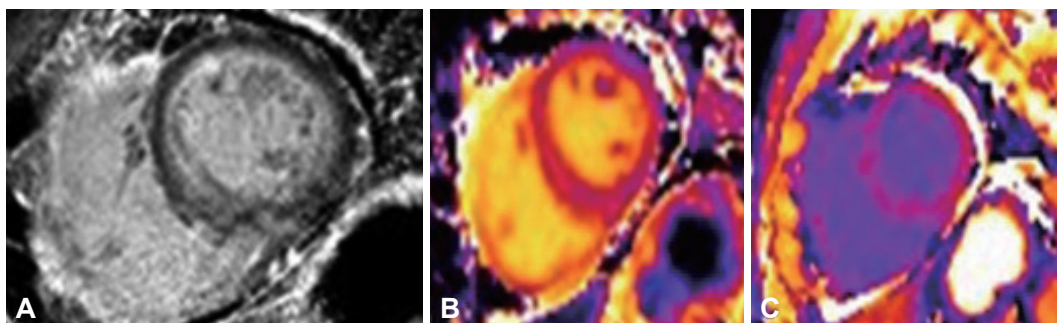


Fig. 2. Late gadolinium enhancement (LGE) (A), pre- and post-contrast (B and C) T1 map images using 3-T MR system in a patient with secondary myocardial amyloidosis from multiple myeloma. LGE-MR image shows diffuse subendocardial gadolinium enhancement, which is a typical finding of myocardial amyloidosis deposition. Post-contrast T1 map image shows decrease of T1 value in the myocardium which enables quantification of extracellular volume fraction.

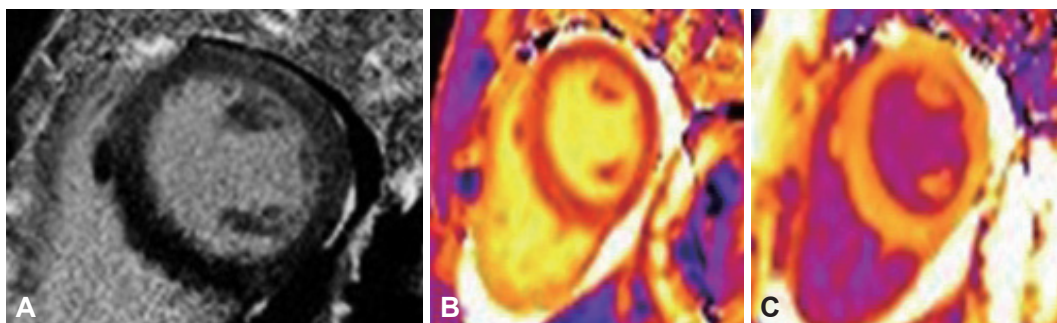


Fig. 3. Late gadolinium enhancement (LGE) (A), pre- and post-contrast (B and C) T1 map images using 3-T MR system in a patient with eosinophilic myocarditis diagnosed by the biopsy. LGE-MR image shows no remarkable late gadolinium enhancement in the myocardium. Pre-contrast T1 map image shows the prolongation of T1 value in the focal area of mid ventricular septum, compared to the lateral wall. It can suggest the probable edema in the myocardium. Post-contrast T1 mapping show diffusely low T1 value (mean±standard deviation, 410.4±34.4 msec) from gadolinium-induced T1 shortening in the myocardium. Myocardial extracellular volume fraction calculated by the T1 mapping results is 33.5% which is higher than that in normal control in the literature.

normal myocardium by T1 mapping with MOLLI sequence at 1.5T. Kehr et al.⁴¹⁾ also showed that post-contrast T1 values for both diffuse and replacement fibrosis were significantly shorter than those for normal myocardium. In addition, myocardial ECV obtained by combining pre- and post-contrast T1 mapping may be useful to detect mild or diffuse abnormalities. Ugander et al.¹⁰⁾ reported that the ECV obtained by T1 mapping at 1.5T of "normal appearing" myocardium without LGE was 26±3%, and increased with age. Mild ECV abnormalities were consistent with fibrosis according to age in the remote myocardium from infarction. A recent study reported that extracellular volume expansion measured by CMR might predict both mortality and other composite end points, including death, cardiac transplantation, and left ventricular assist device implantation.⁴²⁾ The investigators enrolled 793 patients and 9 volunteers, and measured ECV in non-infarcted myocardium. The ECV in patients ranged from 21.0% to 45.8%, while that in volunteers ranged from 21.7% to 26.2%. After the cohort was followed for 0.8 year, ECV was related to all-cause mortality and the other composite end points (hazard ratio, 1.5 and 1.48 for every 3% increase in ECV, respectively). Myocardial infiltrative diseases, such as amyloidosis and sarcoidosis usually reveal LGE at the diseased myocardium. Cardiac amyloidosis is characterized by a deposition of amyloid fibrils mainly in the endocardial myocardium, where LGE can be seen with an expanded extracellular space.²³⁾ Diffuse subendocardial enhancement is a hallmark of cardiac amyloidosis. T1 mapping can be a useful method to detect and quantify diffuse infiltrative pathology in the myocardium (Fig. 2).

Myocarditis

Although myocarditis is represented by myocardial inflammation, temporary pathologic status, according to disease progression or severity varies from edema to necrosis or fibrosis. T2WI of CMR is quite sensitive to detect regional myocardial edema in active myocarditis. LGE is a standard noninvasive imaging technique to evaluate irreversible myocardial injury related to myocarditis. However, diffuse or mild regional myocarditis typically in early or borderline disease may not be detected with T2-weighted imaging or LGE. Recently, a study reported that pre-contrast T1 mapping was sensitive to diagnose acute myocarditis that was CMR diagnosis based on T2-weighted imaging and LGE.⁴³⁾ With combination of pre-contrast and post-contrast T1 mapping, early detection and quantification of water contents or extracellular space will be feasible in myocarditis (Fig. 3).

Conclusion

Despite its sensitivity affected by many confounding technical

factors, CMR T1 mapping with MOLLI technique has begun to offer insight into early or diffuse myocardial disease and offered the potential for clinical utility. Being in need of the critical cut-off to differentiate between "normal" and "abnormal" myocardium by T1 mapping, ECV which can quantify myocardial interstitial expansion might be useful and stable index to characterize myocardium by using pre- and post-contrast T1 mapping.

References

1. Bottomley PA, Foster TH, Argersinger RE, Pfeifer LM. A review of normal tissue hydrogen NMR relaxation times and relaxation mechanisms from 1-100 MHz: dependence on tissue type, NMR frequency, temperature, species, excision, and age. *Med Phys* 1984;11:425-48.
2. Cummings KW, Bhalla S, Javidan-Nejad C, Bierhals AJ, Gutierrez FR, Woodard PK. A pattern-based approach to assessment of delayed enhancement in nonischemic cardiomyopathy at MR imaging. *RadioGraphics* 2009;29:89-103.
3. Callot V, Galanaud D, Figarella-Branger D, et al. Correlations between MR and endothelial hyperplasia in low-grade gliomas. *J Magn Reson Imaging* 2007;26:52-60.
4. Friedrich MG. Myocardial edema--a new clinical entity? *Nat Rev Cardiol* 2010;7:292-6.
5. Arai AE. Magnetic resonance imaging for area at risk, myocardial infarction, and myocardial salvage. *J Cardiovasc Pharmacol Ther* 2011; 16:313-20.
6. Foltz WD, Yang Y, Graham JJ, Detsky JS, Wright GA, Dick AJ. MRI relaxation fluctuations in acute reperfused hemorrhagic infarction. *Magn Reson Med* 2006;56:1311-9.
7. Croisille P, Revel D, Saeed M. Contrast agents and cardiac MR imaging of myocardial ischemia: from bench to bedside. *Eur Radiol* 2006;16: 1951-63.
8. Judd RM, Atalay MK, Rottman GA, Zerhouni EA. Effects of myocardial water exchange on T1 enhancement during bolus administration of MR contrast agents. *Magn Reson Med* 1995;33:215-23.
9. Newton N, Liu CY, Croisille P, Bluemke D, Lima JA. Assessment of myocardial fibrosis with cardiovascular magnetic resonance. *J Am Coll Cardiol* 2011;57:891-903.
10. Ugander M, Oki AJ, Hsu LY, et al. Extracellular volume imaging by magnetic resonance imaging provides insights into overt and sub-clinical myocardial pathology. *Eur Heart J* 2012;33:1268-78.
11. Lee JJ, Liu S, Nacif MS, et al. Myocardial T1 and extracellular volume fraction mapping at 3 tesla. *J Cardiovasc Magn Reson* 2011;13:75.
12. Kawel N, Nacif M, Zavodni A, et al. T1 mapping of the myocardium: intra-individual assessment of the effect of field strength, cardiac cycle and variation by myocardial region. *J Cardiovasc Magn Reson* 2012; 14:27.
13. Zhang Y, Yeung HN, O'Donnell M, Carson PL. Determination of sample time for T1 measurement. *J Magn Reson Imaging* 1998;8:675-81.
14. Messroghli DR, Radjenovic A, Kozerke S, Higgins DM, Sivananthan MU, Ridgway JP. Modified Look-Locker inversion recovery (MOLLI) for high-resolution T1 mapping of the heart. *Magn Reson Med* 2004;52:141-6.

15. Scheffler K, Hennig J. T(1) quantification with inversion recovery True-FISP. *Magn Reson Med* 2001;45:720-3.
16. Messroghli DR, Plein S, Higgins DM, et al. Human myocardium: single-breath-hold MR T1 mapping with high spatial resolution--reproducibility study. *Radiology* 2006;238:1004-12.
17. Piechnik SK, Ferreira VM, Dall'Armellina E, et al. Shortened Modified Look-Locker Inversion recovery (ShMOLLI) for clinical myocardial T1-mapping at 1.5 and 3 T within a 9 heartbeat breathhold. *J Cardiovasc Magn Reson* 2010;12:69.
18. Messroghli DR, Greiser A, Fröhlich M, Dietz R, Schulz-Menger J. Optimization and validation of a fully-integrated pulse sequence for modified look-locker inversion-recovery (MOLLI) T1 mapping of the heart. *J Magn Reson Imaging* 2007;26:1081-6.
19. Karamitsos TD, Francis JM, Myerson S, Selvanayagam JB, Neubauer S. The role of cardiovascular magnetic resonance imaging in heart failure. *J Am Coll Cardiol* 2009;54:1407-24.
20. Mahrholdt H, Wagner A, Judd RM, Sechtem U, Kim RJ. Delayed enhancement cardiovascular magnetic resonance assessment of non-ischaemic cardiomyopathies. *Eur Heart J* 2005;26:1461-74.
21. McCrohon JA, Moon JC, Prasad SK, et al. Differentiation of heart failure related to dilated cardiomyopathy and coronary artery disease using gadolinium-enhanced cardiovascular magnetic resonance. *Circulation* 2003;108:54-9.
22. Gai N, Turkbey EB, Nazarian S, et al. T1 mapping of the gadolinium-enhanced myocardium: adjustment for factors affecting interpatient comparison. *Magn Reson Med* 2011;65:1407-15.
23. Maceira AM, Joshi J, Prasad SK, et al. Cardiovascular magnetic resonance in cardiac amyloidosis. *Circulation* 2005;111:186-93.
24. Broberg CS, Chugh SS, Conklin C, Sahn DJ, Jerosch-Herold M. Quantification of diffuse myocardial fibrosis and its association with myocardial dysfunction in congenital heart disease. *Circ Cardiovasc Imaging* 2010;3:727-34.
25. Messroghli DR, Nordmeyer S, Dietrich T, et al. Assessment of diffuse myocardial fibrosis in rats using small-animal Look-Locker inversion recovery T1 mapping. *Circ Cardiovasc Imaging* 2011;4:636-40.
26. Arheden H, Saeed M, Higgins CB, et al. Measurement of the distribution volume of gadopentetate dimeglumine at echo-planar MR imaging to quantify myocardial infarction: comparison with 99mTc-DTPA autoradiography in rats. *Radiology* 1999;211:698-708.
27. Willinek WA, Gieseke J, Kukuk GM, et al. Dual-source parallel radiofrequency excitation body MR imaging compared with standard MR imaging at 3.0 T: initial clinical experience. *Radiology* 2010;256:966-75.
28. Judd RM, Levy BI. Effects of barium-induced cardiac contraction on large- and small-vessel intramyocardial blood volume. *Circ Res* 1991;68:217-25.
29. Wansapura J, Gottliebson W, Crotty E, Fleck R. Cyclic variation of T1 in the myocardium at 3 T. *Magn Reson Imaging* 2006;24:889-93.
30. Abdel-Aty H, Zagrosek A, Schulz-Menger J, et al. Delayed enhancement and T2-weighted cardiovascular magnetic resonance imaging differentiate acute from chronic myocardial infarction. *Circulation* 2004;109:2411-6.
31. Payne AR, Casey M, McClure J, et al. Bright-blood T2-weighted MRI has higher diagnostic accuracy than dark-blood short tau inversion recovery MRI for detection of acute myocardial infarction and for assessment of the ischemic area at risk and myocardial salvage. *Circ Cardiovasc Imaging* 2011;4:210-9.
32. Friedrich MG, Sechtem U, Schulz-Menger J, et al. Cardiovascular magnetic resonance in myocarditis: A JACC White Paper. *J Am Coll Cardiol* 2009;53:1475-87.
33. Abdel-Aty H, Simonetti O, Friedrich MG. T2-weighted cardiovascular magnetic resonance imaging. *J Magn Reson Imaging* 2007;26:452-9.
34. Williams ES, Kaplan JI, Thatcher F, Zimmerman G, Knoebel SB. Prolongation of proton spin lattice relaxation times in regionally ischemic tissue from dog hearts. *J Nucl Med* 1980;21:449-53.
35. Dall'Armellina E, Piechnik SK, Ferreira VM, et al. Cardiovascular magnetic resonance by non contrast T1-mapping allows assessment of severity of injury in acute myocardial infarction. *J Cardiovasc Magn Reson* 2012;14:15.
36. Ferreira VM, Piechnik SK, Dall'Armellina E, et al. Non-contrast T1-mapping detects acute myocardial edema with high diagnostic accuracy: a comparison to T2-weighted cardiovascular magnetic resonance. *J Cardiovasc Magn Reson* 2012;14:42.
37. Bello D, Shah DJ, Farah GM, et al. Gadolinium cardiovascular magnetic resonance predicts reversible myocardial dysfunction and remodeling in patients with heart failure undergoing beta-blocker therapy. *Circulation* 2003;108:1945-53.
38. Kwong RY, Chan AK, Brown KA, et al. Impact of unrecognized myocardial scar detected by cardiac magnetic resonance imaging on event-free survival in patients presenting with signs or symptoms of coronary artery disease. *Circulation* 2006;113:2733-43.
39. Kwong RY, Sattar H, Wu H, et al. Incidence and prognostic implication of unrecognized myocardial scar characterized by cardiac magnetic resonance in diabetic patients without clinical evidence of myocardial infarction. *Circulation* 2008;118:1011-20.
40. Messroghli DR, Walters K, Plein S, et al. Myocardial T1 mapping: application to patients with acute and chronic myocardial infarction. *Magn Reson Med* 2007;58:34-40.
41. Kehr E, Sono M, Chugh SS, Jerosch-Herold M. Gadolinium-enhanced magnetic resonance imaging for detection and quantification of fibrosis in human myocardium in vitro. *Int J Cardiovasc Imaging* 2008;24:61-8.
42. Wong TC, Piehler K, Meier CG, et al. Association between extracellular matrix expansion quantified by cardiovascular magnetic resonance and short-term mortality. *Circulation* 2012;126:1206-16.
43. Ferreira V, Piechnik SK, Dall'Armellina E, et al. The diagnostic performance of non-contrast T1-mapping in patients with acute myocarditis on cardiovascular magnetic resonance imaging. *J Cardiovasc Magn Reson* 2012;14(Suppl 1):179.