

Received: 2020.01.05

Accepted: 2020.02.25

Available online: 2020.03.26

Published: 2020.05.20

# Quantitative Characterization of Bone Viability of Femoral Head and Subchondral Bone by Using Single Photon Emission Computerized Tomography/Computerized Tomography (SPECT/CT)

Authors' Contribution:  
Study Design A  
Data Collection B  
Statistical Analysis C  
Data Interpretation D  
Manuscript Preparation E  
Literature Search F  
Funds Collection G

AE 1,2 **Lu Cao\***  
CE 3 **Yanan Liao\***  
B 1 **Chunfeng Song**  
C 1 **Haochen Jiang**  
F 1 **Zenggan Chen**  
A 1 **Zuoqin Yan**  
AFG 1 **Changan Guo**

1 Department of Orthopedic Surgery, Zhongshan Hospital, Fudan University, Shanghai, P.R. China  
2 Department of Orthopedic Surgery, Zhongshan Hospital Xiamen Branch, Fudan University, Xiamen, Fujian, P.R. China  
3 Department of Orthopedic Surgery, The Second People's Hospital of Kashgar Prefecture, Kashgar, Xinjiang, P.R. China

\* Lu Cao and Yanan Liao contributes equally to this work

**Corresponding Authors:** Zuoqin Yan, e-mail: yan.zuoqin@zs-hospital.sh.cn, Changan Guo, e-mail: changanguo@hotmail.com, Zenggan Chen, e-mail: orthfile@163.com

**Source of support:** This work was supported by grants from the National Natural Science Foundation of China (No. 81672142) and Shanghai "Rising Stars of Medical Talent" Youth Development Program

**Background:** Vascularized fibular grafting (VFG) has been successfully employed for treating avascular necrosis of the femoral head (ANFH). In this study, we aimed to evaluate the bone viability of the femoral head and subchondral bone following VFG by using single photon emission computerized tomography and computerized tomography (SPECT/CT).


**Material/Methods:** Between March 2011 and June 2014, 14 ANFH patients (17 hips) treated with VFG at Zhongshan Hospital, Fudan University, were prospectively enrolled. The patients included 9 males and 5 females with an average age of 26.6 years (range, 18–34 years). According to the ARCO (Association Research Circulation Osseous) stage criteria, 3 hips corresponded to stage IIA, 4 hips to stage IIB, 2 hips to stage IIC, 5 hips to stage IIIA, and 3 hips to stage IIIB. A novel method based on SPECT/CT was developed to quantitatively characterize the bone viability of femoral head and subchondral bone prior to surgery and at 3 months after VFG. All patients were followed for an average duration of 3.8 years (ranging 2.6–5.5 years).

**Results:** The bone viability of the femoral head ( $V_{fh}$ ) and subchondral bone ( $V_{sb}$ ) of patients' hips at ARCO stage III was  $58.9 \pm 7.6$  and  $48.9 \pm 6.1$ , respectively, which were significantly lower than the preoperative  $V_{fh}$  ( $78.1 \pm 5.2$ ) and  $V_{sb}$  ( $69.8 \pm 4.3$ ) of hips at stage II ( $P < 0.05$ ). The  $V_{fh}$  of hips at stage II improved to  $104.0 \pm 9.7$  at 3 months post-intervention, and there was no significant difference compared with the  $V_{fh}$  ( $97.3 \pm 7.4$ ) of hips at stage III ( $P = 0.15$ ). The  $V_{sb}$  of hips at stage III improved to  $80.4 \pm 7.3$  at 3 months after VFG; however, this value was significantly lower than that of hips at stage II ( $92.7 \pm 5.5$ ) ( $P < 0.05$ ).

**Conclusions:** The  $V_{fh}$  and  $V_{sb}$  of our patients were associated with their ARCO stages, and could be improved after vascularized fibular grafting procedure as measured by SPECT/CT.

**MeSH Keywords:** **Arthroplasty, Subchondral • Composite Tissue Allografts • Femur Head Necrosis • Tomography, Emission-Computed, Single-Photon**

**Full-text PDF:** <https://www.medscimonit.com/abstract/index/idArt/922624>

 1723

 1

 3

 37



## Background

Avascular necrosis of the femoral head (ANFH) is a relatively common disease in which necrotic bone lesions usually progress to hip joint dysfunction and, thereafter, disability in young individuals [1–3]. The pathological process of ANFH initially causes death of bone which then collapses in certain instances and cause subchondral plate collapse and osteoarthritis [4].

Free vascularized fibula grafting (VFG) has been considered a valuable tool for protecting the femoral head from osteonecrosis complications. This biologic option for head-preserving is generally accepted to serve as a biologic support to a devascularized femoral head. This procedure uses the patient's autologous fibula with its accompanying vessels providing a fresh blood supply and bony support to the healing femoral head [5–11]. However, little is known about its efficacy on the bone viability of femoral head and subchondral bone after VFG.

The combination of the single photon emission computerized tomography (SPECT) imaging technology with multi-slice computerized tomography (CT) scanning has helped us to detect nonspecific abnormalities and interpret them as specific focal areas of pathology. Bone SPECT/CT can effectively utilize the merits of both imaging modalities to provide high-quality diagnostic images [12], and it has been widely regarded as a technique with the potential to significantly improve the accuracy of clinical diagnosis. We previously performed SPECT/CT to evaluate viability of femoral head of patients with femoral neck fracture for predicting ANFH [13]. In this report, we present the results of using SPECT/CT to quantitatively characterize the bone viability of femoral head and subchondral bone following free vascularized fibular grafting.

## Material and Methods

Between March 2011 and June 2014, 14 patients (17 hips) with ANFH who were treated with VFG at Zhongshan Hospital, Fudan University, were prospectively enrolled. Each patient was treated with VFG, the surgical procedure was described previously [10]. The patients included 9 males and 5 females with an average age of 26.6 years (range, 18–34 years). The possible etiologies of the disease among the 14 patients were steroid medication in 6 cases (8 hips), consumption of alcohol in 5 cases (6 hips), and trauma in 3 cases (3 hips). The diagnosis of ANFH was based on clinical evaluation and radiography, including plain anteroposterior radiographs, frog lateral radiographs, and magnetic resonance imaging (MRI). According to the ARCO (Association Research Circulation Osseous) stage criteria [14], 3 hips corresponded to stage IIA, 4 hips to stage IIB, 2 hips to stage IIC, 5 hips to stage IIIA, and 3 hips to stage IIIB. These patients were prospectively enrolled into the present

study. Follow-up clinical and radiographic examinations should be performed at 3, 6, and 12 months postoperatively, and annually thereafter. X-rays were performed, and Harris hip scores (HHSs) were evaluated. Signed informed consent documents were obtained from all patients.

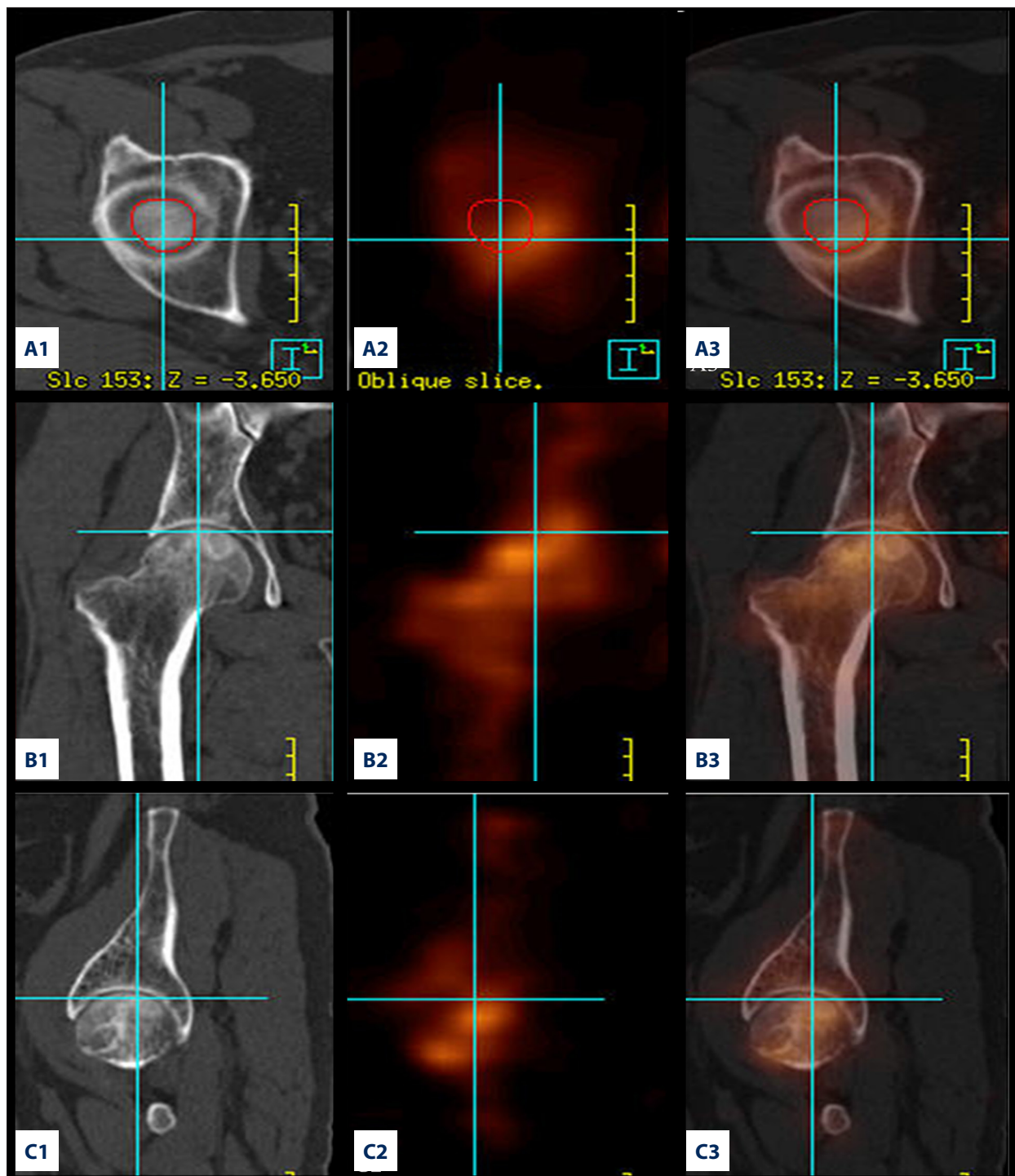
SPECT/CT (Precedence, Philips, Milpitas, CA, USA) was performed prior to operation and at 3 months postoperatively as described previously [13]. An intravenous injection of 925–1110 MBq (25–30 mCi)  $^{99m}\text{Tc}$ -methylene diphosphonate was performed for each patient 3–4 hours before SPECT/CT scan. The scanning method included the following steps: first, the femoral head was located by an x-ray, next, a 16-slice CT scan was performed. The scan time interval of CT and SPECT was <2 minutes.

The SPECT image and CT image were integrated by using SYNTegra image fusion software, and then the image data were collected and evaluated by a nuclear medicine physician who was not involved in the operation. The region of interest (ROI) of the femoral head was outlined on the surgical side by the nuclear medicine physician, ranging from the top of the head (Figure 1) to the junction plane of the head and the neck (Figure 2), then it would be automatically generated based on the fusion image. When the first sacral vertebra was outlined, a 3-dimensional reconstruction image of the sacral vertebra would then be generated. A 5-mm distance distal to the chondro-osseous junction was used as the ROI of subchondral bone for each femoral head (Figures 2, 3B). This distance that was chosen was based on the reported average thickness of the subchondral bone of 5 mm [15–17]. SYNTegra software calculated the number of radioactive nuclides of each ROI and expressed it as  $\gamma$  photons/cm<sup>3</sup>. To improve the accuracy, we used the number of  $\gamma$  photons/cm<sup>3</sup> in the femoral head and subchondral bone treated with VFG against the number of  $\gamma$  photons/cm<sup>3</sup> in the first sacral vertebrae to express the bone viability of the femoral head ( $V_{fm}$ ) (Figure 3A) and subchondral bone ( $V_{sb}$ ) (Figure 3B).

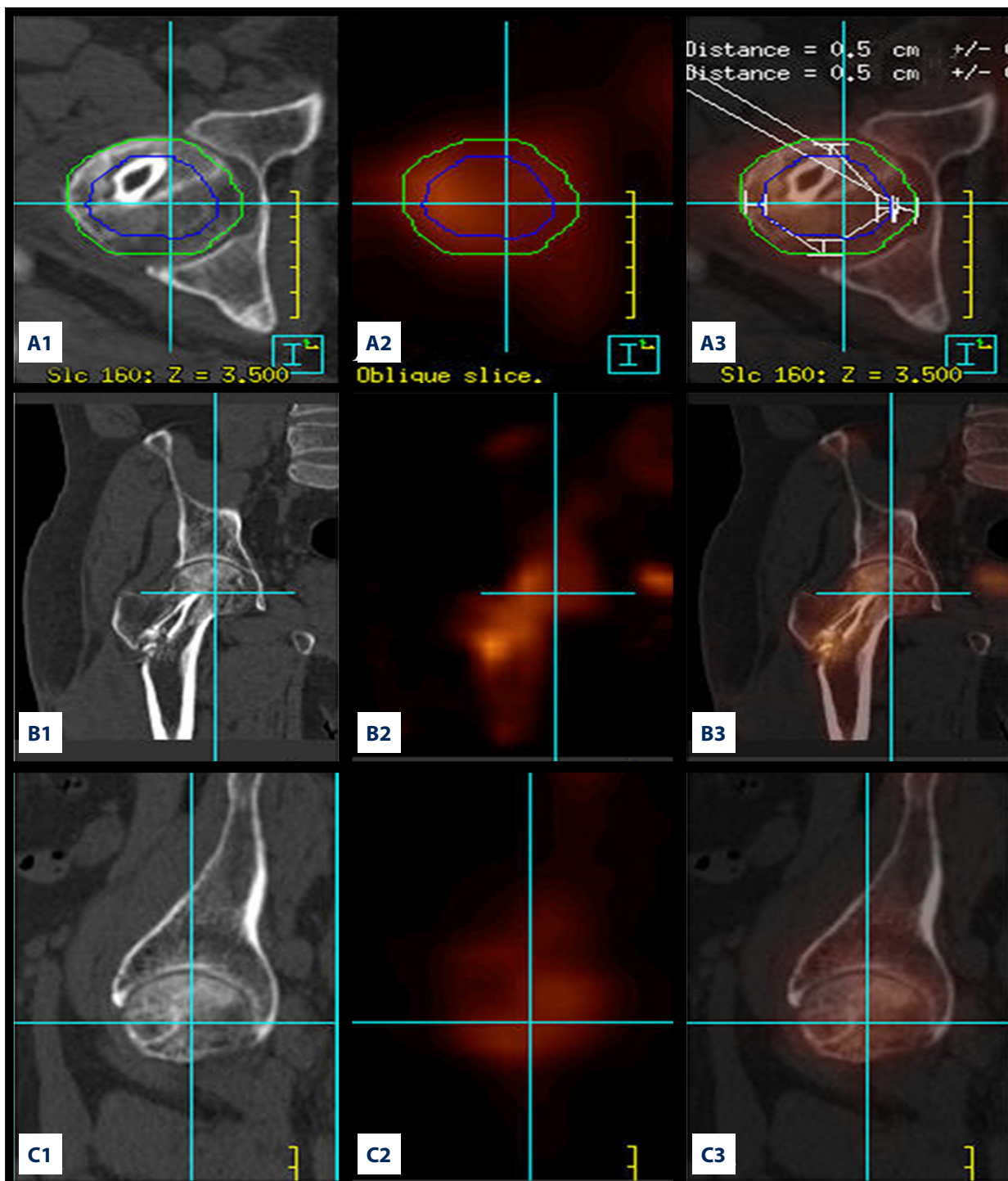
$$V_{fm} = \left( \frac{\gamma \text{ photon numbers/1 cm}^3 \text{ in femoral head}}{\gamma \text{ photon numbers/1 cm}^3 \text{ in the first sacral vertebrae}} \right) \times 100 (\%) \quad (1)$$

$$V_{sb} = \left( \frac{\gamma \text{ photon numbers/1 cm}^3 \text{ in subchondral bone}}{\gamma \text{ photon numbers/1 cm}^3 \text{ in the first sacral vertebrae}} \right) \times 100 (\%) \quad (2)$$

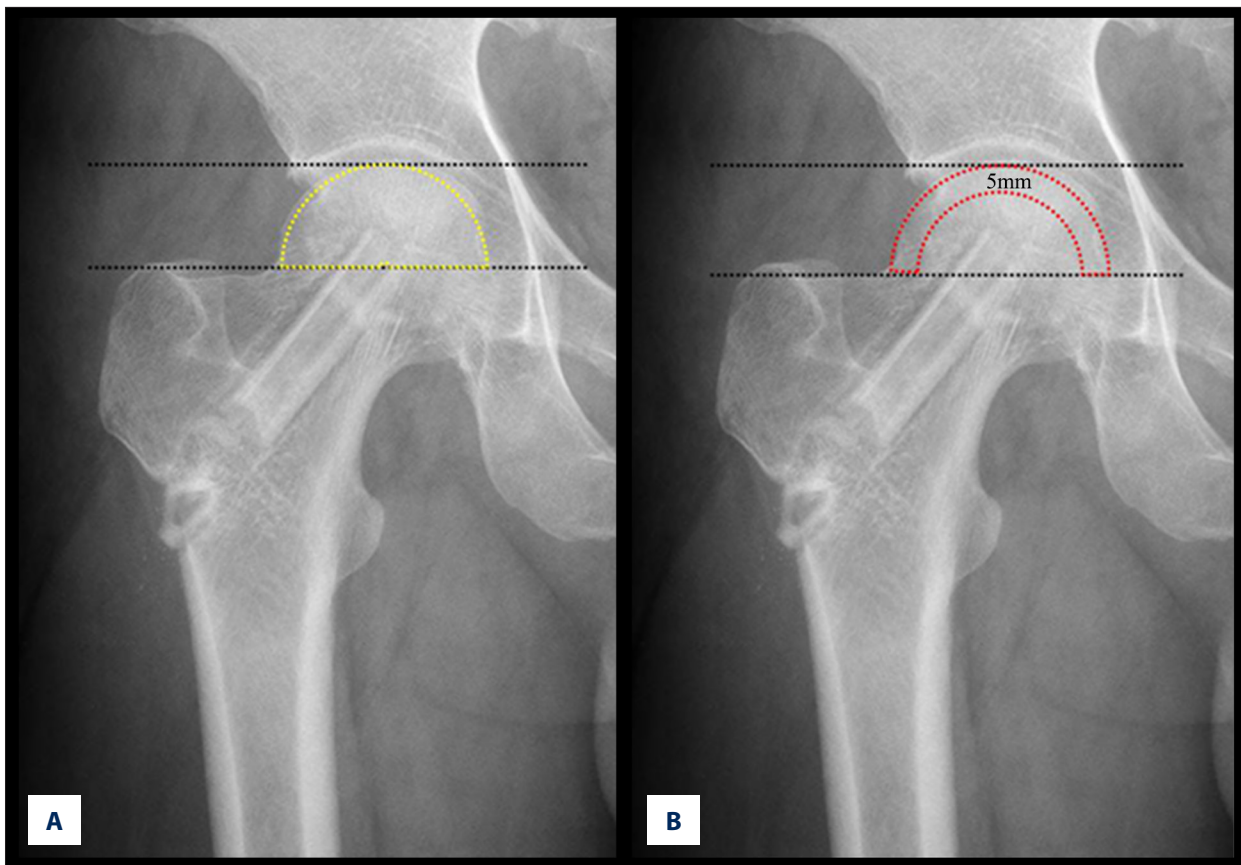
The HHS data were presented as the mean  $\pm$  standard deviation (SD). The preoperative and postoperative  $V_{fm}$  and  $V_{sb}$  of hips at ARCO stage II were compared with  $V_{fm}$  and  $V_{sb}$  of hips at ARCO stage III by using a paired *t*-test. Statistical analysis was performed using SPSS version 14.0. A *P* value of <0.05 was considered statistically significant.



**Figure 1.** The SPECT/CT images of a 27-year-old male patient obtained prior to surgery are shown. **(A1)** CT image: the ROI of the femoral heads was outlined on the surgical side by the nuclear medicine physician. **(A2)** The SPECT images: the ROI would be automatically generated based on CT images. **(A3)** SPECT/CT fusion images with ROI. **(B1)** The coronal CT image of patient's hip is shown. **(B2)** The SPECT image: the distribution and bone uptake of radionuclide in the patient's hip. **(B3)** Bone viability of the femoral head is shown on the coronal fused SPECT/CT image. **(C1)** The sagittal CT image of femoral head is shown. **(C2)** The SPECT image: the distribution and bone uptake of radionuclide of the patient's femoral head. **(C3)** Bone viability of the hip is shown on the sagittal SPECT/CT image. SPECT/CT – single photon emission computerized tomography and computerized tomography; ROI – region of interest.



**Figure 2.** The SPECT/CT images of the patient’s hip shown in Figure 1, obtained 3 months after VFG. **(A1)** The ROI of the femoral heads was outlined on the surgical side by the nuclear medicine physician on the CT image. The region in the green circle indicates the ROI for  $V_{fm}$ , and the region between green and blue circle indicates the ROI for  $V_{sb}$ . **(A2)** SPECT image: the ROI would be automatically generated based on CT images. **(A3)** SPECT/CT fusion images with ROI. **(B1)** The coronal CT image of patient’s hip after VFG is shown. **(B2)** The distribution and bone uptake of radionuclide of the femoral head can be seen in this SPECT image. **(B3)** Bone viability of the femoral head after VFG is shown on the coronal fused SPECT/CT image. **(C1)** The sagittal CT image of femoral head is shown. **(C2)** SPECT image: the distribution and bone uptake of radionuclide of the patient’s femoral head can be seen. **(C3)** Bone viability of the hip is shown on the sagittal SPECT/CT image. SPECT/CT – single photon emission computerized tomography and computerized tomography; VFG – vascularized fibular grafting.



**Figure 3.** ANFH graded as ARCO stage II for the right hip 3 months post-surgical treatment: ROI for bone viability of the femoral head (A) and subchondral bone (B). ANFH – avascular necrosis of the femoral head; ARCO – Association Research Circulation Osseous; ROI – region of interest.

**Table 1.** Bone viability of the femoral head ( $V_{fh}$ ) and subchondral bone ( $V_{sb}$ ) of hips at ARCO stage II and ARCO stage II.

	Pre-operation		3 months post-operation	
	$V_{fh}$	$V_{sb}$	$V_{fh}$	$V_{sb}$
ARCO stage II	78.1±5.2	69.8±4.3	104.0±9.7	92.7±5.5
ARCO stage III	58.9±7.6	48.9±6.1	97.3±7.4	80.4±7.3

ARCO – Association Research Circulation Osseous.

## Results

No patients had postoperative complications. No patient was lost to follow-up, the mean follow-up was 3.8 years (ranging 2.6–5.5 years). One stage III hip progressed to a total hip arthroplasty at 4 years after the operation. The preoperative HHS of all patients was 51.1±5.0 and significantly improved to 85.6±3.5 and 89.9±2.3 at 6 and 12 months, respectively, post-intervention ( $P<0.05$ ).

Preoperative SPECT/CT analysis revealed that the bone viability of the femoral head ( $V_{fh}$ ) and subchondral bone ( $V_{sb}$ ) of hips at

ARCO stage III was 58.9±7.6 and 48.9±6.1, respectively, which were significantly lower than the preoperative  $V_{fh}$  (78.1±5.2) and  $V_{sb}$  (69.8±4.3) of hips at a stage II ( $P<0.05$ ). The  $V_{fh}$  of hips at stage II improved to 104.0±9.7 at 3 months post-intervention, and there was no significant difference compared with the  $V_{fh}$  (97.3±7.4) of hips at stage III ( $P=0.15$ ). The  $V_{sb}$  of hips at stage III improved to 80.4±7.3 at 3 months post-intervention; however, the viability was significantly lower than that of hips at stage II (92.7±5.5) ( $P<0.05$ ) (Table 1).

## Discussion

Many studies on ANFH to-date have focused on head-preserving surgery, such as core decompression [18,19], implantation of stem cells [20], non-vascularized and vascularized fibular grafting [8–11], and pedicled iliac bone flap transfer [21], which yield improved clinical results in the early stages of osteonecrosis. Among these techniques, the VFG surgical procedure has been reported to be a biological option for hip preservation for 20 or more years [6,11,22–24].

There are several deficiencies in the existing literature regarding the effect of free vascularized fibular grafting after ANFH. According to Zhang and associates [9,10,25], radiographic improvement is defined as necrosis that has healed and has been replaced with new bone, while radiographic worsening is defined as necrosis that has progressed or collapsed. Aldridge et al. [6,22], determined the size and location of necrotic lesions and the presence or absence of collapse and/or joint space narrowing on each film. Digital subtraction angiography (DSA) was also employed to select vascularized bone grafts in the management of ANFH [26], however it was difficult to quantitatively characterize bone viability femoral head. We believe that these common methods are either invasive or inaccurate because different observers can easily make a wide range of observations. Additionally, radiographic assessments based on x-ray and magnetic resonance imaging (MRI) do not adequately quantitatively characterize the bone viability status of ANFH or detect blood supply to the femoral head compared with the preoperative state, and multiple imaging sessions are not suggested.

ANFH results from a loss of blood supply and leads to a flattening deformity [27]. This disruption of blood flow causes extensive cell death. It is generally accepted that advantage of VFG procedure is the development of a supply of nutrient blood to the healing necrotic femoral head. The rich vascularity and biologic potential of the vascularized fibular graft allows to achieve callus formation from the purposely exposed cortex and the cambial layer of the periosteum of the cephalad end of the graft to the cancellous bone and the remaining subchondral bone of the devascularized femoral head [28]. Unfortunately, little is known about the improvement of bone viability status of the subchondral bone and femoral head following VFG. No single method has been demonstrated to both effectively and quantitatively evaluate subchondral bone and femoral head bone viability. SPECT/CT can provide more

anatomical precision for evaluating bone metabolism and viability while fully and effectively utilizing the merits of both imaging modalities to provide high-quality diagnostic images [12]. The potential use of SPECT/CT for detecting femoral head bone viability following femoral neck fracture has been recently demonstrated [13]. In the present study, SPECT/CT was performed to calculate the bone uptake of radionuclides in the hip and local subchondral bone. Local microenvironment including bone viability and mineral metabolism would affect bone uptake of radionuclides [29]. It has previously been shown that a necrotic lesion in the femoral head results in low perfusion and metabolic activity [30]. Therefore, the uptake rate of radionuclides in the femoral head with ANFH would be lower compared with the sacral vertebrae. After VFG treatment, the uptake of radionuclides increases due to the improvement of blood supply and bone viability.

Subchondral bone plays an important role in intra-articular stress distributions, cartilage nutrition and, ultimately, joint homeostasis [31,32]. AVN can lead to a subchondral fracture and subsequent femoral head collapse [33,34]. Nishii et al. [35] examined the pathogenesis of subchondral fracture and femoral head deformity following osteonecrosis by using magnetic resonance imaging. The present study demonstrated that the bone viability of subchondral bone of hips at ARCO stage III was significantly lower than the bone viability of hips at ARCO stage II. After VFG, the bone viability of subchondral bone was significantly increased in hips at both stages II and III, and there was no significant difference between hips at stages II and III following VFG. Our results support the previous hypothesis regarding the relevance of vascular supply for subchondral bone [36,37], which could conclude this method as a joint-preserving treatment for osteonecrosis is a reasonable option.

Limitations of the present study include the relatively brief follow-up period and the SPECT/CT examination. Further SPECT/CT analyses are necessary to evaluate the long-term post-VFG changes of the bone viability of the femoral head and subchondral bone and its relationship with hip function and the long-term hip survival rate.

## Conclusions

The  $V_m$  and  $V_{sb}$  of our patients are associated with their ARCO stages, and can be improved after vascularized fibular grafting procedure as measured by SPECT/CT.

## References:

1. Fan M, Peng J, Qin L, Lu S: Experimental animal models of osteonecrosis. *Rheumatol Int*, 2011; 31(8): 983–94
2. Lieberman JR, Engstrom SM, Meneghini RM, SooHoo NF: Which factors influence preservation of the osteonecrotic femoral head? *Clin Orthop Relat Res*, 2012; 470(2): 525–34
3. Babhulkar S: Osteonecrosis of femoral head: Treatment by core decompression and vascular pedicle grafting. *Indian J Orthop*, 2009; 43: 27–35
4. Marker DR, Seyler TM, McGrath MS et al: Treatment of early stage osteonecrosis of the femoral head. *J Bone Joint Surg Am*, 2008; 90: 175–87
5. Wood MB: Free vascularized fibular grafting – 25 years' experience: Tips, techniques, and pearls. *Orthop Clin N Am*, 2007; 38: 1–12
6. Aldridge JM 3<sup>rd</sup>, Urbaniak JR: Vascularized fibular grafting for osteonecrosis of the femoral head with unusual indications. *Clin Orthop Relat Res*, 2008; 466(5): 1117–24
7. Korompilias AV, Beris AE, Lykissas MG et al: Femoral head osteonecrosis: Why choose free vascularized fibula grafting. *Microsurgery*, 2011; 31: 223–28
8. Eward WC, Rineer CA, Urbaniak JR et al: The vascularized fibular graft in pre-collapse osteonecrosis: Is long-term hip preservation possible? *Clin Orthop Relat Res*, 2012; 470(10): 2819–26
9. Gao YS, Liu XL, Sheng JG et al: Unilateral free vascularized fibula shared for the treatment of bilateral osteonecrosis of the femoral head. *J Arthroplasty*, 2013; 28(3): 531–36
10. Gao YS, Chen SB, Jin DX et al: Modified surgical techniques of free vascularized fibular grafting for treatment of the osteonecrosis of femoral head: Results from a series of 407 cases. *Microsurgery*, 2013; 33: 646–51
11. Ünal MB, Cansu E, Parmaksızoğlu F et al: Treatment of osteonecrosis of the femoral head with free vascularized fibular grafting: Results of 7.6-year follow-up. *Acta Orthop Traumatol Turc*, 2016; 50(3): 323–29
12. Duan R, Shi H: Clinical study of the application of SPECT, CT, and SPECT/CT for diagnosing rib diseases. *Jpn J Radiol*, 2015; 33(3): 131–39
13. Yuan HF, Shen F, Zhang J et al: Predictive value of SPECT-CT in osteonecrosis after femoral neck fracture: A prospective study. *Int Orthop*, 2015; 39(7): 1417–22
14. Ohzono K, Saito M, Sugano N et al: The fate of nontraumatic avascular necrosis of the femoral head. A radiologic classification to formulate prognosis. *Clin Orthop Relat Res*, 1992; (277): 73–78
15. Dewire P, Simkin PA: Subchondral plate thickness reflects tensile stress in the primate acetabulum. *J Orthop Res*, 1996; 14(5): 838–41
16. Harada Y, Wevers HW, Cooke TD: Distribution of bone strength in the proximal tibia. *J Arthroplasty*, 1988; 3(2): 167–75
17. Johnston JD, Masri BA, Wilson DR: Computed tomography topographic mapping of subchondral density (CT-TOMASD) in osteoarthritic and normal knees: Methodological development and preliminary findings. *Osteoarthr Cartil*, 2009; 17(10): 1319–26
18. Helbig L, Simank HG, Kroeber M et al: Core decompression combined with implantation of a demineralised bone matrix for non-traumatic osteonecrosis of the femoral head. *Arch Orthop Trauma Surg*, 2012; 132(8): 1095–103
19. Wang CJ, Huang CC, Wang JW et al: Long-term results of extracorporeal shockwave therapy and core decompression in osteonecrosis of the femoral head with eight- to nine-year follow-up. *Biomed J*, 2012; 35(6): 481–85
20. Zhao D, Cui D, Wang B et al: Treatment of early stage osteonecrosis of the femoral head with autologous implantation of bone marrow-derived and cultured mesenchymal stem cells. *Bone*, 2012; 50(1): 325–30
21. Zhao D, Xie H, Xu Y et al: Management of osteonecrosis of the femoral head with pedicled iliac bone flap transfer: A multicenter study of 2190 patients. *Microsurgery*, 2017; 37(8): 896–901
22. Aldridge JM 3<sup>rd</sup>, Berend KR, Gunneson EE, Urbaniak JR: Free vascularized fibular grafting for the treatment of postcollapse osteonecrosis of the femoral head: surgical technique. *J Bone Joint Surg Am*, 2004; 86(suppl. 1): 87–101
23. Judet H, Gilbert A: Long-term results of free vascularized fibular grafting for femoral head necrosis. *Clin Orthop Relat Res*, 2001; 386: 114–19
24. Yoo M, Kim K, Hahn C, Parvizi J: Long-term follow up of vascularized fibular grafting for femoral head necrosis. *Clin Orthop Relat Res*, 2008; 466: 1133–40
25. Zhang C, Zeng B, Xu Z et al: Treatment of femoral head necrosis with free vascularized fibula grafting: A preliminary report. *Microsurgery*, 2005; 25(4): 305–9
26. Zhao D, Xiaobing Y, Wang T et al: Digital subtraction angiography in selection of the vascularized greater trochanter bone grafting for treatment of osteonecrosis of femoral head. *Microsurgery*, 2013; 33(8): 656–59
27. Aruwajoye OO, Patel MK, Allen MR et al: Microcrack density and nanomechanical properties in the subchondral region of the immature piglet femoral head following ischemic osteonecrosis. *Bone*, 2013; 52(2): 632–39
28. Aldridge JM 3<sup>rd</sup>, Urbaniak JR: Avascular necrosis of the femoral head: Role of vascularized bone grafts. *Orthop Clin North Am*, 2007; 38: 13–22
29. Soundararajan R, Naswa N, Sharma P et al: SPECT-CT for characterization of extraosseous uptake of 99mTc-methylene diphosphonate on bone scintigraphy. *Diagn Interv Radiol*, 2013; 19(5): 405–10
30. Ryu JS, Kim JS, Moon DH et al: Bone SPECT is more sensitive than MRI in the detection of early osteonecrosis of the femoral head after renal transplantation. *J Nucl Med*, 2002; 43: 1006–11
31. Imhof H, Sulzbacher I, Grampp S et al: Subchondral bone and cartilage disease: A rediscovered functional unit. *Invest Radiol*, 2000; 35(10): 581–88
32. Madry H, van Dijk CN, Mueller-Gerbl M: The basic science of the subchondral bone. *Knee Surg Sports Traumatol Archosc*, 2010; 18(4): 419–33
33. Kim HK, Su PH: Development of flattening and apparent fragmentation following ischemic necrosis of the capital femoral epiphysis in a piglet model. *J Bone Joint Surg Am*, 2002; 84-A: 1329–34
34. Park SS, Kim HK: Subchondral fracture after ischemic osteonecrosis of the immature femoral head in piglet model. *J Pediatr Orthop B*, 2011; 20: 227–31
35. Nishii T, Sugano N, Ohzono K et al: Significance of lesion size and location in the prediction of collapse of osteonecrosis of the femoral head: A new three-dimensional quantification using magnetic resonance imaging. *J Orthop Res*, 2002; 20(1): 130–36
36. Urbaniak JR, Coogan PG, Gunneson EB, Nunley JA: Treatment of osteonecrosis of the femoral head with free vascularized fibular grafting. A long-term follow-up study of one hundred and three hips. *J Bone Joint Surg Am*, 1995; 77: 681–94
37. Urbaniak JR, Harvey EJ: Revascularization of the femoral head in osteonecrosis. *J Am Acad Orthop Surg*, 1998; 6: 44–54