



Arthroscopic Bone Grafting of the Humeral Head for Treatment of a Deep Hill-Sachs Lesion

Jin Tang, M.B., Caiqi Xu, M.D., and Jinzhong Zhao, M.D.

Abstract: Recurrent anterior shoulder dislocation often leads to the presence of a Hill-Sachs lesion. A large Hill-Sachs lesion compromises shoulder stability and should be addressed with bone augmentation when it is too deep. Here, we introduce a method of arthroscopic bone grafting of the humeral head for the treatment of a deep Hill-Sachs lesion in patients with anterior shoulder instability. Our indication for this procedure is a deep off-track Hill-Sachs lesion measuring at least 8 mm in depth and 10 mm in width. The main steps of this procedure include graft placement via special shoulder bone grafting instruments, graft suspension fixation using suture anchors, and bone fragment compression using the infraspinatus tendon. We routinely use this technique in combined treatment procedures for complicated anterior shoulder instability.

Recurrent anterior shoulder dislocation is a common injury that typically occurs with labral or capsular injury as well as bony lesions of both the glenoid and humeral head.^{1,2} A common pathology of anterior shoulder dislocation, Hill-Sachs lesion was first described in 1940 as the impression left by dense cortical glenoid bone on cancellous bone of the posterolateral humeral head.³ In 2000, Burkhart and De Beer⁴ described the “engaging” Hill-Sachs lesion, which refers to a lesion that engages the rim of the glenoid when the shoulder is in abduction and external rotation. Recently, Yamamoto et al.⁵ expanded the concept of “engagement” by describing the “glenoid track” as the area of the humeral head that contacts the glenoid,

and noting that this footprint shifts with increased abduction, external rotation, and extension of the shoulder. The contact line of the anterior glenoid rim on the humeral head forms the medial edge of the glenoid track. When the medial edge of the Hill-Sachs lesion lies lateral to the medial edge of the glenoid track, the lesion is defined as on-track and non-engaging; on the contrary, when the medial edge of the Hill-Sachs lesion lies medial to the medial edge of the glenoid track, the lesion is defined as off-track and engaging.⁶

A variety of open or arthroscopic techniques have been introduced to treat “engaging” Hill-Sachs lesions, including humeroplasty or disimpaction that may only be possible in acute setting,^{7,8} rotational humeral osteotomy with the risk of nonunion and malunion,^{9,10} and arthroplasty (resurfacing arthroplasty, hemiarthroplasty) with the risk of prosthetic loosening.^{11,12} Arthroscopic remplissage,^{13,14} which has gained popularity because of its simplicity and good biomechanical and clinical outcomes, may not be suitable for throwing athletes because of consequent external rotation limitation,¹⁵ and is more applicable for shallow defects. Humeral head augmentation to restore native anatomy using osteochondral bone plugs or size-matched bulk allograft transfer is more suitable for deep defect.¹⁶

From the Operating Theatre (J.T.); and Department of Sports Medicine (C.X., J.Z.), Shanghai Sixth People’s Hospital, Shanghai Jiao Tong University, Shanghai, China.

The authors report the following potential conflicts of interest or sources of funding: J.Z. holds the patent of the shoulder bone grafting instruments (patent number: ZL 2014 1 0263721.1) described in this work. This research was funded by National Natural Science Foundation of China (NSFC), Grant No. 31400800 and 31370945. Full ICMJE author disclosure forms are available for this article online, as [supplementary material](#).

Received February 11, 2017; accepted June 26, 2017.

Address correspondence to Jinzhong Zhao, M.D., Department of Sports Medicine, Shanghai Sixth People’s Hospital, Shanghai Jiao Tong University, 600 Yishan Road, Shanghai 200233, China. E-mail: zhaojinzhong@vip.163.com

© 2017 by the Arthroscopy Association of North America. Published by Elsevier. This is an open access article under the CC BY-NC-ND license (<http://creativecommons.org/licenses/by-nc-nd/4.0/>).

2212-6287/17180

<http://dx.doi.org/10.1016/j.eats.2017.06.023>

Table 1. Indication and Contraindication

Attributes of a Hill-Sachs Lesion	On-/Off-track	Depth	Width
Indication	Off-track	≥8 mm	≥10 mm
Contraindication	On-track	<8 mm	<10 mm

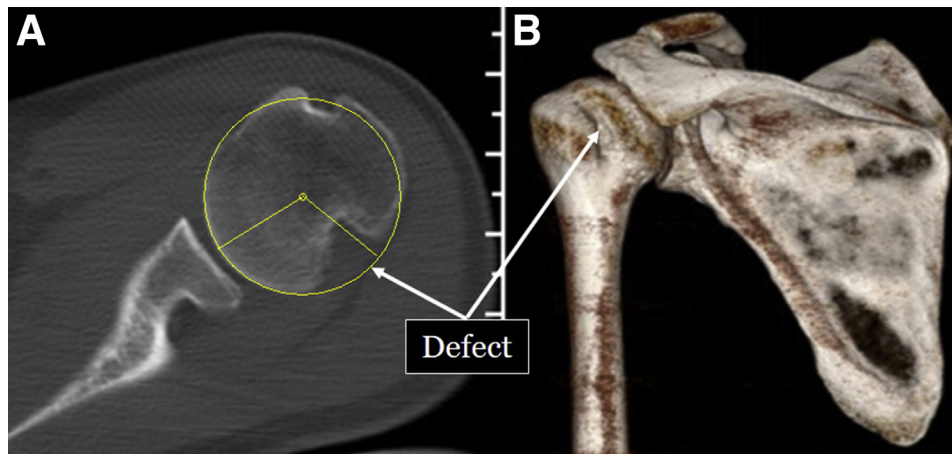


Fig 1. Preoperative computed tomography scans. (A) Cross-section of the left shoulder, showing a Hill-Sachs lesion measuring 14.9 mm in depth. (B) Three-dimensional reconstruction of the humeral head, showing the defect.

Table 2. Step-by-Step Surgical Procedure

1. Perform desired shoulder imaging studies before surgery (e.g. magnetic resonance imaging and computed tomography, with 3-dimensional reconstruction). Measure the size of the Hill-Sachs lesion on the images
2. Obtain a unicortical bone graft measuring 10 mm wide, 9 to 10 mm thick, and 30 mm long. Drill 2 holes through the graft approximately 15 mm apart
3. Place the patient in the lateral decubitus position under general anesthesia. Create posterior, anterior, and anterosuperior portals. Observe the Hill-Sachs lesion from the anterosuperior portal
4. Freshen the bone bed of the Hill-Sachs lesion and the area between the bone bed and rotator cuff insertion
5. Insert 2 double-loaded suture anchors through the posterior portal to the bottom of the groove of the Hill-Sachs lesion, placed approximately 15 mm apart
6. Insert the shoulder bone grafting instruments (guide pin, core bar, and trocar) through the posterior portal sequentially. Retrieve 1 suture limb from each of the 2 anchors out of the joint through the trocar to serve as guide sutures
7. Insert the sutures through the corresponding holes in the graft. Push the graft along the sutures into the trocar. Pass the guide sutures through the respective holes in the core bar
8. Push the graft through the trocar into the joint using the core bar. Release the graft from the trocar
9. Tie 2 sutures in their appropriate locations to tether the graft to the humeral head
10. Retrieve the remaining sutures from the medial to the posterior side of the graft and then through the infraspinatus tendon
11. After all other procedures, such as anterior glenoid bone grafting or Bankart repair, tie the remaining sutures on the infraspinatus tendon to compress the graft to the bone bed via the tendon

Table 3. Key Points, Pearls, and Pitfalls

Key Points

1. Indicated in patients with recurrent anterior shoulder instability and a deep and wide engaging Hill-Sachs lesion (at least 8 mm deep and 10 mm wide)
2. Freshen the bone bed and the area between the bone bed and rotator cuff insertion
3. Complete graft placement and tethering before reconstruction procedures, such as Bankart repair, at the anterior side
4. Use bone grafting instruments properly
5. Realize graft compression through a remplissage-like procedure

Pearls and pitfalls

1. Should be performed with the patient in the lateral decubitus position, with the arthroscope inserted through the anterosuperior portal to observe the Hill-Sachs lesion
2. When preparing the bone bed of the Hill-Sachs defect, it is important to be gentle and remove a minimal amount of surface bone to avoid sabotaging the bone
3. Two double-loaded suture anchors should be placed at appropriate locations
4. When placing the bone grafting instruments, leave the sutures at the medial side in the posterior portal to facilitate future suture management
5. The suture limb from the distal anchor should be inserted through the distal hole in the graft and then the distal hole in the core bar, and vice versa, to prevent suture tangling
6. Primary graft fixation is achieved with 1 suture from each anchor, whereas compression is realized with the other suture from each anchor
7. When a demineralized bone graft is used, a cortical layer over 1 mm thick is required. Otherwise, the graft will be too brittle and easily broken

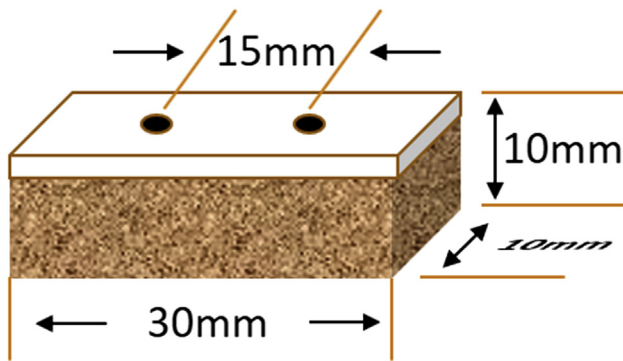


Fig 2. Preparation of the graft. A unicortical graft fragment measuring 30 mm long, 10 mm wide, and 9 to 10 mm thick is customized. Two 2-mm-wide holes, centered to the midline of the graft and placed approximately 15 mm apart, are drilled through the graft from the superior to the inferior side.

This Technical Note will describe a humeral head augmentation technique, an arthroscopic approach of humeral head bone grafting for the treatment of a deep Hill-Sachs lesion in a patient with anterior shoulder instability. The indication of the current technique is an off-track Hill-Sachs lesion that is at least 8 mm in depth and 10 mm in width. The contraindications of this technique include an on-track Hill-Sachs lesion that is less than 8 mm in depth and less than 10 mm in width (Table 1).

Surgical Technique

Preoperative Planning

Before surgery, magnetic resonance imaging and computed tomography are routinely performed. A 3-dimensional reconstruction of the computed tomography image is created. The size of the Hill-Sachs lesion is measured on the images via reconstructed contours of the humeral head (Fig 1). When the depth and width of

the Hill-Sachs lesion reach 8 and 10 mm, respectively, humeral head bone grafting is considered.

Surgical Procedure

Positioning, Portal Placement, and Diagnostic Arthroscopy. The patient is placed in the lateral decubitus position under general anesthesia (Video 1; Tables 2 and 3). Posterior, anterior, and anterosuperior portals are routinely fashioned, and disposable cannulas are placed. Arthroscopic examination is performed to detect all pathologies, and the Hill-Sachs lesion is addressed before all reconstruction procedures are performed. The arthroscope is inserted into the joint via the anterosuperior portal to observe the Hill-Sachs lesion. The size and location of the humeral head defect along with the width of the glenoid are measured to determine the on- and/or off-track properties of the lesion.

Graft Preparation

Regarding the bone graft, both autograft and allograft may be used; we routinely use a unicortical allograft (demineralized or fresh-frozen). The cortical side is used as the superior side, whereas the cancellous side is used as the inferior side and faces the bone bed after plantation. When an allograft is used, a graft fragment measuring 30 mm long, 10 mm wide, and 9 to 10 mm thick is customized.

When an autograft is used, a unicortical iliac crest bone graft is harvested. Two 2-mm-wide holes, centered to the midline of the graft and placed approximately 15 mm apart, are drilled through the graft from the superior to the inferior side using K-wires (Fig 2).

Anchor Placement

The bone bed of the Hill-Sachs lesion and the area between the bone bed and rotator cuff insertion are freshened using a burr or curet. Then, 2 double-loaded suture anchors are inserted through the posterior portal

Fig 3. Suture anchor placement. Two double-loaded suture anchors are inserted through the posterior portal to the bottom of the groove of the Hill-Sachs lesion, centered to the midpoint of the groove and placed approximately 15 mm apart (illustration of the left shoulder in the lateral decubitus position). (A) illustration; (B) arthroscopic view.

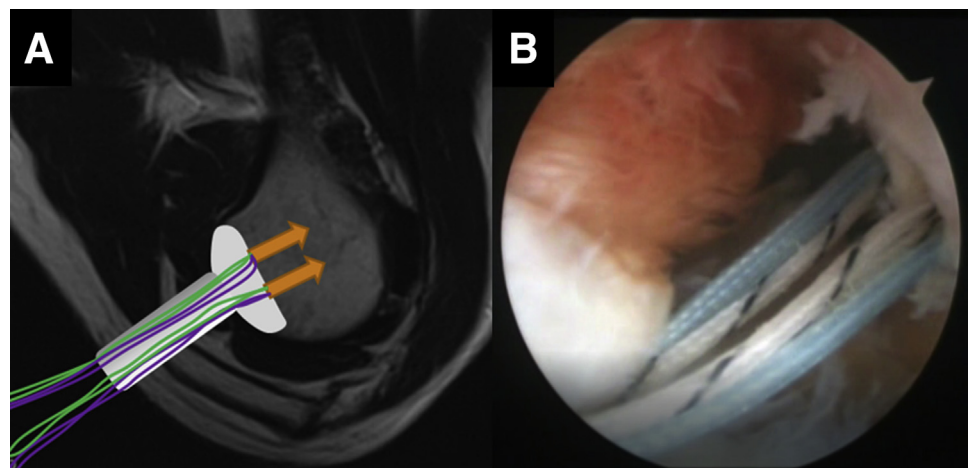




Fig 4. Three views of the core bar.

to the bottom of the groove of the Hill-Sachs lesion, centered to the midpoint of the groove and placed approximately 15 mm apart (Fig 3).

Grafting Instrument Placement

The cannula in the posterior portal is removed. With the sutures kept at the medial side of the posterior portal, the customized shoulder bone grafting instruments (patent number: ZL 2014 1 0263721.1),¹⁷ namely the guide pin, the core bar with 2 longitudinal holes (Fig 4), and the trocar (Fig 5), are sequentially inserted through the posterior portal (Fig 6). Then, the guide pin and core bar are removed to leave just the trocar.

Graft Placement

One suture limb from each of the 2 anchors is retrieved from the joint through the trocar to serve as guide sutures (Fig 7). The suture limb from the distal anchor is passed through the anterior hole of the graft, whereas that from the proximal anchor is passed through the posterior hole of the graft, from the inferior side to the superior side. Then, the graft is pushed along the sutures into the trocar. The suture limb from the distal anchor is passed through the anterior hole of the core bar, whereas that from the proximal anchor is passed through the posterior hole of the core bar. Afterward, the graft is pushed through the trocar into the joint along the guide sutures with the use of the core bar (Fig 8) and then released from the trocar into the joint (Fig 9). Next, the bone grafting trocar is removed and replaced with a routine disposable cannula.

Graft Fixation and Tendon Compression

The 2 guide suture limbs are tied to their counter limbs, which are passed around the medial side of the graft, to tether the graft to the defect groove of the



Fig 5. Two views of the trocar.




Fig 6. The trocar within the core bar.

humeral head (Fig 10). The remaining sutures are retrieved through the infraspinatus tendon, as in routine remplissage, from the medial to the posterior side of the graft. After all other indicated reconstruction procedures at the anterior side of the shoulder, such as glenoid bone grafting or Bankart repair, the remaining sutures are tied on the infraspinatus tendon in the subacromial space to compress the graft to the bone bed via the tendon (Fig 11). After final intra-articular and subacromial examination, all portals are closed.

Postoperative Care

Computed tomography is performed immediately after surgery to confirm the position of the graft (Fig 12). Postoperatively, the arm is kept in neutral external rotation with a brace for 6 weeks. From the seventh week, passive range-of-motion exercise begins. Active range-of-motion exercise and muscle-strengthening exercise begin in the fourth month.

Key steps of this procedure are outlined in Table 1, and key points, pearls, and pitfalls are noted in Table 2.

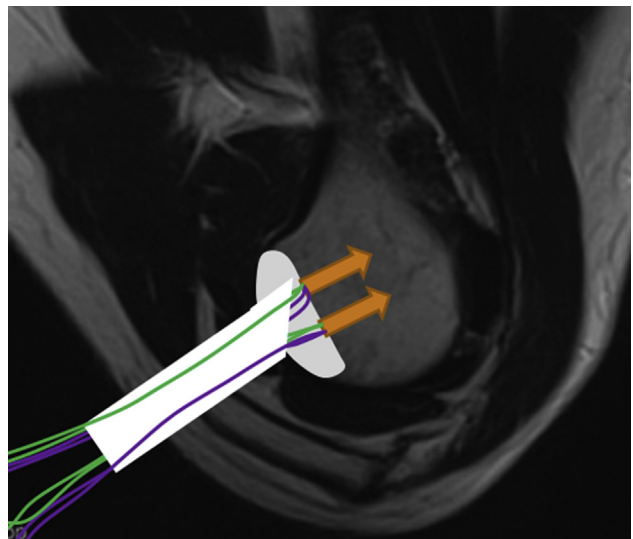


Fig 7. Guide suture retrieval. One suture limb from each of the 2 anchors is retrieved from the joint through the trocar to serve as guide sutures, with all the other sutures kept at the medial side of trocar (illustration of the left shoulder in the lateral decubitus position).

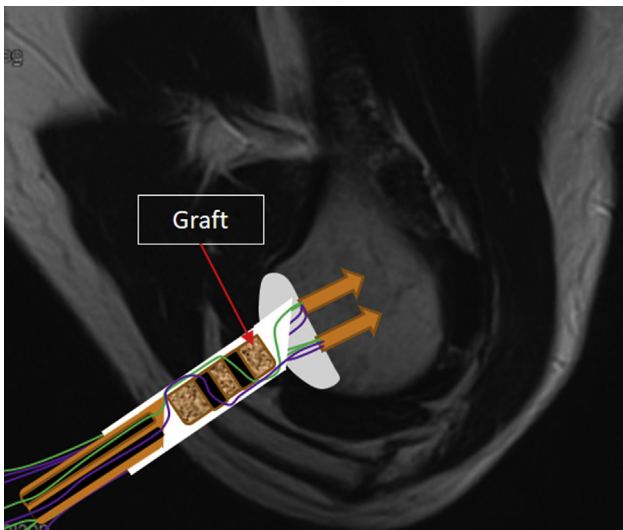


Fig 8. Graft placement through the trocar. The suture limb from the distal anchor is passed through the anterior hole of the graft and the anterior hole of the core bar, whereas that from the proximal anchor is passed through the posterior hole of the graft and the posterior hole of the core bar. The graft is pushed along the sutures into the trocar (illustration of the left shoulder in the lateral decubitus position).

Discussion

Hill-Sachs lesion is one of the most common pathologies of anterior shoulder dislocation. Several clinical and biomechanical studies have confirmed that engaging Hill-Sachs lesions are prone to recurrence.^{18,19} A variety of anatomic and nonanatomic reconstruction techniques have been developed to address large, deep, and engaging Hill-Sachs lesions, with both effectiveness and potential complications, such as implant failure, allograft nonunion, glenohumeral arthritis, and high medical cost.⁷⁻¹⁶

Various open and arthroscopic reconstruction procedures for Hill-Sachs lesion have been described.

Yagishita and Thomas,²⁰ in 2002, reported an open allograft reconstruction of large, deep Hill-Sachs lesions associated with anterior shoulder dislocation using a structural femoral allograft. Miniaci and Gish²¹ reported a larger cohort study in which 18 patients with recurrent anterior shoulder instability and large Hill-Sachs defects underwent osteochondral transplantation with a fresh-frozen allograft. During the follow-up, most patients regained full range of motion and reported no further apprehension or instability. However, several complications were detected, including partial graft collapse, hardware retrieval, and early radiologic evidence of osteoarthritis. Considering the potential complications of an open procedure, arthroscopic allograft reconstruction was developed. Chapovsky and Kelly²² described the case of a 16-year-old patient with a large Hill-Sachs lesion who underwent revision arthroscopic allograft mosaicplasty together with anterior capsular plication. Snir et al.²³ introduced an all-arthroscopic approach for anatomic humeral head reconstruction with osteochondral allograft transplantation.

Arthroscopic remplissage is the most common treatment for a Hill-Sachs lesion. A large number of clinical trials and biomechanical studies have confirmed fewer complications, less recurrence of dislocation, and minimal loss of shoulder range of motion with this procedure.^{14,24,25} Although a systematic review, by Longo et al.,²⁶ concluded that arthroscopic remplissage was the safest technique for the management of shoulder instability with humeral bone loss, an associated loss of external rotation precludes its suitability to all population,¹⁵ especially to throwing athletes.

The current technique is a modification of allograft reconstruction combined with remplissage. This modified procedure has several advantages: (1) simplification of graft preparation—only 2 holes are needed to be drilled into the graft; (2) simplification of graft fixation—nonrigid fixation using 2 sutures from the anchors; (3) use of the

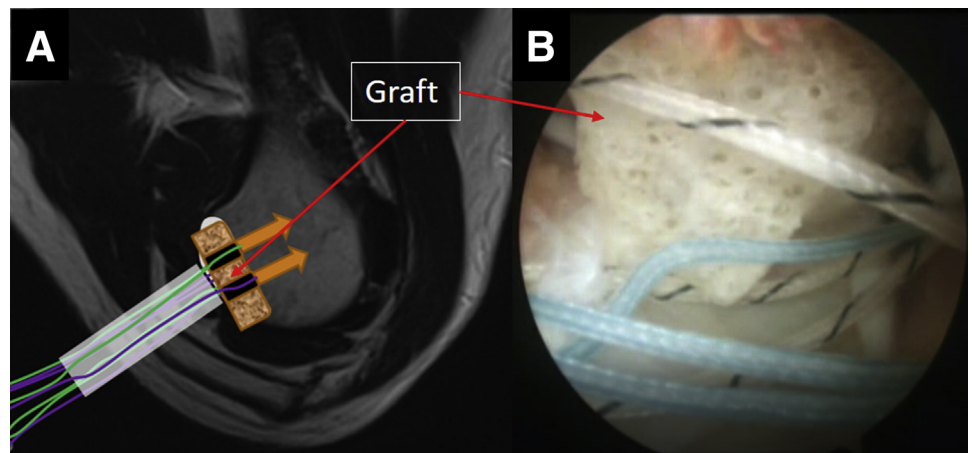


Fig 9. Graft released from the trocar into the joint. (A) Illustration of the left shoulder in the lateral decubitus position; (B) left shoulder viewing through the anterosuperior portal.

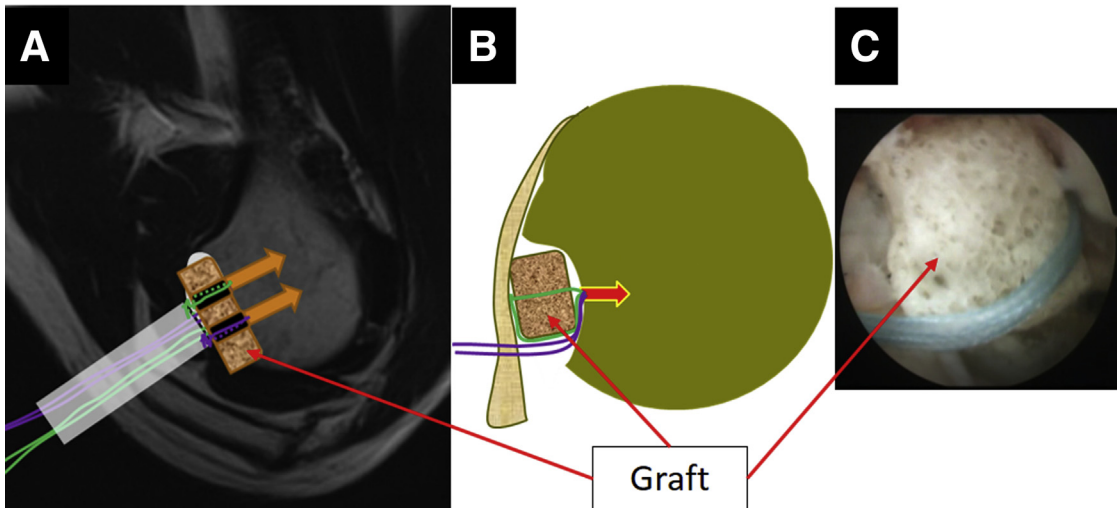


Fig 10. Graft fixation. The 2 guide suture limbs are tied to their counter limbs, which are passed around the medial side of the graft, to tether the graft to the defect groove of the humeral head. (A) Sagittal view illustration; (B) axial view illustration; (C) arthroscopic view of the left shoulder from the anterosuperior portal.

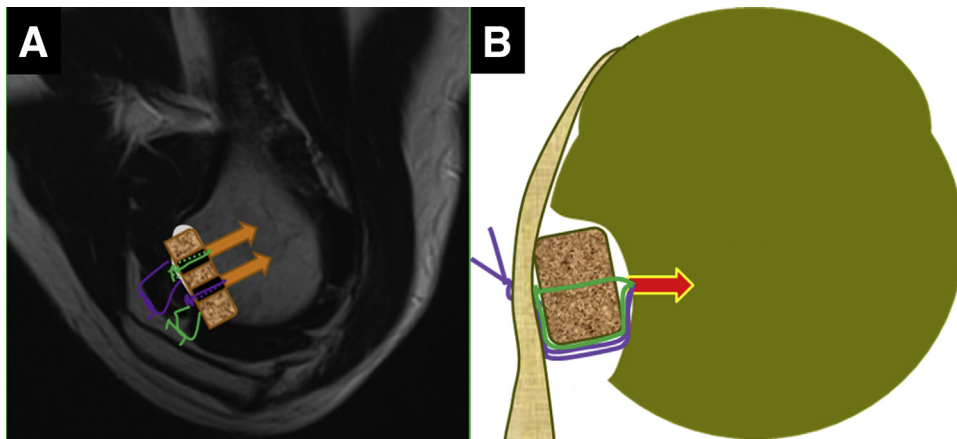
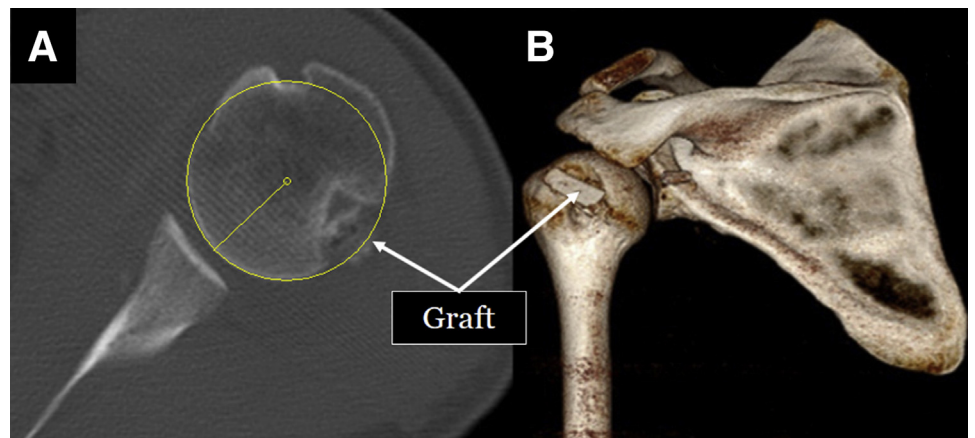


Fig 11. Tendon compression in the left shoulder. The remaining sutures are tied on the infraspinatus tendon in the sub-acromial space to compress the graft to the bone bed via the tendon. (A) Sagittal view illustration; (B) axial view illustration.

Fig 12. Postoperative computed tomography scans. (A) Cross-section of the shoulder after surgery, showing the defect filled with bony tissue. (B) Three-dimensional reconstruction of the shoulder after surgery, showing the graft.



remplissage technique for graft compression; and (4) high feasibility—it takes a senior sports medicine surgeon 15 to 20 min to accomplish the bone grafting procedure.

References

- Widjaja AB, Tran A, Bailey M, Proper S. Correlation between Bankart and Hill-Sachs lesions in anterior shoulder dislocation. *ANZ J Surg* 2006;76:436-438.
- Kurokawa D, Yamamoto N, Nagamoto H, et al. The prevalence of a large Hill-Sachs lesion that needs to be treated. *J Shoulder Elbow Surg* 2013;22:1285-1289.
- Hill HA, Sachs MD. The grooved defect of the humeral head: A frequently unrecognized complication of dislocations of the shoulder joint. *Radiology* 1940;35:11.
- Burkhart SS, De Beer JF. Traumatic glenohumeral bone defects and their relationship to failure of arthroscopic Bankart repairs: Significance of the inverted-pear glenoid and the humeral engaging Hill-Sachs lesion. *Arthroscopy* 2000;16:677-694.
- Yamamoto N, Itoi E, Abe H, et al. Contact between the glenoid and the humeral head in abduction, external rotation, and horizontal extension: A new concept of glenoid track. *J Shoulder Elbow Surg* 2007;16:649-656.
- Di Giacomo G, Itoi E, Burkhart SS. Evolving concept of bipolar bone loss and the Hill-Sachs lesion: From “engaging/non-engaging” lesion to “on-track/off-track” lesion. *Arthroscopy* 2014;30:90-98.
- Ratner D, Backes J, Tokish JM. Arthroscopic reduction and balloon humeroplasty in the treatment of acute Hill-Sachs lesions. *Arthrosc Tech* 2016;5:e1327-e1332.
- Re P, Gallo RA, Richmond JC. Transhumeral head plasty for large Hill-Sachs lesions. *Arthroscopy* 2006;22:798.e1-798.e4.
- Weber BG, Simpson LA, Hardegger F. Rotational humeral osteotomy for recurrent anterior dislocation of the shoulder associated with a large Hill-Sachs lesion. *J Bone Joint Surg Am* 1984;66:1443-1450.
- Brooks-Hill AL, Forster BB, van Wyngaarden C, Hawkins R, Regan WD. Weber osteotomy for large Hill-Sachs defects: Clinical and CT assessments. *Clin Orthop Relat Res* 2013;471:2548-2555.
- Armitage MS, Faber KJ, Drosdowech DS, Litchfield RB, Athwal GS. Humeral head bone defects: Remplissage, allograft, and arthroplasty. *Orthop Clin North Am* 2010;41:417-425.
- Pritchett JW, Clark JM. Prosthetic replacement for chronic unreduced dislocations of the shoulder. *Clin Orthop Relat Res* 1987;216:89-93.
- Purchase RJ, Wolf EM, Hobgood ER, Pollock ME, Smalley CC. Hill-Sachs “remplissage”: An arthroscopic solution for the engaging Hill-Sachs lesion. *Arthroscopy* 2008;24:723-726.
- Hartzler RU, Bui CN, Jeong WK, et al. Remplissage of an off-track Hill-Sachs lesion is necessary to restore biomechanical glenohumeral joint stability in a bipolar bone loss model. *Arthroscopy* 2016;32:2466-2476.
- Omi R, Hooke AW, Zhao KD, et al. The effect of the remplissage procedure on shoulder range of motion: A cadaveric study. *Arthroscopy* 2014;30:178-187.
- Kropf EJ, Sekiya JK. Osteoarticular allograft transplantation for large humeral head defects in glenohumeral instability. *Arthroscopy* 2007;23:322.e1-322.e5.
- Zhao J, Huangfu X, Yang X, Xie G, Xu C. Arthroscopic glenoid bone grafting with nonrigid fixation for anterior shoulder instability: 52 patients with 2- to 5-year follow-up. *Am J Sports Med* 2014;42:831-839.
- Cetik O, Uslu M, Ozsar BK. The relationship between Hill-Sachs lesion and recurrent anterior shoulder dislocation. *Acta Orthop Belg* 2007;73:175-178.
- Bakshi NK, Jolly JT, Debski RE, Sekiya JK. Does repair of a Hill-Sachs defect increase stability at the glenohumeral joint? *Orthop J Sports Med* 2016;4:2325967116645091.
- Yagishita K, Thomas BJ. Use of allograft for large Hill-Sachs lesion associated with anterior glenohumeral dislocation. A case report. *Injury* 2002;33:791-794.
- Miniaci A, Gish MW. Management of anterior glenohumeral instability associated with large Hill-Sachs defects. *Tech Shoulder Elbow Surg* 2004;5:170-175.
- Chapovsky F, Kelly JD IV. Osteochondral allograft transplantation for treatment of glenohumeral instability. *Arthroscopy* 2005;21:1007.
- Snir N, Wolfson TS, Hamula MJ, Gyftopoulos S, Meislin RJ. Arthroscopic anatomic humeral head reconstruction with osteochondral allograft transplantation for large Hill-Sachs lesions. *Arthrosc Tech* 2013;2:e289-e293.
- Merolla G, Paladini P, Di Napoli G, Campi F, Porcellini G. Outcomes of arthroscopic Hill-Sachs remplissage and anterior Bankart repair: A retrospective controlled study including ultrasound evaluation of posterior capsulotenodesis and infraspinatus strength assessment. *Am J Sports Med* 2015;43:407-414.
- Cho NS, Yoo JH, Rhee YG. Management of an engaging Hill-Sachs lesion: Arthroscopic remplissage with Bankart repair versus Latarjet procedure. *Knee Surg Sports Traumatol Arthrosc* 2016;24:3793-3800.
- Longo UG, Loppini M, Rizzello G, et al. Remplissage, humeral osteochondral grafts, weber osteotomy, and shoulder arthroplasty for the management of humeral bone defects in shoulder instability: Systematic review and quantitative synthesis of the literature. *Arthroscopy* 2014;30:1650-1666.