




Obstructive Sleep Apnea Treatment with Oral Appliance in a Myotonic Dystrophy Type I Subject: A Case Report

Maria de Lourdes Rabelo Guimarães¹ Milena Carvalho Tourino Ribeiro²
Thiago Antunes da Silva Barbosa² Laila Gabriela de Figueiredo Costa³  Patricia Souza Bastos⁴

¹ Universidade Federal de Minas Gerais, Centro de Tecnologia em Medicina Molecular, Belo Horizonte, Minas Gerais, Brazil.

² Centro Universitário de Belo Horizonte, Faculty of Dentistry, Belo Horizonte, Minas Gerais, Brazil.

³ Newton Paiva, Faculty of Dentistry, Belo Horizonte, Minas Gerais, Brazil.

⁴ Rede Sarah de Hospitais de Reabilitação, Setor de Eletrodiagnósticos, Belo Horizonte, Minas Gerais, Brazil.

Address for correspondence Maria de Lourdes Rabelo Guimarães, Universidade Federal de Minas Gerais, Centro de Tecnologia em Medicina Molecular, Belo Horizonte, Minas Gerais 30130-100, Brazil (email: mlourdesrg@gmail.com).

Sleep Sci 2023;16(3):e375–e380.

Abstract

Keywords

- ▶ myotonic dystrophy type 1
- ▶ sleep apnea syndromes
- ▶ sleepiness
- ▶ oral appliance
- ▶ biomarker
- ▶ therapeutics

Objective to report a myotonic dystrophy type 1 (MD1) subject with obstructive sleep apnea syndrome treated with oral appliance.

Methods A review of individual's history and records, associated with a photographic register of all diagnostic methods and literature research about the topic were done.

Final Statements This case depicts the therapeutical choices disposable to treat subjects with obstructive sleep apnea and DM1. Although considered an uncommon treatment, the oral appliances, if well indicated in adequately selected cases, can satisfactorily improve respiratory parameters, symptoms and quality of life.

Introduction

Myotonic dystrophy type I (MD1) is a hereditary condition caused by an abnormal expansion of cytosine-thymine-guanine (CTG) repeats, located in the myotonic dystrophy protein kinase gene (*DMPK*).¹ This condition can cause respiratory impairment due to a neuromuscular condition and central ventilatory control derangement.² It is a rare disease, with multisystemic involvement and a great variety of phenotypic expressions, affecting from 1/3,000 to 1/8,000 people in the world.³ The respiratory system impairment is related to respiratory and pharyngeal muscle weakness, and

obstructive sleep apnea syndrome (OSAS)⁴ and alveolar hypoventilation can occur.

Since respiratory and cardiac diseases are common causes of death in MD1 individuals, the control of comorbidities like OSAS will promote quality of life, cardiovascular health, and survival rates.⁵

Continuous positive air pressure (CPAP)⁶ is often necessary to treat MD1 subjects with OSAS without hypoventilation. Despite being considered the gold pattern of OSAS treatment, poor compliance has been observed.⁷ Oral appliances (OA) are good options to treat mild/moderate apnea and it has been proven to be effective with better compliance.⁸ These devices

received
October 18, 2021
accepted
December 5, 2022

DOI <https://doi.org/10.1055/s-0043-1772817>.
ISSN 1984-0659.

© 2023. Brazilian Sleep Association. All rights reserved.
This is an open access article published by Thieme under the terms of the Creative Commons Attribution-NonDerivative-NonCommercial-License, permitting copying and reproduction so long as the original work is given appropriate credit. Contents may not be used for commercial purposes, or adapted, remixed, transformed or built upon. (<https://creativecommons.org/licenses/by-nc-nd/4.0/>)
Thieme Revinter Publicações Ltda., Rua do Matoso 170, Rio de Janeiro, RJ, CEP 20270-135, Brazil

advance and stabilize the jaw, improving the upper airway patency during sleep.⁹

Case Report

Anamnesis

A woman, 30-years-old, with MD1, was referred from the sleep doctor to the dentist for OSAS treatment. There were no comorbidities. She reported diurnal somnolence (DS) with 1 to 2 hours of naps necessary in the morning and afternoon. The Epworth scale score was 15. The patient also described nocturnal snoring, gasping, bruxism, and sometimes initial insomnia. She claimed to be bothered by coughing during sleep and by a delayed sleep-wake phase. Furthermore, the patient reported symptoms like tongue myotony and leg pains related to DM1.

She was submitted to tonsillectomy at infancy. The recent spirometry was normal. She takes fluoxetine regularly and has never been treated for OSAS. The patient is married, childless, and a housewife. She was followed by a neurologist, cardiologist, and pneumologist. Her father and sister were also diagnosed with MD1.

Clinical Findings

The patient had been submitted to orthodontic treatment during her infancy. There was pain during masticatory muscles palpation, and bilateral temporomandibular joint clicking (TMJ). She also presented with hypotonic and enlarged tongue, ogival palate, maxillary atresia, oroscopy with mallampati level IV, soft palate hypotony, and angle class I malocclusion.

► **Table 1** depicts the timeline of the conducts adopted. Appointments were realized to gradual advances of the oral appliance and sleep apnea type III monitoring, ApneaLink Air (ResMed, San Diego, CA, USA).

Diagnostic Approach

The MD1 diagnosis was confirmed clinically and by a genetic test, using molecular biology to detect anomalous expansion of CTC repeat of *DMPK* gene.

The polysomnography (PSG), a type I sleep study, results showed moderate obstructive sleep apnea (apnea-hypopnea index [AHI], 22.2 events/h, SpO₂ minimum 88%).

Therapeutic Intervention

The treatment of MD1 is symptomatic since there is no modified therapy, and an interdisciplinary approach is essential. Systemic non-neuromuscular manifestations are the most treatable symptoms of the disease.⁴

Non-hypoventilated patients with OSAS can be treated with both CPAP and OA. The absence of hypoventilation is mandatory for this choice of therapy.

The type o device chosen was the PLP-lateroprotrusive plaque of jaw advancement,¹⁰ installed with a vertical dimension of 2 mm and 50% of the maximum protrusion. The progressive advancements happened every 15 days, with an increment between 0.5 and 1 mm until the individual's maximum protrusion was reached.

Follow-up and Results

Teleradiography and cephalometric measures were performed with and without the device (► **Fig. 2**).

► **Table 2** depicts cephalometric measures with and without OA. In cases with OA we observed increased median posterior-palatal space, middle pharyngeal space, hyoid-third vertebrae distance, hyoid-mandibular plane distance, and reduction of tongue height. However, there was a reduction of the upper pharyngeal space and inferior airway space.

Even at the beginning of treatment, the patient reported elimination of nocturnal cough and persistence of excessive daytime sleepiness (EDS).

After compliance and necessary adjustments, the patient was submitted to a diagnostic test type III, with the ApneaLink Air (ResMed). Finally, she underwent a polysomnography type I for therapeutic control (► **Table 3**).

There were sleep improvement and snoring control with the OA use. A reduction of the arousal index (from 52.3 to 37.5/h) was also reported, as well as arousal related to respiratory index (from 15.3 to 3.4/h), and slight improvement of sleep architecture (N3 from 13.3 to 15.9/h; rapid eye movement

Table 1 Treatment timeline

Date	Procedure
10/06/2020	Initial appointment.
10/16/2020	Appliance advancement of 2 and 4 mm (vertical dimension).
10/30/2020	No complaints; appliance advancement of 1 mm.
11/18/2020 to 01/07/2021	Gradual adjustments. Teeth pain complaints and dry mouth. Cough and sleep quality improvement.
01/21/2021	ApneaLink: AHI: 5.7/h, RI: 7.0/h, sat. min.: 85.0%, 1%, below 90.0%.
01/26/2021 to 02/09/2021	More adjustments. Difficulty to lick the lips and tight teeth sensation. Cough resolution.
02/11/2021	ApneaLink: AHI: 4.7/h, RI: 6.0/h, sat. min.: 85.0%, 4.0%, below 90.0%.
03/16/2021	PSG type I with OA showed AHI: 5.9/h, sat. min.: 88.0%. Control appointment after 6 months (2021, September).

Abbreviations: AHI, apnea-hypopnea index; RI, risk index; PSG, polysomnography; OA, oral appliances.

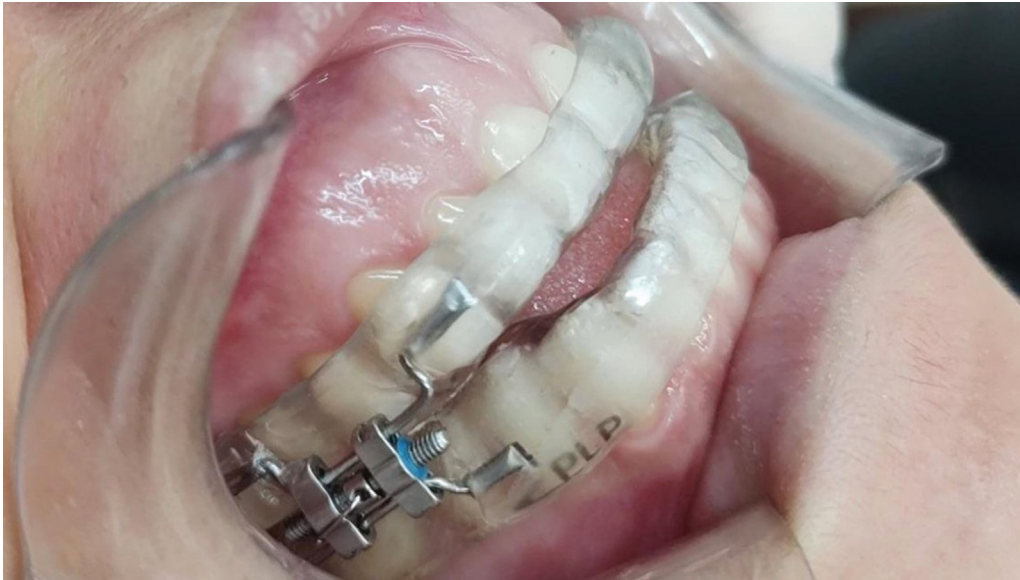

Fig. 1 Oral appliance in situ.

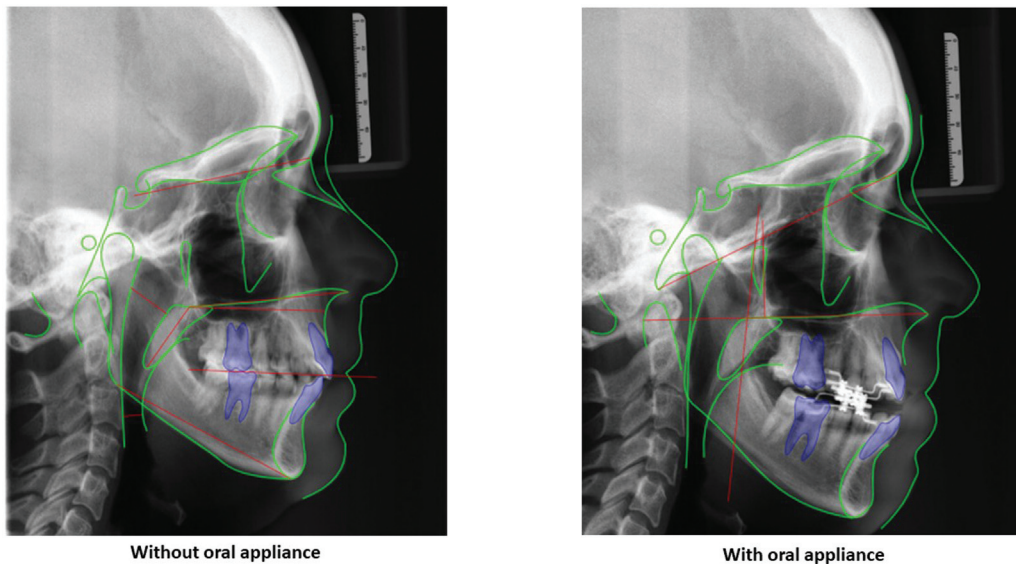


Fig. 2 Teleradiography with and without OA.

sleep (REM) stage from 7.5 to 10.7/h). Clinical and dental controls will be done at 6-months to verify compliance, recurrence of symptoms, and therapy side effects.

Compliance with OA treatment was self-reported. The main side effects reported were teeth discomfort, which was solved with wearing in the plaque, and dry mouth, which did not persist after a few days.

Discussion

Diagnosis and early treatment of OSAS can improve the quality of life of MD1 patients and extend survival time. Treatment with OA is an alternative to CPAP that can result in auspicious outcomes. The case reported here chose the use of OA¹¹ due to its simplicity.

Improvement of respiratory events was observed with OA, which is in agreement with Ramar et al., who reported a reduction of > 50% of the ODI in their studies.¹² Additionally, the REM and N3 stages improved slightly, which is also in consonance with Ramar et al.'s report that OA treatment does not have a significant effect on sleep architecture.¹² However, in our study, there was improvement in the arousal index related to respiratory events, which was not reported by them.

People with MD1 report poor sleep quality and EDS.⁵ The case reported here persisted with EDS, despite the satisfactory treatment displayed at last PSG. As for EDS, this symptom usually does not correspond to the OSAS degree of severity in individuals with MD1, which implies a possible central etiology and tends to persist after appropriate CPAP treatment.⁵

Table 2 Cephalometric measures with and without the patient wearing OA

Description	Without device	With device	Normal/Class
	Value	Value	
Anterior cranial base	66.19	65.69	73 ± 3
Maxillary length	58.53	58.28	54 ± 3
Mandibular length	72.70	70.54	74 ± 5
Atlas-maxilla distance	31.60	33.10	36 ± 3
Upper pharyngeal space	16.17	13.92	24 ± 3.5
Median posterior-palatal Space	9.0	10.46	14 ± 2
Soft palate length	27.35	27.78	35 ± 4.5
Middle pharyngeal space	23.27	26.78	21 ± 3.5
PAS	16.89	11.81	13 ± 2.5
Hyoid-third vertebrae distance	–	72.70	36 ± 3
Hyoid-mandibular plane distance	–	26.09	15 ± 3
TGL	69.33	70.51	72.5 ± 3
TGH	30.44	23.32	24 ± 3
IAS	6.68	5.17	13.5 ± 2

Abbreviations: IAS, inferior airway space; PAS, posterior airway space; TGH, tongue height; TGL, tongue length.

Table 3 Monitoring results of type III diagnostic test and type I PSG showing respiratory events

Age	BMI	PSG data	AHI (ev/h)	AI	HI	SpO ₂ average	SpO ₂ Min	% Time < 90%	ODI
30	19.5	09/16/2020	22.2	9.5	12.7	95	88	0.2	11.4
30	20	01/21/2021	5.7	3.5	2.3	94	85	1	5.4
30	20	02/10/2021	4.7	3.5	1.2	94	85	4	4.6
30	20.3	02/25/2021	5.9	0.3	5.6	96.5	88	0.2	4.3

Abbreviations: % Time < 90%, percentage of time O₂ saturation below 90%; AI, apnea index; AHI, apnea/hypopnea index; HI, hypopnea index; IDO, O₂ desaturation index; SpO₂ average, SpO₂ minimum.

Cephalometric analysis only brings modest benefits to identify a successful predictor of DRS treatment with OA.¹³ However, we found cephalometric changes when comparing our patient with and without wearing the OA. A greater reduction in the apnea-hypopnea index (AHI) is related to a greater reduction in the distance from the hyoid-mandibular plane with the use of the oral appliance,¹⁴ which is in consonance with our results. A shorter anterior base of the skull translates into a smaller decrease of the AHI results.¹⁵ However, in the present study, despite having a reduced cranial base, the subject presented a significant decrease in the AHI. The increase in the tongue's dimensions can displace the hyoid inferiorly and increase the distance from the hyoid-mandibular plane, increasing the index's results.¹⁶ In our study, the patient had an increased tongue height, but with the use of OA, this height was reduced, which may have contributed to the improvement in the AHI.

We used a type III testing to monitor treatment and avoid multiple sleep laboratory polysomnography. Because the treatment efficacy must not be based only on type III studies,¹⁷ a type I PSG control was included.

Related side effects (discomfort in teeth and dry mouth) were considered mild and OA use was not discontinued. Since these side effects can worsen with time,^{18,19} a follow-

up was scheduled after 6-months to check the occurrence of craniofacial or occlusion changes.

Our study presented a follow-up time limitation (5-months). However, a clinical evaluation and a polysomnographic study will be done at 6-months. Despite the existence of objective measures that define OA compliance, they are not usually applied. The compliance criterion employed in our study was the patient's concern of being unable to sleep with OA.

Conclusion

The case reported and the literature review brought up the complex discussion about OSAS in MD1 patients. Although it is not the most common treatment, for select patients and when properly conducted by an expert, OA can successfully treat OSAS, allowing for improvement of respiratory patterns, disease symptoms, and quality of life.

Funding Source

No.

Conflict of Interests

The authors have no conflict of interests to declare.

References

- 1 Udd B, Krahe R. The myotonic dystrophies: molecular, clinical, and therapeutic challenges. *Lancet Neurol* 2012;11(10):891–905
- 2 Poussel M, Thil C, Kaminsky P, et al. Lack of correlation between the ventilatory response to CO₂ and lung function impairment in myotonic dystrophy patients: evidence for a dysregulation at central level. *Neuromuscul Disord* 2015;25(05):403–408
- 3 Ashizawa T, Gagnon C, Groh WJ, et al. Consensus-based care recommendations for adults with myotonic dystrophy type 1. *Neurol Clin Pract* 2018;8(06):507–520
- 4 Wenninger S, Montagnese F, Schoser B. Core clinical phenotypes in myotonic dystrophies. *Front Neurol* 2018;9:303
- 5 Bhat S, Gupta D, Chokroverty S. Sleep disorders in neuromuscular diseases. *Neurol Clin* 2012;30(04):1359–1387
- 6 Gutiérrez Gutiérrez G, Díaz-Manera J, Almendrote M, et al. Clinical guide for the diagnosis and follow-up of myotonic dystrophy type 1, MD1 or Steinert's disease. *Med Clin (Barc)* 2019;153(02):82.e1–82.e17
- 7 Barnes M, McEvoy RD, Banks S, et al. Efficacy of positive airway pressure and oral appliance in mild to moderate obstructive sleep apnea. *Am J Respir Crit Care Med* 2004;170(06):656–664
- 8 Lim J, Lasserson TJ, Fleetham J, Wright J. Oral appliances for obstructive sleep apnoea. *Cochrane Database Syst Rev* 2006;2006(01):CD004435
- 9 Mogell K, Blumenstock N, Mason E, Rohatgi R, Shah S, Schwartz D. Definition of an Effective Oral Appliance for the Treatment of Obstructive Sleep Apnea and Snoring: An Update for 2019. *J Dent Sleep Med* 2019;6(03):
- 10 Guimarães MLR, Oliveira JJM, Azevedo PG. Aparelho PLP para tratamento de ronco e apnéia obstrutiva do sono. *Orthod. Sci. Pract.* 2015;8(29):113–117
- 11 Hoffstein V. Review of oral appliances for treatment of sleep-disordered breathing. *Sleep Breath* 2007;11(01):1–22
- 12 Ramar K, Dort LC, Katz SG, et al. Clinical practice guideline for the treatment of obstructive sleep apnea and snoring with oral appliance therapy: an update for 2015. *J Clin Sleep Med* 2015;11(07):773–827
- 13 Petri N, Christensen IJ, Svanholt P, Sonnesen L, Wildschjødtz G, Berg S. Mandibular advancement device therapy for obstructive sleep apnea: a prospective study on predictors of treatment success. *Sleep Med* 2019;54:187–194
- 14 Poon KH, Chay SH, Chiong KF. Airway and craniofacial changes with mandibular advancement device in Chinese with obstructive sleep apnoea. *Ann Acad Med Singap* 2008;37(08):637–644
- 15 Liu Y, Zeng X, Fu M, Huang X, Lowe AA. Effects of a mandibular repositioner on obstructive sleep apnea. *Am J Orthod Dentofacial Orthop* 2000;118(03):248–256
- 16 Chi L, Comyn FL, Mitra N, et al. Identification of craniofacial risk factors for obstructive sleep apnoea using three-dimensional MRI. *Eur Respir J* 2011;38(02):348–358
- 17 Rosen IM, Kirsch DB, Chervin RD, et al; American Academy of Sleep Medicine Board of Directors. Clinical use of a home sleep apnea test: an American Academy of Sleep Medicine position statement. *J Clin Sleep Med* 2017;13(10):1205–1207
- 18 Doff MH, Hoekema A, Pruim GJ, Huddleston Slater JJ, Stegenga B. Long-term oral-appliance therapy in obstructive sleep apnea: a cephalometric study of craniofacial changes. *J Dent* 2010;38(12):1010–1018
- 19 Tsuda H, Almeida FR, Tsuda T, Moritsuchi Y, Lowe AA. Craniofacial changes after 2 years of nasal continuous positive airway pressure use in patients with obstructive sleep apnea. *Chest* 2010;138(04):870–874

