



Since January 2020 Elsevier has created a COVID-19 resource centre with free information in English and Mandarin on the novel coronavirus COVID-19. The COVID-19 resource centre is hosted on Elsevier Connect, the company's public news and information website.

Elsevier hereby grants permission to make all its COVID-19-related research that is available on the COVID-19 resource centre - including this research content - immediately available in PubMed Central and other publicly funded repositories, such as the WHO COVID database with rights for unrestricted research re-use and analyses in any form or by any means with acknowledgement of the original source. These permissions are granted for free by Elsevier for as long as the COVID-19 resource centre remains active.

**Dermoscopy of chilblain-like lesions during the COVID-19 outbreak: A multicenter study on 10 patients**



*To the Editor:* We recently reported 63 patients who developed chilblain-like lesions (CBL) during the COVID-19 pandemic, but the association with severe acute respiratory syndrome coronavirus 2 has not been proven.<sup>1</sup> Because most patients' information was not previously obtained by in-person visits by the investigators, dermoscopy was not available.

Ten patients with CBL were recruited from April 1 to 15, 2020 (Table I). There were 7 male and 3 female patients, with a median age of 13 years (range, 11-20 y). The feet were mostly affected (8/10 patients). The erythematous-edematous type was seen in 8 of 10 patients, and the blistering type was observed in 2 of 10 patients. The median time to diagnosis was 13 days (range, 6-34 d). Patients were otherwise healthy, and COVID-19 status, when

investigated through swab (1/10) or serology (2/10), was negative.

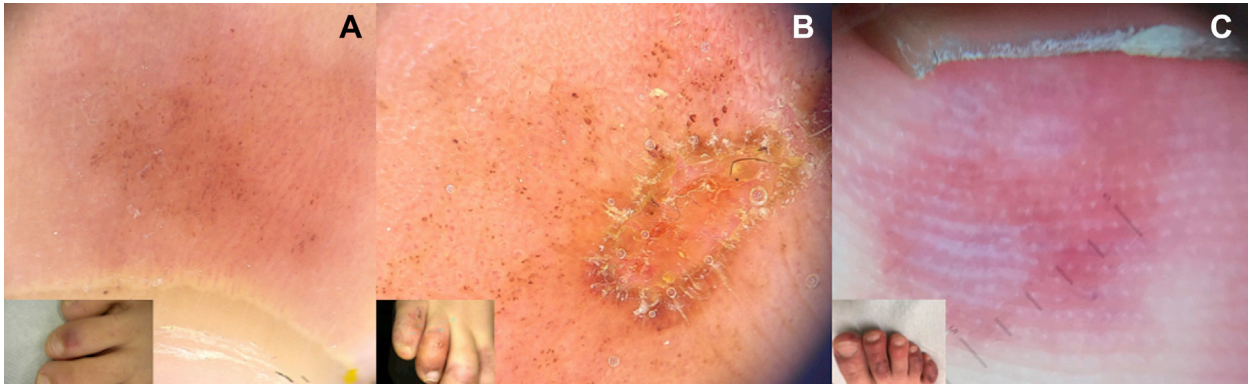Dermoscopy evaluated background color, vessels, and additional features. Background color was coppery red in 6 of 10 and red in 4 of 10 patients. Erythema was blanching in early cases, and it did not disappear in long-standing red-purple lesions. In plantar lesions, erythema mostly involved ridges. Vessels were seen in all patients. Hemorrhagic dots were commonly detectable (6/10); nonblanching blurred dotted, linear, glomerular, and irregular vessels were occasionally found. Additional features, including crusts and whitish areas, were seen in the blistering type (Figs 1 and 2).

Because there was an outbreak of CBL, it was quite logical to think about a causal relationship between COVID-19 and CBL, although poor data about patients' COVID status did not allow us to confirm this supposition.<sup>1,2</sup> Most patients were adolescents, and only a minority presented mild

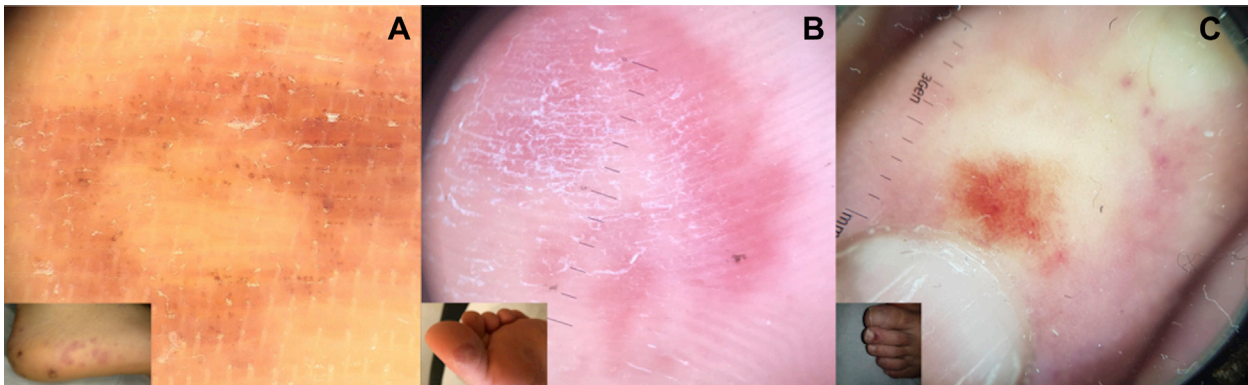
**Table I.** Patients' characteristics

Patient	Sex	Age, y	Location	Time to diagnosis, d	Clinical type	Dermoscopy		
						Background	Vessels	Other findings
1	M	20	Feet	14	Erythematous-edematous	Erythematous	Dotted	—
2	M	11	Feet	33	Erythematous-edematous	Erythematous	Linear	—
3	M	13	Feet	34	Blistering	Coppery red	Hemorrhagic dots, linear	—
4	F	12	Feet	10	Erythematous-edematous	Coppery red	Hemorrhagic dots	—
5	M	14	Feet	10	Erythematous-edematous	Coppery red	Hemorrhagic dots	Crusts Purple unstructured areas Bullae
6	M	13	Feet	12	Blistering	Coppery red	Hemorrhagic dots Glomerular Vessels	Crusts Purple unstructured areas
7	F	11	Hands/feet	10	Erythematous-edematous	Coppery red	Irregular linear vessels Cuticular vessels Vessels with branches	Multiple short vessels arranged perpendicularly Purple unstructured areas
8	F	13	Hands	15	Erythematous-edematous	Erythematous	Hemorrhagic dots Irregular dots Cuticular vessels	—
9	M	12	Feet	6	Erythematous-edematous	Coppery red	Hemorrhagic dots Dotted, irregular linear vessels	Round brown unstructured area with within halo
10	M	13	Feet	17	Erythematous-edematous	Erythematous	Dotted	—

F, Female; M, male.



**Fig 1.** **A**, Dermoscopy findings of a classical erythematous-edematous lesion of the dorsal aspect of the toe showing a predominant coppery red background associated with dotted vessels and hemorrhagic dots. **B**, Dermoscopy of a blistering-type CBL showing a coppery red background associated with hemorrhagic dots and crusts. **C**, Another dermoscopic facet of a blistering lesion of the toe showing a white area corresponding to skin detachment. Note how the erythema is mainly distributed on the ridges. *CBL*, Chilblain-like lesions.



**Fig 2.** **A**, A plantar lesion at dermoscopy showing a coppery red background associated with nonblanching hemorrhagic dots. **B**, Another lesion of the sole with erythema on the background, mostly seen on plantar creases. **C**, The late phase of CBL, showing on dermoscopy coppery red areas and blurred dotted vessels. *CBL*, Chilblain-like lesions.

systemic symptoms preceding cutaneous signs. A possible mechanism could be a delayed immune reaction to the viral infection leading to microvascular damage and secondary development of cutaneous lesions. Dermoscopy could be a support in discovering the morphologic features of CBL and the potential pathogenesis hiding behind this mysterious sign.

In most patients, a coppery red background was present at dermoscopy, probably indicating the presence of inflammatory cells and hemosiderin in the dermis. The presence of vascular damage was also indicated by hemorrhagic dots and nonblanching vessels. The presence of some additional features in the blistering type confirms that there was skin detachment in those patients. These dermoscopic findings could be partially justified by the histologic features recently described,<sup>3</sup> with dermal and perivascular lymphocyte infiltrate associated with

keratinocyte necrosis. Dermoscopic findings of CBL are not novel, because they overlap with those of pigmented purpuric dermatoses (PPD)<sup>4</sup> and chilblains. The combination of coppery-red background with hemorrhagic dots is typical of the PPD, whose association with viral infections has been sometimes documented. On the other hand, the similarity of CBL to chilblains is not only clinical but also dermoscopic, so we maintain that the denomination of *CBL* for this cutaneous sign could be the most appropriate and that the term *acro-ischemia* should be avoided.<sup>5</sup> The dermoscopic analogy with PPD could suggest a common histopathology, with a perivascular lymphocyte infiltration and augmented erythrocyte extravasation, although different reasons could lie at the bases of the 2 different conditions.

Our preliminary dermoscopic observations suggest a possible pathogenic explanation for this poorly understood condition.

Vincenzo Piccolo, MD,<sup>a</sup> Andrea Bassi, MD,<sup>b,c</sup>  
Giuseppe Argenziano, MD, PhD,<sup>a</sup> Carlo  
Mazzatenta, MD,<sup>b</sup> Alba Guglielmo, MD,<sup>d</sup> An-  
nalisa Patrizi, MD, PhD,<sup>d</sup> and Iria Neri, MD<sup>d</sup>

From the Dermatology Unit, University of Campa-  
nia Luigi Vanvitelli, Naples, Italy<sup>a</sup>; Unità Oper-  
ativa Dermatologia Lucca—Azienda Unità  
Sanitaria Locale, Toscana Nordovest, Italy<sup>b</sup>;  
Department of Health Science, University of  
Florence, Italy<sup>c</sup>; and Division of Dermatology,  
Department of Experimental, Diagnostic and  
Specialty Medicine, University of Bologna, Italy.<sup>d</sup>

Funding sources: None.

Conflicts of interest: None disclosed.

IRB approval status: Not applicable.

Reprints not available from the authors.

Correspondence to: Vincenzo Piccolo, MD, c/o II  
Policlinico, Edificio 9, Primo piano, Via Pansini 5,  
80131 Naples, Italy

E-mail: [piccolo.vincenzo@gmail.com](mailto:piccolo.vincenzo@gmail.com)

#### REFERENCES

1. Piccolo V, Neri I, Filippeschi C, et al. Chilblain-like lesions during COVID-19 epidemic: a preliminary study on 63 patients. *J Eur Acad Dermatol Venereol*. 2020;34:e291-e293.
2. Piccolo V, Neri I, Manunza F, Mazzatenta C, Bassi A. Chilblain-like lesions during the COVID-19 pandemic: should we really worry? *Int J Dermatol*. 2020;59:1026-1027.
3. Colmenero I, Santonja C, Alonso-Riaño M, et al. SARS-CoV-2 endothelial infection causes COVID-19 chilblains: histopathological, immunohistochemical and ultrastructural study of 7 paediatric cases. *Br J Dermatol*. Published online June 20, 2020. <https://doi.org/10.1111/bjd.19327>.
4. Piccolo V, Russo T, Moscarella E, Brancaccio G, Alfano R, Argenziano G. Dermatoscopy of vascular lesions. *Dermatol Clin*. 2018;36(4):389-395.
5. Piccolo V, Bassi A. Acral findings during the COVID-19 outbreak: chilblain-like lesions should be preferred to acro-ischemic lesions. *J Am Acad Dermatol*. 2020;83(3):e231. <https://doi.org/10.1016/j.jaad.2020.05.077>.

<https://doi.org/10.1016/j.jaad.2020.07.058>

### All that glisters is not COVID: Low prevalence of seroconversion against SARS-CoV-2 in a pediatric cohort of patients with chilblain-like lesions



To the Editor: On January 7, 2020, a novel coronavirus, severe acute respiratory syndrome coronavirus 2 (SARS-CoV-2), was isolated in a patient affected by interstitial pneumonia. As SARS-CoV2 infection has spread worldwide, an increasing number of authors

have reported chilblainlike lesions as possible manifestations of SARS-CoV-2 infection.<sup>1,2</sup>

To test this hypothesis, we performed serologic and stool/rectal polymerase chain reaction tests in a cohort of children who developed chilblainlike lesions during the SARS-CoV-2 outbreak in Italy, between March 8 and April 30, 2020.

Enrollment criteria are described in the Supplemental material (available via Mendeley at <https://doi.org/10.17632/wzh2tyb46y.2>).

During the enrollment period, 35 cases of chilblainlike lesions were eligible for the study. Twenty-four patients agreed to serologic testing (68.6%).

All patients were white, mean age was 13 years (range, 6-17 years), and the female to male ratio was 2:1. Twenty-two patients presented with chilblains on the toes (Fig 1) and 2 lesions were located on the heels, 6 patients developed blistering lesions, 83% of lesions lasted more than 14 days, and 8% lasted less than 1 week.

Two patients had known contact with SARS-CoV-2—positive individuals, defined by positive nasal swab result. Seven more patients had close contact with someone who presented symptoms that might be SARS-CoV-2 related such as asthenia, loss of smell (anosmia), cough, and prolonged fever. In 25% of cases, at least 1 parent was a health worker. Further details are available in the Supplemental Results.

Chemiluminescence assay (Liaison SARS-CoV-2 IgG, Diasorin) was performed for all patients; 7 patients were tested with In3diagnostic ERADIKIT COVID19, and the other 17 with EDI Novel Coronavirus COVID-19.

A total of 3 patients (12.5%) tested positive via both enzyme-linked immunosorbent assay and chemiluminescence. In 1 patient (4.1%), enzyme-linked immunosorbent assay test result was positive, whereas chemiluminescence result was negative. None of the 4 patients with positive results presented with fever, 50% had cough, and 25% presented with transient diarrhea up to 14 days before skin lesion appearance. All 4 patients had contact with a relative who had confirmed SARS-CoV-2 infection (2 patients) or anosmia (2 patients). Fecal polymerase chain reaction was tested in 4 patients (16.6%), and no result was positive; rectal swab was performed in 17 patients (70.8%) and was positive in 1, which also was positive at both serologic tests.

Finally, patients with chilblainlike lesions were compared with a cohort of 24 SARS-CoV-2—infected children. Table I shows the comparison between the 2 groups. Chilblain patients were significantly older (13 vs 4 year;  $P < .001$ ); fever was present in a limited