

CASE REPORT

Tailgut cyst: 2 case reports

Nizar Kardoun^{1,2} | Zied Hadrich^{1,2}  | Amira Akrouf^{1,2} | Houssein Harbi^{1,2} | Salah Boujelben^{1,2} | Rafik Mzali^{1,2}

¹Departement of Surgery, Habib Bourguiba Hospital, Sfax, Tunisia

²Faculty of Médecine of Sfax, Sfax, Tunisia

Correspondance

Zied Hadrich, Departement of Surgery, Habib Bourguiba Hospital, Sfax, Tunisia.
Email: hadrich1988@gmail.com

Funding information

None

Abstract

Tailgut cysts, or retrorectal cystic hamartomas, are rare congenital developmental lesions. It is a benign lesion, but there is a risk of degeneration, so surgical resection is necessary.

KEY WORDS

retrorectal mass, surgical resection, tailgut cyst, transabdominal approach

1 | INTRODUCTION

Tailgut cysts, or retrorectal cystic hamartomas, are rare congenital developmental lesions that are thought to be derived from remnants of the embryonic postanal gut with incomplete regression during development. They are located in the retrorectal space and are more common in women. In fact, as the embryo starts to fold inward during the 4th week of gestation to enclose the future gut, the cloacal membrane (made from the endoderm below the level of Hensen's node) comes to lie ventral and encloses the caudal portion distal to the eventual hindgut and is called a tailgut.¹ The tailgut normally regresses by the 6th week of gestation. If the mucous-secreting remnants fail to regress, a tailgut cyst is formed.

We present two cases of retrorectal tailgut cyst managed by using a transabdominal approach.

2 | CASE REPORT

2.1 | Case 1

We present the case of a 53-year-old woman who presented with incidentally detected retrorectal mass during

stratification of acute pancreatitis. The physical examination showed an anal sphincter with normal tone, normal flexibility of the perianal soft tissue, and an empty rectal vault with extrarectal fullness posteriorly that is reachable with the fingertip.

The CT scan showed a left-lying, well-circumscribed, rounded presacral mass at the level of the 4th sacral vertebra, measuring 5 × 3.4 cm (Figure 1: red arrow), with a central liquid component, a peripheral tissue density of 36HE, and fine calcification at the right rim. No sign of osseous destruction was noted.

The diagnosis of a cyst has been evoked, but the confirmation requires a histological examination of the surgical specimen. The patient was operated after restitutio ad integrum of the acute pancreatitis. She had a laparoscopic cholecystectomy, and then at laparotomy (through an under umbilical midline incision), we found a retrorectal mass of 5 cm without any extension. A complete resection through an avascular plane of the retrorectal mass was done.

Pathological examination of the surgical specimen revealed a tailgut cyst without any malignancy (Figure 2). The patient did not present any recurrence of the mass at 12 months of follow-up.

2.2 | Case 2

A 68-year-old woman presented with pelvic pain that started 3 months ago. Abdominal examination was normal. The rectal examination revealed a bulge in the posterior wall.

Magnetic resonance imaging (MRI) of the abdomen and pelvis showed a retrorectal polylobed oval mass measuring 4 cm (Figure 3). The biopsy was not done because of the risk of dissemination and bleeding.

The patient was operated. At laparotomy (through a mid-line incision), we found a retrorectal cyst without extension to the rectal wall and the coccyx. A complete resection of the mass was made (Figure 4).

Pathological examination of the specimen showed a tailgut cyst without malignancy. The patient did not present any recurrence of the cyst at 24 months of follow-up.

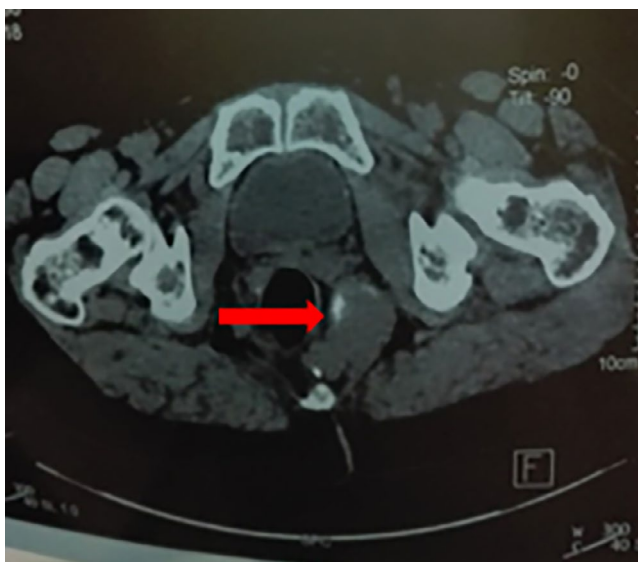


FIGURE 1 Axial sections of the abdominopelvic CT scan showing the tailgut cyst with wall calcification

3 | DISCUSSION

Retrorectal tailgut cysts, also known as retrorectal cystic hamartomas, are rare congenital lesions in the retrorectal space, which bounded anteriorly by the rectum, posteriorly by the sacrum, superiorly by the peritoneal reflection, inferiorly by the levator ani and coccygeus muscle, and laterally by the ureters and iliac vessels (Figure 5).

Tailgut cyst is most prevalent in middle-aged women, arising from postnatal primitive gut remnants but can also be found in a wide range of age-groups, including infancy. Most tailgut cysts are asymptomatic, and they are often discovered incidentally or presented as a compressive effect of a growing mass within the pelvis such as change in stool caliber, a palpable rectal mass, urinary frequency, and frequently as an infected tailgut cyst with a rectal fistula or anal fistula.^{2,3}

The diagnosis can take place as early as a finding on prenatal screening ultrasonography or as late as a finding in autopsy. Tailgut cyst lining can exhibit different types of the epithelium including columnar, transitional, and squamous. The presence of some glandular or transitional epithelium differentiates them from epidermoid and dermoid cysts, which can communicate with the skin.

On CT, a tailgut cyst is a presacral mass with a central liquid component, a high peripheral tissue density, and fine calcification at the rim. On MRI, a tailgut cyst typically demonstrates low signal intensity on T1-weighted images and high signal intensity on T2-weighted images, although it may vary according to the content. Transrectal ultrasound provides a summary of major pelvic lymph node regions and parietal pelvic fascia extension.⁴

Surgical excision followed by a complete histological examination is the recommended path of treatment, instead of a preoperative biopsy. Complete surgical resection is the traditional treatment of choice, eliminating the potential of recurrence, hemorrhage, infection, compression, and malignant transformation.

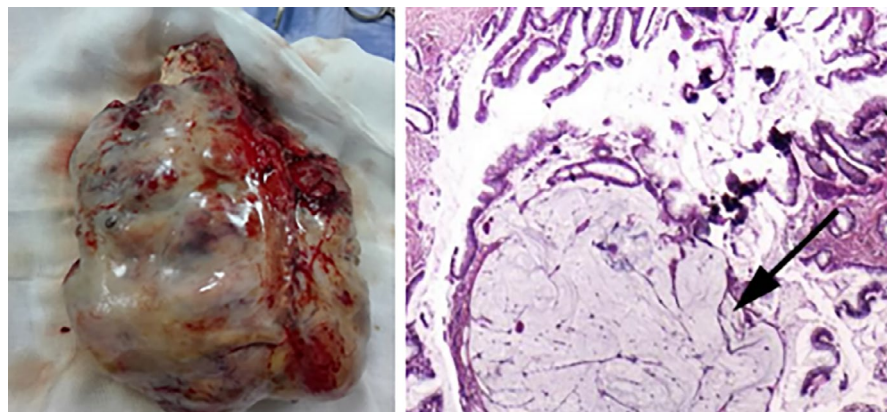


FIGURE 2 Pathological examination of specimen

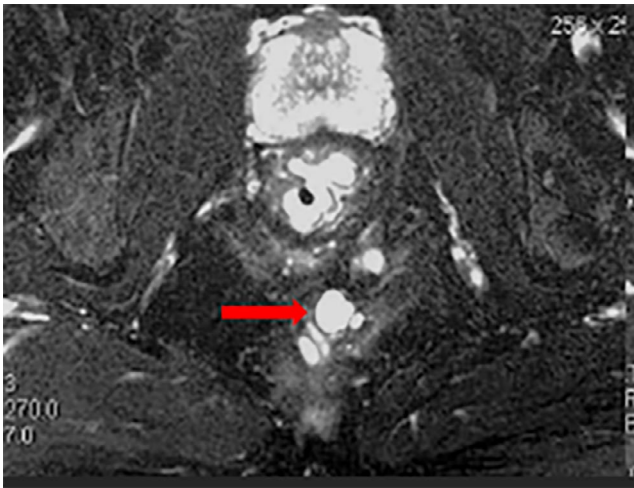


FIGURE 3 Retrorectal polylobed oval mass

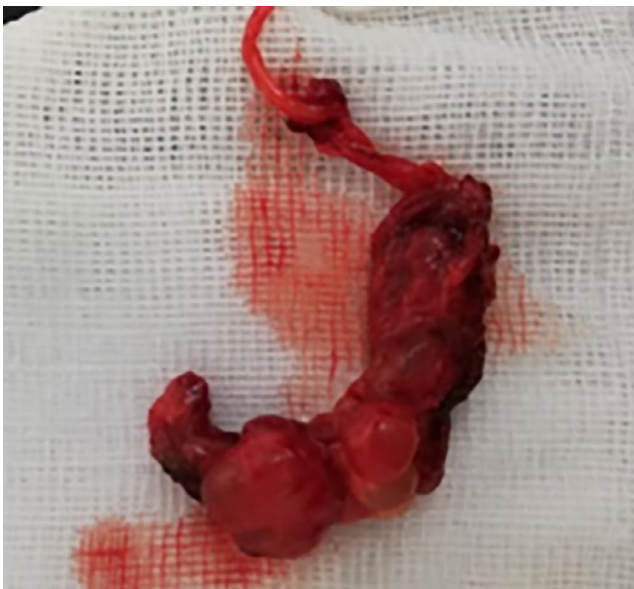

FIGURE 4 Surgical specimen

The most common surgical approach described for tailgut cyst excision is a posterior parasacral incision, for a complete removal of the cyst.^{3,5-7} In the present series, the decision whether to use an anterior-only, posterior-only, or combined approach was determined by the degree of proximal extension of the cyst (if higher than the third sacral body, a combined anterior-posterior or anterior-only approach was used), whether or not the cyst had been infected and was adherent to surrounding structures (bladder, ureters, or rectum), and whether lesions were malignant and required en bloc organ resection. The results confirm that most benign cysts can be removed successfully using a posterior approach and that these patients have improved recovery, with fewer complications, compared with those undergoing an anterior or combined approach.

Preoperative evaluation of presacral cysts at this institution currently involves CT of the pelvis, which provides

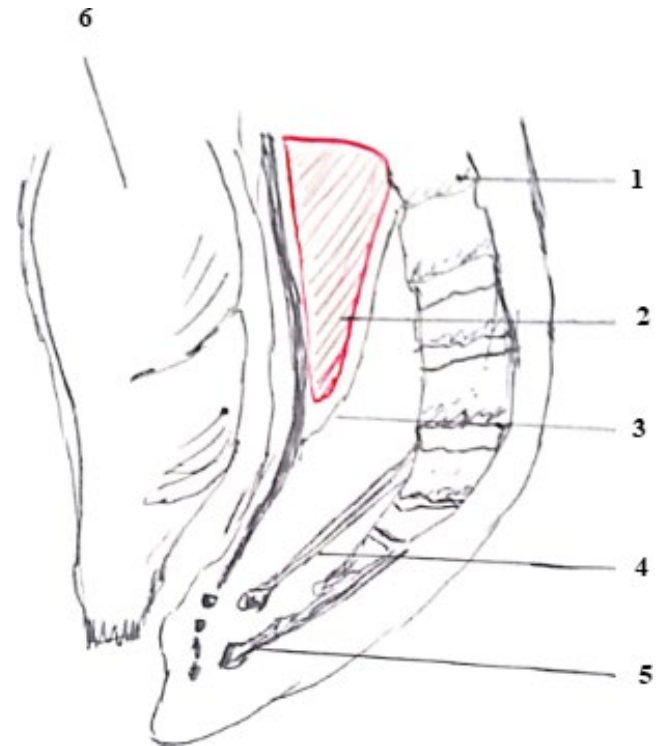


FIGURE 5 Retrorectal space. 1: sacrum 2: retrorectal space 3: Waldeyer's fascia 4: levator ani 5: anococcygeal ligament 6: rectum

important information to guide surgical planning, such as the overall size and upper pelvic extent of the cyst; whether or not it is inflamed, infected, or adherent to surrounding structures; and whether or not malignant features are present.^{8,9}

Recently, a laparoscopic approach for tailgut cyst removal has been introduced; this approach is particularly useful for low-lying cysts.^{7,10} The main advantage of this approach is the magnifying effect it provides in a narrow pelvis. In selected cases involving small and radiologically uncomplicated lesions, the laparoscopic approach is a feasible option for experienced surgeons.

The issue of whether to carry out a coccygectomy in the setting of benign congenital presacral cysts is controversial. Several authors advocate coccygectomy, stating that this approach improves surgical exposure and decreases the risk of recurrence as the coccyx may harbor a nidus of totipotential cellular remnants that may later evolve into a recurrent cyst. The concern that retention of the coccyx will increase the risk of recurrence is not supported by published data, and some authors believe, if the cyst is not adherent to the coccyx and can be removed entirely without coccygectomy, that the coccyx should be left in place.^{8,11-13} It is probable that the cyst itself, and not the coccyx, harbors the aberrant remnants of the postanal gut, leading to the formation of the cyst, and so coccygectomy carries no advantage if the cyst is not adherent to the coccyx. This perspective was adopted in the present series, with most surgeons electing to preserve the coccyx, unless en bloc resection was required for malignancy or the cyst was densely adherent to the coccyx.

TABLE 1 Cases of tailgut cyst reported in the literature

First author	Year	Number of cases	Gender	Age (years)	Surgical approach
A. Faradji	2020	1	F ^a	NP ^c	NP ^c
Gustavo de Castro Gouveia ¹³	2020	1	F	28	Posterior intergluteal
Jiannan Li ⁷	2019	1	F	46	Posterior parasacral
Ismael Mora-Guzmán ¹⁴	2018	4	F	35, 41, 56, and 56	Posterior approach
M Ostiz Llanos ¹⁵	2017	1	F	42	Posterior approach
Andreas Volk ¹¹	2016	2	F	48 and 67	Anterior approach
Mazen Haydar ³	2015	1	F	42	Posterior approach
D Patsouras ¹⁰	2015	17	15 F/2M ^b	35(mean age)	Posterior approach
Nadeem Haider ¹⁶	2015	2	1F/1 M	14 months/7 months	Posterior sagittal approach
Vasileios Charalampakis ¹⁷	2012	1	M	35	Anterior approach
E. A. Joyce ¹²	2012	1	F	43	Posterior approach
Rosa G ⁶	2012	6	F	NP	Transperineal approach
Bathla L ⁵	2013	1	F	46	Posterior approach
M. Delemer ¹⁸	2010	1	F	24	Transvaginal approach
Mathis KL ⁸	2010	31	28F/3 M	52 (mea nage)	Posterior approach (8 sacral resection or coccygectomy)
V Aflalo-Hazan ⁴	2008	11	8F/3 M	40,8(mean age)	NP ^c
Jang SH ²	2007	1	M	14	NP ^c
İpek Işık Gönül ⁹	2006	1	F	37	NP ^c
Florence Le Pessot ¹⁹	2003	1	F	23	Anterior approach
Parasad AR ¹	2000	5	F	NP	Anterior approach

^aFemale.

^bMale.

^cNot precise.

Table 1 summarizes cases of tailgut cysts reported in the literature (Table 1).

4 | CONCLUSION

Tailgut cysts are derivatives of the embryonic postanal gut. Tailgut cysts are usually asymptomatic, and they are often discovered in adults as an incidental retrorectal mass. Complications include infection, with the formation of retrorectal abscesses and occasionally anal fistulae, and a long-term risk of malignant change, which means that once discovered, surgical excision using an anterior or posterior approach is advised.

ACKNOWLEDGMENTS

Published with the consent of the patients.

AUTHOR CONTRIBUTIONS

Z Hadrich conceived the idea of the document and contributed to the writing and editing of the manuscript. N Kardoun contributed to the writing and editing of the manuscript.

A Akrouit reviewed and edited the manuscript. H Harbi reviewed and edited the manuscript. S Boujelben contributed to the literature review, manuscript writing, editing, and review of the manuscript. All authors read and approved the final manuscript.

CONFLICTS OF INTERESTS

None declared.

ETHICAL APPROVAL

Personal data have been respected.

DATA AVAILABILITY STATEMENT

Personal data of the patient were respected. No data are available for this submission.

ORCID

Zied Hadrich  <https://orcid.org/0000-0002-5048-3755>

REFERENCES

1. Prasad AR, Amin MB, Randolph TL, Lee CS, Ma CK. Retrorectal cystic hamartoma. *Arch Pathol Lab Med.* 2000;124:5.

2. Jang S-H, Jang K-S, Song Y-S, et al. Unusual prerectal location of a tailgut cyst: a case report. *World J Gastroenterol*. 2006;12:5081-5083.
3. Haydar M, Griepentrog K. Tailgut cyst: a case report and literature review. *Int J Surg Case Rep*. 2015;10:166-168.
4. Aflalo-Hazan V, Rousset P, Mourra N, Lewin M, Azizi L, Hoeffel C. Tailgut cysts: MRI findings. *Eur Radiol*. 2008;18:2586-2593.
5. Bathla L, Singh L, Agarwal PN. Retrorectal cystic hamartoma (Tailgut Cyst): report of a case and review of literature. *Indian J Surg*. 2013;75:204-207.
6. Rosa G, Lolli P, Vergine M, El-Dalati G, Malleo G. Surgical excision of developmental retrorectal cysts: results with long-term follow-up from a single institution. *Updates Surg*. 2012;64:279-284.
7. Li J, Song X, Shi J, Zhang K, Liu T. Surgical management of tailgut cysts. *Medicine (Baltimore)*. 2019;98:e14448.
8. Mathis KL, Dozois EJ, Grewal MS, Metzger P, Larson DW, Devine RM. Malignant risk and surgical outcomes of presacral tailgut cysts. *Br J Surg*. 2010;97:575-579.
9. Gönül II, Bağlan T, Pala I, Menteş B. Tailgut cysts: diagnostic challenge for both pathologists and clinicians. *Int J Colorectal Dis*. 2007;22:1283-1285.
10. Patsouras D, Pawa N, Osmani H, Phillips RKS. Management of tailgut cysts in a tertiary referral centre: a 10-year experience. *Colorectal Dis*. 2015;17:724-729.
11. Volk A, Plodeck V, Toma M, Saeger H-D, Pistorius S. Treatment of tailgut cysts by extended distal rectal segmental resection with rectoanal anastomosis. *Surg Today*. 2017;47:457-462.
12. Joyce EA, Kavanagh DO, Winter DC. A rare cause of low back pain: report of a tailgut cyst. *Case Rep Med*. 2012;2012:e623142.
13. de Castro Gouveia G, Okada LY, Paes BP, Moura TM, da Conceição Júnior AH, Pinheiro RN. Tailgut cyst: from differential diagnosis to surgical resection—case report and literature review. *J Surg Case Rep*. 2020;2020(7):1–3.
14. Mora-Guzmán I, Alonso Casado AP, Rodríguez Sánchez A, Bermejo ME. Tailgut cysts: presentation of four cases. *Gastroenterol Hepatol*. 2018;41:103-105.
15. Ostiz Llanos M, Yanguas Barea N, Jiménez López de Oñate G, González Álvarez G, Fernández de Los Reyes I. [Retrorectal cystic hamartoma (tailgut cyst): an uncommon cause of recurrent abdominal pain]. *An Sist Sanit Navar*. 2017;40:303-307.
16. Haider N, Shaheen I, Squire R, Stringer MD. Tailgut cysts in children: a report of two cases and literature review. *Pediatr Surg Int*. 2015;31:597-601.
17. Charalampakis V, Stamatiou D, Christodoulakis M, et al. Large presacral tailgut cyst with a carcinoid tumor in a male: report of a case. *Surg Today*. 2014;44:961-966.
18. Delemer M, Detchev R, Dugue T, Gosset P, Houzé de l'Aulnoit D. L'hamartome kystique rétrorectal (HKRR): à propos d'un cas révisé par abord vaginal et revue de la littérature. *Journal de Gynécologie Obstétrique et Biologie de la Reproduction* 2011;40:569-571.
19. Le Pessot F, Ranty M-L, Lemoine F, Koning E, Michot F, Métayer J. [Retrorectal cystic hamartomas. Report of one case] *Ann Pathol*. 2003;23:157–160.

How to cite this article: Kardoun N, Hadrach Z, Akrouf A, Harbi H, Boujelben S, Mzali R. Tailgut cyst: 2 case reports. *Clin Case Rep*. 2021;9:e04490. <https://doi.org/10.1002/ccr3.4490>