


# Prevalence and Distribution of Macular Fluid with Central Retinal Artery Occlusion and Anterior Ischaemic Optic Neuropathy [Response to Letter]

Yousef A Fouad , Mohamed Nabil Hamza, Moataz M Wessam

Department of Ophthalmology, Ain Shams University Hospitals, Cairo, Egypt

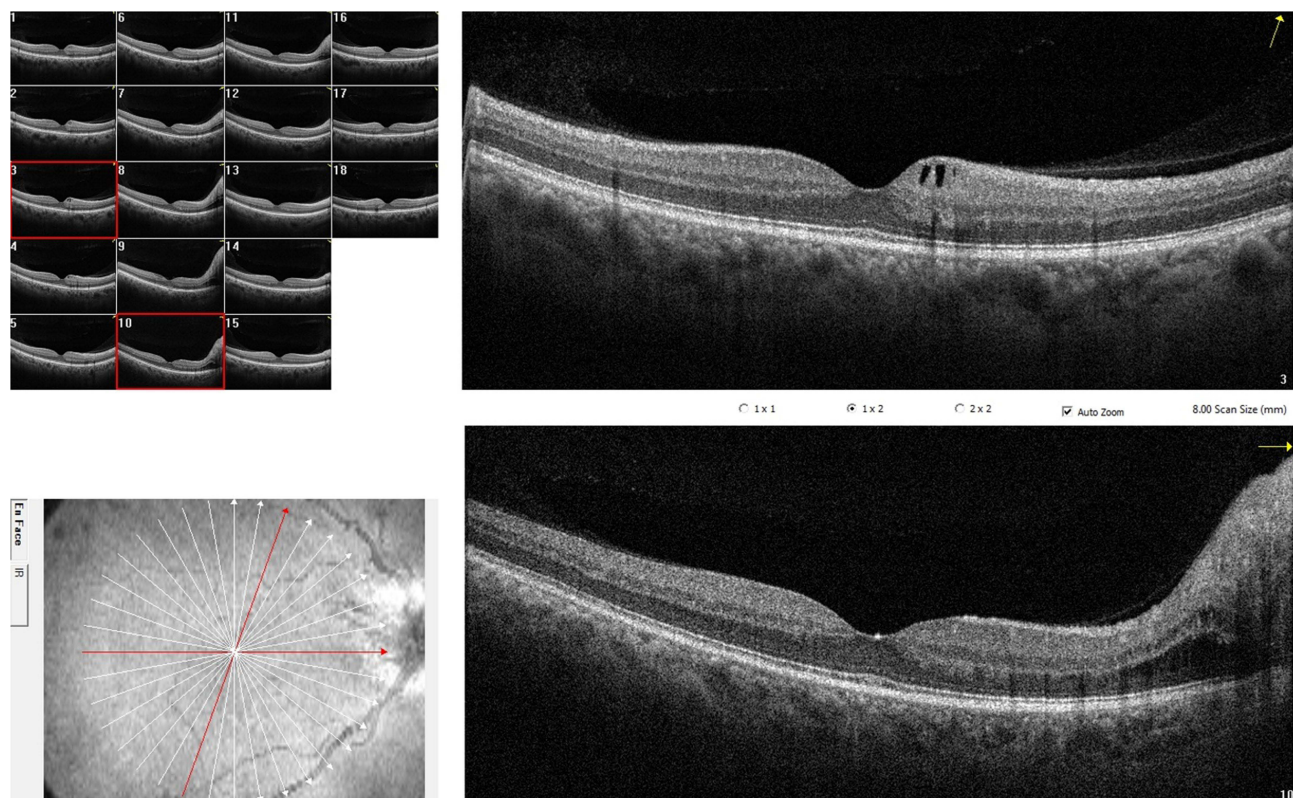
Correspondence: Yousef A Fouad, Ophthalmology Department, Ain Shams University, Ramses street, Abbassiya, Cairo, 11517, Egypt, Tel +201063781237, Email yousef.a.fouad@gmail.com

## Dear editor

We thank Plant et al for their interest in our article “Prevalence and Distribution of Macular Fluid with Central Retinal Artery Occlusion and Anterior Ischemic Optic Neuropathy”.<sup>1</sup> In our study, 6 out of 11 eyes with acute non-arteritic anterior ischemic optic neuropathy (AION) had intraretinal fluid on optical coherence tomography (OCT). All 6 eyes had fluid involving the outer nuclear layer, 4 eyes had fluid within the inner nuclear layer (INL), and 3 eyes had fluid within the ganglion cell layer (GCL).

We agree with the authors of the letter on the importance of distinguishing the acutely developing microcystic macular edema from the later developing cystic degeneration of the INL (referred to as “retrograde maculopathy”). In a prior article by the authors,<sup>2</sup> it was hypothesized that the former develops due to “axonal swelling and further vascular compromise” that leads to “leakage of the peripapillary vessels” saturating Müller cell capacity to remove fluid. To support their hypothesis, the authors cited a study<sup>3</sup> that quantified INL cells across the retina and suggested that the decrease in Müller cell density with eccentricity from the fovea explains why fluid is observed in the peripapillary area and not the fovea in eyes with AION. It is important to note that the cited article by Masri and colleagues<sup>3</sup> actually found the peak Müller cell density to be at 0.8 mm eccentricity from the fovea, with lower density noted in the central fovea and peripheral macula, and with a higher proportion of Müller cells in the peripheral compared to the central retina. Further, the overwhelmed Müller cells by the leakage from the peripapillary vessels would not explain why in some instances fluid cysts could be noted within the GCL even away from the peripapillary region (an example from our cohort is given in [Figure 1](#)).

The authors of the letter also address the description of central retinal artery occlusion (CRAO) cases included in our study. They suggest that the term “cloudy swelling” should be used instead of whitening when describing the colored fundus photographs of CRAO cases, and that the term also serves the OCT appearance of the GCL in such cases. We would like to point out that CRAO has different grades and may evolve over time.<sup>4</sup> For example, paracentral acute middle maculopathy with INL infarcts and without GCL involvement may present as greyish-white lesions within the macula and can be the sole presentation in milder cases of CRAO.<sup>5</sup> That is why we believe that not all cases of CRAO involve cloudy swelling of the GCL (although the case depicted in our article had full-blown CRAO and did indeed show cloudy swelling). It is also important to distinguish between increased macular thickness with CRAO due to swelling of the inner retinal layers<sup>6</sup> from actual cystic fluid accumulation within the middle and outer retinal layers.<sup>7</sup> While the former does represent tissue edema (cytotoxic edema) as the authors accurately point out, the latter may evolve during the disease course<sup>7</sup> and could possibly have a different pathophysiological mechanism of Müller cell dysfunction. Again, we thank the authors for their interest in our article, congratulate them on their prior studies and look forward to their future work on this important topic.



**Figure 1** Optical coherence tomography scans depicting different distribution of intraretinal fluid in an eye with acute anterior ischemic optic neuropathy. A horizontal macular radial scan (lower B-scan) shows peripapillary accumulation of fluid within the outer and inner nuclear layers and a swollen optic disc. An oblique macular radial scan (upper B-scan) shows cystic cavities within the ganglion cell layer in the upper nasal parafovea.

## Funding

There is no funding to report.

## Disclosure

The authors report no conflicts of interest in this communication.

## References

1. Fouad Y, Hamza M, Wessam M. Prevalence and distribution of macular fluid with central retinal artery occlusion and anterior ischemic optic neuropathy. *Clin Ophthalmol*. 2024;18:887–893. doi:10.2147/OPTH.S457503
2. Chapelle A-C, Rakic J-M, Plant GT. The occurrence of intraretinal and subretinal fluid in anterior ischemic optic neuropathy. *Ophthalmology*. 2023;130:1191–1200. doi:10.1016/j.ophtha.2023.07.015
3. Masri RA, Weltzien F, Purushothuman S, et al. Composition of the inner nuclear layer in human retina. *Invest Ophthalmol Vis Sci*. 2021;62:22. doi:10.1167/iovs.62.9.22
4. Chen C, Singh G, Madike R, Cugati S. Central retinal artery occlusion: a stroke of the eye. *Eye*. 2024. doi:10.1038/s41433-024-03029-w
5. Scharf J, Freund KB, Sadda S, Sarraf D. Paracentral acute middle maculopathy and the organization of the retinal capillary plexuses. *Prog Retin Eye Res*. 2021;81:100884. doi:10.1016/j.preteyeres.2020.100884
6. Shinoda K, Yamada K, Matsumoto CS, et al. Changes in retinal thickness are correlated with alterations of electroretinogram in eyes with central retinal artery occlusion. *Graefes Arch Clin Exp Ophthalmol*. 2008;246:949–954. doi:10.1007/s00417-008-0791-x
7. Estawro R, Abraham N, Fouad Y, et al. Cystoid macular edema as a complication of central retinal artery occlusion. *Am J Ophthalmol Case Reports*. 2024;33:101998. doi:10.1016/j.ajoc.2024.101998

Dove Medical Press encourages responsible, free and frank academic debate. The content of the Clinical Ophthalmology 'letters to the editor' section does not necessarily represent the views of Dove Medical Press, its officers, agents, employees, related entities or the Clinical Ophthalmology editors. While all reasonable steps have been taken to confirm the content of each letter, Dove Medical Press accepts no liability in respect of the content of any letter, nor is it responsible for the content and accuracy of any letter to the editor.

### Clinical Ophthalmology

Dovepress

## Publish your work in this journal

Clinical Ophthalmology is an international, peer-reviewed journal covering all subspecialties within ophthalmology. Key topics include: Optometry; Visual science; Pharmacology and drug therapy in eye diseases; Basic Sciences; Primary and Secondary eye care; Patient Safety and Quality of Care Improvements. This journal is indexed on PubMed Central and CAS, and is the official journal of The Society of Clinical Ophthalmology (SCO). The manuscript management system is completely online and includes a very quick and fair peer-review system, which is all easy to use. Visit <http://www.dovepress.com/testimonials.php> to read real quotes from published authors.

Submit your manuscript here: <https://www.dovepress.com/clinical-ophthalmology-journal>