

Comparison of posterior occlusion between patients with anterior open bite and scissor deep bite

Kun Qi^{1,2}, Yifei Xu², Yuxia Hou¹ and Mei-Qing Wang²

Abstract

Objective: A minor alteration in the posterior occlusal height elicits a large transformation in the anterior vertical dimension. Thus, the present study was performed to determine whether a posterior cusp-to-cusp relation that increases the posterior vertical dimension contributes to an anterior open bite.

Methods: Study casts were examined from orthodontic patients aged 10 to 27 years, 21 with an open bite and 28 with a scissor deep bite. A logistic regression model was used to analyze the contribution of various factors to these two anterior occlusal patterns. The dental arch width and number of worn cusps were compared between the two groups.

Results: Patients with an open bite had a significantly higher incidence of a posterior buccal–lingual cusp-to-cusp relation, wider mandibular arch in the molar region, and larger numbers of worn maxillary buccal cusps and mandibular lingual cusps than patients with a scissor deep bite.

Conclusions: A posterior buccal–lingual cusp-to-cusp relation is associated with a larger anterior vertical dimension, such as that in patients with an open bite.

¹Key Laboratory of Shaanxi Province for Craniofacial Precision Medicine Research & Clinical Research Center of Shaanxi Province for Dental and Maxillofacial Diseases, Department of Orthodontics, Stomatological Hospital, Xi'an Jiaotong University, Xi'an, P.R. China

²State Key Laboratory of Military Stomatology, National Clinical Research Center for Oral Disease & Shaanxi International Joint Research Center for Oral Diseases, Department of Oral Anatomy and Physiology and TMD, School of Stomatology, Fourth Military Medical University, Xi'an, P.R. China

Corresponding author:

Mei-Qing Wang, Department of Oral Anatomy and Physiology and TMD, School of Stomatology, Fourth Military Medical University, 145 West Changle Road, Xi'an 710032, P.R. China.

Email: mqwang@fmmu.edu.cn



Keywords

Open bite, scissor deep bite, occlusion, vertical dimension, overjet, overbite

Date received: 14 November 2017; accepted: 12 February 2018

Introduction

The posterior teeth maintain the vertical dimension of occlusion, and the ratio of the posterior-to-anterior vertical dimension is around 1:2.¹ This means that a minor increase in the posterior vertical dimension will elicit an approximately two-fold increase in the anterior vertical dimension.

The anterior open bite, in which the maxillary and mandibular anterior teeth lack vertical trespass with vertical space, is believed to be accompanied by an increase in the vertical dimension.² Alternately, the scissor deep bite, in which the mandibular teeth are vertically and extensively overlapped by the maxillary teeth, is characterized by a decrease in the vertical dimension.³ To the best of our knowledge, however, a direct comparison of the posterior occlusal vertical dimension between patients with an open bite and scissor deep bite has not been reported. This may be due to the difficulties in precisely measuring the posterior occlusal dimension at the maximal intercuspal relation using reasonable markers on the molar or premolar crowns. The maxillary and mandibular posterior teeth normally contact in a convex-to-concave pattern and a cusp-to-fossa relation. A notable increase in the occlusal vertical dimension can be associated with a change from a cusp-to-fossa relation to a cusp-to-cusp relation (Figure 1). Whether such an increase in the posterior occlusal vertical dimension plays a role in an increase in the anterior vertical dimension remains unknown.

We compared such a cusp-to-fossa/cusp-to-cusp posterior relation between patients with open bites (larger vertical dimension) and patients with scissor deep bites (smaller vertical dimension). The hypothesis was that there is no difference in the posterior occlusal contact pattern or arch width

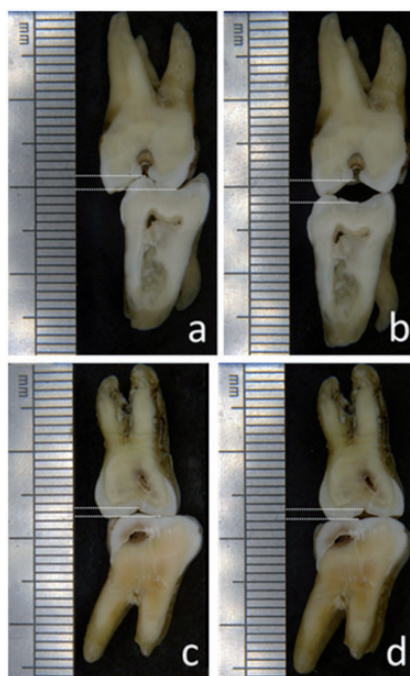


Figure 1. Attribution of the posterior occlusal contact condition to the vertical dimension of occlusion. (a, b) Buccal–lingual section. (c, d) Mesial–distal section. (a, c) Cusp-to-fossa relation. (b, d) Cusp-to-cusp relation. The occlusal vertical dimension of the cusp-to-cusp relation is nearly three times larger than that of the cusp-to-fossa relation.

between patients with an open bite and scissor deep bite.

Materials and methods

Patients and groups

Study casts from patients with an open bite (collected from 2008 to 2015) and patients with a scissor deep bite (collected during the spring of 2015) were obtained from the collection in the Orthodontic Department of Qindu Oral Hospital, the Fourth Military Medical University, Xian, China. In the open-bite casts, the vertical separation between the maxillary and mandibular incisors was at least 1 mm. The maxillary incisors in the scissor deep-bite group were aligned vertically or inclined lingually, and the degree of overbite was deep enough to cover two-thirds or more of the length of the mandibular incisors. This study was approved by the Human Subjects Ethics Committees of the Fourth Military Medical University. All patients provided written informed consent.

Scoring of posterior occlusal contact relation

The cusp-to-cusp or cusp-to-fossa occlusal relation was observed and recorded in both the mesial–distal and buccal–lingual relations as described below.

Mesial–distal relation. The mesial–distal relation of the first molar was classified into five types (Figure 2(a)). Types 2 and 4 in Figure 2(a) were recorded as 1, meaning that the first molars were in a cusp-to-cusp occlusal relation. Types 1, 3, and 5 were recorded as 0, meaning that the occlusion of the first molars was at least partially in a convex-to-concave relation. The variable of the mesial–distal relation was scored as 1 if any side was recorded as 1. If no side was recorded as 1, this variable would be scored as 0.

Buccal–lingual relation. The buccal–lingual relation of all pairs of posterior teeth was evaluated according to the classification shown in Figure 2. Types 2, 4, and 6 in

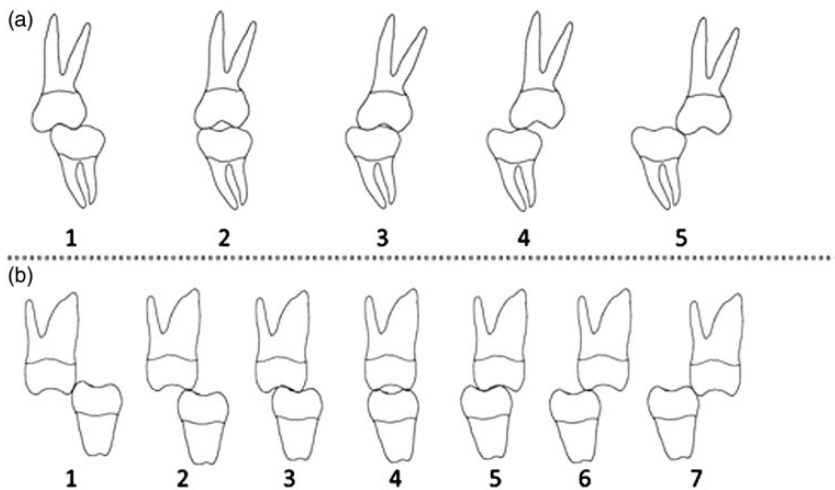


Figure 2. This schematic drawing illustrates the scoring methods used for the posterior occlusion relation. (a) The mesial–distal occlusal contact relation of the first molar (five types) with the mesial direct to left and the distal direct to right. (b) The buccal–lingual occlusal contact relation of a pair of the posterior teeth (seven types) with the lingual direct to left and buccal direct to right.

Figure 2(b) indicate that a cusp-to-cusp occlusion relation was recorded as 1. The other types, (Types 1, 3, 5, and 7) were recorded as 0. The variable of the buccal–lingual relation was scored as 1 if any one pair of the posterior teeth was recorded as 1. If no pair of the posterior teeth was recorded as 1, the variable of the buccal–lingual relation was scored as 0.

Tooth wear

The cusps with a cusp-to-cusp occlusal relation were expected to be more worn. Because all enrolled patients were young (<27 years old), the degree of tooth wear was not taken into consideration. Instead, we focused on the location of tooth wear, such as wear on the cusp tip or outside of the cusp tip. We visually calculated the number of worn cusp tips for each posterior tooth on the casts for comparison between groups. The numbers of worn buccal and lingual cusps on the posterior teeth were recorded separately because of the difference between these two cusps in maintaining the vertical dimension.

Arch width

A wider mandibular arch, or a narrow maxillary arch, is expected in a cusp-to-cusp occlusal relation in the buccal–lingual direction. Therefore, we measured the arch width at the cusp tips of different teeth. The distance between the buccal cusp tips of each pair of homonymic teeth on the left and right sides (in total, 539 pairs in the present sample) was measured using Vernier calipers (Guanglu Measuring Instrument Co., Ltd., Guilin, China). Forty-nine pairs of posterior teeth were ruled out because they exhibited ectopia or impaction, were out of the dental arch, or had caries that had destroyed the cusps.

Statistical methods

Initially, the contribution of four variables (sex, age, the score of the mesial–distal relation, and the score of the buccal–lingual relation) to the anterior occlusal pattern, the open bite, and the scissor deep bite were analyzed through logistic regression analysis using SPSS Statistics, version 17.0 (SPSS Inc., Chicago, IL, USA). Variables were quantified as follows. Anterior occlusal pattern group: 0 for the scissor deep-bite group, 1 for open-bite group. Sex: 0 for men, 1 for women. Mesial–distal relation and buccal–lingual relation: 1 for cusp-to-cusp occluding relation, 0 for others. The variables' entry level was set at 0.05. Arch width, the average number of worn cusp tips of the posterior teeth, and the total number of worn cusp tips of the buccal and lingual posterior teeth were compared between the open-bite and scissor deep-bite groups using Student's t-test ($\alpha = 0.05$).

Results

Patients

In total, 49 study casts were obtained from 21 patients with an open bite and 28 patients with a scissor deep bite. The open-bite casts originated from 7 male and 14 female patients with a mean age of 16 ± 3.7 years, and the scissor deep-bite casts originated from 15 male and 13 female patients with a mean age of 16 ± 3.8 years.

Logistic regression for occlusion scores, sex, and age

The buccal–lingual relation variable ($P = 0.007$ for multivariable logistic regression and $P = 0.009$ for simple logistic regression analysis), but not the other three variables (the score of the mesial–distal

relation, sex, and age) were entered into the logistic regression model, suggesting that the posterior buccal–lingual cusp-to-cusp occlusal relation was associated with the occurrence of open-bite vs. scissor deep-bite. The odds ratio (OR) was 6.60 when the simple logistic regression analysis was performed and 7.503 when the four variables were analyzed together using the multivariable logistic regression model. The 95% confidence interval for the OR was 1.69–25.76 and 1.671–33.694 for the simple and multivariable logistic regression analyses, respectively. These data indicated that the possibility of having an open bite increased up to 6.60 times in patients with a buccal–lingual cusp-to-cusp occlusal relation in contrast to those without. When the variables of mesial–distal relation, sex, and age were considered simultaneously, this value increased to 7.503.

Number of worn cusp tips

The numbers of worn buccal and lingual cusp tips in the maxillary and mandibular dentitions of the open-bite vs. scissor deep-bite groups are shown in Table 1. The mean and total numbers of worn cusp tips in the

open-bite group were significantly greater than those in the scissor deep-bite group, for both molars and premolars ($P < 0.001$), except for the mandibular premolar lingual cusps. Both the number of worn supporting cusps (mandibular buccal cusps and maxillary lingual cusps) and the number of worn non-supporting cusps (maxillary buccal cusps and mandibular lingual cusps) were significantly larger in the open-bite than scissor deep-bite group ($P < 0.001$).

Arch width

The widths of the mandibular dental arches were larger in the open-bite group than in the scissor deep-bite group at most of the measuring sites (mandibular first and second premolars, mesial and distal cusps of the mandibular first molar, and distal cusp of the mandibular second molar) (Table 2). However, differences in the widths of the maxillary dental arches between the two groups were found only at the sites of the maxillary first and second premolars and not at molar sites; they were larger in the open-bite group than in the scissor deep-bite group.

Table 1. Comparison of the mean and total number and worn cusp tips of the buccal and lingual posterior teeth cusps, premolars and molars, between the open-bite and scissor deep-bite groups.

			Total number of worn cusp tips			Mean number of worn cusp tips		
			Open bite	Scissor deep bite	P	Open bite	Scissor deep bite	P
Maxillary dentition	Premolar	Buccal cusps	41	11	<0.000	2.0 ± 1.28	0.4 ± 0.57	<0.000
		Lingual cusps	29	4	<0.000	1.4 ± 1.12	0.1 ± 0.36	<0.000
	Molar	Buccal cusps	61	7	<0.000	2.9 ± 2.43	0.3 ± 0.59	<0.000
		Lingual cusps	92	31	<0.000	4.4 ± 2.29	1.1 ± 0.92	<0.000
Mandibular dentition	Premolar	Buccal cusps	43	25	<0.000	2.1 ± 1.40	0.9 ± 0.88	0.002
		Lingual cusps	1	0	0.247	0.1 ± 0.22	0.0 ± 0.00	0.329
	Molar	Buccal cusps	181	84	<0.000	8.7 ± 2.09	3.0 ± 2.16	<0.000
		Lingual cusps	41	0	<0.000	2.0 ± 2.29	0.0 ± 0.00	0.001

Data are presented as n or mean ± standard deviation.

Table 2. Comparison of arch widths between open-bite and scissor deep-bite groups.

Arch width (mm)		Open bite		Scissor deep bite		P
		Mean	SD	Mean	SD	
Upper arch	U4	42.7	2.63	41.0	2.80	0.036
	U5	49.2	3.34	46.8	3.19	0.018
	U6M	53.5	3.56	52.7	3.02	0.378
	U6D	55.6	3.38	54.7	2.79	0.312
	U7M	61.1	3.29	59.6	3.24	0.135
	U7D	61.5	3.38	60.2	3.16	0.191
Mandibular arch	L4	37.0	2.54	33.9	3.11	0.001
	L5	42.6	3.44	39.6	2.38	0.001
	L6M	47.5	3.88	45.2	3.33	0.034
	L6D	51.0	4.43	48.6	3.22	0.036
	L7M	53.2	3.70	51.1	3.08	0.052
	L7D	55.7	3.74	53.6	2.72	0.046

SD: standard deviation. Note: The abbreviations in the second column represent the placement for measuring the tips of different cusps of the posterior teeth. U: maxilla, L: mandible, 4: first premolar, 5: second premolar, 6: first molar, 7: second molar, M: mesial cusp, D: distal cusp.

Discussion

In the clinical setting, the raising of posterior prosthetic crowns generally leads to an anterior open bite.⁴ In agreement with this, the present study showed that a buccal–lingual cusp-to-cusp relation of the posterior occlusion contacts (which increased the vertical dimension constituted by a cusp-to-fossa relation) was associated with an anterior open bite, a type of occlusion with an increased vertical dimension.² The open bite is generally associated with a wider mandibular arch dimension that geometrically contributes to the posterior buccal–lingual cusp-to-cusp relation. Furthermore, the number of worn posterior teeth cusp tips (especially the non-supporting cusps; i.e., the lingual cusps of the mandibular premolars and molars and the buccal cusps of the maxillary premolars and molars) was larger in the open-bite group than in scissor deep-bite group. The cusp-to-cusp relation led to tooth tip wear in both the supporting and non-supporting cusps in these young patients. Hence, we rejected our hypothesis.

Our finding that patients with an open bite had a wider mandibular dentition is in accordance with previous findings that an open bite is associated with abnormal tongue size or function.^{5–7} This means that enhanced tongue function or increased tongue volume may apply increased compression to the lingual side of the mandibular arch. Considering the general belief that a cusp-to-cusp occlusal relation produces a pressure concentration and is thus traumatic to the teeth or periodontal tissues, the weakening of the occlusal force that is often observed in patients with an open bite^{8–10} might be a protective response of the masticatory system to the cusp-to-cusp traumatic relation. Therefore, correction of the cusp-to-cusp to cusp-to-fossa relation in a buccal–lingual direction is helpful to reduce the vertical height of occlusion, leading to an improvement in the anterior open bite as shown in the current study. Accordingly, molar intrusion that reduces the posterior occlusal dimension^{11,12} and expansion of the maxillary arch¹³ are recommended as treatment strategies for an open bite. The skeletal pattern

is also related to the presence of an anterior open bite and posterior occlusal pattern, and the relationship between them still needs further research.

Based on the present results, an additional strategy for correcting a cusp-to-cusp relation to a cusp-to-fossa relation is suggested when aiming to decrease anterior vertical dimensions such as an open bite. For this purpose, using a method such as reshaping the occlusal surface of the posterior teeth is acceptable to establish a well-arranged cusp-to-fossa relation when orthodontic treatment is not possible. Moreover, after completing the orthodontic treatment, establishment of a stable cusp-to-fossa relation by occlusal adjustment should help to diminish the common occurrence of open-bite relapse¹⁴; however, this requires further exploration. Accordingly, an improvement in the deep bite relation can be achieved by increasing the posterior bite height beyond what is generally experienced; this is also worthy of further investigation. The inclination angle of the posterior teeth, such as the mesially inclined second molars in some patients with first molar loss, could also affect the vertical dimension. The relationship between the inclination angle of the posterior teeth and an open bite still needs further research. During treatment, the influence of growth should be kept in mind because patients with different posterior contact relations may develop different occlusion growth patterns, especially in the early developmental stage. The final occlusion is a result of many complex factors. In such cases, the orthodontic strategies employed would be far more complex than a simple correction of the cusp-to-cusp relation.

Conclusions

The present results indicate that the posterior buccal-lingual cusp-to-cusp relation plays a role in the anterior vertical

occlusion pattern, such as an open bite versus a deep bite. Establishing and maintaining a stable posterior cusp-to-fossa occlusal relation should be a major factor in the successful correction of anterior occlusion.

Declaration of conflicting interest

The authors declare that there is no conflict of interest.

Acknowledgement

The authors thank Mr. Gao Feng for collection of the study materials.

Funding

The author(s) disclosed receipt of the following financial support for the research, authorship, and/or publication of this article: The present study was supported by the National Nature Science Foundation of China (NSFC) (No. 30540130469).

References

1. Scheffler NR, Proffit WR and Phillips C. Outcomes and stability in patients with anterior open bite and long anterior face height treated with temporary anchorage devices and a maxillary intrusion splint. *Am J Orthod Dentofacial Orthop* 2014; 146: 594-602.
2. Uribe F and Nanda R. Management of open bite malocclusion. In: R Nanda (ed) *Biomechanics and esthetic strategies in clinical orthodontics*. St. Louis. Missouri: Elsevier Saunders, 2005: 156.
3. Uribe F and Nanda R. Management of open bite malocclusion. In: R Nanda (ed) *Biomechanics and esthetic strategies in clinical orthodontics*. St. Louis. Missouri: Elsevier Saunders, 2005: 131.
4. Sazegara H, Seyedan K and Behnia H. Prosthetic and surgical approach for oral rehabilitation in a patient with Amelogenesis Imperfecta: a clinical report. *J Dent* 2007; 4: 92-96.

5. Ngan P and Fields HW. Open bite: a review of etiology and management. *Pediatr Dent* 1997; 19: 91–98.
6. Speidel TM, Isaacson RJ and Worms FW. Tongue-thrust therapy and anterior dental open-bite. A review of new facial growth data. *Am J Orthod* 1972; 62: 287–295.
7. Melsen B, Stensgaard K and Pedersen J. Sucking habits and their influence on swallowing pattern and prevalence of malocclusion. *Eur J Orthod* 1979; 1: 271–280.
8. Proffit WR, Fields HW and Nixon WL. Occlusal forces in normal- and long-face adults. *J Dent Res* 1983; 62: 566–570.
9. Proffit WR and Fields HW. Occlusal forces in normal- and long-face children. *J Dent Res* 1983; 62: 571–574.
10. Bakke M and Michler L. Temporalis and masseter muscle activity in patients with anterior open bite and craniomandibular disorders. *Scand J Dent Res* 1991; 99: 219–228.
11. Gurton AU, Akin E and Karacay S. Initial intrusion of the molars in the treatment of anterior open bite malocclusions in growing patients. *Angle Orthod* 2004; 74: 454–464.
12. Alev Ç, Amir RA and Sercan A. Skeletal open bite correction with rapid molar intruder appliance in growing individuals. *Angle Orthod* 2007; 77: 632–639.
13. Cozza P, Baccetti T, Franchi L, et al. Treatment effects of a modified quad-helix in patients with dentoskeletal open bites. *Am J Orthod Dentofacial Orthop* 2006; 129: 734–739.
14. Guilherme J, Marcus VC, Karina MS, et al. Stability of anterior open-bite treatment with occlusal adjustment. *Am J Orthod Dentofacial Orthop* 2010; 138: 14–15.