



## Case Report

Spontaneous resolution of blastomycosis symptoms caused by *B. dermatitidis*Jennifer L. Anderson<sup>a,\*</sup>, Holly M. Frost<sup>b,c,d</sup>, Jennifer K. Meece<sup>a</sup><sup>a</sup> Integrated Research and Development Laboratory, Marshfield Clinic Research Institute, Marshfield Clinic Health System, Marshfield, WI, 54449, USA<sup>b</sup> Denver Health and Hospital Authority, Department of Pediatrics, Denver, CO, 80204, USA<sup>c</sup> Denver Health and Hospital Authority, Office of Research, Denver, CO, 80204, USA<sup>d</sup> University of Colorado School of Medicine, Department of Pediatrics, Aurora, CO, 80045, USA

## ARTICLE INFO

## Keywords:

Blastomycosis  
Spontaneous  
Symptom  
Resolution  
*Blastomyces dermatitidis*

## ABSTRACT

Given the propensity of blastomycosis to disseminate or reoccur and the inability to predict which infections will experience severe manifestations, nearly all cases of blastomycosis are treated. Although, spontaneous resolution of symptoms is referred to generally in the literature, to our knowledge an individual case of this has not been previously reported. We report the spontaneous resolution of blastomycosis symptoms in a 40 year-old Caucasian male.

## 1. Introduction

Blastomycosis, caused by *Blastomyces* spp., is primarily a pulmonary disease though dissemination to skin, bone, and other organs is common [1,2]. Cases are rare, usually causing moderate disease, but occasionally resulting in fulminant respiratory failure from acute respiratory distress syndrome and mortality in about 6% of cases. In North America, the disease occurs most commonly along the Ohio and Mississippi River valleys, in southeastern states, and around the Great Lakes [3].

Seven distinct species of *Blastomyces* have been described [4,5]. Of these, only *B. gilchristii* and *B. dermatitidis* have been broadly studied, with *B. gilchristii* being more often associated with pulmonary-only disease and *B. dermatitidis* being more likely to disseminate [6,7]. *B. dermatitidis* infections are typically less severe than those caused by *B. gilchristii* and are less likely to have an acute pulmonary presentation or result in hospitalization [7].

Half of all blastomycosis cases are thought to be asymptomatic [8,9]. Of patients who are symptomatic, nearly half (40%) of cases are mild and do not require hospitalization [6,7]. Given the propensity of blastomycosis to disseminate or reoccur and the inability to predict which infections will experience severe manifestations, including death, nearly all cases of blastomycosis are treated. Although, spontaneous resolution of cases is referred to generally in the literature [10,11], to our knowledge an individual case of this has not been previously reported. We report the spontaneous resolution of blastomycosis symptoms in a 40

year-old Caucasian male.

## 2. Case presentation

A 40 year-old Caucasian male with a past history of testicular cancer in remission presented to primary care at an outside health care center with a persistent cough (day 0). Chest x-ray showed left upper lobe consolidation and he was treated with a 10-day course of antibiotics (unspecified) for presumed bacterial pneumonia. At follow up, 14 days post presentation, the patient's chest x-ray was unchanged and on day +20 a CT scan was performed and left upper lobe consolidation with nodular infiltrates was documented. He was referred to Marshfield Clinic pulmonary medicine for further evaluation and when seen on day +31 he reported intermittent cough, occasionally productive sputum streaked with blood, but denied any other symptoms. Fungal antibody testing was ordered and was subsequently negative for *Histoplasma*, *Blastomyces*, *Coccidioides*, and *Aspergillus* and the patient was prescribed a 10-day course of moxifloxacin, which was extended to 15 days due to cough being improved, but not resolved. The patient presented again in pulmonary medicine on day +56 with unresolved cough and "feeling of fevers and chills". Labs were obtained and the patient's blood cell counts and ESR were all within normal ranges. On day +62 the patient returned for another chest CT (Fig. 1, Panel A). His chest infiltrate was unchanged and an attempt at sputum collection was unsuccessful. A bronchial wash specimen was obtained on day +80. The

\* Corresponding author.

E-mail address: [anderson.jennifer@MarshfieldResearch.org](mailto:anderson.jennifer@MarshfieldResearch.org) (J.L. Anderson).<https://doi.org/10.1016/j.mmcr.2020.10.003>

Received 15 September 2020; Received in revised form 19 October 2020; Accepted 20 October 2020

Available online 24 October 2020

2211-7539/© 2020 The Authors. Published by Elsevier B.V. on behalf of International Society for Human and Animal Mycology. This is an open access article

under the CC BY-NC-ND license (<http://creativecommons.org/licenses/by-nc-nd/4.0/>).

bronchial wash was negative by cytopathology for malignant cells, fungi, and *Pneumocystis*, but follow up culture was reported positive for *Blastomyces* on day 94. The culture specimen was bio-banked for pathogen genotyping at a later date. The patient was notified of culture results via telephone and was symptom-free without cough or sputum production at that time. Given that he was asymptomatic the decision was made to hold on antifungal treatment (as the disease “appears to be clinically controlled”) and he was instructed to return for CT and labs in 3 months’ time. The patient returned for follow-up on day +194. Chest CT was much improved with nodular opacities being reduced in size, in the left perihilar lung (Fig. 1, Panel B) and the physician determined the infection was “spontaneously resolving”. Urine antigen testing and/or repeat culture were not performed. The patient was counseled to follow up if he developed respiratory symptoms. He remained free of blastomycosis symptoms for the next 20 months, after which he moved out of state and was lost to follow up. The patient was seen 3 times in the 20 months prior to his move, twice in oncology to follow up on his past cancer and once in cardiology for an echocardiogram. During those visits he reported no new symptoms or concerns consistent with blastomycosis.

The previously bio-banked culture specimen was genotyped to determine *Blastomyces* species. DNA was extracted directly from the culture specimen and species-typed by sequencing a portion of the ITS2 rDNA as previously described [12]. The isolate was determined to be *B. dermatitidis*. Genotyping of the specimen was reviewed and approved, as part of a larger study, by the Marshfield Clinic Research Institute, Institutional Review Board.

### 3. Discussion

We report a mild case of culture confirmed pulmonary blastomycosis with spontaneous resolution of symptoms exclusive of treatment. The clinical presentation of blastomycosis is usually a mild to moderate respiratory illness, but can cause respiratory failure and death. Mild cases (non-hospitalized) make up about 40% of symptomatic cases [6, 7], although given the large number of asymptomatic cases (50%) [8,9] and similar presentation to other respiratory illnesses, it is likely that the reported incidence of blastomycosis is severely underestimated. Understanding what factors contribute, both host and pathogen, to clinically mild or asymptomatic disease manifestation, such as the one described here, versus those that result in fulminate respiratory failure are crucial to better outcomes for blastomycosis patients.

Diagnosis of this case was significantly delayed, 94 days from initial

presentation. Because the symptoms of blastomycosis may mimic other respiratory illnesses, like bacterial pneumonia, delays in diagnosis are common and sometimes result in worse outcomes [13]. We previously found that *B. gilchristii* infections, which tend to have a much more acute pulmonary presentation are diagnosed much faster than *B. dermatitidis* infections, which tend to have a much milder or masked pulmonary aspect [5,6]. This is likely due to both the differential pathogenicity of the 2 species and increased testing for patients with ARDS compared to those with less fulminant disease. The mild presentation of this case could be due to the etiologic agent being *B. dermatitidis* or alternatively, could have been due to low exposure inoculum. Both strain and inoculum have been shown to influence the speed of disease progression in a mouse model [14]. In histoplasmosis, a closely related fungal disease, severity is associated with exposure inoculum, and this is presumed to be true in regard to blastomycosis as well, although host immune-competency plays more of an additional protective role against histoplasmosis severity [15]. In this case, the diagnosis was delayed an additional 14 days as a result of so few organisms being present in the sample that they were undetectable on cytology. Two weeks of culture was required to grow visible colonies, indicating a low number of organisms clinically present. This is a common challenge with blastomycosis diagnoses as visualization with cytopathology depends on sufficient sample collection and number of organisms present. Culture results can take up to 30 days to be positive, but are routinely incubated for up to 6 weeks [10].

It is unknown what proportion of untreated or incompletely treated blastomycosis cases result in natural clearance, dissemination, prolonged subclinical infection, or return of fulminate infection. It is likely that natural clearance is much more common than reported given the large number of estimated asymptomatic patients and diagnostic challenges. Future studies assessing these outcomes are important because antifungals used to treat blastomycosis have numerous side effects including renal impairment and elevated liver function tests. Understanding natural clearance rates could prevent some patients from prolonged medication courses if unnecessary. Additionally, many patients receive shorter than recommended treatment courses due to medication intolerance, insurance challenges, or physician unfamiliarity with treating this rare disease. Long-term outcomes of patients who receive shorter than recommended duration of therapy are not known. The rates of natural clearance likely differ by *Blastomyces* species do to the pathogenicity differences, reflected in presentation and hospitalization as discussed above. Unfortunately, while urine antigen can assist with monitoring clearance, its use in mild or subclinical infections,

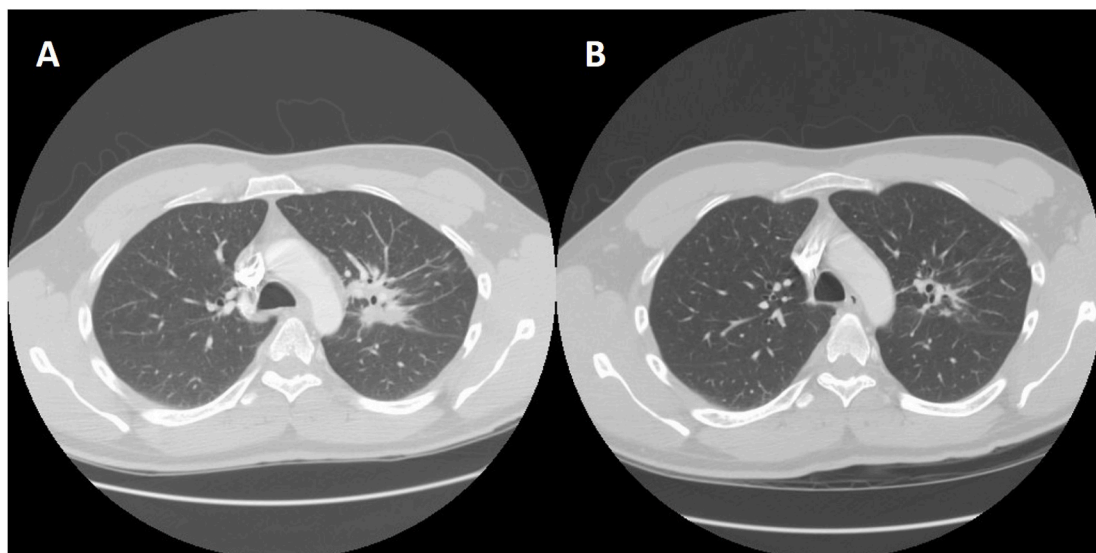


Fig. 1. (A) Chest CT with contrast, showing nodular infiltrates on + Day 62. (B) Chest CT with contrast, showing nodular opacities much improved on + Day 194.

disseminated disease, and *B. dermatitidis* infections may be limited [13, 16].

It is difficult to predict which blastomycosis cases will experience severe manifestations, including death [10]. In addition, infections can disseminate to other organ systems or reoccur after treatment in some cases. Due to these factors, both the Infectious Disease Society of America and American Thoracic Society assert that treatment is recommended for all blastomycosis patients, even if symptoms have already resolved by the time diagnosis is made [17,18]. We strongly agree that all blastomycosis patients should receive a full course of treatment (at least 6 months). In addition, we encourage close monitoring of all cases for relapse for at least 6 months post treatment. While rare, blastomycosis relapse has been well documented in the literature. Although most documented cases of infection relapse or reoccurrence emerge within 6 months after initial treatment, we previously documented a case of mild pulmonary blastomycosis that relapsed as disseminated CNS disease 18 months after itraconazole therapy [19]. In this case the patient was 20 months out without return of symptoms, which may indicate the infection was cleared without treatment, though this cannot be determined definitively.

In this report we describe the spontaneous resolution of symptoms in a mild case of blastomycosis infection. Further study of asymptomatic and mild self-resolving cases could provide much insight into pathogenesis and host immune response and contribute to future vaccine development. Understanding long-term outcomes in patients who have abbreviated treatment or symptoms resolution without treatment is important to improve clinical care.

### Funding

This work was supported by the Marshfield Clinic Research Institute, with support from MCRI's Infectious Diseases Distinguished Physician/Scientist Endowment, and the Denver Health and Hospital Authority. HF received salary support from the Eunice Kennedy Shriver National Institute of Child Health & Human Development of the National Institutes of Health under Award Number K23HD099925. The content is solely the responsibility of the authors and does not necessarily represent the official views of the National Institutes of Health.

### Declaration of competing interest

There are none.

### Acknowledgements

There are none.

### References

- [1] P.G. Pappas, W.E. Dismukes, Blastomycosis: gilchrist's disease revisited, *Curr. Clin. Top. Infect. Dis.* 22 (2002) 61–77.
- [2] J.K. Meece, J.L. Anderson, S. Gruszka, B.L. Sloss, B. Sullivan, K.D. Reed, Variation in clinical phenotype of human infection among genetic groups of *Blastomyces dermatitidis*, *J. Infect. Dis.* 207 (2013) 814–822.
- [3] R.W. Bradsher, S.W. Chapman, P.G. Pappas, Blastomycosis. *Infect Dis Clin North Am* 17 (2003) 21–40, vii.
- [4] I.S. Schwartz, N.P. Wiederhold, K.E. Hanson, T.F. Patterson, L. Sigler, *Blastomyces helicus*, a new dimorphic fungus causing fatal pulmonary and systemic disease in humans and animals in western Canada and United States, *Clin. Infect. Dis.* 68 (2019) 188–195.
- [5] K. Dukiki, J.F. Munoz, Y. Jiang, P. Feng, L. Sigler, J.B. Stielow, et al., Novel taxa of thermally dimorphic systemic pathogens in the *Ajellomyces* (*Onygenales*), *Mycoses* 60 (2017) 296–309.
- [6] J.K. Meece, J.L. Anderson, S. Gruszka, B.L. Sloss, B. Sullivan, K.D. Reed, Variation in clinical phenotype of human infection among genetic groups of *Blastomyces dermatitidis*, *J. Infect. Dis.* 207 (2013) 814–822.
- [7] J.L. Anderson, H.M. Frost, J.P. King, J.K. Meece, Racial difference in clinical phenotype and hospitalization of blastomycosis patients, *Open Forum Infect Dis* 6 (2019) ofz438.
- [8] F.E. Tosh, H.J. Hammerman, R.J. Weeks, G.A. Sarosi, A common source epidemic of North American blastomycosis, *Am. Rev. Respir. Dis.* 109 (1974) 525–529.
- [9] B.S. Klein, J.M. Vergeront, R.J. Weeks, U.N. Kumar, G. Mathai, B. Varkey, et al., Isolation of *Blastomyces dermatitidis* in soil associated with a large outbreak of blastomycosis in Wisconsin, *N. Engl. J. Med.* 314 (1986) 529–534.
- [10] M. Saccente, G.L. Woods, Clinical and laboratory update on blastomycosis, *Clin. Microbiol. Rev.* 23 (2010) 367–381.
- [11] R.W. Bradsher, Systemic fungal infections: diagnosis and treatment. I. Blastomycosis, *Infect. Dis. Clin.* 2 (1988) 877–898.
- [12] H.M. Frost, J.L. Anderson, L. Ivacic, B.L. Sloss, J. Embil, J.K. Meece, Development and validation of a novel single nucleotide polymorphism (SNP) panel for genetic analysis of *Blastomyces* spp. and association analysis, *BMC Infect. Dis.* 16 (2016) 509.
- [13] H.M. Frost, T.J. Novicki, *Blastomyces* antigen detection for diagnosis and management of blastomycosis, *J. Clin. Microbiol.* 53 (2015) 3660–3662.
- [14] J.E. Williams, S.A. Moser, Chronic murine pulmonary blastomycosis induced by intratracheally inoculated *Blastomyces dermatitidis* conidia, *Am. Rev. Respir. Dis.* 135 (1987) 17–25.
- [15] R.W. Bradsher, Histoplasmosis and blastomycosis, *Clin. Infect. Dis.* 22 (1996) S102–S111.
- [16] K.L. Laux, J.L. Anderson, S.P. Bentivenga, J.A. McBride, A. Sterkel, E. Matkovic, et al., Use of urine antigen detection in *B. dermatitidis* and *B. gilchristii* infections, *Clin. Med. Res.* (2020) 1534 (Online ahead of print).
- [17] S.W. Chapman, W.E. Dismukes, L.A. Proia, R.W. Bradsher, P.G. Pappas, M. G. Threlkeld, et al., Clinical practice guidelines for the management of blastomycosis: 2008 update by the infectious disease society of America, *Clin. Infect. Dis.* 46 (2008) 1801–1812.
- [18] A.H. Limper, K.S. Knox, G.A. Sarosi, N.M. Ampel, J.E. Bennett, A. Catanzaro, et al., An official American Thoracic Society statement: treatment of fungal infections in adult pulmonary and critical care patients, *Am. J. Respir. Crit. Care Med.* 183 (2011) 96–128.
- [19] J.L. Anderson, J.K. Meece, M.C. Hall, H.M. Frost, Evidence of delayed dissemination or re-infection with *Blastomyces* in two immunocompetent hosts, *Med Mycol Case Rep* 13 (2016) 9–11.