

RESEARCH ARTICLE

Clinical and ultrasonographic features of male breast tumors: A retrospective analysis

Wei-Hsin Yuan^{1,2,3*}, Anna Fen-Yau Li^{2,4}, Yi-Hong Chou^{2,3*}, Hui-Chen Hsu⁵, Ying-Yuan Chen^{2,6}

1 Division of Radiology, Taipei Municipal Gan-Dau Hospital (Managed by Taipei Veterans General Hospital), Taipei, Taiwan, Republic of China, **2** School of Medicine, National Yang Ming University, Taipei, Taiwan, Republic of China, **3** Department of Radiology, Taipei Veterans General Hospital, Taipei, Taiwan, Republic of China, **4** Department of Pathology, Taipei Veterans General Hospital, Taipei, Taiwan, Republic of China, **5** Department of Medical Imaging, Taiwan Adventist Hospital, Taipei, Taiwan, Republic of China, **6** Division of Radiology, National Yang-Ming University Hospital, Ilan City, Taiwan, Republic of China

* yhchou@vghtpe.gov.tw (YHC); williamyuan.tw@gmail.com (WHY)

Abstract

Objective

The purpose of this study was to determine clinical and ultrasonographic characteristics of male breast tumors.

Methods


The medical records of male patients with breast lesions were retrieved from an electronic medical record database and a pathology database and retrospectively reviewed. A total of 112 men (125 breast masses) with preoperative breast ultrasonography (US) were included (median age, 59.50 years; age range, 15–96 years). Data extracted included patient age, if the lesions were bilateral, palpable, and tender, and the presence of nipple discharge. Breast lesion features on static US images were reviewed by three experienced radiologists without knowledge of physical examination or pathology results, original breast US image interpretations, or surgical outcomes. The US features were documented according to the BI-RADS (Breast Imaging-Reporting and Data System) US lexicons. A forth radiologist compiled the data for analysis.

Results

Of the 125 breast masses, palpable tender lumps and bilateral synchronous masses were more likely to be benign than malignant (both, 100% vs 0%, $P < 0.05$). Advanced age and bloody discharge from nipples were common in malignant lesions ($P < 0.05$). A mass eccentric to a nipple, irregular shape, the presence of an echogenic halo, predominantly internal vascularity, and rich color flow signal on color Doppler ultrasound were significantly related to malignancy (all, $P < 0.05$). An echogenic halo and the presence of rich color flow signal were independent predictors of malignancy.

Conclusion

Specific clinical and US characteristics of male breast tumors may help guide treatment, and determine if surgery or conservative treatment is preferable.



OPEN ACCESS

Citation: Yuan W-H, Li AF-Y, Chou Y-H, Hsu H-C, Chen Y-Y (2018) Clinical and ultrasonographic features of male breast tumors: A retrospective analysis. PLoS ONE 13(3): e0194651. <https://doi.org/10.1371/journal.pone.0194651>

Editor: Gabriele Multhoff, Technische Universitat Munchen, GERMANY

Received: May 8, 2017

Accepted: March 7, 2018

Published: March 20, 2018

Copyright: © 2018 Yuan et al. This is an open access article distributed under the terms of the [Creative Commons Attribution License](https://creativecommons.org/licenses/by/4.0/), which permits unrestricted use, distribution, and reproduction in any medium, provided the original author and source are credited.

Data Availability Statement: All relevant data are within the paper.

Funding: The authors received no specific funding for this work.

Competing interests: The authors have declared that no competing interests exist.

Introduction

The majority of male breast lesions are benign; malignancy of the male breast is rare [1], accounting for only 0.7% to 1% of all breast cancers and 0.17% of all cancers in men [2, 3]. Gynecomastia within the subareolar regions is the most common benign condition of the male breast in newborns, adolescents, and the elderly [2, 3]. Gynecomastia is seen histologically in 50% of all men at autopsy [4]. Other reported benign masses of the male breast include epidermal cysts, lipomas, intraductal papillomas, pseudoangiomatous stromal hyperplasia, granular cell tumors, hemangiomas, schwannomas, myofibroblastomas, and fibromatosis [5, 6].

Men with breast lesions may present with various symptoms and signs that include a palpable breast mass, pain or tenderness, or even nipple discharge. Gynecomastia and the other benign masses usually are palpable and tender [1]. Approximately half of patients with gynecomastia have synchronous bilateral nodules [7]. Men who have one or more of the symptoms and signs often have significant anxiety or emotional distress, as they fear the lesions are malignant [8, 9]. In fact, gynecomastia often resolves spontaneously or upon removal of a causative medication, or treatment of a systemic or endocrine disease [4]. Management of male breast lesions may include fine needle aspiration cytology, excisional biopsy, or even mastectomy, mainly depending on the degree of suspicion of breast cancer, progressive enlargement, persistent gynecomastia, refractory response to medical therapy, and patient requests [4]. However, excessive surgical intervention may result in psychological, physical, and economic burden, and occasionally lead to complications.

Both ultrasound (US) and mammography are significantly more specific than physical examination for the evaluation of male breast masses [7]. Mammography can detect a suspicious mass, suspicious calcifications, and/or architectural distortion of breasts of both sexes, and can evaluate gynecomastia on male breasts [1, 2]. A non-calcified mass is the most common mammographic finding in male breast cancer [2]. However, some case reports have shown that male breast cancers were not detected by mammography [3]. There are no statistically significant differences between the sensitivity and specificity of mammography and US in diagnosing male breast lesions [2, 7]. In addition, a male receiving diagnostic mammography needs to undergo exposure to ionizing radiation, and this is especially inappropriate for adolescents.

Ultrasonography is recommended for the evaluation of male breast lesions because it is a convenient, non-invasive, and low-cost tool that does not require exposure to ionizing radiation [3]. The BI-RADS (Breast Imaging-Reporting and Data System) US lexicon [10] is widely used to describe the characteristics of breast lesions in women. Some US features associated with female breast cancer are irregular shape, nonparallel orientation, non-circumscribed margins, echogenic halo, and increased vascularity in the lesion [11]. However, as breast lesions in men are much less commonly seen than in women, the US features of lesions in the male breast are not well established.

The purpose of this retrospective study was to describe clinical and US features of male breast tumors and their correlations to pathologic findings following biopsies or surgery with a view towards helping to evaluate and manage breast masses in males.

Materials and methods

Patients and preoperative clinical presentations

The Institutional Review Board of Taipei Veterans General Hospital (TVGH) approved the study, and waived patient informed consent because of the retrospective nature.

Inclusion criteria for this study were patients with preoperative breast sonographic images and biopsy and/or postoperative pathology of male breast lesions. Once patients received operation in TVGH, surgeon always submit their biopsy specimens or excised tissue to the pathology department in TVGH for examination. Patients with only imaging results or clinical diagnosis were excluded. Biopsy or postoperative pathological examination results served as the final diagnostic standard.

A research assistant blind to the study hypothesis abstracted medical findings and pathology results from the electronic medical record database and pathology database at TVGH using the index terms “male” and “breast”. Over an 8-year period from January 1, 2007 to December 31, 2014, 1,319 male patients had records matching the search terms.

Of the 1,319 patients, 1,110 who did not receive a biopsy or surgery were excluded. Of the remaining 209 patients who received either a biopsy or surgery, 97 were excluded: 11 with inadequate specimens, 19 who were actually females, and 67 without preoperative breast US. Thus, a total of 112 males who had breast US and a postoperative pathological diagnosis were included in the study.

The median age of the 112 patients 59.50 ± 20.19 years (mean age 60.36 years, range 15–96 years), and age was not normally distributed. Preoperative findings included a non-tender palpable lump in 61 (55%) patients, bilateral nontender lumps (one in each breast) in 8 (7%), two lumps in the left breast and one in the right in 1 (1%), bilateral tender palpable lumps (one in each breast) in 1 (1%), areolar swelling bilaterally in 1 (1%), bilateral breast tenderness in 1 (1%), one tender palpable lump in 24 (21%), nontender unilateral areolar swelling in 2 (2%), tender unilateral areolar swelling in 5 (5%), unilateral bloody nipple discharge in 2 (2%), unilateral serous nipple discharge in 1 (1%), a tender lump and serous nipple discharge in 1 (1%), and unilateral breast tenderness in 4 (4%).

Sonographic examination

Ultrasound was performed from 1 day to 1 week of the physical examination. Technicians with at least 10 years' experience at the departments of radiology performed the bilateral breast US examinations. Examinations were performed with the patient in the supine position with a scanner using high-resolution linear probes (L12–5 MHz) (S2000 Siemens Healthcare, Mountain View, CA; HDI 5000 and IU 22; Philips Healthcare, Bothell, WA; and LOGIQ E9; GE Healthcare, Milwaukee, WI). The technicians also performed color Doppler US (CDU) if a breast mass was detected, using an appropriate Doppler setting after the gray scale US study. The Doppler gain setting was adjusted to a level associated with minimal noise. The technicians examined a breast in four planes (sagittal, transverse, radial, and orthogonal), and obtained images at the 12 o'clock, 2 o'clock, 4 o'clock, 6 o'clock, 8 o'clock, and 10 o'clock positions, and of the nipple and axilla. If something suspicious was detected, multiple images in different planes were obtained on gray-scale US and CDU. The size, site, and distant to the nipple of lesions were recorded. After the bilateral examination was completed, all images were uploaded to a picture archiving and communication system (PACS) for storage. Revision of static US images was not allowed.

Sonography interpretation

Two experienced radiologists (H-CH, with 20 years of experience, and Y-YC with 10 years of experience), without knowledge of the physical examination findings, the previous preoperative breast image interpretation, or the histopathological results, reinterpreted the preoperative static breast US images of all 125 masses. Final results were determined by consensus. Disagreement were resolved by a third radiologist (Y-HC with 35 years of experience). The following 13 features were recorded for each of the images: maximum diameter of the lesion, site, relationship to the nipple, echotexture, echo pattern, homogeneity, shape, margin, boundary,

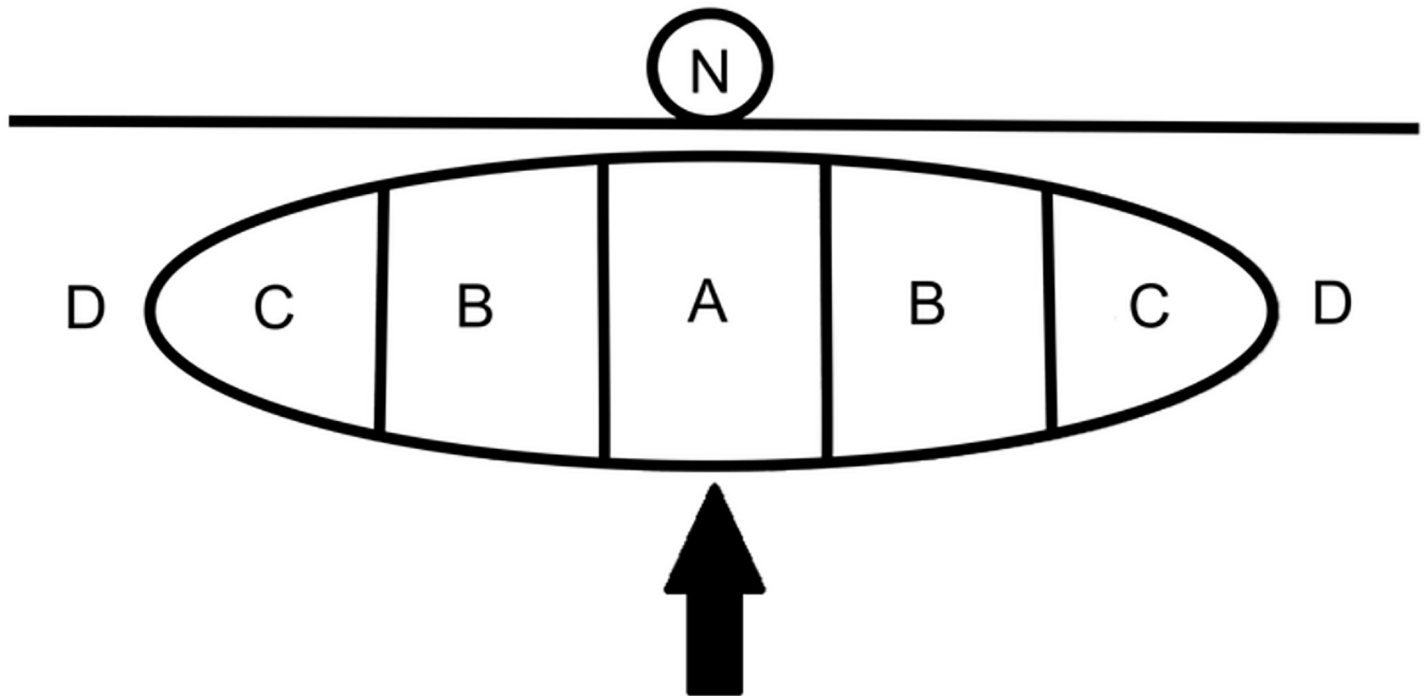


Fig 1. The relationship of a mass to a nipple. The mass (arrow) is divided into five parts of equal width. When part A is located below the center of a nipple, it is classified as concentric to the nipple, as in this example. When part B is below the nipple, it is classified as mildly eccentric to the nipple. If part C is below the nipple or the mass is in area D and not below the nipple at all, it is classified as markedly eccentric to the nipple.

<https://doi.org/10.1371/journal.pone.0194651.g001>

orientation, posterior acoustic features on gray-scale US, and vascularity and grading on CDU. The lesion diameter (mm) was determined by the maximum diameter shown on US. The lesion site was the right or left breast. For the relationship to the nipple, we divided a mass into five parts of equal width (Fig 1). When the center of the mass (part A) was located under the center of a nipple, the mass was classified as concentric to the nipple. If it was somewhat off center, with part B under the nipple, it was classified as mildly eccentric to the nipple. If either part C or none of the mass was under a nipple, it was classified as markedly eccentric to the nipple.

The echotexture of each mass was characterized as cystic (cystic changes > 75% of a mass), solid (cystic changes < 25% of a mass), or solid and cyst (cystic changes 25–75% of a mass). Color flow distribution was defined as absent, vessels predominantly in the rim, or predominantly internal vascularity. Color flow grading of a mass on CDU was classified as low color flow signal or rich color flow signal. Low color flow signal was defined as the absence of color signals, the presence of occasional transient color pixels, or the presence of only a single color flow signal in or around the mass. Rich color flow signal was defined as multiple color pixels, multiple pedicles of blood supply, or the presence of multiple well-defined vessels in or around the mass. The image with the maximum color flow signals for each mass was chosen for grading.

Other US findings, including echo pattern, heterogeneity, shape, margin, boundary, orientation, and posterior acoustic features, were recorded according to BI-RADS sonographic lexicon classification. The echo pattern relative to fat was classified as anechoic, hypoechoic, isoechoic, hyperechoic, or complex. Heterogeneity was reported as predominantly homogeneous or heterogeneous. Shape was classified as oval, round, or irregular. The margin was defined as circumscribed or noncircumscribed. A circumscribed margin indicated a well-

defined or sharp border with an abrupt transition between the lesion and surrounding tissue. The margin of a breast mass was classified as noncircumscribed if the margin had one or more of the following features: an indistinct, angular, microlobulated, or spiculated margin. The mass boundary was defined as an abrupt interface or echogenic halo. Orientation was classified as parallel or nonparallel. Parallel orientation indicated that the long axis of the mass was parallel to the surface of the skin or the anterior-posterior diameter of the mass was shorter than the transverse diameter. Nonparallel orientation indicated that the long axis of the mass was perpendicular to the surface of skin or the anterior-posterior diameter of the mass was equal to or larger than the transverse diameter. The posterior acoustic appearance was categorized as normal, enhancement, or shadowing. Because microcalcifications on conventional US are not easily determined during the examination [12], microcalcifications were not recorded on the re-evaluation of the images.

Histopathologic evaluation

Within 1 day to 5 months of the US examination, all 112 patients underwent a needle biopsy, excisional biopsy, or mastectomy, yielding a total 125 specimens for histopathological examination. This included tissue from one lesion in 100 patients, two lesions in 11 patients, and three lesions in 1 patient. One experienced pathologist (A-FL) with 25 years of experience and without knowledge of the preoperative US findings, retrospectively reviewed all the microscope slides from the 112 patients and confirmed the histopathological results for all 125 lesions.

A fourth radiologist (W-HY) integrated the clinical findings, histopathological results, and the US interpretations of all 125 masses to analyze the clinical and US characteristics, and their association with pathological results.

Statistical analysis

Data were analyzed with SPSS version 19.0 software (SPSS Inc., Chicago, IL). The level of significance was set at $P < 0.05$. An unpaired *t* test was used to compare continuous variables (age and maximum diameter), and a χ^2 or Fisher exact test for categorical variables. Statistically significant US variables were further assessed by multivariate logistic regression analysis, with calculation of odds ratios (ORs) and 95% confidence intervals (CIs).

Results

Preoperative clinical findings

[Table 1](#) summarizes the preoperative clinical findings of the 125 breast lesions in 112 male patients. The mean age of the 87 patients with breast benign masses was 56.68 ± 20.51 years (range 15–88 years), and that of 25 patients with breast malignancies was 73.16 ± 12.63 years (range 50–96 years) ($P < 0.001$). In addition to advanced age, bloody discharge from the nipple was also significantly associated with malignancy ($P = 0.0387$, Fisher's exact test). In contrast, bilateral synchronous masses and palpable tender lumps were more likely to be benign (both, 100% vs 0%, $P = 0.0037$ and $P = 0.0019$, respectively, Fisher's exact test). Of the 125 masses, 50 (40%) that were bilateral and/or palpable tender lumps were benign, and 2 (1.6%) with bloody discharge from the nipple were malignant.

Ultrasound features

[Table 2](#) summarizes the gray-scale US findings of all 125 breast lesions. The features of the masses on color Doppler ultrasonography are summarized in [Table 3](#). Mildly or markedly eccentric

Table 1. Clinicopathologic characteristics of 125 breast masses in males.

Variables	N (%)	Benign (%)	Malignant (%)	P value
Mean of age ±SD		56.68±20.51	73.16±12.63	< 0.001
Laterality	125			0.0037 ^a
Unilateral	100(80)	75(75)	25(25)	
Bilateral	25(20)	25(100)	0(0)	
Palpable lump	125			1.0000 ^a
Present	107(86)	85(79)	22(21)	
Absent	18(14)	15(83)	3(17)	
Palpable tender lump	125			0.0019 ^a
Present	27(22)	27(100)	0(0)	
Absent	98(78)	73(74)	25(26)	
Tender, nonpalpable	125			0.6922 ^a
Present	11(9)	10(91)	1(9)	
Absent	114(91)	90(79)	24(21)	
Bloody discharge, nipple	125			0.0387 ^a
Present	2(2)	0(0)	2(100)	
Absent	123(98)	100(81)	23(19)	
Serous discharge, nipple	125			1.0000 ^a
Present	2(2)	2(100)	0(0)	
Absent	123(98)	98(80)	25(20)	
Swelling, nonpalpable	125			0.5829 ^a
Present	4(3)	4(100)	0(0)	
Absent	121(97)	96(79)	25(21)	

SD, standard deviation; N (%), number (percentage).

^a Fisher’s exact test.

<https://doi.org/10.1371/journal.pone.0194651.t001>

to nipple ($P = 0.044$), round or irregular shape ($P = 0.044$), presence of an echogenic halo ($P < 0.001$), predominantly internal vascularity ($P = 0.006$), and rich color flow signal ($P < 0.001$) were significantly associated with malignancy (Figs 2–7). At least 1 of 5 statistically significant US features was present in each malignancy. In addition, the mean maximum diameter, echotexture, echo pattern, heterogeneity, margins, orientation, and posterior acoustic features were not helpful for distinguishing malignant (Figs 2–7) from benign masses (Figs 8–11).

As shown in Table 4, multivariate logistic regression analysis identified echogenic halo (OR = 3.955; 95% CI: 1.005–15.564; $P = 0.049$) and the presence of a rich color flow signal (OR = 8.330; 95% CI: 1.505–46.102; $P = 0.015$) as independent factors for malignancy. These 2 independent risk factors accounted for 19 (76%) of 25 malignancies.

Table 5 summarizes the histopathological results of the 125 lesions. Twenty-five of the 125 masses (20%) were malignant (Figs 2–7) and 100 (80%) were benign (Figs 8–11). The most common malignancy was invasive ductal carcinoma (17/25, 68%) (Figs 2–5), whereas gynecomastia was the most common type of benign mass (53/100, 53%) (Figs 8–10).

Of the 12 patients with synchronous bilateral benign masses, 1 had bilateral pseudogynecomastia in the subareolar area, 1 had epidermal cysts in each breast, and the other 10 had bilateral gynecomastia, of whom 1 also had a benign palpable lymph node in the left breast near the axilla.

As shown in Table 1, being palpable was not different for benign versus malignant masses (79% vs 21%, $P = 1.0$, Fisher’s exact test). The 3 nonpalpable malignant masses included: 1 ductal carcinoma *in situ* with bloody nipple discharge, 1 intraductal papilloma with ductal

Table 2. The features of 125 breast masses in males on gray-scale ultrasonography.

Feature	N (%)	Benign (%)	Malignant (%)	P value
MMD ± SD, mm		19.97 ± 11.17	24.29 ± 13.84	0.103
Relationship to nipple	125			0.044
Concentric	56 (45)	50 (89)	6 (11)	
Mildly eccentric	24 (19)	16 (67)	8 (33)	
Markedly eccentric	45 (36)	34 (76)	11 (24)	
Echotexture	125			0.464 ^a
Cystic	1 (1)	1(100)	0 (0)	
Solid and cystic (mixed)	5 (4)	3 (60)	2 (40)	
Solid	119(95)	96 (81)	23 (19)	
Echo pattern	125			0.710 ^a
Anechoic	1 (1)	1 (100)	0 (0)	
Hypoechoic	110(88)	88 (80)	22 (20)	
Isoechoic	2 (2)	2 (100)	0 (0)	
Hyperechoic	7 (6)	6 (86)	1 (14)	
Complex	5 (4)	3 (60)	2 (40)	
Heterogeneity	125			0.088
Predominantly homogeneous	69 (55)	59 (86)	10 (14)	
Heterogeneous	56 (45)	41 (73)	15 (27)	
Shape	125			0.044 ^a
Round	4 (3)	2 (50)	2 (50)	
Oval	43 (34)	39 (91)	4 (9)	
Irregular	78 (62)	59 (76)	19 (24)	
Margin	125			0.177
Circumscribed	39 (31)	34 (87)	5 (13)	
Non-circumscribed	86 (69)	66 (77)	20 (23)	
Boundary	125			<0.001 ^a
Abrupt interface	108(86)	92 (85)	16 (15)	
Echogenic halo	17(14)	8 (47)	9 (53)	
Orientation	125			0.618
Parallel	90 (72)	73 (81)	17 (19)	
Nonparallel	35 (28)	27 (77)	8 (23)	
Posterior acoustic feature	125			0.632
Normal	85 (68)	70 (82)	15 (18)	
Enhancement	36 (29)	27 (75)	9 (25)	
Shadowing	4 (3)	3 (75)	1 (25)	

MMD, mean maximum diameter; SD, standard deviation; N (%), number (percentage);

^aFisher's exact test.

<https://doi.org/10.1371/journal.pone.0194651.t002>

carcinoma *in situ* presenting with bloody nipple discharge, and 1 invasive ductal carcinoma presenting with left breast with tenderness. Furthermore, 1 palpable tender mass with serous nipple discharge was chronically inflamed tissue. A nonpalpable lipoma presented with serous discharge from the right nipple, while the other nonpalpable benign masses presented with focal breast swelling and/or tenderness on physical examination.

As shown in Table 2, relative to the position of the nipple, of the 50 benign lesions with concentric features 38 (76%) were gynecomastia (Fig 8) and 12 (24%) were not. Of 16 benign conditions with mildly eccentric features, 10 (63%) were gynecomastia (Fig 9) and 6 (38%) were

Table 3. The features of 125 breast masses in males on color Doppler ultrasonography.

Feature	N (%)	Benign (%)	Malignant (%)	P value
Color Flow Distribution	125			0.006
Absent	49 (39)	46 (94)	3 (6)	
Vessels predominantly in the rim	25 (20)	19 (76)	6 (24)	
Predominantly Internal vascularity	51 (41)	35 (69)	16 (31)	
Color Flow Grading	125			<0.001
Low color flow signal	93 (74)	82 (88)	11 (12)	
Rich color flow signal	32 (26)	18 (56)	14 (44)	

N (%), number (percentage).

<https://doi.org/10.1371/journal.pone.0194651.t003>

not. Of 34 conditions with markedly eccentric features, 5 (15%) were gynecomastia (Fig 10) and 29 (85%) were not (Fig 11). One cystic mass was a benign lymphangioma with an anechoic pattern. Of the 5 lesions with solid and cystic echotexture, 3 (60%) were benign masses including 2 abscesses and 1 area of chronic inflammation, and 2 (40%) were malignant and both were invasive ductal carcinomas (Fig 5). Five masses with a complex echo pattern were non-gynecomastia lesions with solid and cystic texture.

Of the 39 oval lesions that were benign, 22 (56%) were gynecomastia (Fig 9) and 17 (44%) were not. Of 59 masses with an irregular shape, 31 (53%) were gynecomastia (Figs 8 and 10), and 28 (47%) were benign non-gynecomastia (Fig 11). Of 4 round masses, the 2 (50%) benign round masses were a myofibroblastoma and an abscess. The 8 benign conditions with an echogenic halo included 2 cases of gynecomastia, 1 of reactive hyperplasia of a lymph node, 1 epidermal cyst with rupture, 1 neurofibroma, 1 myofibroblastoma, 1 case of nodular fasciitis, and 1 of stromal fibrosis (Fig 11). Of 27 benign lesions with nonparallel orientation, 7 (26%) lesions were gynecomastia and 20 (74%) were not. In terms of posterior acoustic features, of 27 benign lesions with posterior acoustic enhancement, 9 (33%) masses were gynecomastia and 18 (67%) were not. Of 3 benign lesions with shadowing, all (100%) were gynecomastia.

As shown in Table 3, among 46 benign masses with absent color flow vascularity, 26 (57%) were gynecomastia and 20 (44%) were not (Fig 11). Of 19 with vessels predominantly in the rim, 6 (32%) were gynecomastia (Fig 8) and 13 (68%) were not. Of 35 with predominantly internal vascularity, 21 (60%) were gynecomastia (Figs 9 and 10) and 14 (40%) were not. Of 82 benign lesions with low color flow signal, 44 (54%) were gynecomastia and 38 (46%) were not. Moreover, 9 (50%) of 18 masses with rich color flow signal were gynecomastia.

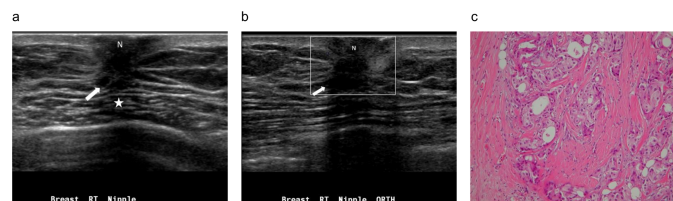


Fig 2. A palpable lump in the right breast of a 66-year-old man. (a) Radial ultrasound shows an irregular shape, a noncircumscribed margin, and a heterogeneously hypoechoic, subareolar, solid nodule (arrow). The nodule has a nonparallel orientation, an abrupt interface, posterior acoustic shadowing (star), and a concentric relationship to the nipple (N). There is no echogenic halo. (b) Color Doppler ultrasound shows an absence of vessels in the nodule, categorized as a low color flow signal (arrow). (c) Pathology specimen shows invasive ductal carcinoma with a surrounding fibrous reaction. Collagen fibers are arranged in laminated layers. There is no tumor necrosis. (Hematoxylin-eosin, original magnification $\times 200$).

<https://doi.org/10.1371/journal.pone.0194651.g002>

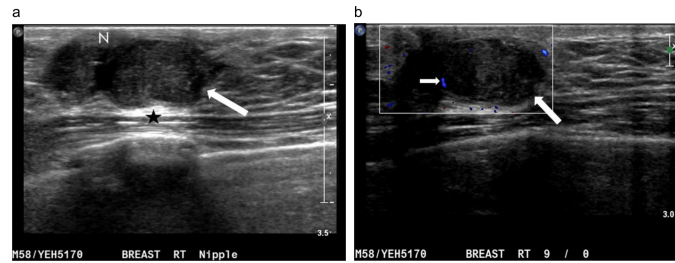


Fig 3. A palpable nodule in the right breast of a 58-year-old man. (a) Radial sonogram shows an irregular shape, a noncircumscribed margin, and a heterogeneously hypoechoic, subareolar nodule (arrow). The nodule has a parallel orientation and a mildly eccentric relationship to the nipple (N). There is posterior acoustic enhancement (black star). (b) Transverse color Doppler ultrasound shows a short color flow signal (short arrow) in the nodule (long arrow), categorized as low color flow with predominantly internal vascularity. The postoperative pathological diagnosis is invasive ductal carcinoma.

<https://doi.org/10.1371/journal.pone.0194651.g003>

Discussion

Male breast cancer is much less common than gynecomastia and other benign breast pathologies [4], which makes it challenging for clinicians to differentiate malignancies from benign conditions in men with breast masses. Benign conditions of the male breast usually need only conservative therapy, but breast malignancies require timely surgical intervention. Clinical examination is the first step towards evaluating male breast masses. In our study, advanced age (mean age 73.16 vs. 56.68 years, $P < 0.001$) and bloody discharge from the nipple ($P = 0.0387$) were significant clinical features associated with malignancy. Synchronous bilateral lesions and palpable tender lumps were more likely to be benign than malignant. Of the 125 masses, 50 (40%) that were bilateral and/or palpable tender lumps were benign; 2 (1.6%) with bloody discharge from nipple were malignant. Among US features, being eccentric to a nipple, having an irregular shape, the presence of an echogenic halo, the presence of internal vascularity, and a rich color flow signal were all significantly associated with malignancy. Moreover, the presence of an echogenic halo and a rich color flow signal were independent predictors of breast malignancy. Six (4.8%) of 125 masses with anechoic cystic echotexture or complex solid and cyst features were all non-gynecomastia lesions.

Clinical presentations in concert with US assessment may help the evaluation and management of male breast masses. Gynecomastia or non-gynecomastia benign masses usually

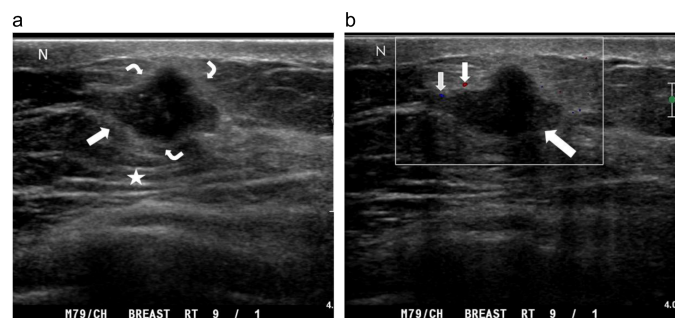


Fig 4. A palpable lump in the right breast of a 79-year-old man. (a) Radial ultrasound shows an irregular shape, a noncircumscribed margin, and a heterogeneously hypoechoic, subareolar, solid nodule (straight arrow). The nodule has a parallel orientation, an echogenic halo (curved arrows), posterior acoustic enhancement (star), and a markedly eccentric relationship to the nipple (N). (b) Color Doppler ultrasound shows transient occasional color pixels (short arrows) around the nodule (long arrow), classified as a low color flow signal with vessels predominantly in the rim. The postoperative pathological diagnosis is invasive ductal carcinoma.

<https://doi.org/10.1371/journal.pone.0194651.g004>

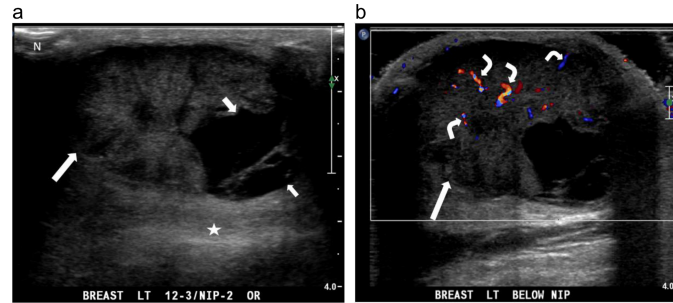


Fig 5. A palpable mass in the left breast of an 84-year-old man. (a) anti-radial ultrasound shows an oval-shaped, circumscribed mass (long arrow) with solid and cystic (small arrows) components. There is posterior acoustic enhancement (star) and a markedly eccentric relationship to the nipple (N). (b) Color Doppler ultrasound shows multiple color pixels and multiple pedicles of blood supply (curve arrows) in the mass, categorized as a rich color flow signal with predominantly internal vascularity. The postoperative pathological diagnosis is invasive ductal carcinoma.

<https://doi.org/10.1371/journal.pone.0194651.g005>

present as palpable tender lesions [1, 4]. Synchronous, bilateral nodules in the subareolar areas are present in approximately half of patients with gynecomastia [7]. Our research results are compatible to those of prior studies that suggested US might not be necessary for bilateral and/or palpable tender lumps (50/125, 40%) in male breasts ($P < 0.05$). Correcting underlying cause of gynecomastia and close follow-up might be a good strategy for managing bilateral and/or palpable tender lumps [4]. In converse, male breast cancer usually presents as an unilateral, palpable, and painless lump [1]. The incidence of synchronous bilateral breast cancers is in men reported to be only 1.5% to 2% of all male breast cancers [13]. Moreover, bloody nipple discharge or retraction and axillary lymphadenopathy might be present in the case of malignancy [1]. Bloody nipple discharge is found in 25% of men with breast cancers [5]. In our study, 2 of 2 masses presenting as bloody nipple discharge were malignant ($P = 0.0387$). Previous reports have shown that the mean age at diagnosis of male breast cancer is 67–69 years [6, 14, 15, 16], which is younger than the mean age of our patients (73.16 years). Timely biopsy might be performed when the male breast masses (75/125, 60%) exhibit significantly malignant clinical and US features, such as advanced age, bloody discharge from the nipple, presence of an echogenic halo, and a rich blood flow signal. However, when conservative treatment for any mass is not effective, biopsy or excision should be performed [4].

The relationship between US features of malignant breast lesions and pathological characteristics of breast cancers have been reported [5, 6, 8, 17–19]. An irregular shape and

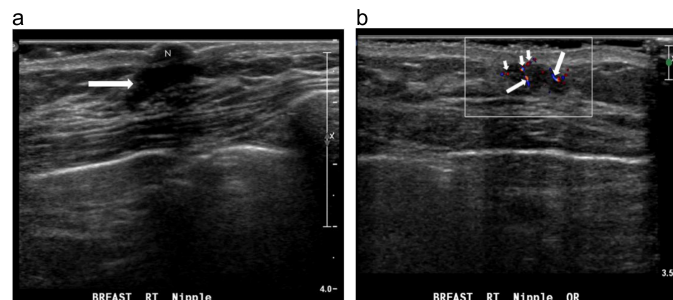


Fig 6. A nonpalpable nodule in the right breast of a 77-year-old man with bloody discharge from the right nipple. (a) Radial sonogram shows an irregular shape, a noncircumscribed margin, a mildly eccentric, homogeneously hypoechoic, subareolar nodule. The nodule has a parallel orientation and an abrupt interface. Neither an echogenic halo nor posterior features are present. (b) Transverse color Doppler ultrasound shows multiple color pixels (short arrows) and short pedicles of blood supply (long arrows) in the nodule, categorized as a rich color flow signal with predominantly internal vascularity. The postoperative pathological diagnosis is ductal carcinoma *in situ*.

<https://doi.org/10.1371/journal.pone.0194651.g006>

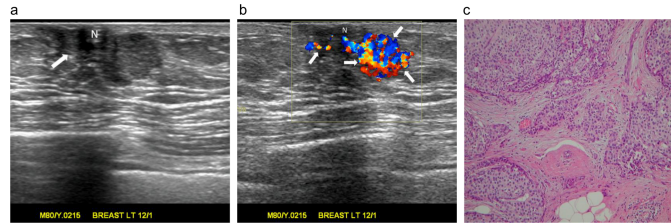


Fig 7. A palpable lump in the left breast of an 80-year-old man. (a) Radial sonogram shows an irregular shape, a noncircumscribed margin, a heterogeneously hypoechoic, subareolar, solid nodule (arrow). The nodule has a parallel orientation (arrow) and a concentric relationship to the nipple (N). There is an abrupt interface. (b) Color Doppler ultrasound shows multiple color pixels and pedicles of blood supply (arrows) pooling in the nodule, classified as a rich color flow signal with predominantly internal vascularity. (c) Pathology specimen shows an invasive papillary carcinoma with tissue invasion and fibrous reaction. There is no tumor necrosis. (Hematoxylin-eosin, original magnification $\times 100$).

<https://doi.org/10.1371/journal.pone.0194651.g007>

noncircumscribed margins on US suggest tumor invasion into surrounding tissue. Nonparallel orientation may represent tumor spread through tissue-plane boundaries [20]. Posterior acoustic shadowing may indicate a desmoplastic reaction in breast cancers. More highly vascular lesions and intralesional color flow signals on CDU are compatible with increased angiogenesis in breast malignancies [18].

Gynecomastia in its early stage is characterized histologically by proliferation of intraductal epithelium, periductal inflammation, and surrounding edema, which clinically corresponds to a painful breast mass and usually appears on US as a hypoechoic oval nodule with a well circumscribed margin in the subareolar region [14]. However, late stage gynecomastia has dilated ducts surrounding stromal fibrosis, and usually presents as a hypoechoic lesion with an irregular, ill-defined, or macrolobulated margin [5, 14]. In our study, some masses in cases of gynecomastia (Figs 8–10) had various projections, which could develop a nonparallel orientation, and noncircumscribed margins mimicking breast cancer. These particular US features, therefore, were not helpful in our series for differentiating malignant from benign conditions. The situation is different in women, where the 3 most common breast masses are simple cysts, fibrocystic changes, and fibroadenoma [21, 22]. These usually present with typical benign US features with high predictive value: an oval shape, circumscribed margins, an abrupt interface, and a homogeneous echo texture.

Previous studies have demonstrated that heterogeneity and hypoechoic features are not useful in differentiating benign from malignant male breast lesions [2, 6, 23]. Hyperechogenicity is thought to be a reliable predictor of benignity, but there was a malignant mass in our series

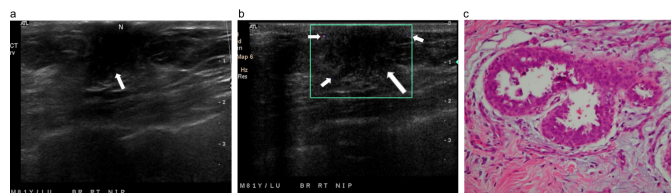


Fig 8. A palpable tender lump in the right breast of an 81-year-old man. (a) Radial ultrasound shows an irregular shape, a noncircumscribed margin, and a homogeneously hypoechoic, subareolar, solid nodule (arrow). The nodule has a nonparallel orientation and a concentric relationship to the nipple (N). (b) Color Doppler ultrasound shows occasional transient pixels (short arrows) around the nodule (long arrow), classified as a low color flow signal with flow predominantly in the rim. (c) Pathology specimen shows gynecomastia characterized by intraductal epithelial hyperplasia and proliferation of periductal collagenous connective tissue (hematoxylin-eosin, original magnification $\times 100$).

<https://doi.org/10.1371/journal.pone.0194651.g008>

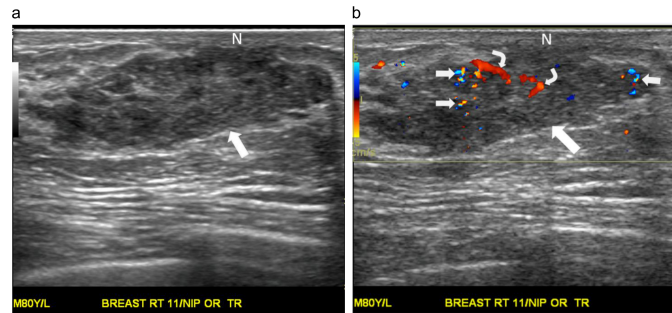


Fig 9. A palpable mass in the right breast of an 80-year-old man. (a) Transverse ultrasound shows an oval shape, a noncircumscribed margin, and a heterogeneously hypoechoic, solid nodule (arrow). The nodule has a parallel orientation and a mildly eccentric relationship to the nipple (N). (b) Color Doppler ultrasound shows multiple color pixels (short arrows) and two pedicles of blood supply (curve arrows) in the nodule (long arrow), categorized as a rich color flow signal with predominantly internal vascularity. The postoperative pathological diagnosis is gynecomastia.

<https://doi.org/10.1371/journal.pone.0194651.g009>

with heterogeneous hyperechogenicity. Posterior acoustic enhancement has been reported to be associated with relative preservation of the transmitted ultrasound beam distal to a mass [24]. Fluid, mucin, hemorrhage, or necrosis usually results in the appearance of posterior acoustic enhancement [25, 26]. Conversely, Maturen et al. considered that fluid within a mass was not required for posterior acoustic enhancement [24]. Any mass with a simple internal architecture might have posterior enhancement on US, which may be why in our study the appearance of posterior features did not differ significantly between malignant and benign lesions.

In terms of the relationship of male breast masses to the nipple, we found that lesions mildly or markedly eccentric from nipple were significantly associated with cancer; in contrast, masses concentric to the nipple were significantly more likely to be benign ($P = 0.044$). Prior studies have also suggested that gynecomastia usually appears as a concentric subareolar mass, while other benign masses and cancers in men are usually eccentric to the nipple-areolar complex [14, 27]. However, eccentricity to the nipple was present in some cases of gynecomastia in our study, as well as with a number of other benign lesions, so the relationship of the lesion to the nipple was not a statistically significant independent predictor of malignancy.

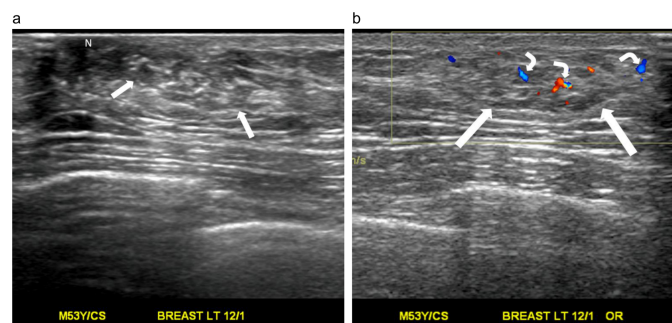


Fig 10. A palpable lump in the left breast of a 53-year-old man. (a) Radial ultrasound shows an irregular shape, a noncircumscribed margin, and a heterogeneously isoechoic, solid nodule (arrows). The nodule has a parallel orientation and a markedly eccentric relationship to the nipple (N). (b) Color Doppler ultrasound shows occasional transient color pixels and multiple short pedicles of blood supply (curve arrows) in the nodule (straight arrows), classified as a rich color flow signal with predominantly internal vascularity. The postoperative pathological diagnosis is gynecomastia.

<https://doi.org/10.1371/journal.pone.0194651.g010>

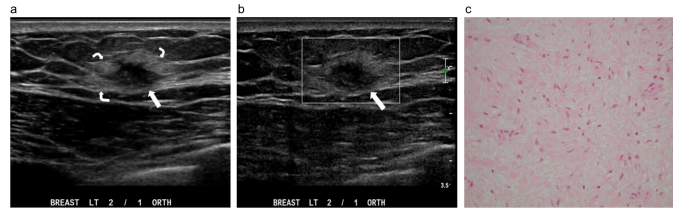


Fig 11. A palpable nodule in the left breast of a 55-year-old man. (a) Transverse ultrasound shows an irregular shape, a noncircumscribed margin, and a heterogeneously hypoechoic, solid nodule (straight arrow) with the center 1 cm away from the nipple. The nodule has an echogenic halo (curve arrows) and a markedly eccentric relationship to the nipple. (b) Color Doppler ultrasound shows absent color signal in the nodule (arrow), categorized as a low color flow signal. (c) Pathology specimen mainly shows fibroadipose stromal tissue with stromal fibrosis, myxoid degeneration, and focal fatty necrosis. No mammary gland tissue or malignant cells can be identified. (Hematoxylin-eosin, original magnification $\times 200$).

<https://doi.org/10.1371/journal.pone.0194651.g011>

Chen et al. recommended that a mass in the male breast with a cystic component on US should be considered suspicious for malignancy [6]. Chau et al. reported that invasive or *in situ* papillary cancers in the male breast often had complex mixed cystic and solid composition on US [15]. In our study, 2 (40%) of 5 male breast lesions with cystic and solid components were invasive ductal carcinomas. The only invasive papillary carcinoma in our series did not have mixed components. A small number of benign conditions (3/100, 3%), 1 case of chronic inflammation and 2 abscesses also had cystic and solid US features. Our findings thus suggest that mixed components on US are not a feature specific for male breast cancers, and are not present in gynecomastia.

The histopathological findings associated with an echogenic halo indicate the invasion of malignant cells into fat tissue, where they exist along with adipocytes and elastic fibers [19]. Abscesses can also display an echogenic halo, which may be related to an inflammatory reaction and edema seen on histopathological examination. An echogenic halo is considered to be of no diagnostic significance for breast malignancy in the 2013 BI-RADS Atlas (5th edition).

Table 4. Multivariate logistic regression analysis of ultrasonographic features of male breast malignancies.

Features	OR (95% CI)	P value
Relationship to nipple		
Concentric	1	
Mildly eccentric	2.961 (0.707–12.396)	0.137
Markedly eccentric	3.065 (0.789–11.910)	0.106
Shape		
Oval	1	
Round	8.340 (0.590–117.927)	0.117
Irregular	2.564 (0.661–9.938)	0.173
Lesion boundary		
Abrupt interface	1	
Echogenic halo	3.955 (1.005–15.564)	0.049
Color flow Distribution		
Absent	1	
Vessels predominantly in the rim	1.999 (0.389–10.281)	0.407
Predominantly internal vascularity	1.159 (0.161–8.334)	0.884
Color flow Grading		
Low color flow signal	1	
Rich color flow signal	8.330 (1.505–46.102)	0.015

<https://doi.org/10.1371/journal.pone.0194651.t004>

Table 5. The histopathological diagnosis of 125 breast masses in males.

Histopathological diagnosis	N (%)
Benign Mass	
Gynecomastia	53 (42.4%)
Pseudogynecomastia	2 (1.6%)
Chronic inflammation	7 (5.6%)
Cystic Lymphangioma	1 (0.8%)
Vasculitis	1 (0.8%)
Nodular fasciitis	1 (0.8%)
Abscess	2 (1.6%)
Epidermal cyst	6 (4.8%)
Epithelial hyperplasia	3 (2.4%)
Lipoma	4 (3.2%)
Angiolipoma	2 (1.6%)
Neurofibroma	2 (1.6%)
Reactive hyperplasia of a lymph node	1 (0.8%)
Myofibroblastoma	2 (1.6%)
Stromal fibrosis	4 (3.2%)
Fibroadipose tissue	5 (4.0%)
Normal breast tissue	4 (3.2%)
Malignant Mass	
Invasive ductal carcinoma	17 (13.6%)
Ductal carcinoma in situ (DCIS)	1 (0.8%)
Intraductal papilloma with DCIS	2 (1.6%)
Invasive papillary carcinoma	1 (0.8%)
Apocrine adenocarcinoma	1 (0.8%)
Metastatic adenocarcinoma	1 (0.8%)
Neuroendocrine carcinoma	1 (0.8%)
Metastatic carcinoma	1 (0.8%)
Total	125 (100%)

N (%), number (percentage)

<https://doi.org/10.1371/journal.pone.0194651.t005>

However, our findings suggest that an echogenic halo was not only a significant feature, but also an independent US predictor for male breast malignancy. In our study, 8 (47%) of 17 masses were benign lesions, including 2 cases of gynecomastia, and had an echogenic halo. Conversely, there was no obvious echogenic halo around 2 abscesses in the current series.

Some studies [28, 29] have found that vascular characteristics were the best diagnostic determinant in women to distinguish malignant from benign breast lesions. Benign breast lesions either had no vascularization, or had vessels around the margin of the lesions, while breast cancers had multiple vessels penetrating into, or blood pooling in the lesions [28–30]. However, our study showed that absent vascularization, predominantly in the rim or predominantly internal vascularity, could be present in benign male breast masses. The feature of predominantly internal vascularity was significantly more common in malignancies than in benign masses, but on multivariate analysis it was still not an independent predictor of cancer. On the other hand, a rich color flow signal was an independent predictor of malignancy (OR = 8.330, CI: 1.505–46.102, P < 0.001).

This retrospective study has some bias. Ultrasound is a dynamic study, and very much operative dependent. Information bias is introduced in our study when using the static US

images saved by technicians that performed the examination. Selection bias occurred when the question selecting patients with the preoperative ultrasonic examination and the pathological results thus missing many examinations. However, it is very difficult to accumulate enough cases of a rare condition like male breast cancer.

This study also has several limitations. First, it is a retrospective study with a relatively small number of patients. Only biopsy-proven diagnoses of masses in patients who had had preoperative US were included. Had cases without US had been included, the findings might have differed somewhat. Second, because of the retrospective nature data recorded in the charts may have been incomplete. For this reason, we did not evaluate other risk factors for male breast cancer including prior radiation therapy of the chest, smoking and alcohol history, liver disease, hyperestrogenism, androgen deficiency, undescended testes, orchitis, congenital inguinal herniation, Klinefelter's syndrome, or family history of breast cancer [6, 27, 31]. Third, evaluation of microcalcifications and axillary lymph nodes were not included in this study. Fourth, we did not compare US to mammography. Last, because of incomplete data a detailed correlation between the US findings and clinical presentation of benign and malignant lesions, including onset, duration, skin changes, and other associated symptoms and signs could not be investigated.

Conclusions

In conclusion, clinicians might use an integration of clinical and US findings to evaluate and manage a male breast lesion. Advanced age, bloody discharge from the nipple, a mass eccentric to a nipple, irregular shape, the presence of an echogenic halo, predominantly internal vascularity, and rich color flow signal on CDU were features more common in cancers than in benign lesions. The presence of an echogenic halo and rich color flow signal were independent US predictors of male breast cancers on multivariate analysis. The abovementioned specific clinical and US features of male breast cancers suggest that a biopsy or surgical excision be performed. Conversely, synchronous bilateral subareolar and/or palpable tender masses were almost always benign, and conservative follow-up may be appropriate. However, when conservative management is not effective, surgery should be considered.

Acknowledgments

We thank Chih-Ping Chiu (senior research assistant) for assistance in preparation of this manuscript. We also thank Hui-Ju Chiang, Chuen-Lan Liu and Yi-Ching Lo, Hsiao-Ling Shen, Shu-Ya Yeh, Wen-Hsin Chang (all senior technicians) for performing breast ultrasound examinations.

Author Contributions

Conceptualization: Wei-Hsin Yuan.

Data curation: Wei-Hsin Yuan, Anna Fen-Yau Li.

Formal analysis: Wei-Hsin Yuan, Anna Fen-Yau Li, Yi-Hong Chou, Hui-Chen Hsu, Ying-Yuan Chen.

Investigation: Anna Fen-Yau Li.

Methodology: Wei-Hsin Yuan.

Resources: Wei-Hsin Yuan.

Software: Ying-Yuan Chen.

Visualization: Anna Fen-Yau Li.

Writing – original draft: Wei-Hsin Yuan, Hui-Chen Hsu.

Writing – review & editing: Wei-Hsin Yuan, Yi-Hong Chou, Hui-Chen Hsu.

References

1. Ng AM, Dissanayake D, Metcalf C, Wylie E. Clinical and imaging features of male breast disease, with pathological correlation: a pictorial essay. *J Med Imag Radiat On.* 2014; 58(2): 189–198.
2. Chen PH, Slanetz PJ. Incremental clinical value of ultrasound in men with mammographically confirmed gynecomastia. *Eur J Radiol.* 2014; 83(1): 123–129. <https://doi.org/10.1016/j.ejrad.2013.09.021> PMID: 24161780
3. Athwal RK, Donovan R, Mirza M. Clinical examination allied to ultrasonography in the assessment of new onset gynecomastia: an observational study. *J Clin Diagn Res.* 2014; 8(6): 09–11.
4. Narula HS, Carlson HE. Gynaecomastia-pathophysiology, diagnosis and treatment. *Nat Rev Endocrinol.* 2014; 10: 684–698. <https://doi.org/10.1038/nrendo.2014.139> PMID: 25112235
5. Lattin Jr GE, Jesinger RA, Mattu R, Glassman LM. From the radiologic pathology archives: diseases of the male breast: radiologic-pathologic correlation. *Radiographics.* 2013; 33(2): 461–489. <https://doi.org/10.1148/rg.332125208> PMID: 23479708
6. Chen L, Chantra PK, Larsen LH, Barton P, Rohitopakarn M, Zhu EQ, et al. Imaging characteristics of malignant lesions of the male breast. *Radiographics.* 2006; 26(6): 993–1006.
7. Carrasco RM, Benito MÁ, Gomariz EM, Povedano JL, Paredes MM. Mammography and ultrasound in the evaluation of male breast disease. *Eur Radiol.* 2010; 20(12): 2797–2805. <https://doi.org/10.1007/s00330-010-1867-7> PMID: 20571799
8. Yitta S, Singer CI, Toth HB, Mercado CL. Sonographic appearances of benign and malignant male breast disease with mammographic and pathologic correlation. *J Ultrasound Med.* 2010; 29(6): 931–947. PMID: 20498468
9. Rew L, Young C, Harrison T, Caridi R. A systematic review of literature on psychosocial aspects of gynecomastia in adolescents and young men. *J Adolescence.* 2015; 43: 206–212.
10. Mendelson EB, Böhm-Vélez M, Berg WA, et al. ACR BI-RADS® Ultrasound. In: ACR BI-RADS® Atlas, Breast Imaging Reporting and Data System. Reston, VA, American College of Radiology; 2013. pp. 35–100.
11. Okello J, Kitembo H, Bugeza S, Galukande M. Breast cancer detection using sonography in women with mammographically dense breasts. *BMC Med Imaging.* 2014; 14(41): <https://doi.org/10.1186/s12880-014-0041-0> PMID: 25547239
12. Park AY, Seo BK, Cho KR, Woo OH. The utility of micropure ultrasound technique in assessing grouped microcalcifications without a mass on mammography. *J Breast Cancer.* 2016; 19(1): 83–86. <https://doi.org/10.4048/jbc.2016.19.1.83> PMID: 27066098
13. Sun WY, Lee KH, Lee HC, Ryu DH, Park JW, Yun HY, et al. Synchronous bilateral male breast cancer: a case report. *J Breast Cancer.* 2012; 15(2): 248–251. <https://doi.org/10.4048/jbc.2012.15.2.248> PMID: 22807945
14. Nguyen C, Kettler MD, Swirsky ME, Miller VI, Scott C, Krause R, et al. Male breast disease: pictorial review with radiologic-pathologic correlation. *Radiographics.* 2013; 33(3): 763–779. <https://doi.org/10.1148/rg.333125137> PMID: 23674773
15. Chau A, Jafarian N, Rosa M. Male breast: clinical and imaging evaluations of benign and malignant entities with histologic correlation. *Am J Med.* 2016; 129(8): 776–791. <https://doi.org/10.1016/j.amjmed.2016.01.009> PMID: 26844632
16. Yang WT, Whitman GJ, Yuen EHY, Tse GMK, Stelling CB. Sonographic features of primary breast cancer in men. *Am J Roentgenol.* 2001; 176(2): 413–416.
17. Cho SH, Park SH. Mimickers of breast malignancy on breast sonography. *J Ultrasound Med.* 2013; 32(11): 2029–2036. <https://doi.org/10.7863/ultra.32.11.2029> PMID: 24154908
18. Ma Y, Li G, Li J, Ren WD. The diagnostic value of superb microvascular imaging (SMI) in detecting blood flow signals of breast lesions: a preliminary study comparing SMI to color doppler flow imaging. *Medicine.* 2015; 94(36):e1502. <https://doi.org/10.1097/MD.0000000000001502> PMID: 26356718
19. Zhang L, Li J, Xiao Y, Cui H, Du G, Wang Y, et al. Identifying ultrasound and clinical features of breast cancer molecular subtypes by ensemble decision. *Sci Rep.* 2015; 5(11085): <https://doi.org/10.1038/srep11085> PMID: 26046791

20. Hong AS, Rosen EL, Soo MS, Baker JA. BI-RADS for sonography: positive and negative predictive values of sonographic features. *Am J Roentgenol.* 2005; 184(4): 1260–1265.
21. Ginat DT, Destounis SV, Barr RG, Castaneda B, Strang JG, Rubens DJ. US elastography of breast and prostate lesions 1. *Radiographics.* 2009; 29(7): 2007–2016. <https://doi.org/10.1148/rg.297095058> PMID: 19926759
22. Kaneda HJ, Mack J, Kasales CJ, Schetter S. Pediatric and adolescent breast masses: a review of pathophysiology, imaging, diagnosis, and treatment. *Am J Roentgenol.* 2013; 2009(2): 204–212.
23. Yen PP, Sinha N, Barnes PJ, Butt R, Iles S. Benign and malignant male breast diseases: radiologic and pathologic correlation. *Can Assoc Radiol J.* 2015; 66(3): 198–207. <https://doi.org/10.1016/j.carj.2015.01.002> PMID: 26073217
24. Maturen KE, Wasnik AP, Bailey JE, Higgins EG, Rubin JM. Posterior acoustic enhancement in hepatocellular carcinoma. *J Ultrasound Med.* 2011; 30(4): 495–499. PMID: 21460149
25. Lai YC, Hsu CY, Chou YH, Tiu CM, Tseng LM, Wang HK, et al. Sonographic presentations of metaplastic breast cancers. *J Chin Med Assoc.* 2012; 75(11): 589–594. <https://doi.org/10.1016/j.jcma.2012.08.005> PMID: 23158037
26. Kim TH, Kang DK, Kim SY, Lee EJ, Jung YS, Yim H. Sonographic differentiation of benign and malignant papillary lesions of the breast. *J Ultrasound Med.* 2008; 27(1): 75–82. PMID: 18096733
27. Mathew J, Perkins GH, Stephens T, Middleton LP, Yang WT. Primary breast cancer in men: clinical, imaging, and pathologic findings in 57 patients. *Am J Roentgenol.* 2008; 191(6): 1631–1639.
28. Stuhmann M, Aronius R, Schietzel M. Tumor vascularity of breast lesions: potentials and limits of contrast-enhanced Doppler sonography. *Am J Roentgenol.* 2000; 175(6): 1585–1589.
29. Kettenbach J, Helbich TH, Huber S, Zuna I, Dock W. Computer-assisted quantitative assessment of power Doppler US: effects of microbubble contrast agent in the differentiation of breast tumors. *Eur J Radiol.* 2005; 53(2): 238–244. <https://doi.org/10.1016/j.ejrad.2004.04.017> PMID: 15664287
30. Kwee RM, van den Bosch MA, El Ouamari M, Kemps B, Arensman L, van Hillegersberg R, et al. Contrast-enhanced breast ultrasonography reveals an unusual breast tumor in a male patient with gynecomastia. *J Ultrasound Med.* 2006; 25(10): 1347–1351. PMID: 16998111
31. Carmalt HL, Mann LJ, Kennedy CW, Fletcher JM, Gillett DJ. Carcinoma of the male breast: a review and recommendations for management. *Aust N Z J Surg.* 1998; 68(10): 712–715. PMID: 9768607