



Since January 2020 Elsevier has created a COVID-19 resource centre with free information in English and Mandarin on the novel coronavirus COVID-19. The COVID-19 resource centre is hosted on Elsevier Connect, the company's public news and information website.

Elsevier hereby grants permission to make all its COVID-19-related research that is available on the COVID-19 resource centre - including this research content - immediately available in PubMed Central and other publicly funded repositories, such as the WHO COVID database with rights for unrestricted research re-use and analyses in any form or by any means with acknowledgement of the original source. These permissions are granted for free by Elsevier for as long as the COVID-19 resource centre remains active.



## Pityriasis Rosea Shortly After mRNA-1273 COVID-19 Vaccination

Sun Hye Shin<sup>1</sup>, Jun Ki Hong<sup>1</sup>, Soon Auck Hong<sup>2</sup>, Kapsok Li<sup>1</sup>, Kwang Ho Yoo<sup>1,\*</sup>

<sup>1</sup> Department of Dermatology, Chung-Ang University College of Medicine, Seoul, Korea

<sup>2</sup> Department of Pathology, Chung-Ang University College of Medicine, Seoul, Korea



### ARTICLE INFO

#### Article history:

Received 16 October 2021

Revised 27 October 2021

Accepted 28 October 2021

#### Keywords:

COVID-19

mRNA-1273

Pityriasis rosea

Vaccination

With the increase in rates of vaccination against COVID-19, various cutaneous reactions have been reported after vaccination, including pityriasis rosea (PR) (Catala *et al.*, 2021; Johansen *et al.*, 2021; Marcantonio-Santa Cruz *et al.*, 2021; McMahon *et al.*, 2021). It is easy to overlook because the incidence of PR as a side effect of COVID-19 vaccination is extremely low, accounting for about 0.96% of all cutaneous reactions (McMahon *et al.*, 2021).

A 29-year-old man presented with a herald patch on his right chest 2 hours after the second dose of mRNA-1273 COVID-19 vaccination (Figure 1A). Within 2–3 days, multiple skin lesions rapidly disseminated to the upper trunk and extremities (Figure 1B). He had no other systemic symptoms and no previous history of COVID-19 infection. Skin biopsy showed focal parakeratosis, spongiosis, and superficial perivascular inflammatory infiltrates (Figure 1C). Based on the clinical and histological features he was diagnosed with PR.

According to Ogata *et al.* (Ogata *et al.*, 2021), the SARS-CoV-2 viral spike protein antigen is detected as early as day 1 post-vaccination, and peak levels are detected after an average of 5 days. Based on the literature, the time lapse between COVID-19 vaccination and skin lesions ranges 5–17 days, with an average of 12.7 days. However, our patient developed PR after only 2 hours of receiving the vaccination, which is a very short time interval. This case did not enable a conclusion to be made that a true causal link exists between PR and vaccination. This is because the short interval of 2 hours may be insufficient for the vaccine to circulate

throughout the bloodstream and induce an appropriate immune response.

However, in this patient, the skin lesions occurred after the second dose of the vaccination, and it is possible that PR may occur sooner in such cases than after the first dose of the vaccination. Johnston *et al.* (Johnston *et al.*, 2021) recently reported that delayed localized cutaneous reactions may occur sooner after the second administration of the vaccine. Moreover, a previous history of PR is not generally related to recurrence or onset of the lesion, and is not an important consideration for this patient because there was no history of PR. Therefore, in the future, researchers should study the onset duration of cutaneous reactions that occur following the administration of the first and second doses of the COVID-19 vaccine.

None.

### Ethical approval

This study was performed in accordance with the Helsinki Declaration and the patient provided written informed consent for the publication of his case details.

### Acknowledgment

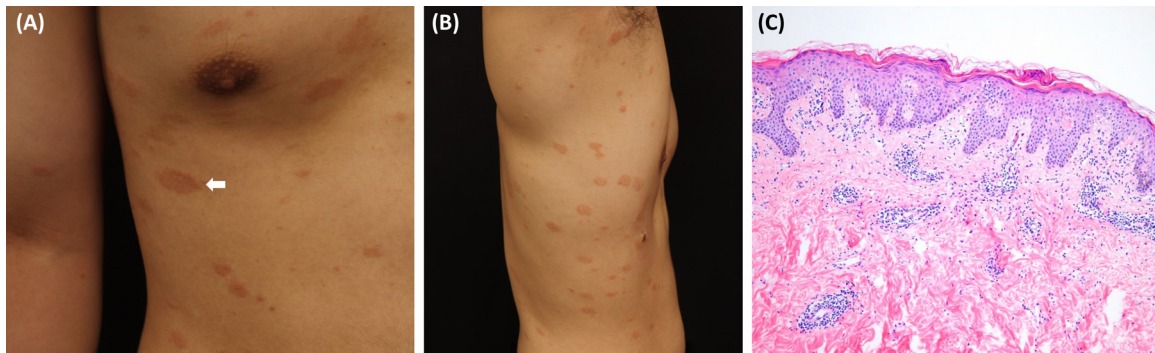
None.

### Conflicts of interest

The authors have no conflicts of interest to declare.

\* Corresponding author: Department of Dermatology, Chung-Ang University Hospital 224-1 Heukseok-dong, Dongjak-gu, Seoul 156-755, Korea. Tel: +82.2-6299-1544; fax: +82.2-6299-1718.

E-mail address: [psyfan9077@naver.com](mailto:psyfan9077@naver.com) (K.H. Yoo).



**Figure 1.** (A) A 3 × 4 cm sized, solitary large, erythematous patch with trailing scale (herald patch, white arrow) on his right chest. (B) Multiple oval, salmon-colored patches along the lines of cleavage on the trunk. (C) Histopathologic examination shows patchy parakeratosis, mild spongiosis, and perivascular lymphocytic infiltration. (Hematoxylin and Eosin, original magnification × 100).

## References

- Catala A, Munoz-Santos C, Galvan-Casas C, Roncero Riesco M, Revilla Nebreda D, Sola-Truyols A, et al. Cutaneous reactions after SARS-COV-2 vaccination: A cross-sectional Spanish nationwide study of 405 cases. *Br J Dermatol* 2021.
- Johansen M, Chisolm SS, Aspey LD, Brahmbhatt M. Pityriasis rosea in otherwise asymptomatic confirmed COVID-19-positive patients: A report of 2 cases. *JAAD Case Rep* 2021;7:93–4.
- Johnston MS, Galan A, Watsky KL, Little AJ. Delayed Localized Hypersensitivity Reactions to the Moderna COVID-19 Vaccine: A Case Series. *JAMA Dermatol* 2021;157(6):716–20.
- Marcantonio-Santa Cruz OY, Vidal-Navarro A, Pesque D, Gimenez-Arnau AM, Pujol RM, Martin-Ezquerria G. Pityriasis rosea developing after COVID-19 vaccination. *J Eur Acad Dermatol Venereol* 2021.
- McMahon DE, Amerson E, Rosenbach M, Lipoff JB, Moustafa D, Tyagi A, et al. Cutaneous reactions reported after Moderna and Pfizer COVID-19 vaccination: A registry-based study of 414 cases. *J Am Acad Dermatol* 2021;85(1):46–55.
- Ogata AF, Cheng CA, Desjardins M, Senussi Y, Sherman AC, Powell M, et al. Circulating SARS-CoV-2 Vaccine Antigen Detected in the Plasma of mRNA-1273 Vaccine Recipients. *Clin Infect Dis* 2021.