

Evolution of Minimally Invasive Approaches to the Sella and Parasellar Region

Robert G. Louis¹ Amy Eisenberg¹ Garni Barkhoudarian¹ Chester Griffiths¹ Daniel F. Kelly¹

¹Brain Tumor Center & Pituitary Disorders Program, John Wayne Cancer Institute, Providence Saint John's Health Center, Santa Monica, California, United States

Address for correspondence Daniel F. Kelly, MD, Brain Tumor Center, John Wayne Cancer Institute, 2200 Santa Monica Blvd., Santa Monica, CA 90404, United States (e-mail: kellyd@jwci.org).

Int Arch Otorhinolaryngol 2014;18:S136–S148.

Abstract

Introduction Given advancements in endoscopic image quality, instrumentation, surgical navigation, skull base closure techniques, and anatomical understanding, the endonasal endoscopic approach has rapidly evolved into a widely utilized technique for removal of sellar and parasellar tumors. Although pituitary adenomas and Rathke cleft cysts constitute the majority of lesions removed via this route, craniopharyngiomas, clival chordomas, parasellar meningiomas, and other lesions are increasingly removed using this approach. Paralleling the evolution of the endonasal route to the parasellar region, the supraorbital eyebrow craniotomy has also been increasingly used as an alternative minimally invasive approach to reach this skull base region. Similar to the endonasal route, the supraorbital route has been greatly facilitated by advances in endoscopy, along with development of more refined, low-profile instrumentation and surgical navigation technology.

Objectives This review, encompassing both transcranial and transsphenoidal routes, will recount the high points and advances that have made minimally invasive approaches to the sellar region possible, the evolution of these approaches, and their relative indications and technical nuances.

Data Synthesis The literature is reviewed regarding the evolution of surgical approaches to the sellar region beginning with the earliest attempts and emphasizing technological advances, which have allowed the evolution of the modern technique. The surgical techniques for both endoscopic transsphenoidal and supraorbital approaches are described in detail. The relative indications for each approach are highlighted using case illustrations.

Conclusions Although tremendous advances have been made in transitioning toward minimally invasive transcranial and transsphenoidal approaches to the sella, further work remains to be done. Together, the endonasal endoscopic and the supraorbital endoscope-assisted approaches are complementary minimally invasive routes to the parasellar region.

Keywords

- ▶ endoscopy
- ▶ pituitary neoplasms
- ▶ craniopharyngioma
- ▶ chordoma
- ▶ meningioma
- ▶ skull base

Introduction

Successful resection of sellar and parasellar tumors amidst the confines of the carotid arteries, optic nerves, hypothalamus, normal pituitary gland, and cavernous sinuses can

present a significant technical challenge. Moreover, the sellar region is relatively centrally located within the head, meaning any approach requires not only precise surgical technique but also the use of relatively long instruments through a deep and

received
May 17, 2014
accepted
July 3, 2014

DOI <http://dx.doi.org/10.1055/s-0034-1395265>.
ISSN 1809-9777.

Copyright © 2014 by Thieme Publicações
Ltda, Rio de Janeiro, Brazil

License terms



narrow corridor. Since the first attempts at resection of a sellar tumor in the early 1900s, stepwise advances in technique and technology have paved the way for safer and more effective access to the sellar region. This review, encompassing both transcranial and transsphenoidal routes, will recount the high points and advances that have made minimally invasive approaches to the sellar region possible in the modern era.

Review of the Literature

Earliest Attempts

Transcranial Approaches

Although he did not report on it until 1906, Sir Victor Horsley performed the first transcranial pituitary operation in 1889 but met with limited success using the approach because of what was later determined to be forceful retraction of the frontal lobe.^{1,2} In 1905, Fedor Krause of Berlin used a frontal transcranial approach to reach the sella turcica in a living patient.³ It was this initial work that provided the basis on which the majority of subsequent variations on transcranial approaches were developed. One variation by McArthur involved an extradural approach with resection of the supra-orbital ridge and the orbital plate, allowing dissection to extend posteriorly toward the optic chiasm.⁴ Further modifications were made by several neurosurgical pioneers in the early part of the 20th century, including Dandy, Heuer, Frazier, and Cushing.³ Harvey Cushing advocated a trans-frontal craniotomy with a direct right subfrontal midline approach.⁵ As a result of Cushing's commitment to perfecting intracranial approaches and his powerful influence on American neurosurgery, the mainstream neurosurgical teaching during the 1930s and 1940s continued to focus on a transcranial approach to the pituitary gland.³

Transsphenoidal Approach

Based upon the work of Giordano, Hermann Schloffer of Austria reported the first successful resection of a pituitary tumor via a transsphenoidal approach in 1907. With local anesthesia provided by cocaine, Schloffer performed a three-stage procedure that appeared to represent a modification of contemporaneous approaches to treat sphenoid sinusitis.⁶ Although the first transsphenoidal operations by Schloffer, von Eiselsberg, and Kocher required external rhinotomy incisions, techniques quickly developed that decreased the invasiveness of this approach.⁷ In 1910, Hirsch introduced the endonasal approach by reporting two cases.⁸ Nearly simultaneously, Halstead pioneered the sublabial approach whereby he was able to preserve the cartilaginous septum, thus obtaining more pleasing postoperative aesthetic outcomes.⁹ Although these approaches both required some degree of turbinectomy or ethmoidectomy, they represent the earliest versions of the two most common transsphenoidal approaches to the sella used today.

By 1914, Cushing described the successful use of the sublabial transseptal approach and used the transsphenoidal approach between 1910 and 1925 to operate on 231 pituitary

tumors, with a mortality rate of only 5.6%.¹⁰ Despite being recognized as less invasive and providing better visualization, Cushing abruptly abandoned its use from 1929 to 1932 in favor of the transcranial route.⁷ Cushing returned to the transcranial approach for sellar tumors largely due to poor visualization and likely because he considered the extent of resection and intraoperative complications to be more easily evaluated and treated from above.

By 1956, one of Cushing's pupils, Norman Dott of Edinburgh, who recognized the importance of the transsphenoidal operation, had performed 80 consecutive transsphenoidal operations with no deaths.¹¹ He is also credited with developing a lighted speculum retractor that improved illumination of the surgical site. Dott then introduced his method to Gerard Guiot, who began to perform the transsphenoidal approach in 1957 and subsequently accrued a series of more than 1,000 cases of pituitary adenomas. These few pioneers, by preserving and improving the transsphenoidal approach, paved the way for the modern era of neurosurgery. Although leaving no visible cosmetic defects, these early transsphenoidal operations could hardly be considered minimally invasive. Still, over the ensuing decades, advances in technique and technology allowed future neurosurgeons to build upon the principles set forth by Cushing, Halstead, Hirsch, Dott, and Guiot.

Technological Advances: Paving the Way for Modern Approaches to the Sella

Beginning in the 1950s, a series of technical and technological innovations would set the stage for the transition toward 21st-century approaches to the sella. With the increased use of antibiotics and the introduction of hydrocortisone replacement, the mortality and morbidity associated with pituitary surgery continued to decrease. Subsequently, two innovations contributed to a renewed interest in the transsphenoidal approach.

Intraoperative Fluoroscopy

Soon after performing his first transnasal resection, Guiot introduced intraoperative fluoroscopy, allowing the surgeon to visualize the depth and positioning of surgical instruments in real time. This real-time visualization revolutionized the technical aspects of pituitary surgery and can be considered the first step toward intraoperative neuronavigation. Fluoroscopy allowed for safer, more extensive resection of sellar, parasellar, and suprasellar lesions and was soon associated with improved surgical outcomes.

Jules Hardy—The Operative Microscope and Selective Adenomectomy

Although the basic techniques of transsphenoidal surgery had been established, adequate illumination of the operative field had always been a limitation.² Cushing had used a headlamp, Hirsch used the otolaryngologic mirror, and Dott tried to improve illumination by attaching small lightbulbs near the tip of the retractor blade.¹² Although otolaryngologists had used the operating microscope since the 1920s, its applications to transsphenoidal surgery were pioneered by Jules Hardy in 1965, who first used it for a total hypophysectomy

for metastatic breast cancer. The microscope improved illumination, added magnification, and provided stereoscopic visualization, allowing Hardy to develop the technique of selective adenectomy with pituitary gland preservation.³ These benefits quickly became widely recognized, and the microscope was soon adopted as an essential component of the transsphenoidal approach.

Endoscope

Many argue that the major limitation of the microscope in the transsphenoidal approach is the restricted visualization limited to a corridor confined within the nasal speculum. In contrast, the modern rod-lens endoscope provides a more panoramic view unobtainable with the microscope. This limited “tunnel vision” microscopic view coupled with technical advances and a growing experience in sinonasal endoscopy fueled the revolution in endoscopic transsphenoidal surgery that began in the 1990s.¹³

Neuronavigation, Doppler Probe, and Electrophysiologic Monitoring

Prior to the development of modern neuroimaging techniques, tumor localization was typically based on surface or internal landmarks. Currently, with the ability to apply frameless image guided navigation, surgical planning and intraoperative maneuvering can be more precise and thus reduce the risk of collateral damage to the normal brain, cranial nerves, and cerebral vasculature. The application of image-guided navigation in both transcranial and transsphenoidal surgery has allowed us to maximize surgical resection while minimizing risk. The enhanced ability afforded by neuronavigation to localize tumors has allowed surgeons to minimize the use of large craniotomy flaps in favor of more precise “keyhole” approaches.¹⁴ These minimally invasive approaches allow the surgeon to identify both the tumor and key anatomical structures while minimizing the risk of injury and the risks and discomforts of larger exposures and approaches. As a result, neuronavigation based on computed tomography (CT) or magnetic resonance imaging (MRI) has become a standard adjunct for sellar tumor resection.

Evolution of the Transsphenoidal Technique—Progress toward Minimally Invasive Neurosurgery

Fueled by advances in both technology and progressively more detailed understanding of microsurgical anatomy, the end of the 20th century saw a relatively rapid evolution in surgical techniques for access to the sellar region. Thanks to the increasing availability of information through online publication of medical literature, this evolution was led by a few pioneers but has spread rapidly to become widely accepted. In the late 1980s and 1990s, there was a transition for many neurosurgeons, including our group, away from the traditional sublabial transsphenoidal approach toward the direct endonasal transsphenoidal approach initially described by Griffith and Veerapen.^{15,16} Although these techniques were performed primarily under microscopic visualization, they represent advances along the stepwise progression leading to our current technique.

As neurosurgeons gained more experience with the rod-lens endoscope, increasing collaboration with otolaryngologists resulted in the elimination of the nasal speculum and microscope in transsphenoidal procedures. In 1997, Jho and Carrau published the first large series (50 patients) with predominantly pituitary adenomas treated via a fully endoscopic transsphenoidal approach.¹⁷ Subsequently, during the late 20th and early 21st centuries, many neurosurgeons began to transition initially from a traditional microscopic to an endoscope-assisted and eventually to a fully endoscopic approach. Cappabianca et al further refined the procedure by developing unique endoscopic instrumentation and identifying areas for technical improvement.¹⁸ In addition, by providing a panoramic view, the endoscope has been increasingly utilized for lesions beyond the sella. Contributions made by Kassam, Carrau, Snyderman, Gardner, Prevedello, and others facilitated a further reach of extended approaches to the midline skull base, which were originally described using the microscope by Weiss, Oldfield, and Laws.¹³ These endoscopic approaches include the transcribiform and transplanum approaches to the anterior cranial fossa, ethmoid-pterygoid-sphenoid or direct transsphenoidal approach to the cavernous sinus, and the transclival approach for infrasellar skull base and prepontine lesions.

Discussion

Advantages and Limitations of Pure Endoscopic Transsphenoidal Approach

The advantages of the endoscopic approach can best be appreciated in comparison with the microscopic approach. Although both the endoscopic and microscopic techniques have been used successfully on a variety of sellar and parasellar tumors, our evolving experience suggests that the endoscope may have several distinct advantages in certain situations. Perhaps most importantly, by providing a panoramic wide-angle view, the endoscope provides superior visualization compared with the microscopic approach. This attribute is of particular importance for tumors with extension beyond the sella, including suprasellar, cavernous sinus, and anterior cranial fossa, as can often be seen with nonfunctioning pituitary adenomas, craniopharyngiomas, and parasellar meningiomas. The limited field of view provided by the microscope rarely allows for visualization of the optic and carotid protuberances or the opticocarotid recesses. Although not as important during resection of small, midline tumors, visualization of these key landmarks can be critical to avoid catastrophic injury, particularly during resection of larger and more expansive tumors. An additional advantage of the endoscope is the ability to manipulate the line of sight. Once set in place, the operative microscope provides a clear, three-dimensional view of the sellar region. The endoscope is mobile and provides the ability to “see around corners,” particularly with using 30- and 45-degree angled lenses. This can be a particular advantage for close inspection of the tumor/gland interfaces and for removing tumors from the optic chiasm region and cavernous sinuses.

The advantages of the endoscope are not without cost. The endoscopic approach introduces an entirely new system for neurosurgeons, who are usually more accustomed to the operating microscope. The importance of surgeon familiarity with instruments and camera systems cannot be overstated, and there is a significant learning curve when attempting endonasal endoscopy. This fact is underscored by the reality that operator experience is associated with better outcomes and lower complication rates.¹⁹ Besides the new technology, the presence of the endoscope within the operative field introduces a unique challenge, representing a physical obstacle that must be accommodated with wide exposure and instrument adjustment. The endoscope itself limits maneuverability of other surgical instruments, which is exacerbated by its limited zoom capacity. Because the scope must often be advanced deep into the operative field to achieve the optimal view, collision and conflict (“sword-fighting”) with other instruments is a frequent challenge that must be minimized. Because of the presence of multiple simultaneous instruments, the nasal mucosa is at greater risk of being injured and care must be taken to sufficiently lateralize the middle turbinates to minimize damage. Finally, and perhaps most importantly, to perform two-handed microneurosurgery, the endoscope must be held or driven by another surgeon who can provide an optimal view of the surgical field while minimizing conflict with the other surgical instruments. This cosurgeon is increasingly an otolaryngologist who is skilled in sinonasal endoscopy, as originally described by Jho and Carrau in 1997.¹⁷ Static instrument holders have been used as an alternative to the two-physician strategy, though this comes with added equipment cost, cumbersome setup, and the need for manual adjustment of view by the primary surgeon.

Another limitation of the endoscope is that it provides only a two-dimensional image as compared with the three-dimensional microscopic visualization. Although this is potentially a problem particularly for less experienced surgeons, the dynamic movement of the endoscope within the sinonasal skull base space allows the surgeon to progressively gain a three-dimensional anatomical understanding. Whether newer three-dimensional endoscopes that are being progressively being improved will ultimately be proven superior over current two-dimensional endoscopes in terms of tumor removal rates and complications remains to be proven.²⁰

Transsphenoidal Surgery in the 21st Century—Surgical Technique

Currently at our institution and many others around the world, endonasal endoscopic surgery for sellar lesions utilizes a binostrial technique with a neurosurgeon and otolaryngologist working together throughout the majority of the procedure. The operation is begun with a 4-mm 0-degree rod-lens endoscope with 30- and 45-degree endoscopes available for use later in the procedure.

Patient Positioning

The patient’s head is placed either in a horseshoe head-holder for standard transsphenoidal cases or in a three-point Mayfield fixation for more extended endonasal procedures that

are anticipated to last over 6 hours. The head is tilted toward the left shoulder and turned 20 to 30 degrees toward the right, the endotracheal tube is positioned at the left side of the mouth, and the anesthesiologist and anesthesia equipment are positioned on the patient’s left side. This setup allows for both surgeons to have a comfortable operative position on the patient’s right. For sellar lesions, we position the head in a neutral plane (0 degrees) relative to the floor; when removing lesions primarily in the suprasellar region, 10 to 15 degrees of neck extension is applied; for infrasellar and clival lesions, 10 to 15 degrees of neck flexion is used. Following positioning of the head, the surgical navigation mask (Stryker Navigation, Stryker Corp, Kalamazoo, MI) is placed on the patient’s face, and the system is registered to the preoperative MRI and/or CT angiogram. Finally two high-definition video monitors displaying the endoscopic picture are positioned at almost 90-degree angles to one another, allowing for each to be directed at one of the two operating surgeons. A third monitor for neuronavigation is placed between the two high-definition monitors (► Fig. 1).

Nasal Preparation and Approach to Sphenoid Sinus

The nasal cavity is prepared prior to beginning the approach by spraying oxymetazoline in both nares. The face, perinasal area, and right lower abdominal area (for potential fat graft) are then sterilely prepped and draped. The initial approach into the sphenoid sinus is performed normally by the otolaryngologist alone with the 0-degree 4-mm endoscope. Xylocaine 1% with 1:100,000 epinephrine is first injected into the middle turbinates and posterior nasal septum bilaterally. Both inferior turbinates are first in-fractured then out-fractured. Similarly, the middle turbinates are out-fractured, exposing the sphenoid ostia. Next, bilateral nasoseptal “rescue flaps” are elevated.²¹ A curved microtip unipolar electrocautery is used to incise the mucoperiosteum beginning immediately inferior to the sphenoid ostium and extending to a point ~2 cm anteriorly, along the inferior vomer and posterior nasal septum. The two “rescue flaps” are then pushed downward toward the nasopharynx to minimize obstruction into the sphenoid sinus and are kept in place during the procedure with oxymetazoline-soaked cottonoids, preserving the posterior nasoseptal artery on both sides. The septal olfactory strip is preserved bilaterally and elevated away from the perpendicular plate of the ethmoid bone (► Fig. 2). This technique allows for preservation of the olfactory fibers and opens additional space in which the endoscope can be positioned during the remainder of the procedure. Next, a posterior septectomy is performed with a back-biter to connect the right and left nasal cavities. A wide sphenoidotomy is then performed that extends lateral to the sphenoid ostia and generally to the floor of the sphenoid inferiorly and to the roof of the sphenoid/ethmoid junction, superiorly. An attempt is made to remove the vomer in one piece to preserve the bone for sellar floor reconstruction if necessary. Posterior ethmoid air cells are also opened and removed as necessary to facilitate better superior exposure. This is often done using the 30-degree angled-lens endoscope.

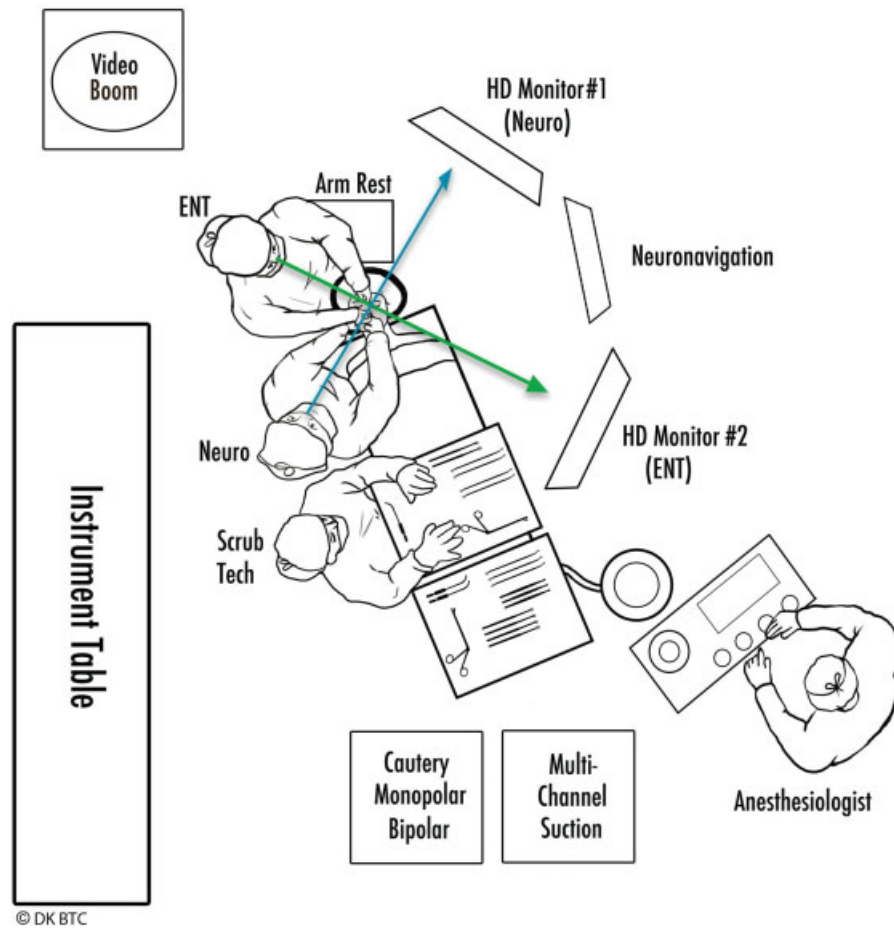


Fig. 1 Artist representation of the room setup for endoscopic endonasal transsphenoidal surgery. Two high-definition (HD) monitors are positioned at oblique angles to allow for comfortable working position for both the otolaryngologist (ENT) and the neurosurgeon (neuro).

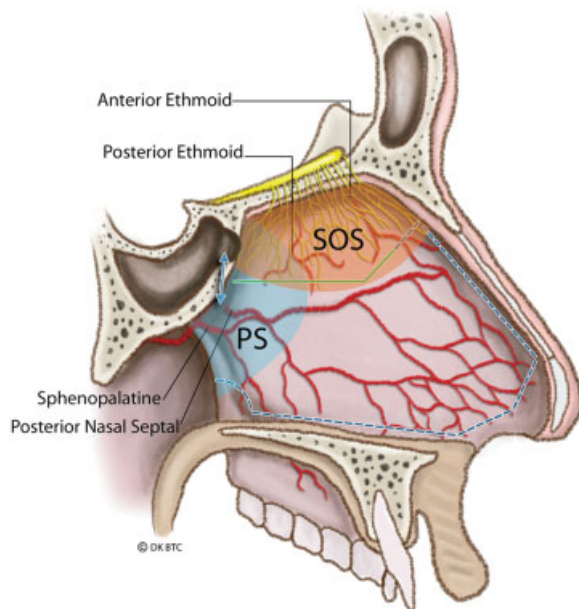


Fig. 2 Artist representation of the nasal septal anatomy, vasculature, and location of olfactory fibers. Proper placement of the rescue flap incision allows elevation and preservations of the septal olfactory strip. Abbreviations: PS, posterior septum; SOS, septal olfactory strip.

Sellar Exposure

Once the sphenoid sinus has been entered, any bony septations limiting access to the sella are carefully removed using a rongeur or high-speed drill with a 4-mm course diamond bit. Special attention is paid to lateral septations as they often lead directly to the petrous and cavernous carotid arteries. Aggressive removal or torquing of these septations can result in carotid artery laceration. The mucosa over the sella is then removed but the remaining sphenoid sinus mucosa is left intact to preserve as much normal sinus architecture and functional tissue as possible. The sellar face is then opened to expose the sellar dura. Depending on the size of the tumor and the degree of surrounding invasion, bone is typically removed laterally from cavernous sinus to cavernous sinus, superiorly to the tuberculum sella, and inferiorly to the sellar floor. When possible, the floor is preserved to facilitate fat graft placement. The opening is typically started with the drill and then completed with a 2-mm Kerrison rongeur. For large macroadenomas, there is often extensive bony erosion or thinning and dural invasion, which may extend out to and over the cavernous carotid arteries. If this is found to be the case, it should be assumed that the bone over the carotid arteries may also be eroded by tumor and extreme caution should be exercised before definitive localization of both arteries has occurred.

Dural Opening

Prior to sellar dural opening, the location of the cavernous carotid arteries is precisely determined with a micro-Doppler probe (10-MHz ES-100X MiniDop with NRP-10H bayonet probe; Koven, St. Louis, Missouri, United States) and surgical navigation (→ Fig. 3).²² The locations of the adenoma and pituitary gland should be anticipated based on the preoperative MRI. Ideally, the dura is opened without entering into the gland or transgressing the adenoma pseudocapsule. In most instances of macroadenomas, the pituitary gland will be compressed laterally and/or superiorly, but occasionally, a portion of the gland may be draped anteriorly over the tumor. A wide dural opening is performed in u-shaped fashion with a standard straight microblade (Mizuho America Inc., Union City, CA). Next, angled microdissectors are used to carefully separate and elevate the dura from the underlying tumor and pituitary gland. The dural opening can then be extended more laterally as needed with a right-angle microhook blade or curved microscissors. Laterally, the opening will normally extend to within 1 to 2 mm of the medial wall of the cavernous sinus. If cavernous sinus bleeding is encountered, this low-pressure venous bleeding is generally easily controlled with Surgifoam (Ethicon Inc., Johnson & Johnson Co., Piscataway, New Jersey, United States) or Gelfoam (Pfizer Inc., New York, New York, United States) and gentle direct pressure. In patients with microadenomas and a low-lying diaphragm, care must be taken to not extend the dural opening too far superiorly as this may often result in an early and anterior cerebrospinal fluid (CSF) leak.

Tumor Removal

Complete tumor resection with preservation or improvement in pituitary gland function is the goal for all patients undergoing endonasal resection of a pituitary adenoma. Oldfield and Vortmeyer were the first to describe the technique of adenoma removal utilizing the tumor pseudocapsule in

Cushing disease as a means of achieving complete tumor resection.²³ This technique is particularly useful for microadenomas but can also be applied in macroadenomas. For microadenomas, in which the tumor is behind a small rim of anterior gland, an incision can be made in the gland at its thinnest point to reach the pseudocapsule, which is a thin rim of compressed normal gland. A plane is then established between the adenoma and normal gland using micro-dissectors, irrigation, and gentle traction. The tumor is carefully separated from the compressed normal gland and gently removed with the surrounding pseudocapsule intact.

For larger macroadenomas with suprasellar extension, it is often best to first inferiorly and centrally debulk the tumor with ring curettes and suction. This initial decompression allows the more superior portion of the tumor with its pseudocapsule intact to be separated from compressed normal gland and the diaphragma sellae and is often removed in one remaining large rind. With this technique, one avoids pulling the tumor down from the diaphragm sellae without direct visualization, thus decreasing the likelihood of CSF leak.

Once all the visualized tumor has been removed with the 0-degree endoscope, the 30- or 45-degree angled lenses are utilized to obtain a clear view of regions not in direct line of sight.²⁴ This angled view is especially helpful for tumors with extensive suprasellar or cavernous sinus extension. The 45- and 90-degree up-angled ringed curettes may be used along with angled suctions to probe the folds of the diaphragma to dislodge residual tumor. In addition, a Valsalva maneuver or bilateral jugular vein compression can be administered to encourage downward descent of any suprasellar tumor that remains attached to the diaphragma. Ultimately, full inversion of the diaphragma into the enlarged sella should be seen if complete tumor removal has been accomplished. In cases of large macroadenomas, the redundant and collapsed diaphragma sellae often falls fully into the sella and obscures visualization of the sellar recesses. In such cases, it is extremely helpful to elevate this tissue with a spatula dissector and/or a cottonoid to facilitate an unobstructed view of these hidden regions to avoid missing residual adenoma. In all tumors with suspected cavernous sinus invasion, inspection of the medial cavernous sinus wall is performed with a 30- or 45-degree angled-lens endoscope. If present, tumor within the medial cavernous sinus may be safely removed using angled ring curettes and gentle suction. Venous bleeding from the cavernous sinus is once again controlled with Surgifoam or Gelfoam. In contrast to tumor within the medial cavernous sinus compartment, tumor that has extended along or lateral to the internal carotid artery (ICA) is difficult to access safely, and removal is associated with a higher risk of neurovascular injury. Monitoring and direct stimulation of cranial nerves III and VI is helpful for this lateral, posterior cavernous sinus dissection.

Skull Base Reconstruction and Cerebrospinal Fluid Leak Repair

Once tumor removal is complete, the sellar resection area is irrigated with full-strength hydrogen peroxide for approximately 1 minute and hemostasis is achieved with Surgifoam. If there is significant diaphragmatic defect, irrigation with

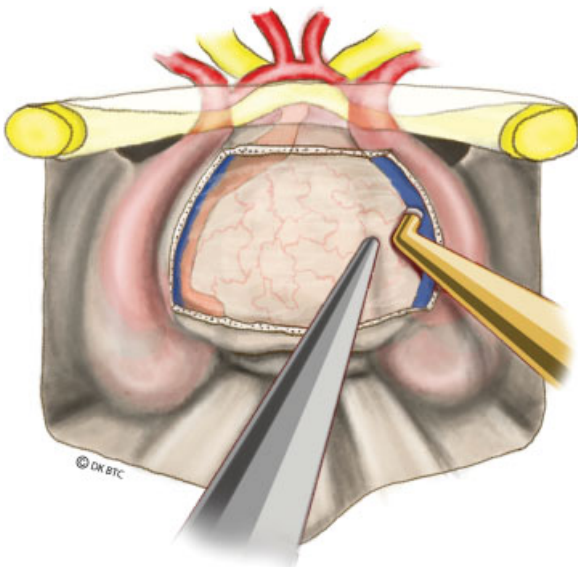


Fig. 3 Artist representation of micro-Doppler usage for localization of the cavernous carotid arteries.

hydrogen peroxide should not be performed. The type of skull base reconstruction performed depends primarily on whether or not a CSF leak is present. Although the grading system for categorizing CSF leaks we described in 2007 is still quite useful, the technical details of repair have evolved in the endoscopic era.²⁵ All repairs involved the use of collagen sponge (Helistat Integra, Hudson NH) as part of the reconstruction. In patients found to have no evidence of a CSF leak following a Valsalva maneuver (grade 0), a single layer of collagen sponge placed over the exposed dura is utilized as the only repair material. This is sealed in place using fibrin glue. Exceptions include very large “dead space” defects or translucent diaphragm sellae that may have potential for hemorrhage or leakage. In such cases, the dead space is filled with an abdominal fat graft. In cases where a small amount of CSF is detected following a Valsalva maneuver but no obvious diaphragmatic defect is visualized (grade 1), a layer of collagen sponge is initially placed under the dural edges. An intrasellar extradural buttress consisting of either the patient’s previously harvested bony septum or a Medpore polyethylene plate (Stryker, Kalamazoo, Michigan, United States) is then placed over the collagen sponge followed by a second outer layer of collagen. The repair is bolstered with tissue glue (DuraSeal, Integra US, Hudson NH; or Tisseel, Baxter Healthcare Corp., Deerfield, IL). Medium-sized CSF leaks (grade 2) or grade 1 leaks with a large amount of intrasellar dead space require the placement of an abdominal fat graft. After harvesting from the lower abdomen, the fat graft is initially placed within the intrasellar space, taking care not to re-create too much mass effect on the suprasellar neurovascular structures. Again, this is followed by an intradural layer of collagen sponge and in some instances an intrasellar extradural rigid buttress. A second layer of fat and collagen is typically placed over this construct and bolstered with tissue glue. To assess the adequacy of the repair, prior to placing tissue glue, the anesthesiologist is asked to perform a Valsalva maneuver to raise the patient’s intracranial pressure. In some instances of grade 1 and 2 leaks in which a buttress is needed but no lateral bone edges are available to safely wedge the buttress in place, a temporary buttress with a Merocel sponge (Medtronic Inc, Minneapolis, MN) is placed in one or both nostrils for up to 5 days (continuous antibiotics while the packs are in place are necessary to prevent toxic shock syndrome). Large defects (grade 3) are typically seen only in extended suprasellar approaches for tumors such as craniopharyngiomas or tuberculoma meningiomas. The repair for such grade 3 leaks consists of virtually the same construct utilized to treat a grade 2 leak with the addition of a nasoseptal flap that is held in place with bilateral Merocel nasal packs, left in place for 5 days.²⁶ Any patient with an intraoperative CSF leak is placed on acetazolamide for 48 to 72 hours after surgery to decrease CSF production. CSF diversion with lumbar drainage is rarely employed.

Closure

Following the sellar reconstruction, blood is suctioned from the sphenoid sinus, nasal cavity, and nasopharynx, and good nasal mucosal hemostasis is obtained to minimize the

amount of blood that is swallowed in the immediate postoperative period. If a nasoseptal flap is necessary to complete our repair, one of the two rescue flaps may be extended in the standard fashion. If not, then the rescue flaps are carefully elevated back along the remaining portion of the vomer and inferior nasal septum to their original location. The middle turbinates are then repositioned anatomically. Nasal packing is typically not utilized unless a buttress is needed as described above to help hold the repair in position. To minimize chances of a postoperative CSF leak, nasal epistaxis, or intrasellar bleeding, excessive coughing or “bucking” should be avoided during extubation and blood pressure carefully monitored and controlled in the early postoperative period. The pharyngeal and gastric contents are typically aspirated of blood products to reduce postoperative nausea/vomiting. Throat packs are not routinely used as they are abrasive to the oropharynx, frequently resulting in patient discomfort.

Indications and Case Illustrations

The endoscopic endonasal transsphenoidal approach and its superior, inferior, and lateral extensions is ideal for a wide variety of sellar and parasellar lesions and is now the most common route for access to the pituitary gland. Lesions accessible through this route include pituitary adenomas, Rathke cleft cysts, clival chordomas, craniopharyngiomas, and sellar arachnoid cysts as well as tuberculoma sellae, cavernous sinus, and petroclival meningiomas. The following cases are illustrative examples of lesions that are best suited for this technique.

Case 1—Nonfunctioning Macroadenoma

The patient was a 39-year-old man with headaches and rapid visual loss in the left temporal field. Ophthalmologic examination demonstrated a bitemporal hemianopsia, which was more pronounced on the left. The patient was also found to have a left afferent pupillary defect as well as decreased visual acuity (20/100) in the left eye. The remainder of his neurologic exam was unremarkable. An MRI of the brain demonstrated a 25 × 29 × 19-mm sellar mass with suprasellar extension, causing severe chiasmal compression (→ Fig. 4). Pituitary hormonal testing revealed low T4 (3.5 µg/dL), inappropriately normal thyroid-stimulating hormone (1.95 µIU/mL), low free (23.5 pg/mL) and total (72ng/dL) testosterone, normal adrenocorticotropic hormone (58 pg/mL) and cortisol (10.6 µg/dL), elevated IGF-1 (388 ng/mL) and prolactin (1,253 ng/mL). The patient did not exhibit any of the usual stigmata of acromegaly or hyperprolactinemia. Due to the acute nature of the patient’s visual loss and the concern for a combined growth hormone/prolactin cosecreting tumor, surgical intervention was performed. The patient underwent an endoscopic endonasal transsphenoidal tumor resection with gross total removal. Pathology was consistent with a typical pituitary adenoma with immunohistochemical staining positively for both growth hormone and prolactin and an elevated Ki-67 proliferative index of 5 to 7%.

The sellar floor was repaired in the standard fashion using collagen sponge, abdominal fat graft, nasal septal bone, and fibrin glue. Although an intraoperative CSF leak was not

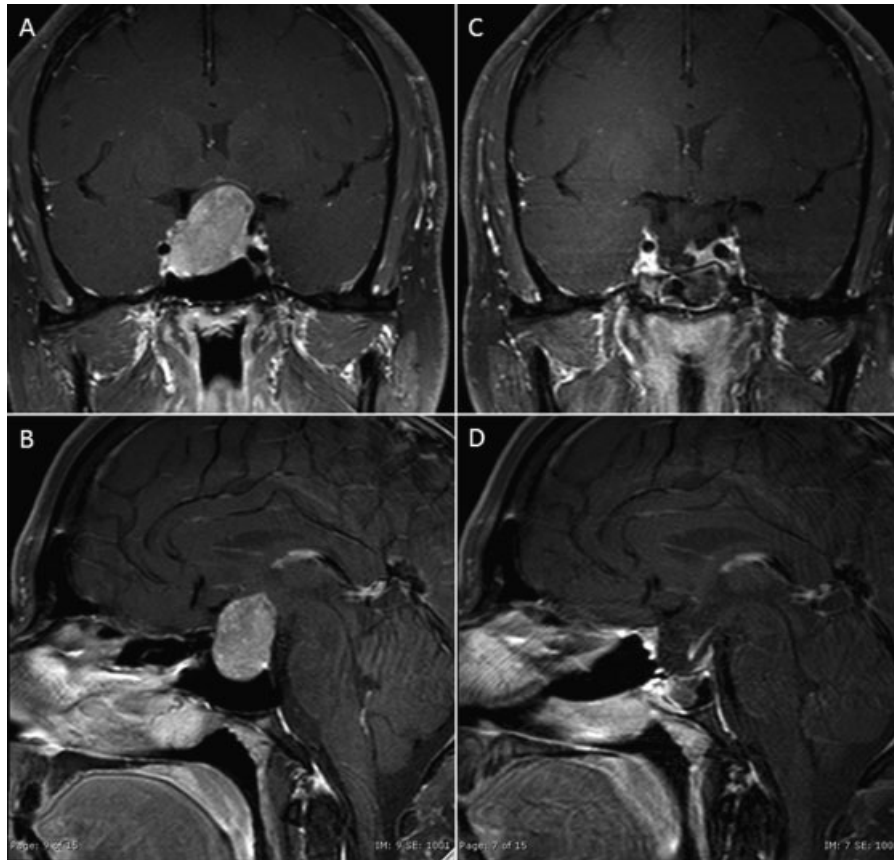


Fig. 4 Case 1. (A, B) Preoperative T1-weighted images with gadolinium demonstrating a hypoenhancing sellar and suprasellar mass with significant optic chiasmal compression and right cavernous sinus invasion. (C, D) Three-month postoperative images demonstrate no evidence of residual or recurrence.

observed, the decision to reinforce the sellar repair with an abdominal fat graft was made due to the large nature of the tumor and to prevent excessive diaphragmatic and optic chiasmal herniation. The patient initially tolerated the procedure well without complications. His postoperative day 2 prolactin level decreased to 53.7 ng/mL. He noticed an immediate improvement in his visual function postoperatively and was discharged home on postoperative day 2. At 3-month follow-up his visual acuity is 20/20 OU and his visual fields are full to confrontation. His follow-up 3-month postoperative MRI demonstrated no obvious residual tumor with a small questionable nodule in the right posterior cavernous sinus region (► **Fig. 4**).

Case 2—Tuberculum Sella Meningioma

A 65-year-old woman presented with transient blurry vision. On further questioning, she reported gradual visual deterioration over several years. Visual acuity testing revealed 20/25 OU. Formal visual field testing revealed bilateral optic nerve dysfunction but without respecting the vertical plane; ophthalmoscopy confirmed bilateral optic atrophy. Sellar MRI demonstrated a 25 × 24 × 23-mm contrast-enhancing suprasellar mass arising from the tuberculum sellae causing severe elevation of the optic apparatus, worse on the right, consistent with a tuberculum sellae meningioma that partially encased the left A2 segment. She had an extended

endoscopic transsphenoidal, transplanum tumor removal. At surgery, the tumor was fibrous and significantly adherent to the right optic nerve and chiasm. Due to the adherent nature of the tumor, a small, 1- to 2-mm fragment of tumor was left along the inferior aspect of the right optic nerve and along the left A2 segment. A grade 3 CSF leak was repaired with collagen sponge, abdominal fat graft, nasoseptal flap, and fibrin glue. Two Merocel nasal packs were left in place as a temporary buttress to hold the repair. She tolerated the procedure well without complications and was discharged home on postoperative day 3. She had transient worsening of her right temporal visual field, which improved by discharge. She had transient diabetes insipidus, requiring one dose of desmopressin (DDAVP), which then resolved and cortisol levels remained normal after surgery. Pathology confirmed a World Health Organization grade 1 meningothelial meningioma. Her MRI on the first postoperative day demonstrated no obvious evidence of residual tumor, despite the known small residual at the time of surgery. She will have another MRI at 3 months postsurgery (► **Fig. 5**).

Lessons Learned—Endoscopic Technique and Technology Applied to Intracranial Surgery: The Supraorbital Eyebrow Craniotomy

As stated by Wilson more than 4 decades ago, “The ideal exposure is one which is large enough to do the job well, while

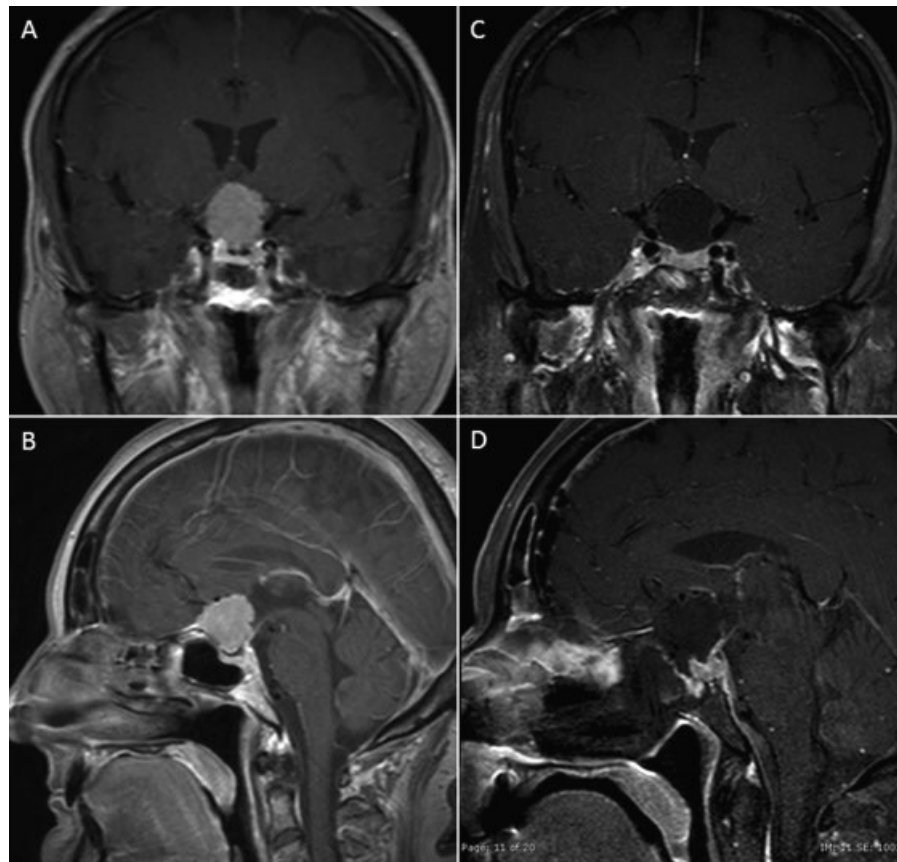


Fig. 5 Case 2. (A, B) Preoperative T1-weighted images with gadolinium demonstrating a homogeneously enhancing lesion arising from the tuberculum sellae causing significant elevation of the optic chiasm. (C, D) Initial postoperative images demonstrate a gross total resection with no evidence of residual.

preserving the integrity of as much normal tissue as possible.” (p. 106)²⁷ The supraorbital eyebrow craniotomy is a well-described, minimally invasive keyhole technique through a small anterolateral craniotomy that provides access to a wide range of anterior and midline skull base pathologies including the anterior fossa floor, the parasellar region, proximal sylvian fissure, circle of Willis, basal frontal lobe, and ventral brainstem.^{14,28} As we described several years ago, this approach is now routinely used as an alternative or complementary approach to the endonasal endoscopic approach for parasellar tumors.²⁹

Determining Which Approach for Which Parasellar Tumors

The most commonly encountered surgical lesions amenable to the supraorbital approach are tuberculum sellae, planum and anterior clinoid meningiomas, some olfactory groove meningiomas, craniopharyngiomas, and intra-axial tumors of the orbitofrontal region, frontal pole, and medial temporal lobe.^{14,28–31} We have employed the supraorbital approach most commonly for select tuberculum sella meningiomas that are over 3 cm in maximal diameter and have vascular encasement or extend well lateral to the supraclinoid carotid arteries or optic nerves. The supraorbital route is used for craniopharyngiomas that are not predominantly in the retrochiasmatic space and instead extend lateral to the supra-

clinoid carotid arteries or into the anterior cranial fossa, as well as some recurrent craniopharyngiomas.

A major benefit of the supraorbital approach over the endonasal endoscopic approach is the simplified closure, which is in stark contrast to the extended endonasal approach that typically requires a nasoseptal flap. Although the benefits of the supraorbital approach are numerous, there are also several key limitations and cautions. These include narrow viewing angles and the necessity for near coaxial control of the microinstruments used through narrow anatomic windows. As with transsphenoidal approaches, one of the most important developments to aid in the evolution of transcranial approaches is the endoscope. The most important disadvantage of a small, less-invasive keyhole approach is the loss of intraoperative light and sight, causing significantly reduced optical control during surgery. For the purpose of bringing light into the surgical field with adequate magnification, the optical properties of modern surgical microscopes can be effectively supplemented with true high-definition endoscopes. Advances in fiberoptic lighting, smaller lenses, and digital camera technology have recently allowed the endoscope to be used for intracranial neurosurgery. Along with these technological advances, neurosurgeons, by building endoscopic skills through transsphenoidal approaches, have increased their experience and versatility with these new techniques. In a series of 450 supraorbital craniotomies,

endoscope-assisted microsurgical techniques were used in 135 cases, giving the advantage of higher light intensity, a clear depiction of details in close-up positions, and an extended viewing angle.³² With the use of angled endoscopes, “blind” corners of the surgical field can be safely controlled without additional extension of the craniotomy. These areas would have been otherwise inaccessible through the keyhole approach using microscopic visualization.

Although the supraorbital approach offers access to most of the anterior fossa floor, parasellar area, and medial aspect of the middle fossa, there are four specific areas that can be difficult to reach and adequately visualize (►Fig. 6). These include the anterior aspect of the olfactory groove, the sellar floor, the region under the ipsilateral optic nerve, and the anterior aspect of the middle fossa under the sphenoid ridge. The midline depression of the olfactory groove along the anterior skull base typically lies below the line of sight provided by the operating microscope. Likewise, a surgical trajectory along the orbital roof will not provide a direct line of sight into the sella itself. Similarly, the area directly under the ipsilateral optic nerve cannot be visualized with microscope without undue optic nerve manipulation. However, reaching these three relative blind spots is possible with the use of an angled endoscope and angled instrumentation. The fourth anatomic limit of the supraorbital approach is the lesser wing of the sphenoid. Lesions with significant extension below the lesser sphenoid wing into the far anterior aspect of the middle cranial fossa may not be accessible from a supraorbital craniotomy. In such cases, a traditional pterional or minipterional craniotomy may be required to achieve access inferior and anterior to the sphenoid ridge.¹⁴

Surgical Technique—Supraorbital “Eyebrow” Craniotomy

The operation is performed under general anesthesia with placement of a Foley catheter and arterial line in most cases. The patient’s head is fixed in a Mayfield three-pin head holder, angled ~30 degrees away from the operative side

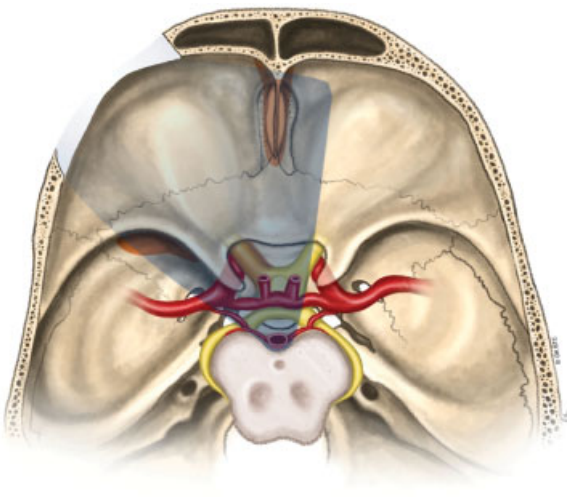


Fig. 6 Artist representation of the surgical access provided by the supraorbital craniotomy.

and extended such that malar eminence is prominent, similar to traditional pterional positioning. The Stryker navigation system is attached to the patient’s head and is registered to the surgical navigation MRI. The ipsilateral upper quadrant of the abdomen is marked and prepped in case an abdominal fat graft should become necessary. The eyebrow incision is marked and prepped and draped in usual sterile fashion. The eyebrow incision is made, starting from just medial to the supraorbital notch and extending laterally in the midst of the eyebrow to its termination with ~5-mm extension in that trajectory. Sharp dissection is taken down to the pericranium, and a subgaleal plane is created in the supraorbital region. The dissection extends laterally to the superior part of the temporalis fascia and just lateral to the superior temporal line. The supraorbital nerve is identified medially and preserved. Multiple fishhooks are placed on the superior aspect of the incision to expose the supraorbital area. A pericranial cuff is then cut, extending from immediately lateral to the supraorbital nerve, coursing superiorly in the arc of the planned craniotomy, over the superior temporal line and into the temporalis fascia and muscle. This pericranial cuff is elevated with subperiosteal dissection and retracted over the brow with a stitch.

A single bur hole is placed with a “matchstick” bit just inferior and lateral to the superior temporal line and behind the frontozygomatic process. The underlying dura is then elevated from the overlying bone. The craniotomy extends from the bur hole, medially along the supraorbital ridge. Although effort should be made to avoid entering the frontal sinus, this should not be at the expense of limiting the extent of the craniotomy, as maximizing the inferior extent of the craniotomy is critical both for visualization and for maneuvering of surgical instruments. The standard supraorbital craniotomy is 2 to 2.5 cm wide and 1.5 to 2 cm tall (►Fig. 7). Again, proper positioning of the craniotomy as low as possible on the anterior fossa floor is important to obtain an optimal surgical trajectory. If the frontal sinus is entered, temporary occlusion accomplished with an iodine-soaked Gelfoam, and definitive repair is completed with an abdominal fat graft during closure. To facilitate exposure, the inner surface of the calvarium is drilled inferiorly along the floor of the frontal fossa including

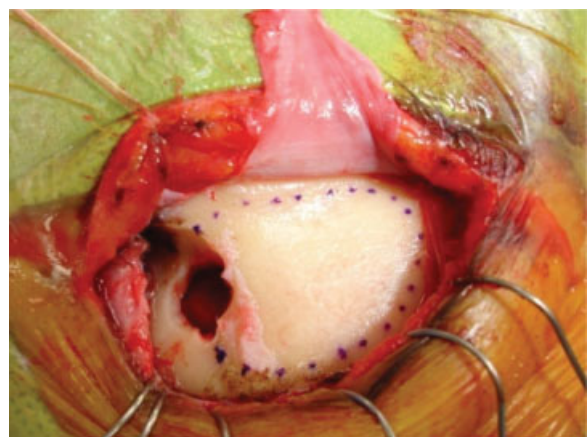


Fig. 7 Intraoperative photograph of a left supraorbital craniotomy demonstrating bur hole and craniotomy placement.

any protuberances of the orbital roof. This maneuver is essential to optimize the flat surgical trajectory along the frontal floor, as even small boney ridges may significantly impair the line of sight to the sellar region. The dura is then opened in a u-shaped fashion and reflected inferiorly over the orbital rim. The dural flap is kept moist and under tension throughout the case to prevent shrinking and allow for a watertight closure. Immediately after dural opening, a small arachnoid incision into the opticocarotid cistern is made to allow for CSF egress as the microscope is brought into position. The remainder of the procedure is completed with a combination of microscopic and endoscopic visualization. Brain retractors are used infrequently.

Under microscopic visualization, the subfrontal corridor is dissected. The frontal lobe is protected with a strip of Telfa (Integra US, Hudson, NH), and the ipsilateral optic nerve and supraclinoid carotid artery are identified. The arachnoid of the opticocarotid and optico-oculomotor cisterns is opened widely to allow further CSF egress. The release of CSF is essential to achieve adequate brain relaxation and avoid frontal lobe retraction. Additional dissection of arachnoid at the base of the frontal lobe and within the proximal sylvian fissure will free the frontal lobe from the basal cisterns and temporal lobe and allow it to fall away with gravity.

Following these maneuvers, a field of view including the ipsilateral proximal sylvian fissure, the ipsilateral third nerve,

both optic nerves, the optic chiasm, the lamina terminalis, both supraclinoid carotid arteries, both A1 segments, the anterior communicating artery, both A2 segments, and the pituitary stalk is possible. Additional dissection through the opticocarotid or optico-oculomotor windows will expose the ventral brainstem, basilar artery, and other posterior circulation vessels and perforators. Standard microsurgical dissection and tumor removal then proceeds with care taken to preserve arachnoid membranes and key neurovascular structures such as the superior hypophyseal arteries. Tumors densely adherent to the optic apparatus or circle of Willis vessels, which is common with craniopharyngiomas, are often best left behind to avoid new neurologic deficits.

With the use of a 30- or 45-degree angled endoscope, a view over the tuberculum sellae into the pituitary fossa, over sphenoid ridge into the middle fossa, over the dorsum sellae into the prepontine cistern, and over the orbital roof to the cribriform recess is possible.¹⁴ When necessary, the supraorbital approach can be used to reach as far posteriorly and inferiorly to the ventral brainstem and superior one-third of the clivus.

The dural closure involves reapproximation and primary closure (when possible) of dural edges, followed by placement of a large piece of collagen sponge. Fat grafts are utilized to seal large defects of the frontal sinus. These are reinforced and secured with Tisseel. The bone flap is reapproximated with a lateral bur hole cover and a medial straight plate with

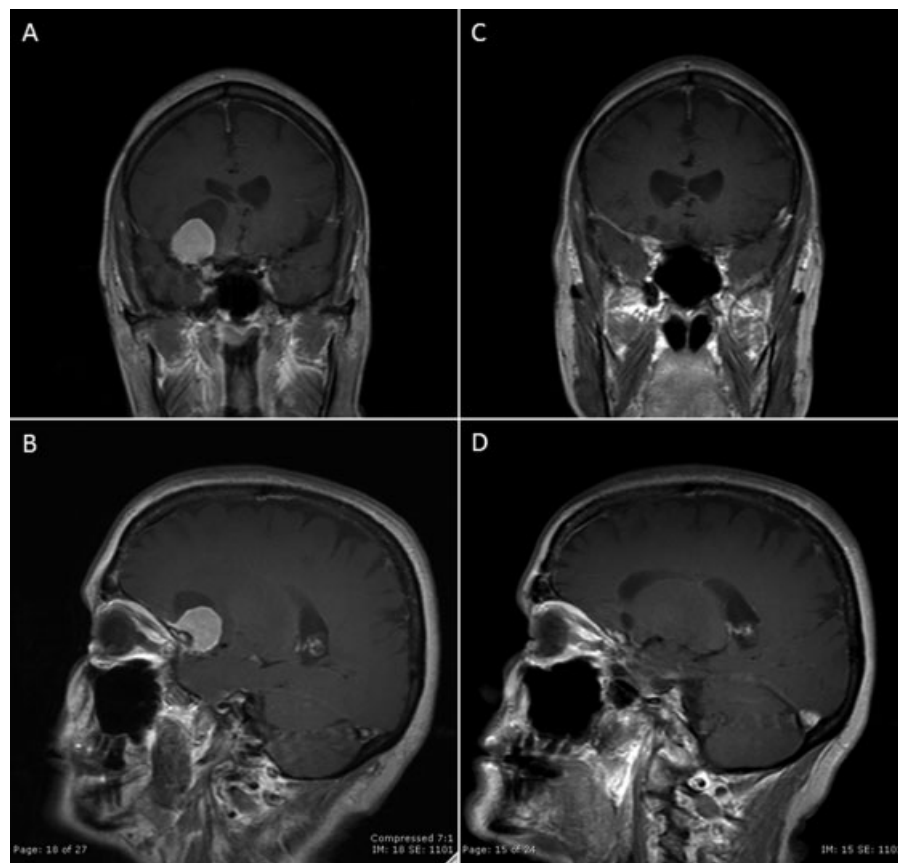


Fig. 8 Case 3. (A, B) Preoperative T1-weighted images with gadolinium demonstrating a homogeneously enhancing lesion arising from the right clinoid and medial sphenoid wing with an associated arachnoid cyst. (C, D) Two-year postoperative images demonstrate no evidence of residual or recurrence.

4-mm titanium screws. The bone flap is placed to eliminate any gap superiorly, and the gap inferiorly is filled with collagen matrix. The incision is irrigated with antibiotic-containing saline. The pericranial flap is repositioned with multiple 3–0 Vicryl stitches (Johnson & Johnson, New Brunswick, NJ). The scalp is closed with interrupted inverted 3–0 Vicryl sutures followed by a running subcuticular 5–0 Monocryl stitches (Johnson & Johnson, New Brunswick, NJ) Antibiotic ointment, sterile dressing, and gentle head wrap compressive dressing is applied to help avoid a hematoma. Care is taken to avoid excess pressure with the head wrap to prevent pressure urticaria or skin necrosis.

Supraorbital Craniotomy—Case Illustration

Case 3—Clinoidal Meningioma

A 67-year-old woman suffered a ground-level fall and was found to have an incidental right paraclinoidal meningioma on CT. An MRI further characterized the lesion as a homogeneously enhancing 26 × 22 × 22-mm mass arising from the right anterior clinoid and medial sphenoid wing with an associated arachnoid cyst. Moderate surrounding vasogenic edema and 6 mm of right-to-left subfalcine herniation were noted. The imaging characteristics were consistent with an anterior clinoidal meningioma. Her neurologic examination was nonfocal. Due to the tumor extending lateral to the optic nerves and supraclinoid carotid artery along the sphenoid wing, a right supraorbital craniotomy was selected for resection. The 30-degree angled endoscope was invaluable in visualizing and resecting tumor along the lateral wall of the cavernous sinus and extending into the sylvian fissure. At the time of surgery, it was felt that gross total resection was achieved. The patient tolerated the procedure well and there were no complications. Postoperative follow-up MRI demonstrates a small amount of persistent enhancement along the clinoidal dura and medial sphenoid wing. Two years after surgery, this has been stable and has not demonstrated any evidence of tumor progression or recurrence (→ Fig. 8).

Final Comments

Although tremendous advances have been made in transitioning toward minimally invasive transcranial and transsphenoidal approaches to the sella, further work remains to be done. Rather than representing a finished product, the current state of the art represents just another step in the continual march toward improved outcomes and decreased morbidity. When considering any approach to a pathologic entity, it is important to understand the advantages and disadvantages of a given procedure. Familiarity with the techniques and the indications and surgical anatomy for each approach will allow the surgeon to tailor the operation to the approach best suited for each patient.

References

- Horsley V. On techniques of the operations of the central nervous system. *BMJ* 1906;2:411–423
- Gandhi CD, Christiano LD, Eloy JA, Prestigiacomo CJ, Post KD. The historical evolution of transsphenoidal surgery: facilitation by technological advances. *Neurosurg Focus* 2009;27(3):E8
- Liu JK, Das K, Weiss MH, Laws ER Jr, Couldwell WT. The history and evolution of transsphenoidal surgery. *J Neurosurg* 2001;95(6):1083–1096
- Mcarthur L. An aseptic surgical access to the pituitary body and its neighborhood. *JAMA* 1912;58:2009–2011
- Cushing H. *The Pituitary Body and Its Disorders: Clinical States Produced by Disorders of the Hypophysis Cerebri*. Philadelphia, PA: J.B. Lippincott; 1912:296–305
- Kanter AS, Dumont AS, Asthagiri AR, Oskouian RJ, Jane JA Jr, Laws ER Jr. The transsphenoidal approach. A historical perspective. *Neurosurg Focus* 2005;18(4):e6
- Jane JA Jr, Han J, Prevedello DM, Jagannathan J, Dumont AS, Laws ER Jr. Perspectives on endoscopic transsphenoidal surgery. *Neurosurg Focus* 2005;19(6):E2
- Hirsch O. Endonasal method of removal of hypophyseal tumors. With a report of two successful cases. *JAMA* 1910;5:772–774
- Halstead A. Remarks on the operative treatment of tumors of the hypophysis. With the report of two cases operated on by an oronasal method. *Trans Am Surg Assoc* 1910;28:73–93
- Henderson WR. The pituitary adenomata. A follow-up study of the surgical results in 338 cases (Dr. Harvey Cushing's series). *Br J Surg* 1939;26(104):811–921
- Horwitz NH. Library: historical perspective. Norman M. Dott (1897–1973). *Neurosurgery* 1999;45(4):944–948
- Landolt AM. History of pituitary surgery from the technical aspect. *Neurosurg Clin N Am* 2001;12(1):37–44, vii–viii
- Cutler AR, Barkhoudarian G, Griffiths CF, Kelly DF. Transsphenoidal endoscopic skull base surgery: state of the art and future perspective. *Innovative Neurosurgery* 2013;1:15–35
- Wilson DA, Duong H, Teo C, Kelly DF. The supraorbital endoscopic approach for tumors. *World Neurosurg* 2013;(e-pub ahead of print)
- Griffith HB, Veerapen R. A direct transnasal approach to the sphenoid sinus. Technical note. *J Neurosurg* 1987;66(1):140–142
- Zada G, Kelly DF, Cohan P, Wang C, Swerdloff R. Endonasal transsphenoidal approach for pituitary adenomas and other sellar lesions: an assessment of efficacy, safety, and patient impressions. *J Neurosurg* 2003;98(2):350–358
- Jho HD, Carrau RL. Endoscopic endonasal transsphenoidal surgery: experience with 50 patients. *J Neurosurg* 1997;87(1):44–51
- Doglietto F, Prevedello DM, Jane JA Jr, Han J, Laws ER Jr. Brief history of endoscopic transsphenoidal surgery—from Philipp Bozzini to the First World Congress of Endoscopic Skull Base Surgery. *Neurosurg Focus* 2005;19(6):E3
- Barahona MJ, Sojo L, Wägner AM, et al. Determinants of neurosurgical outcome in pituitary tumors. *J Endocrinol Invest* 2005;28(9):787–794
- Barkhoudarian G, Del Carmen Becerra Romero A, Laws ER. Evaluation of the 3-dimensional endoscope in transsphenoidal surgery. *Neurosurgery* 2013;73(1, Suppl Operative):ons74–ons78, discussion ons78–ons79
- Griffiths CF, Cutler AR, Duong HT, et al. Avoidance of postoperative epistaxis and anosmia in endonasal endoscopic skull base surgery: a technical note. *Acta Neurochir (Wien)* 2014;156(7):1393–1401
- Dusick JR, Esposito F, Malkasian D, Kelly DF. Avoidance of carotid artery injuries in transsphenoidal surgery with the Doppler probe and micro-hook blades. *Neurosurgery* 2007;60(4, Suppl 2):322–328, discussion 328–329
- Oldfield EH, Vortmeyer AO. Development of a histological pseudocapsule and its use as a surgical capsule in the excision of pituitary tumors. *J Neurosurg* 2006;104(1):7–19
- McLaughlin N, Eisenberg AA, Cohan P, Chaloner CB, Kelly DF. Value of endoscopy for maximizing tumor removal in endonasal transsphenoidal pituitary adenoma surgery. *J Neurosurg* 2013;118(3):613–620

- 25 Esposito F, Dusick JR, Fatemi N, Kelly DF. Graded repair of cranial base defects and cerebrospinal fluid leaks in transsphenoidal surgery. *Neurosurgery* 2007;60(4, Suppl 2):295–303, discussion 303–304
- 26 Hadad G, Bassagasteguy L, Carrau RL, et al. A novel reconstructive technique after endoscopic expanded endonasal approaches: vascular pedicle nasoseptal flap. *Laryngoscope* 2006;116(10):1882–1886
- 27 Wilson DH. Limited exposure in cerebral surgery. Technical note. *J Neurosurg* 1971;34(1):102–106
- 28 Reisch R, Perneczky A, Filippi R. Surgical technique of the supra-orbital key-hole craniotomy. *Surg Neurol* 2003;59(3):223–227
- 29 Fatemi N, Dusick JR, de Paiva Neto MA, Malkasian D, Kelly DF. Endonasal versus supraorbital keyhole removal of craniopharyngiomas and tuberculum sellae meningiomas. *Neurosurgery* 2009;64(5, Suppl 2):269–284, discussion 284–286
- 30 Reisch R, Stadie A, Kockro R, Gawish I, Schwandt E, Hopf N. The minimally invasive supraorbital subfrontal key-hole approach for surgical treatment of temporomesial lesions of the dominant hemisphere. *Minim Invasive Neurosurg* 2009;52(4):163–169
- 31 McLaughlin N, Ditzel Filho LF, Shahlaie K, Solari D, Kassam AB, Kelly DF. The supraorbital approach for recurrent or residual suprasellar tumors. *Minim Invasive Neurosurg* 2011;54(4):155–161
- 32 Reisch R, Perneczky A. Ten-year experience with the supraorbital subfrontal approach through an eyebrow skin incision. *Neurosurgery* 2005;57(4, Suppl):242–255, discussion 242–255