

Compound posterior cruciate ligament and popliteal artery injury due to dog bite: A case report



Yashwant Singh Tanwar ^{a,*}, Atin Jaiswal ^b, Hitesh Lal ^c, Ashok Rajput ^c

^a Indraprastha Apollo Hospital Delhi, Delhi, India

^b Bokaro General Hospital, Bokaro, Jharkhand, India

^c Dr RML Hospital & PGIMER, India

ARTICLE INFO

Article history:

Received 12 July 2015

Received in revised form

28 September 2015

Accepted 11 November 2015

Available online 29 June 2017

Keywords:

Dog bite

PCL injury

Popliteal artery injury

ABSTRACT

Injuries due to dog bites are a common occurrence and are mostly trivial. Severe dog bite injuries requiring hospitalization and complex reconstructive procedures are more common in children. We present the case of a five year old child with popliteal artery thrombosis and compound Posterior Cruciate ligament injury due to a dog bite. The child was managed by immediate thrombectomy, meticulous debridement and knee spanning external fixation followed by Skin Grafting. At one year post surgery range of motion was 10–110°, with no distal neurovascular deficit and no sign of instability.

© 2017 Turkish Association of Orthopaedics and Traumatology. Publishing services by Elsevier B.V. This is an open access article under the CC BY-NC-ND license (<http://creativecommons.org/licenses/by-nc-nd/4.0/>).

Introduction

Humans and dogs have been associated historically. However a dog is a formal wild animal and sometimes due to its retained instincts, may lead to attacks on humans.¹ According to some reports, in a lifetime, at least 50% of the population will sustain a dog bite.² Incidence is especially high in children.³ In younger children most common areas involved are head, neck and face while in older children extremities are involved more often.⁴

Vascular injuries from large-dog bite injuries present with a combination of crush and lacerating injury to the vessel. There is significant adjacent soft tissue injury and a high potential of infection. These injuries can be repaired primarily and a good outcome can be expected provided strict cleaning, debridement, meticulous wound repair, adequate antibiotic and immunization cover is given.

PCL (Posterior Cruciate ligament) injuries are rare in children probably because of elasticity of the ligament. In contrast to PCL injuries in adults where mid-substance tears are more common, paediatric PCL injuries more commonly involve an osteochondral avulsion due to relative weakness of the adjacent physis.⁵ Subtle

signs of injury to the PCL can be easily be missed on plain radiographs in skeletally immature patients, therefore a high index of suspicion is necessary to diagnose them. Isolated PCL injuries when confirmed on Magnetic Resonance Imaging are usually managed conservatively with a predictable outcome.

We present the case of a 5 year old female child who sustained a compound PCL injury and popliteal artery thrombosis due to a dog bite. To the best of our knowledge this is the first case report of a compound PCL injury leading to knee subluxation in a child.

Case report

A 5 years old female child presented to the emergency department with history of pet dog bite. Most of the dog bites occur from animals known to the victim and in this case it was no different. On examination there were multiple lacerated wounds over right ear lobe, right thigh, left thigh, left leg and ankle region, and right arm (Fig. 1). The most grievous wound was over the right popliteal fossa measuring around 8 cm in length and 4 cm in breadth (Fig. 2).

Neurovascular examination revealed absence of posterior tibial and dorsalis pedis pulses distally; distal perfusion was diminished and capillary refill was sluggish. Limb was cold suggesting vascular insult to the limb. Peroneal nerve functions were intact. Urgent Doppler study of the limb was done which suggested blockage of the popliteal artery in popliteal fossa region. Deformity was present at the knee joint suggesting posterior subluxation of the knee. Antitetanus and antirabies prophylaxis (both human

* Corresponding author.

E-mail address: tanwar_yashwant@yahoo.co.in (Y.S. Tanwar).

Peer review under responsibility of Turkish Association of Orthopaedics and Traumatology.

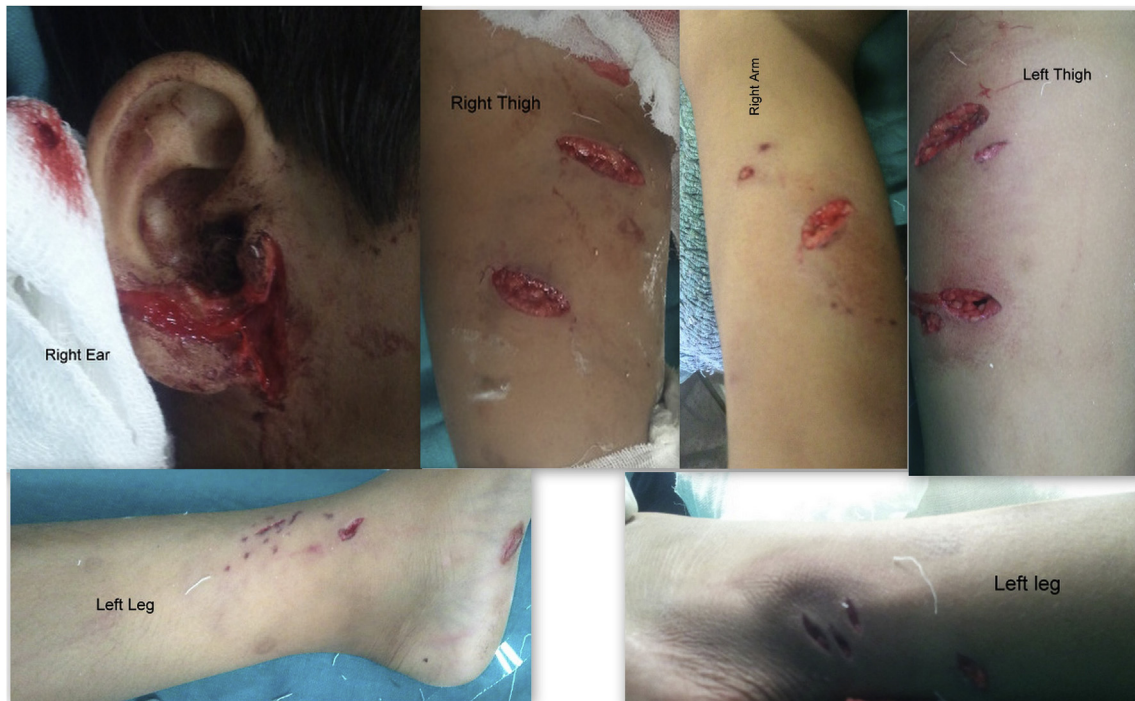

Fig. 1. Showing multiple lacerated wounds over right ear lobe, right thigh, left thigh, left leg and ankle region, and right arm.

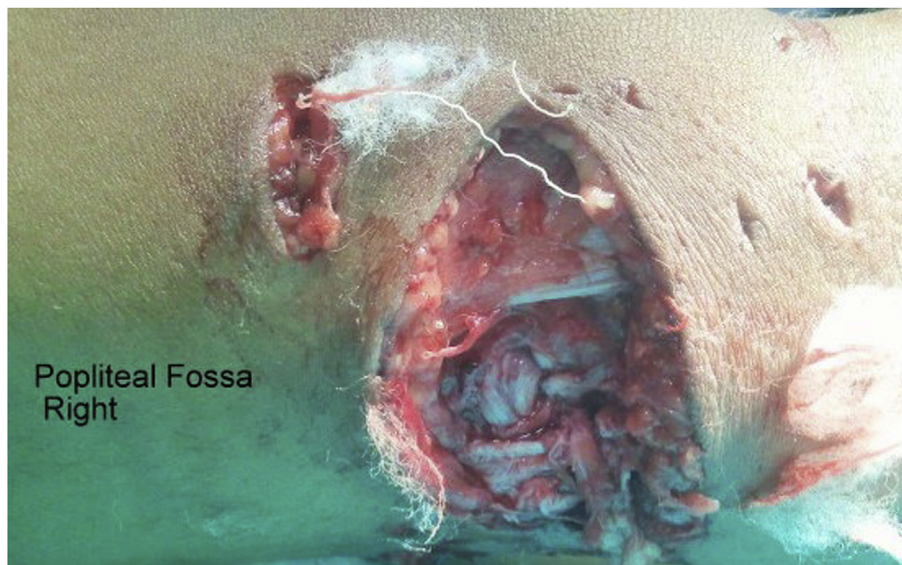

Fig. 2. Showing a large lacerated wound over the right popliteal fossa.

immunoglobulin and vaccine) were given to the patient and broad spectrum intravenous antibiotics in the form of Amoxycillin and Clavulanate combination was given for 5 days.

Patient was immediately taken to the operative room after basic preliminary investigations and vascular surgeons were informed. On exploration the underlying muscles and soft tissue including the PCL tibial attachment site were found to be lacerated and the tibial plateau was exposed. Meticulous debridement of the wound was done. Popliteal artery was found to be intact but was contused and thrombosed (Fig. 3). Arteriotomy was done and a large intramural thrombus was seen. Fogarty's catheter was passed distally, balloon was inflated and the thrombus was removed, adequate back flow

was achieved. Arteriotomy was closed with 5-0 nylon suture. Knee was unstable and posterior Drawer test was positive (Fig. 4). There were no other associated ligamentous injuries including the postero-lateral corner and ACL. Knee was stabilised with external fixator in 30 degrees of flexion to avoid stress on the repaired vascular segment. Wounds were again debrided and lavaged with copious amount of saline. All the wounds were closed primarily except the popliteal one. Since the limb was revascularized within 4 h of the injury, it was decided not to perform prophylactic fasciotomy. Anticoagulant therapy in the form of low molecular weight heparin 15 mg twice daily subcutaneously was started and continued for two weeks. Postoperatively limb remained warm and

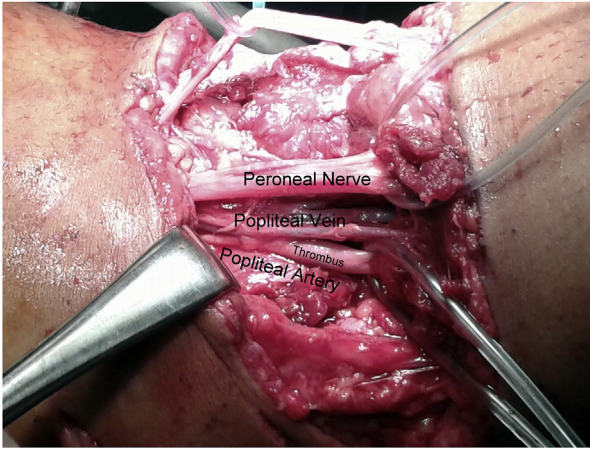


Fig. 3. Showing the neurovascular structures and the thrombus in popliteal artery.

perfused and distal pulsations were present. The limb was observed for reperfusion injury and compartment syndrome. Postoperative period was uneventful and the wound was grafted after 10 days.

External fixator was removed after six weeks and gradual ranges of motion exercises were started. At one year post surgery range of motion was 10–110°, with no distal neurovascular deficit and no sign of instability (Fig. 5).

Discussion

Dog bites account for 0.3%–1.5% of all paediatric presentations for medical attention.^{6,7} WHO classifies contact with a suspected animal into three categories. For category I no treatment is required, whereas for category II immediate vaccination and for category III immediate vaccination and administration of rabies immune globulin are recommended in addition to immediate washing and flushing of all bite wounds and scratches.⁸ As much as possible of the recommended dose (20 IU/kg of body weight of Human Rabies Immunoglobulin) should be infiltrated around the wounds if anatomically feasible. The remainder should be administered intramuscularly (into gluteal region) in a single dose.

Acute dislocation of knee is uncommon in children as forces require to produce dislocation are more likely to fracture adjacent epiphyses and they usually involve major injuries of the associated soft tissues and neurovascular structures.⁹ Ligament reconstruction after acute knee dislocation is usually done after two to three weeks. Before this time there is risk of fluid extravasation during arthroscopy due to capsular tear and after this time period the repair becomes difficult due to scarring and lack of definition of tissues. Isolated paediatric PCL injuries are managed conservatively in a knee splint or brace and have a good functional outcome. Surgical treatment in the form of fixation of a displaced avulsed fragment or reconstruction of a mid-substance tear is usually reserved for patients with multi-ligamentous injuries and those

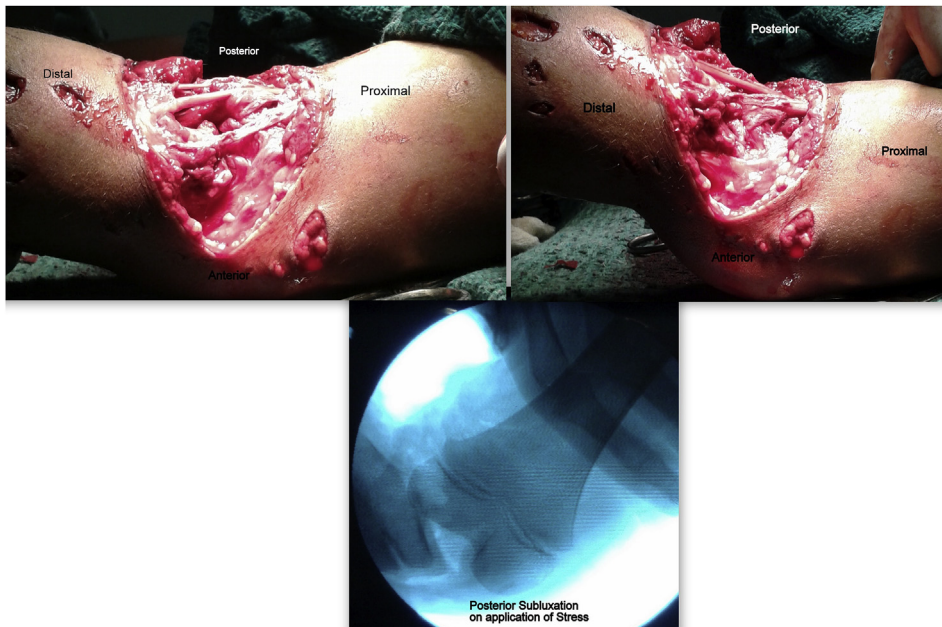


Fig. 4. Showing a positive posterior Drawer test and knee subluxation on application of posterior stress.

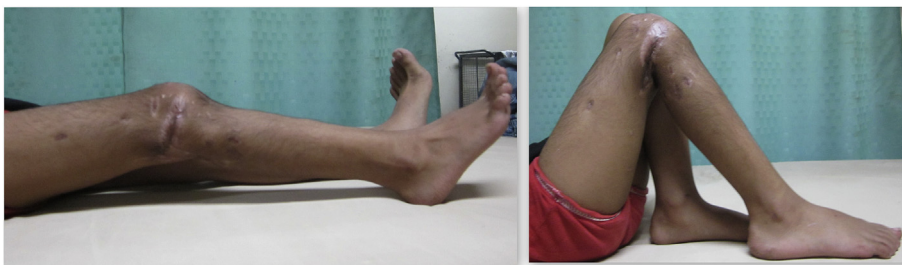

Fig. 5. Showing the range of motion at final follow up at 1 year.

who have failed conservative management.¹⁰ Hesse et al reported a case of femoral avulsion fracture of the posterior cruciate ligament in association with a rupture of the popliteal artery in a 9-year-old boy. Popliteal artery injury was managed by saphenous vein bypass graft and PCL avulsion was fixed using transosseous femoral fixation using non-absorbable stitches.¹¹ We in the present case managed the PCL injury conservatively as immobilization in the form of a knee spanning external fixator was required for the management of the wound and the vascular repair. The PCL injury was a mix of tear and some crushing at the tibia attachment site. The patient had no residual instability at the end of one year and a favourable outcome in the present case further adds evidence to the practice that isolated paediatric PCL injuries can be managed conservatively.

In a study comprising of 371 adult cases of dog bite injuries incidence of vascular injuries requiring repair was found to be 5.4%.¹² The popliteal artery is especially prone to injury since it is fixed proximally at the adductor magnus hiatus, and distally at the fibrous arch of the soleus and interosseus membrane. Vascular injuries of the extremities in paediatric patients usually have a favourable outcome and can be managed most of the times by thrombectomy or simple resection and anastomosis.¹³ Popliteal artery thrombosis in the present case may have been secondary to knee dislocation and not due to direct bite injury. If a long stretch of artery is damaged then resection and reverse Great Saphenous vein graft should be recommended. Due to small size of the GSV, there may be discrepancy between the size of popliteal vessel and the vein. Angiletta et al described stenting of femoro-popliteal artery to defer further surgery until the child was older and the arteries and veins for reconstruction grew larger.¹⁴ There are some key considerations that should be kept in mind while managing paediatric vascular injuries. The vessel size is small, there is a tendency of vessel spasm and for restenosis and the rapid body growth may stretch the repaired segment. Prophylactic fasciotomy after arterial repair is recommended if the interval between injury and repair is more than 6 h and/or if there is an associated venous injury requiring ligation.¹⁵

Complications of dog bite injuries include superficial and deep infections, cellulitis, osteomyelitis, septic arthritis, meningitis, endocarditis, pneumonia, purpura, vascular injuries and death.^{16,17} In addition to physical trauma, psychological and mental disorders has been reported in children after such terrifying experience.¹⁸ The memories of a vicious dog bite may eventually fade but the fear and emotional damage can last a lifetime. Post-traumatic stress disorder has been known to occur in children after animal bite injuries.

Management of dog bite injuries are a topic of controversy as regard to primary wound closure and role of prophylactic antibiotics is concerned. However all the visible dirt should be removed by copious irrigation with normal saline and all the dead and devitalised tissue should be removed with meticulous debridement. Injection of the tissue with irrigant solution should be avoided, because this can spread the infection. Wu PS et al showed that primary repair of paediatric facial dog bite injuries, including complex soft-tissue injuries, is safe when performed in conjunction with antibiotic administration.¹⁹ Puncture wounds, wounds that appear clinically infected and wounds more than 24 h old may have a better outcome with delayed primary closure or healing by secondary intention. History of tetanus immunisation should be asked

for and active tetanus immunisation or immunoglobulins should be administered.²⁰

Conclusion

To conclude Dog bites occur more frequently in young children and have a higher risk of resulting in serious injury or death, usually from exsanguination.²¹ Thorough and copious lavage, wound cleaning and debridement should be done as early as possible to minimise infections. Antibiotic, antitetanus and antirabies prophylaxis should be administered in high risk cases. In case of knee dislocation in a child, there should be a strong suspicion for neurovascular injury. Prompt diagnosis and early intervention in cases of neurovascular injury is desirable for the survival and good functional outcome of limb. Due protection of the repaired vascular structure by immobilisation of the extremity and fasciotomy of the limb to prevent reperfusion injury and compartment syndrome in delayed presentations are the key to have a successful vascular repair.

References

- Weiss HB, Friedman DI, Coben JH. Incidence of dog bite injuries treated in emergency departments. *J Am Med Assoc.* 1998;279(1):51–53.
- Abrahamian FM. Dog bites: bacteriology, management, and prevention. *Curr Infect Dis Rep.* 2000 Oct;2(5):446–453.
- Keuster TD, Lamoureux J, Kahn A. Epidemiology of dog bites: a Belgian experience of canine behaviour and public health concerns. *Vet J.* 2006;172(3):482–487.
- Centers for Disease Control and Prevention. Nonfatal dog bite-related injuries treated in Hospital Emergency Departments—United States, 2001. *MMWR.* 2003;52(26):605–610.
- Frank C, Strother R. Isolated posterior cruciate ligament injury in a child: literature review and a case report. *Can J Surg.* 1989;32(5):373–374.
- Chomel BB, Trotignon J. Epidemiologic surveys of dog, cat bites in the Lyon area, France. *Eur J Epidemiol.* 1992 Jul;8(4):619–624.
- Avner JR, Baker MD. Dog bites in urban children. *Pediatrics.* 1991;88(1):55–57.
- World Health Organisation: Rabies—Guide for Post-exposure Prophylaxis. <http://www.who.int/rabies/human/postexp/en/>.
- Garland JJ, Brenner JH. Traumatic dislocations in the lower extremities in children. *Orthop Clin North Am.* 1976 Jul;7(3):687–700.
- Kocher MS, Shore B, Nasreddine AY, Heyworth BE. Treatment of posterior cruciate ligament injuries in pediatric and adolescent patients. *J Pediatr Orthop.* 2012 Sep;32(6):553–560.
- Hesse E, Bastian L, Zeichen J, Pertschy S, Bosch U, Krettek C. Femoral avulsion fracture of the posterior cruciate ligament in association with a rupture of the popliteal artery in a 9-year-old boy: a case report. *Knee Surg Sports Traumatol Arthrosc.* 2006 Apr;14(4):335–339.
- Akingba AG, Robinson EA, Jester AL, et al. Management of vascular trauma from dog bites. *J Vasc Surg.* 2013 Nov;58(5):1346–1352.
- Corneille MG, Gallup TM, Villa C, Richa JM, Wolf SE, Myers JG. Pediatric vascular injuries: acute management and early outcomes. *J Trauma.* 2011 Apr;70(4):823–828.
- Angiletta D, Impedovo G, Pestrinchella F, Marotta V, Perilli F, Regina G. Blunt femoropopliteal trauma in a child: is stenting a good option. *J Vasc Surg.* 2006;4(1):201–204.
- Field CK, Senkowsky J, Hollier LH, et al. Fasciotomy in vascular trauma: is it too much, too often? *Am Surg.* 1994 Jun;60(6):409–411.
- Garcia VF. Animal bites and Pasteurella infections. *Pediatr Rev.* 1997;18(4):127–130.
- Findling JW, Rose HD. Purpura after dogbite. *South Med J.* 1981 Jan;74(1):89.
- Anyfantakis D, Botzakis E, Mplevrakis E, Symvoulakis EK, Arbiros I. Selective mutism due to a dog bite trauma in a 4-year-old girl: a case report. *J Med Case Rep.* 2009 Nov 3;3:100.
- Wu PS, Beres A, Tashjian DB, Moriarty KP. Primary repair of facial dog bite injuries in children. *Pediatr Emerg Care.* 2011 Sep;27(9):801–803.
- American Academy of Pediatrics. Bite wounds. In: Pickering LK, Baker CJ, Kimberlin DW, Long SS, eds. *Red Book: 2009 Report of the Committee on Infectious Diseases.* 28th ed. Elk Grove Village, IL: American Academy of Pediatrics; 2009:187–191.
- Morgan M, Palmer J. Dog bites. *BMJ.* 2007;334(7590):413–417.