

Available online at www.sciencedirect.com

ScienceDirect

journal homepage: www.elsevier.com/locate/ihj

Case Reports

Aconite poisoning with arrhythmia and shock



Sandeep Tak^{a,*}, Manoj Lakhotia^b, Alok Gupta^b, Amit Sagar^c,
Gopal Bohra^c, Rajesh Bajari^d

^a Asso. Professor of Medicine, Dr. S.N. Medical College, Jodhpur, India

^b Professor of Medicine, Dr. S.N. Medical College, Jodhpur, India

^c Assistant Professor of Medicine, Dr. S.N. Medical College, Jodhpur, India

^d Resident, Department of Medicine, Dr. S.N. Medical College, Jodhpur, India

ARTICLE INFO

Article history:

Received 23 June 2015

Accepted 10 August 2015

Available online 14 January 2016

Keywords:

Aconite

Arrhythmia

Shock

Amiodarone

Cardiotoxicity

ABSTRACT

A 55-year-old male presented with history of nausea, vomiting, palpitation paresthesia and profuse sweating in emergency department 2 h after ingestion of “Bachnaag” (Aconite) root. Examination revealed shock with irregular pulses. Initial ECG showed frequent multifocal ventricular ectopics (VE), which later turned to short runs of ventricular tachycardia (VT). Immediate gastric lavage was done and activated charcoal given. Patient was treated with fluid resuscitation without any improvement in blood pressure. Patient was started on nor-adrenaline infusion with gradual recovery from hypotension over a period of 6 h, but support was continued for 48 h. Amiodarone was started to control ventricular excitability, which persisted over 72 h with gradual decrease in frequency of VT and VE. Patient was discharged with normal sinus rhythm on oral amiodarone on 5th day of hospitalization. On follow-up after 2 weeks patient was totally asymptomatic and amiodarone was stopped.

© 2015 Cardiological Society of India. Published by Elsevier B.V. This is an open access article under the CC BY-NC-ND license (<http://creativecommons.org/licenses/by-nc-nd/4.0/>).

1. Case report

A 55-year-old male presented in emergency department with history of epigastric burning, nausea, vomiting, dizziness, generalized paresthesia, palpitation, and profuse sweating of 2 h duration. Patient had no history of chest pain. Patient had past history of ischemic stroke 1-year back and residual left hemiparesis. After reading a book of traditional/Ayurvedic medicine, patient decided to self-medicate with “Bachnaag” (Aconite) root for residual hemiparesis. He procured Aconite root from Ayurvedic pharmacy and took about five gram of dried root of aconite plant. Patient became symptomatic within 1 h of taking aconite root (Fig. 1).

On examination, patient was anxious, sweating profusely and had pulse rate of 110/min, irregularly irregular, blood pressure of 80/50 mm of mercury, and respiratory rate of 26/min. Cardiovascular examination was normal, except for frequent ectopics and ventricular tachycardia. Neurological examination showed a conscious, coherent but anxious patient with residual left hemiparesis. Other systems were normal.

Electrocardiogram (ECG) obtained showed multifocal ventricular ectopics with bizarre complexes. Complete blood count, renal functions, and liver profile were normal. Serum electrolytes (sodium: 136 mEq/l, potassium: 3.8 mEq/l and magnesium: 1.8 mEq/l) and cardiac enzymes (creatinine phospho kinase-MB and troponin I) were normal. Patient

* Corresponding author.

E-mail address: drstak@yahoo.com (S. Tak).

<http://dx.doi.org/10.1016/j.ihj.2015.08.010>

0019-4832/© 2015 Cardiological Society of India. Published by Elsevier B.V. This is an open access article under the CC BY-NC-ND license (<http://creativecommons.org/licenses/by-nc-nd/4.0/>).

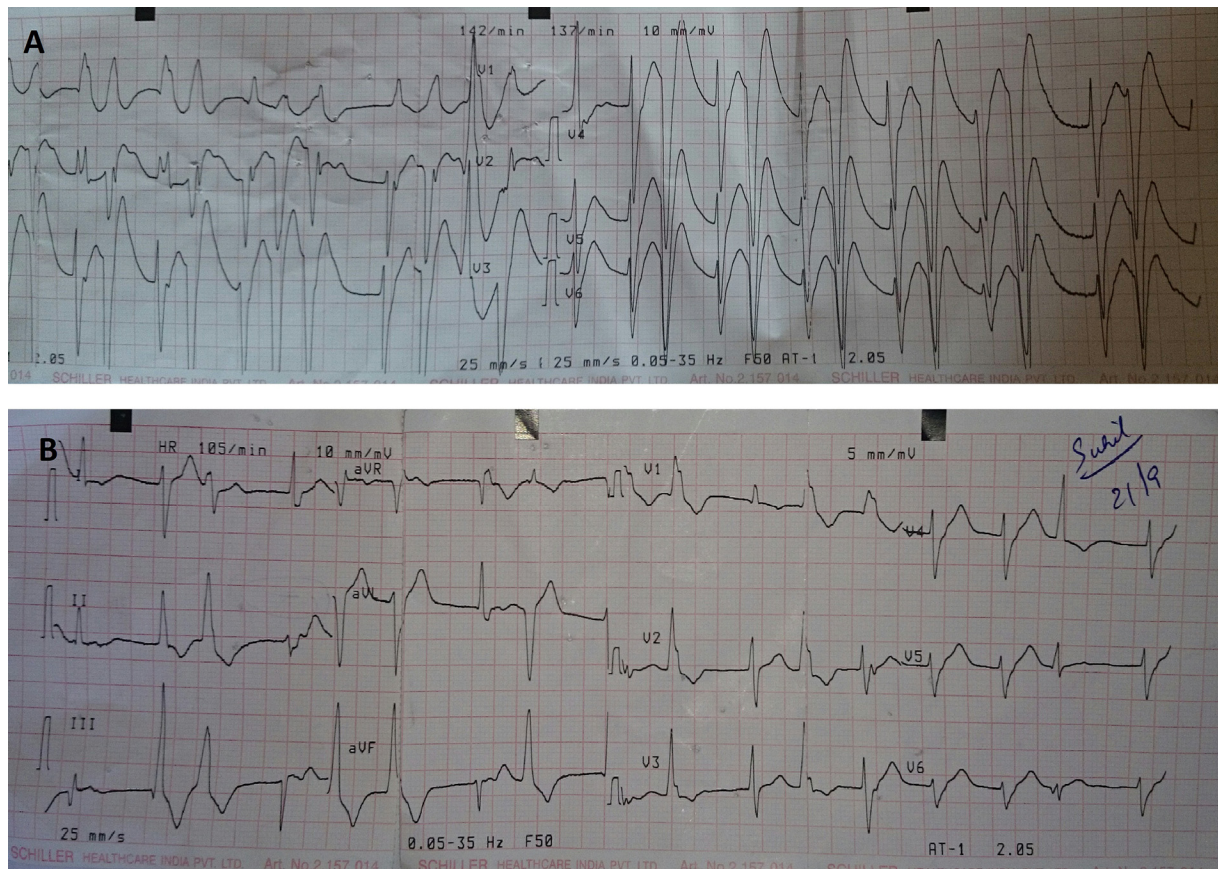


Fig. 1 – (A) ECG at the presentation. (B) ECG after 24 h.

was advised coronary angiography but he refused. Arterial blood gases (ABG) parameters were normal.

Immediate gastric lavage was done and activated charcoal given. Patient was treated with fluid resuscitation to maintain central venous pressure of 14 cm of H₂O but there was no improvement in blood pressure. Patient was started on nor-adrenaline infusion. Blood pressure improved gradually over a period of 6 h but patient required inotropic support for next 48 h. As there was persistent multifocal ventricular activity, patient was also started on amiodarone infusion. Ventricular excitability persisted over 72 h with gradual decrease in frequency of ectopics. Patient was discharged in normal sinus rhythm on oral amiodarone on 5th day of hospitalization. On follow-up after 2 weeks patient was totally asymptomatic and amiodarone was stopped.

2. Discussion

Aconitum also known as aconite, monkshood, women's bane, devil's helmet, Queen of all Poisons, or blue rocket is a genus of over 250 species of flowering plants belonging to the family Ranunculaceae^{1,2}. In India, it is also called as Bachhnaag, Meetha Vish, Vatsanagaka, Vatsanabha or Visa vajranaga. Different species of Aconitum have been used for centuries both as poisons and medicines. It is still being used in traditional medicines of India, China, and Japan. The toxicity

of the extracts follows the same order as the alkaloid content: roots, flowers, leaves, and stems.²

Aconite is a fast-acting toxin. The active principles are aconitine and related alkaloids. Pure aconite 2 mg or aconite plant 1 g may cause death.³ Aconitine's toxicity is characterized by a burning sensation of the lips, tongue, mouth, and throat almost immediately following ingestion; it may be followed by numbness of the oral cavity and throat and difficulty in speech. Salivation, nausea, vomiting, dizziness, syncope, palpitation, and diarrhea may occur. There may be visual blurring or yellow-green color vision distortion, weakness, and incoordination. Toxicity mainly affects cardiovascular system and neuromuscular system. Refractory ventricular arrhythmias and refractory hypotension may lead to death.¹⁻⁴

The cardiotoxicity and neurotoxicity of aconitine and related alkaloids are due to their actions on the voltage-sensitive sodium channels of the cell membranes of excitable tissues, including the myocardium, nerves, and muscles. Aconitine binds with the voltage-sensitive sodium channels thereby causing a persistent activation of the sodium channels, which become refractory to excitation. Arrhythmia is triggered due to delayed after-depolarization and early after-depolarization. The arrhythmogenic properties of aconitine are also in part due to its anticholinergic effects mediated by the vagus nerve. It has hypotensive and bradycardic actions due to activation of the ventromedial nucleus of the hypothalamus. Through its action on voltage-sensitive sodium channels in the axons, aconitine

blocks neuromuscular transmission by decreasing the evoked quantal release of acetylcholine.⁴

Accidental toxicity and death have resulted when the plant has been consumed accidentally, possibly mistaken for wild parsley, horseradish, or other herbs growing in the wild.^{5,6} Few reports of toxicity from western countries have been related to the use of traditional Chinese remedies sometimes with fatal outcome.^{7,8} Most incidents of aconite toxicity have been reported from Asian countries with few case reports from India.^{2-4,6,9-11}

Cardiac arrhythmias arising from aconite poisoning has been successfully treated with amiodarone¹¹ and in resistant cases with charcoal hemoperfusion.¹² Hypotension resistant to inotropes like dopamine and nor-adrenaline has been successfully treated with ventricular-assist device.¹³

A case series published by Dwivedi et al. with twelve patients highlights that cardiotoxic effects of "safe" herbs/minerals preparation are not uncommon.¹⁴ Other cardiotoxic herbs include well-known herbs like Digitalis, Areca catechu, and Belladonna and lesser known herbs like Thevetia peruviana, Cleistanus collinus, Mandragora officinarum, Ephedra distachya, and licorice.

Conflicts of interest

The authors have none to declare.

REFERENCES

- Lampe KF, McCann MA. *AMA Handbook of Poisonous and Injurious Plants*. Chicago, IL: American Medical Association; 1985.
- Lin CC, Chan TY, Deng JF. Clinical features and management of herb-induced aconitine poisoning. *Ann Emerg Med*. 2004;43:574-579.
- Singh S, Fradnis P, Sharma BK. Aconite poisoning. *J Assoc Physicians India*. 1986;34:825-826.
- Chan TY. Aconite poisoning. *Clin Toxicol (Phila)*. 2009;47:279-285.
- Pullela R, Young L, Gallagher B, Avis SP, Randell EW. A case of fatal aconitine poisoning by monkshood ingestion. *J Forensic Sci*. 2008;53:491-494.
- Tai YT, But PP, Young K, Lau CP. Cardiotoxicity after accidental herb-induced aconite poisoning. *Lancet*. 1992;340:1254-1256.
- Smith SW, Shah RR, Hunt JL, Herzog CA. Bidirectional ventricular tachycardia resulting from herbal aconite poisoning. *Ann Emerg Med*. 2005;45:100-101.
- Imazio M, Belli R, Pomari F, et al. Malignant ventricular arrhythmias due to Aconitum napellus seeds. *Circulation*. 2000;102:2907-2908.
- Guha S, Dawn B, Dutta G, Chakraborty T, Pain S. Bradycardia, reversible panconduction defect and syncope following self-medication with a homeopathic medicine. *Cardiology*. 1999;91:268-271.
- Gupta BS, Saigal R, Vottery R, Singhal N, Banerjee S. Sustained ventricular tachycardia in a case of aconite poisoning. *J Assoc Physicians India*. 1999;47:455.
- Yeih DF, Chiang FT, Huang SK. Successful treatment of aconitine induced life threatening ventricular tachyarrhythmia with amiodarone. *Heart*. 2000;84:E8.
- Lin CC, Chou HL, Lin JL. Acute aconitine poisoned patients with ventricular arrhythmias successfully reversed by charcoal hemoperfusion. *Am J Emerg Med*. 2002;20:66-67.
- Fitzpatrick AJ, Crawford M, Allan RM, Wolfenden H. Aconite poisoning managed with a ventricular assist device. *Anaesth Intensive Care*. 1994;22:714-717.
- Dwivedi S, Aggarwal A, Sharma V. Cardiotoxicity from 'safe' herbomineral formulations. *Trop Doct*. 2011;41:113-115.