



Since January 2020 Elsevier has created a COVID-19 resource centre with free information in English and Mandarin on the novel coronavirus COVID-19. The COVID-19 resource centre is hosted on Elsevier Connect, the company's public news and information website.

Elsevier hereby grants permission to make all its COVID-19-related research that is available on the COVID-19 resource centre - including this research content - immediately available in PubMed Central and other publicly funded repositories, such as the WHO COVID database with rights for unrestricted research re-use and analyses in any form or by any means with acknowledgement of the original source. These permissions are granted for free by Elsevier for as long as the COVID-19 resource centre remains active.



# Sequential Complications of Hypercalcemia, Necrotizing Granulomatous Vasculitis, and Aplastic Anemia Occurring in One Patient with Angioimmunoblastic T-cell Lymphoma



Sriman Swarup,<sup>1</sup> Jonathan Kopel,<sup>1</sup> Kyaw Zin Thein,<sup>1</sup> Kaiser Tarafdar,<sup>2</sup> Khatrina Swarup,<sup>3</sup> Seshadri Thirumala,<sup>4</sup> and Donald P. Quick<sup>1,2</sup>

<sup>1</sup>Texas Tech University Health Sciences Center, Lubbock, Texas USA; <sup>2</sup>Internal Medicine and Hematology-Oncology, Covenant Health System, Lubbock, Texas USA; <sup>3</sup>University Medical Center, Lubbock, Texas USA; <sup>4</sup>Department of Pathology, Covenant Health System, Lubbock, Texas USA

## ABSTRACT

In this case report of a patient with angioimmunoblastic T-cell lymphoma (AITL), we describe the occurrence of three sequential complications that have been reported uncommonly in this disease subtype. Firstly, the patient developed hypercalcemia due to elevated 1,25-dihydroxyvitamin D. Although hypercalcemia in AITL is not rare (1-2% incidence), this case was unusual in that the complication developed when disease appeared stable and symptomatically, he was doing well otherwise. Hypercalcemia surprisingly resolved a few months later at a time when his disease appeared to be progressing. A year later, the patient presented with digital ischemia necessitating partial amputation of a finger. Pathological exam revealed granulomatous vasculitis of small and medium arterioles with infiltrating malignant T lymphocytes. Although skin manifestations are common in AITL, necrotizing granulomatous vasculitis with accompanying tumor cells leading to severe digital ischemia appears rare. Subsequently the patient developed profound pancytopenia with bone marrow confirming severe aplastic anemia. To our knowledge only one other case of aplastic anemia has been reported in a patient with AITL. We discuss the diagnostic and management considerations involved in this patient care and review similar reported cases.

**Key Indexing Terms:** Angioimmunoblastic T-Cell Lymphoma (AITL); Hypercalcemia; 1,25-dihydroxyvitamin D; Granulomatous vasculitis; Digital ischemia; Aplastic anemia. [*Am J Med Sci* 2021;361(3):375–382.]

## INTRODUCTION

Angioimmunoblastic T-cell lymphoma (AITL) accounts for approximately 15-20% of all peripheral T-cell lymphomas (PTL) and 1-2% of all non-Hodgkin's lymphomas.<sup>1</sup> Most patients present with advanced stage and systemic symptoms yet non-bulky adenopathy. No treatment standard has been clearly established and prognosis is relatively poor.<sup>2,3</sup> Additionally, patients with AITL may present with a variety of clinical and laboratory characteristics less frequently encountered in other lymphoma subtypes. Included, for example, are immunological disturbances involving the formation of autoantibodies and immune complexes.<sup>2-6</sup> Consequently, patients with AITL have been the subject of a relatively large number of publications detailing a variety of unusual clinical presentations of this disease. At the same time, complications such as hypercalcemia and aplastic anemia (AA) have been reported more frequently in other lymphoma subtypes and are distinctly rare in AITL. In this report, we describe the sequential development of three uncommon complications of the

disease occurring in a single patient with AITL, underscoring the challenges in managing this disease.

## CASE PRESENTATION

A 58-year-old Caucasian male was admitted with weakness, intermittent fever, and new onset profound anemia (hemoglobin of 4.2 gm/dl). He denied any bleeding and had no prior history of significant medical illnesses, recent surgery, or trauma.

Physical examination revealed widespread non-bulky lymphadenopathy. Computed tomography (CT) scans revealed widespread lymphadenopathy in the neck, mediastinum, retroperitoneum, pelvis, and inguinal regions with the largest lymph node 2.2 cm in size. The spleen was enlarged measuring 15 cm with no focal lesions.

Laboratory studies revealed white blood cell count (WBC) 5,600/uL with absolute neutrophil 2,400/uL and small number of myelocytes as well as atypical lymphocytes. Platelet count was 192,000/uL. Direct antiglobulin

test (DAT) was positive for both IgG (3+) and complement (1+). Haptoglobin was low (<31 mg/dL). Reticulocyte count however was low (<0.4%). Erythrocyte sedimentation rate (ESR) was 120 mm/hr. SPEP showed polyclonal gammopathy with no paraprotein by immunofixation. Antinuclear antibody (ANA) and rheumatoid factor (RF) were negative. Serological testing for Hepatitis A, B, C and HIV 1 and 2 antigen and antibodies were negative.

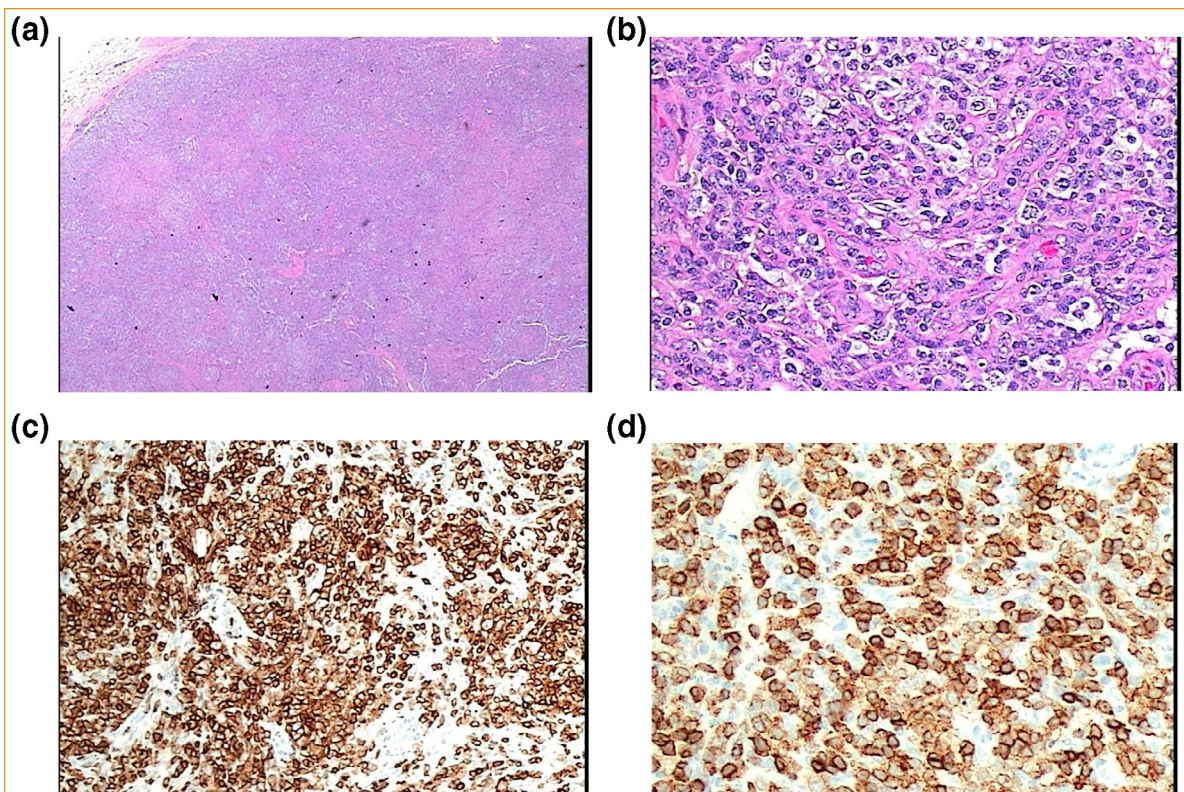
Lymph node biopsy is shown in [Figure 1](#). The architecture was completely effaced by a diffuse lymphoid infiltrate with atrophic/depleted follicles and marked vascular and dendritic cell proliferation. There were clusters of atypical cells with medium-sized nuclei, dispersed chromatin, and abundant clear cytoplasm in a background of reactive lymphocytes, histiocytes, occasional scattered plasma cells, and eosinophils. The neoplastic cells were positive for CD3, CD4, CD5, CD10, CD30 (partial), CD45, bcl6, CXCL13, ICOS, PD-1 (CD279) and vimentin. The cells were negative for CD8, CD15, CD20, MCK, S100. ([Figure 1A-D](#))

Initial bone marrow exam revealed hypercellularity (70-80%) with malignant polymorphous infiltrate occupying 20% of the biopsy. Granulocytic and megakaryocytic hyperplasia was present with relative erythroid hypoplasia (3% on 500-cell count) and moderate to severe reticulin fibrosis. Atypical lymphoid aggregates were positive for CD3 and CD5, negative for ALK, CD20, and focally positive in aggregates for CD30. T-cell receptor gene

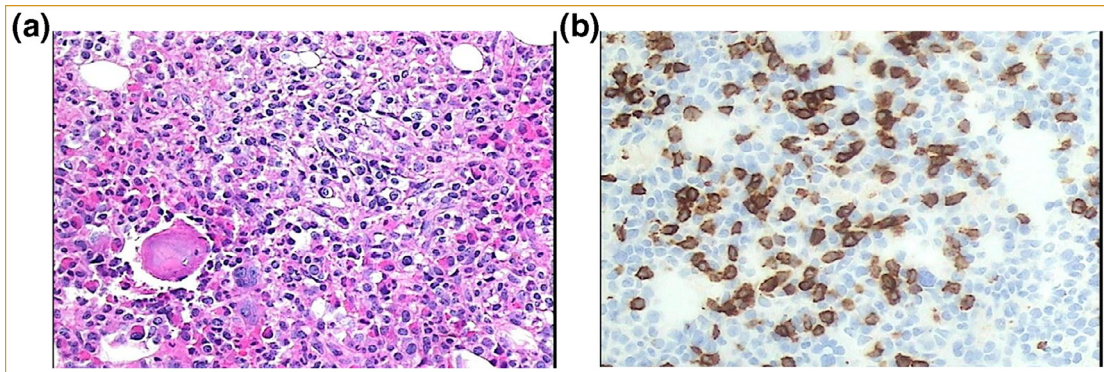
rearrangement was positive for TCR gamma, negative for TCR beta. Flow cytometry did not detect the aberrant T-cell process nor a clonal B-cell population. Cytogenetics were normal (46, XY). ([Figure 2A, B](#))

Diagnosis of Stage IV AITL was established. The patient was treated initially with prednisone 1mg/kg/day which resulted in marked improvement in constitutional symptoms and stabilization of his hemoglobin in the 7,8 gm/dL range. He was discharged from the hospital and outpatient treatment was subsequently initiated utilizing CHOP-Etoposide every three weeks. However, the patient was only able to complete two cycles of chemotherapy due to poor tolerance with recurring culture negative fevers, profound weakness, anorexia, and weight loss. Furthermore, response appeared suboptimal with minimal reduction of adenopathy. At that point it was elected to discontinue chemotherapy and restart prednisone 1 mg/kg/day while considering other treatment options. Once again steroids resulted in good palliation of symptoms with improvement in anemia (hemoglobin levels >12 gm/dL) and stabilization of lymphadenopathy. The prednisone dose was tapered periodically over weeks to 20 mg/day.

Four months after initial presentation he was noted to have new onset of elevated serum calcium level of 13.4 mg/dL (albumin 3.4 gm/dL) although symptomatically he had only mild fatigue. Creatinine level increase to 1.41 mg/dL compared to 0.86 mg/dL from the preceding



**FIGURE 1.** A) Lymph node (LN) biopsy (H&E x100). B) LN biopsy (H&E x400). C) LN biopsy (CD3). D) LN biopsy (CD4).



**FIGURE 2.** A) Bone marrow at diagnosis (H&E X400). B) Bone marrow at diagnosis (CD3).

month when calcium level was normal. Careful review of the patient's intake uncovered no consumption of excessive calcium or exogenous vitamin D foods or supplements. Additional testing revealed reduced parathyroid hormone (PTH) of 3.6 pg/ml (reference range 18.5–88 pg/ml) and parathyroid related protein (PTHrP) 24 pg/ml (reference range 14–27 pg/ml). The 25-hydroxyvitamin D3 (25[OH]D3, or calcidiol) level was low at 22.8 ng/mL (reference range 30.0–100.0 ng/mL). The level of 1,25-dihydroxyvitamin D3 (1,25[OH]<sub>2</sub>D3, or calcitriol) was significantly elevated at 136 pg/ml (reference range 18–72 pg/ml), with 1,25-dihydroxyvitamin D2 (1,25[OH]<sub>2</sub>D2 < 8 pg/ml. Serum IF/SPEP revealed no monoclonal gammopathy. CT scan of chest/abdomen/pelvis showed stable disease as compared to the November 2018 (post-chemotherapy) scan and with no osseous involvement.

Initially the patient was treated with therapeutic doses of calcitonin and zoledronic acid. Prednisone was continued at moderate doses (mean dose 0.5 mg/kg/day) as the patient remained minimally symptomatic. Calcium levels were reasonably controlled with this approach. Surprisingly, over the next four months we saw not only a reduction in medium calcium levels to <11 mg/dL but also a decline in the Vit D, 1,25 (OH)<sub>2</sub> level to 70 pg/ml (reference range 18–72 pg/ml). At that point, calcitonin and zoledronic acid were discontinued and only low dose prednisone continued.

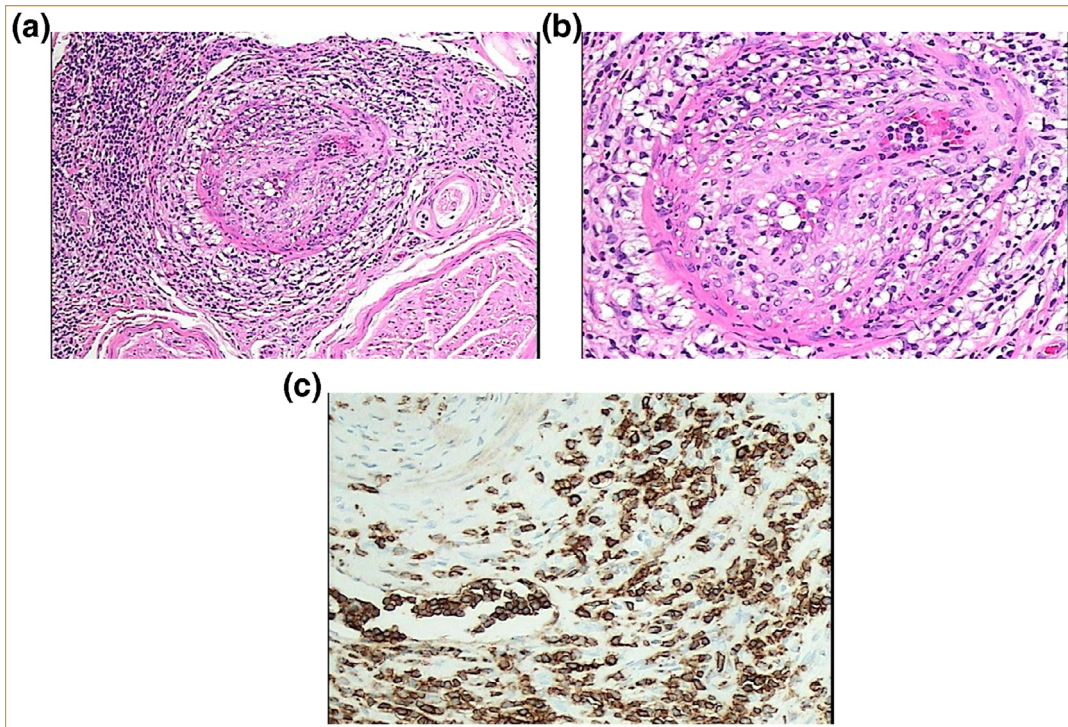
He did well for a few months after resolution of hypercalcemia until onset of increasing fatigue and modest increase in lymphadenopathy confirmed by scans. Various treatment approaches were considered including palliative targeted therapy including brentuximab, romidepsin, and belinostat. He opted then to proceed with salvage chemotherapy in preparation of high-dose chemotherapy followed by hematopoietic stem cell transplant. He was treated with GDP (gemcitabine 1,000 mg/m<sup>2</sup> Day 1 and 8, dexamethasone 40 mg po Day 1, cisplatin 75 mg/m<sup>2</sup> Day 1) with intent to treat him every 3 weeks while awaiting stem cell collection. Treatment was tolerated well and resulted in an approximate 50% reduction in measurable lymphadenopathy. Loss of insurance at that point delayed treatment and then the

patient elected to further delay re-institution of therapy as he was symptomatically feeling good.

Four months from the time of last chemotherapy he presented with discoloration (initially redness) of the right index finger. There had been no precipitating trauma. Pain was at first minimal and there was no associated fever. No improvement occurred with outpatient oral or parenteral antibiotics, with progression to frank ischemia of the finger and new involvement of additional upper and lower digits. Therefore, he was admitted. He remained afebrile and vital signs were normal. He did not look acutely ill. Admission complete blood count (CBC) showed WBC of 8,800/uL with absolute neutrophil count (ANC) of 5,400/uL, hemoglobin (Hgb) 10.6 gm/dL, and platelet count 204,000/uL. Disseminated intravascular coagulation (DIC) screen was negative and there had been no exposure to heparins prior to onset of ischemia (platelet factor IV antibody screen was nevertheless performed, and negative). Blood and urine cultures were negative for significant pathogens. Wound cultures, gram stains, and fungal stains from the ischemic finger revealed no organisms. Transthoracic and transesophageal echocardiograms were both unrevealing. He was treated empirically with vancomycin.

The ischemic changes in the finger progressed within a few days of admission to irreversible necrosis necessitating amputation of the distal portion of the right index finger. Pathology revealed ischemic necrosis of skin and soft tissue without evidence for osteomyelitis or organisms (Figure 3A-C). There was an associated atypical cellular infiltrate, compatible with involvement by AITL of the small and medium-sized vessels, with recent and organizing thrombosis and focal granulomatous vasculitis. The infiltrating lymphocytes were predominantly CD5 positive, equivocal for CD3, and negative for CD20. This granulomatous vasculitis process appeared to be limited to involvement of blood vessels of the digits, with no apparent involvement of sites commonly involved in other vasculitides (renal, pulmonary, CNS).

ANA profile (antibodies to Sm (Smith), RNP, Scl-70, JO-1, SS-B, dsDNA, ribosomal P protein, chromatin, anti-centromeric antibodies) was negative except for modest increase in SS-A/Ro antibody. Rheumatoid



**FIGURE 3.** A) Finger amputation; necrotizing vasculitis (H&E x200). B) Finger amputation; necrotizing vasculitis (H&E x400). C) Finger amputation; atypical lymphocytes (CD5 × 200).

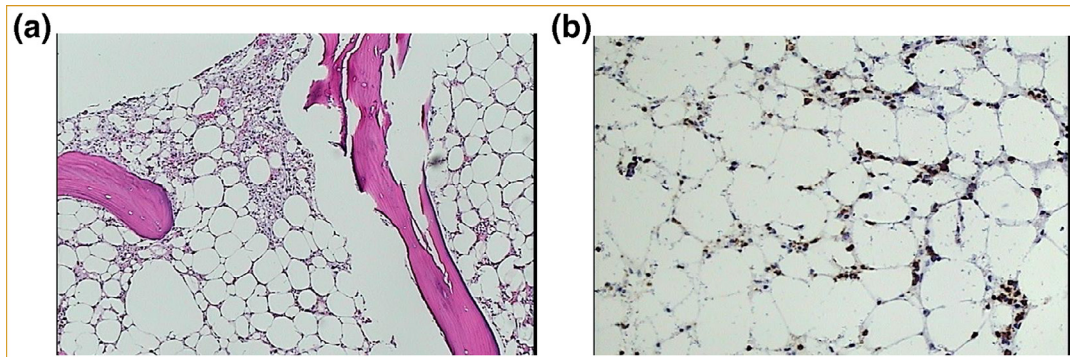
factor (<10 IU/mL), anti-neutrophil antibodies (c-ANCA, p-ANCA, atypical ANCA), cryoglobulins, and cold agglutinins were not detected. Urine analysis and sediment revealed no RBCs or casts. DIC screen, platelet factor IV antibody screen, and antiphospholipid antibody/lupus anticoagulant profile were negative. The patient was treated with moderate dose methylprednisolone followed by prednisone and aspirin 325 mg daily added. No further ischemic events occurred, and he was eventually discharged home. Discharge CBC showed normal neutrophil count, borderline thrombocytopenia, and hemoglobin >9 gm/dL.

Approximately six weeks following the digit amputation, the patient presented to the outpatient clinic for scheduled follow up with progressive pancytopenia (WBC <700/uL, ANC <100/uL, and platelet count <10,000/uL, hemoglobin 7.8 gm/dL, corrected reticulocyte count <0.4%). Bone marrow exam showed hypocellularity (10–15%) with no evidence of infiltrating lymphoma by morphology. Immunohistochemical stains revealed isolated clusters of CD3+ and CD5+, but no CD20+ or CD30+ lymphocytes were identified. CD4+ T-cells showed reduced co-expression of CD7 in 50% of cells by flow cytometry, and no expansion of CD8+ T-cells. No cytogenetic abnormalities were noted. T-cell gene rearrangement by polymerase chain reaction was positive for both T-cell receptor beta and gamma chains. No bacterial, fungal, or mycobacterial organisms were identified by stain in the bone marrow. (Figure 4A, B)

Interestingly, the direct antiglobulin test was now negative and haptoglobin was within normal range. He no longer exhibited pan-hypergammaglobulinemia and was now pan-hypogammaglobulinemia. Anti-neutrophil antibody was not detected. Respiratory viral panel by PCR (influenza A [H1, H1N1, H3], influenza B, coronavirus [OC43, HKU1, 229E, NL63], human metapneumovir, parainfluenza [1, 2, 3, 4], RSV, enterovirus/rhinovirus), Hepatitis A, B, C screen, CMV DNA by PCR, HIV 1 and 2 antigen and antibodies, and mycobacterial stains and cultures were negative. Human T-cell leukemia virus (HTLV) 1 and 2 were considered but not tested, given the patient had no clinical symptoms of HTLV associated myelopathy. Furthermore, HTLV is not endemic to the West Texas region.

CT scan of chest and abdomen surprisingly showed no progressive adenopathy compared to his scans at time of the digital ischemia.

The etiology of the severe AA was not clear. A careful review of medication exposure revealed no probable responsible agent. Management options were discussed with the patient including immunosuppressive therapy with cyclosporine, especially considering reported responses of CSA in relapsed and refractory AITL. He opted initially for supportive care and was managed as an outpatient, receiving blood product support and prophylactic anti-microbials. Two months later we repeated a bone marrow at his request for reassessing his options. This study again reconfirmed very severe AA with



**FIGURE 4.** A) Bone marrow showing hypoplasia with lymphoid aggregate (AITL) (H&E x100). B) Bone marrow showing hypoplasia with scattered atypical lymphocytes (CD5  $\times$  200).

progressive hypo-cellularity (<10%). 500-cell differential revealed 94% lymphocytes, 2 % monocytes, 1% erythroid precursors, 1% eosinophils/precursors, and 2 % myeloid lineage (1% bands, 1% segmented neutrophils). Stromal degenerative changes were now identified. This specimen did reveal positive an 11.6% population of atypical T lymphocytes co-expressing CD2, CD3, and CD4, without co-expression evidence of CD7 by flow. FISH for MDS/myeloid disorders revealed no abnormalities and cytogenetics could not be done due to lack of metaphases. Sequence analysis for specific gene mutations were not performed.

Shortly after his second bone marrow, however, he developed fever with unspecified sepsis resulting in an extended stay at an outside facility. His performance declined steadily after that point and he eventually died at home on hospice care approximately five months after onset of AA and eighteen months after diagnosis of AITL.

## DISCUSSION

Angioimmunoblastic T-cell lymphoma is a peripheral T-cell lymphoma with distinctive clinical as well as pathological features. The median age at diagnosis is mid-60's with a male predilection.<sup>3</sup> Over 80% of cases present in advanced stage and over half with bone marrow involvement and B symptoms. Elevated lactate dehydrogenase (LDH), anemia, and hypergammaglobulinemia are present at some point in most patients.<sup>4,5</sup> The prognosis of AITL is relatively poor with a reported 5-year median survival rate of 32%.<sup>7</sup> A clear standard of treatment has still not been uniformly established, and most patients will experience short durations of remissions and incomplete responses.

The precise pathogenesis of AITL remains speculative, although the cell of origin of AITL has been shown to be the follicular T helper ( $T_{FH}$ ) cell.<sup>8</sup> Deregulated T cell receptor signaling via gene mutations appears key to the pathogenesis of  $T_{FH}$  derived neoplasms.<sup>9</sup> As the  $T_{FH}$  plays a key role in regulating B-cell activation, the subsequent loss of the normal B cell regulatory function of  $T_{FH}$  following malignant transformation, along with perhaps

other additional pathogenic changes such as the development of Epstein-Barr viral (EBV) induced B cell immunoblasts, are likely contributing factors to the relatively large number of patients with AITL presenting with autoimmune related disease features.<sup>10</sup> In the present case, EBV was noted in some CD20 positive B-lymphocytes of the lymph nodes and bone marrow.

In large patient series, commonly reported immune related features have included hypergammaglobulinemia (usually polyclonal), warm autoantibody hemolytic anemia, and elevated non-specific inflammatory markers (erythrocyte sedimentation rate, C-reactive protein).<sup>2,4-6</sup> Immune thrombocytopenia, cold agglutinins, polyarthritis, polychondritis, glomerulonephritis, circulating immune complexes, and autoimmune antibody positivity (rheumatoid factor, smooth muscle, anti-nuclear) are reported less frequently.

It was evident when reviewing the complications noted in our patient that the incidence of hypercalcemia (defined by a corrected serum calcium level of greater than 10.5 mg/dL) in AITL appears to be less common than in other lymphoma subtypes. Hypercalcemia was not listed as a complication in most large series or reviews that examined clinical and laboratory features in AITL.<sup>3-6,11</sup> Only 3 of 184 patients with AITL characterized by the International Peripheral T-Cell Lymphoma Project developed hypercalcemia.<sup>2</sup> Furthermore, individual case reports of hypercalcemia complicating AITL are few. Consequently, there is a paucity of information regarding the mechanism and management of hypercalcemia in AITL. Traditionally, most cases of hypercalcemia in non-Hodgkin's lymphomas had been attributed to elevated serum levels of either PTHrP or 1,25-dihydroxyvitamin D3. Elevated 1,25-dihydroxyvitamin D3 is most often due to increased extrarenal production via autonomous 1- $\alpha$ -hydroxylase activity from tumor cells, tissue macrophages, or both.<sup>12,13</sup> Though the development of hypercalcemia in T cell malignancies is well postulated through dysregulation of RANKL with increased osteoclastic activity mediated by osteoclastic activating factors (i.e. macrophage inflammatory protein-1 $\alpha$  (MIP-1 $\alpha$ )), specifically in adult T cell leukemia.<sup>14,15</sup> The

pathophysiologic mechanism of hypercalcemia may be similar in cases of AITL. However, recent reports have indicated that in a significant number of non-Hodgkin lymphoma patients, the mechanism will remain unknown, or may be multifactorial.<sup>16,17</sup>

The few single case reports of hypercalcemia occurring in AITL illustrate that this complication tended to occur shortly after diagnosis of the disease yet contributed to poor outcome and shorten survival. Early cases published before identification of PTHrP and the availability of vitamin D metabolite assays suggested elevated intact PTH as the likely etiology.<sup>18-21</sup> Furthermore, in the case by Gan, hypercalcemia developed after transformation to "immunoblastic sarcoma." So, in this case, it is more likely that the development of hypercalcemia was due to secondary clonal B immunoblasts (typically EBV infected) transforming to diffuse large B cell lymphoma.<sup>18,22</sup> Chams reported a case of hypercalcemia at presentation of AITL. This was the only other case in our literature search that reported elevation of 1,25-dihydroxyvitamin D3 as the likely cause of elevated calcium level.<sup>22</sup>

In our case, we detected no secondary clonal B cell contributing to the onset of hypercalcemia. Exogenous calcium and vitamin D were not contributing factors. In contrast to the other case reports discussed, our patient developed hypercalcemia not as a pre-terminal event nor at presentation but rather a number of months following diagnosis and after initiation of chemotherapy. As his disease did not appear to be significantly progressing at that point, it is more likely that the increased production of 1,25-dihydroxyvitamin D3 at that point was due to associated macrophage conversion rather than tumor cell mediated conversion. Since progression of lymphoma cells per se did not appear to be directly driving the hypercalcemic process at that time, we elected to manage the hypercalcemia with calcium lowering agents (calcitonin and zoledronic acid) and steroids rather than immediate second line chemotherapy or targeted therapies.

Dermatological manifestation are not uncommon in patients with AITL and may present in a variety of patterns including maculopapular rash, plaques, generalized erythroderma, and purpura.<sup>4,23</sup> Lachenal reported that a cutaneous eruption was present at diagnosis in 35 of 77 patients.<sup>4</sup> Although most exhibited only a maculopapular morbilliform rash, 8 patients presented with histological evidence of vasculitis. A perivascular infiltrate of atypical lymphocytes was present in 3 patients. Martel examined skin biopsies from ten patients with AITL and skin lesions and found that even though clinical suspicion of direct lymphomatous involvement (suspicious plaque-like lesion) was present in only two patients, infiltrating malignant T-cells could be detected in seven patients by TCR gamma gene rearrangement, despite only two of those patients exhibiting circulating malignant T-cells in blood.<sup>24</sup>

Although cutaneous vasculitis is not unusual in AITL cases of severe skin necrosis appear to be very

uncommon, and vasculitis leading to frank digital ischemia, as occurred in our patient, distinctly rare. Mohan reported a case of a patient with newly diagnosed AITL presenting with discoloration of the digits and subsequent impending gangrene.<sup>25</sup> The patient was noted to have positive pANCA by ELISA. Biopsy of the skin lesions were not reported. The patient responded to pulse methylprednisolone. Cassuto described a patient with newly diagnosed AITL and painless necrosis of digits leading to amputation of one finger.<sup>26</sup> Pathology revealed IgG and C'3 deposits in the intima of dermal arterioles. There was no apparent tumor infiltration in the tissue. The patient again responded to steroid therapy.

In our case, the presentation of digital ischemia occurred one year after initial presentation at a time when the disease was progressing. Pathology revealed granulomatous vasculitis with associated tumor infiltration. Autoantibody screening was negative for ANCA and cryoglobulins, and no other organ appeared to be affected by vasculitis. As in those cases noted by Martel, infiltrating lymphocytes seemed to play a pivotal pathogenetic role in the development of the vascular lesions.<sup>23</sup> In prior cases involving clinically significant vasculitis of the skin, our patient seemed to respond to re-initiation of high dose corticosteroids. In our patient, the addition of aspirin may also have provided benefit as no further ischemic events were experienced.

AA occurred as a late complication in our patient. Cytopenia due to marrow infiltration and/or autoimmunity are not infrequent in AITL.<sup>2,4,5,27</sup> Myelosuppression can occur as a result of chemotherapy due to suppression of hematopoietic stem cells self-renewal,<sup>28</sup> however, such suppression is usually temporary. In this case report, patient underwent chemotherapy with CHOEP and GDP chemotherapy regimens. The patient tolerated chemotherapy well, with transient cytopenia likely due to chemotherapy-related myelosuppression, from which he recovered completely. The onset of bone marrow hypoplasia that occurred about 5-6 months after exposure to GDP is unlikely to be related to his previous chemotherapeutic treatment, and to our knowledge, has not been reported in the medical literature. However, cell specific hypoplasia, such as pure red cell aplasia, with or without autoimmune cytopenia (immune thrombocytopenia and autoimmune neutropenia not associated with marrow hypoplasia) are uncommon.<sup>27,29-33</sup> Furthermore, non-treatment associated idiopathic AA would appear to be distinctly rare not only in AITL, but in other lymphomas as well. The Severe Aplastic Anaemia Working Party of the European Society of Blood and Bone Marrow Transplantation (EBMT) examined cases from 83 transplant centers covering a period between 1983-2015 and found only 21 cases of AA in patients with a concomitant diagnosis of non-Hodgkin lymphoma.<sup>34</sup> Of these 21 cases, 19 were in patients with B cell malignancies, and two were reported as unspecified lymphoma. No cases of AA and AITL were noted. In addition, we found only one case report of AA in a patient with AITL via MEDLINE

search.<sup>33</sup> In that case report, AA developed 20 months after achieving a complete remission utilizing interferon-alpha. The authors speculated that cytokine-induced deficiency in CD14+ monocytes and altered CD4+/CD8+ T-cell levels may have contributed to onset of AA. Post-mortem bone marrow showed evidence of erythrophagocytosis, so an associated viral infection could not be entirely ruled out.

Retrospectively, the possibility of HTLV-1 contributing to the complications encountered in this case was considered. Archived tissue was not amenable for testing. This patient was not located in an endemic region for HTLV-1. All blood products were screened for the virus. There was no manifestation specific of acute HTLV-1 infection (e.g., myelopathy/spastic paraparesis) and no histological or radiographic evidence for HTLV-1 associated malignancy (including the absence of lytic bone lesions). There have been some reports of ATLL variants mimicking AITL.<sup>35,36</sup> However, the histological evidence in this case is clearly supportive of AITL (CD4+ follicular helper T-cells expressing CD10, PD-1 (CD279), CXCL13, and bcl-6) rather than ATLL variant. Rare cases of HTLV-1 inhibition of erythropoiesis/red cell aplasia have been reported, but to our knowledge frank pan-hypoplasia have not been reported.<sup>37,38</sup>

In the present case there did not appear to be any associated cause to explain the onset of severe AA, including medications, nutritional factors, or infection. The degree of tumor infiltration was minimal. There was no evidence for myelodysplasia, non-T cell acquired clonal abnormalities, or hematopoietic phagocytosis. Furthermore, the more commonly reported viral causes of AA were not detected, although a less common virus could not be completely ruled out. As in the case by Schwarzmeier, reduced CD8+ T-cells were noted at the time of AA development, yet the significance of this observation is unclear.<sup>39</sup>

The management of this patient's AA ultimately was supportive, given his poor performance status and personal wishes. Following suboptimal response to CHOEP and GDP (given with intent of eventual high-dose chemotherapy and hematopoietic stem cell transplant), various palliative treatment options were considered including pralatrexate, belinostat, romidepsin, and brentuximab.<sup>3</sup> However, issues such as the patient's distance from the treatment center, cost issues, and quality of life preferences early in his treatment factored into his decisions not to pursue alternate therapies, while later in his course, performance status decline and sequential complications ultimately led to the decision of palliative care at end-of-life. Unfortunately, we can only speculate on whether he could have benefited from cyclosporine following the late development of idiopathic AA. Although no longer considered a preferred treatment modality in the setting of relapsed and refractory AITL, cyclosporine has been shown to induce meaningful responses.<sup>40–42</sup> These observations have included patients with significantly impaired hematopoiesis.

This case illustrates the frequent complexity and challenges in managing patients with AITL. The unique interactions of the malignant T-cell and associated non-malignant B immunoblasts produces a myriad of autoimmune and cellular complications not typically seen in other lymphoid malignancies. It also further underscores the need for better understanding of its pathophysiology and the development of more effective treatment strategies.

## AUTHOR CONTRIBUTION

S.S., J.K. and K.Z.T. contributed to the writing of the manuscript. K.T., K.S., and D.Q. helped review and edit the manuscript. S.T. provided the pathology slides and analysis used in the case report.

## ACKNOWLEDGEMENT

Donald S. Quick B.A. for his critical review of the manuscript.

## REFERENCES

1. **Project TN-HsLC.** A clinical evaluation of the international lymphoma study group classification of non-hodgkin's lymphoma. *Blood.* 1997;89(11):3909–3918.
2. **Federico M, Rudiger T, Bellei M, et al.** Clinicopathologic characteristics of angioimmunoblastic T-cell lymphoma: analysis of the international peripheral T-Cell lymphoma project. *J Clin Oncol.* 2013;31(2):240–246.
3. **Lunning MA, Vose JM.** Angioimmunoblastic T-cell lymphoma: the many-faceted lymphoma. *Blood.* 2017;129(9):1095–1102.
4. **Lachenal F, Berger F, Ghesquières H, et al.** Angioimmunoblastic T-Cell lymphoma. *Medicine (Baltimore).* 2007;86(5):282–292.
5. **Mourad N, Mounier N, Brière J, et al.** Clinical, biologic, and pathologic features in 157 patients with angioimmunoblastic T-cell lymphoma treated within the Groupe d'Etude des Lymphomes de l'Adulte (GELA) trials. *Blood.* 2008;111(9):4463–4470.
6. **Li Y, Yang C, Mao L, et al.** Clinical characteristics of angioimmunoblastic T-cell lymphoma in China and C-reactive protein as an independent prognostic factor. *Medicine (Baltimore).* 2017;96(39):e8091.
7. **Vose J, Armitage J, Weisenburger D.** International peripheral T-Cell and natural killer/T-Cell lymphoma study: pathology findings and clinical outcomes. *J Clin Oncol.* 2008;26(25):4124–4130.
8. **Dupuis J, Boye K, Martin N, et al.** Expression of CXCL13 by neoplastic cells in Angioimmunoblastic T-Cell Lymphoma (AITL). *Am J Surg Pathol.* 2006;30(4):490–494.
9. **Vinuesa CG, Tangye SG, Moser B, et al.** Follicular B helper T cells in antibody responses and autoimmunity. *Nat Rev Immunol.* 2005;5(11):853–865.
10. **Przanski W.** Lymphadenopathy associated with dysgammaglobulinemia. *Semin Hematol.* 1980;17(1):44–62.
11. **Hewison M, Kantorovich V, Liker HR, et al.** Vitamin D-mediated hypercalcemia in lymphoma: evidence for hormone production by tumor-adjacent macrophages. *J Bone Miner Res.* 2003;18(3):579–582.
12. **Goldner W.** Cancer-Related hypercalcemia. *J Oncol Practice.* 2016;12(5):426–432.
13. **Marengo A, Rosso C, Bugianesi E.** Liver cancer: connections with obesity, fatty liver, and cirrhosis. *Annu Rev Med.* 2015;67(1):103–117.
14. **Nosaka K, Miyamoto T, Sakai T, et al.** Mechanism of hypercalcemia in adult T-cell leukemia: overexpression of receptor activator of nuclear factor κB ligand on adult T-cell leukemia cells. *Blood.* 2002;99(2):634–640.
15. **Okada Y, Tsukada J, Nakano K, et al.** Macrophage inflammatory protein-1α induces hypercalcemia in adult T-Cell leukemia. *J Bone Miner Res.* 2004;19(7):1105–1111.



16. **Shallis RM, Rome RS, Reagan JL.** Mechanisms of hypercalcemia in non-hodgkin lymphoma and associated outcomes: a retrospective review. *Clin Lymphoma Myeloma Leukemia*. 2018;18(2):e123–e129.
17. **Sworn MJ, Buchanan R, McGill DA.** Angioimmunoblastic lymphadenopathy and hypercalcaemia. *J Clin Pathol*. 1979;32(10): 1072–1072.
18. **Sogaard PE, Molin J.** Nephrocalcinosis in Angioimmunoblastic Lymphadenopathy. *Acta Med Scand*. 2009;211(4):319–320.
19. **Flier JS, Underhill LH, Broadus AE, et al.** Humoral hypercalcemia of cancer. *N Engl J Med*. 1988;319(9):556–563.
20. **Gan E, Van der Weyden MB.** Hypercalcaemia and angioimmunoblastic lymphadenopathy. *BMJ*. 1981;282(6262): 437–437.
21. **Zettl A, Lee S-S, Rüdiger T, et al.** Epstein-barr virus–associated B-Cell lymphoproliferative disorders in angioimmunoblastic T-cell lymphoma and peripheral T-Cell lymphoma, unspecified. *Am J Clin Pathol*. 2002;117(3):368–379.
22. **Chams S, Hajj Hussein I, El Sayegh S, et al.** Hypercalcemia as a rare presentation of angioimmunoblastic T cell lymphoma: a case report. *J Med Case Rep*. 2018;12(1).
23. **Martel P.** Cutaneous involvement in patients with angioimmunoblastic lymphadenopathy with dysproteinemia<subtitle>a clinical, immunohistological, and molecular analysis</subtitle>. *Arch Dermatol*. 2000;136(7):881.
24. **Kumar S, Mahesh A, Mohan A, et al.** Cutaneous infarcts and antineutrophil cytoplasmic antibody-positive vasculitis in angioimmunoblastic T-cell lymphoma: A rare presentation. *Indian J Med Paediatric Oncol*. 2019;40(4):598.
25. **Cassuto J, Campagni J, Creisson G, et al.** Digital necrosis during angioimmunoblastic lymphadenopathy. Immunofluorescence study. *Nouv Presse Med*. 1978;7(44):4055–4056.
26. **Crickx E, Poullot E, Moulis G, et al.** Clinical spectrum, evolution, and management of autoimmune cytopenias associated with angioimmunoblastic T–cell lymphoma. *Eur J Haematol*. 2019;103(1):35–42.
27. **Alberti E, Aldovini D, Mazzon C, et al.** Angioimmunoblastic lymphadenopathy with dysproteinemia. Report of a case with pure red cell aplasia. *Haematologica*. 1982;67(6):919–925.
28. **Wang Y, Probin V, Zhou D.** Cancer therapy-induced residual bone marrow injury-Mechanisms of induction and implication for therapy. *Curr Cancer Ther Rev*. 2006;2(3):271–279.
29. **Lynch JW, Eifenbein GJ, Noyes WD, et al.** Pure red cell aplasia associated with angioimmunoblastic lymphadenopathy with dysproteinemia. *Am J Hematol*. 1994;46(2):72–78.
30. **Tsujimura H, Sakai C, Takagi T.** Pure red cell aplasia complicated by angioimmunoblastic T-cell lymphoma: Humoral factor plays a main role in the inhibition of erythropoiesis from CD34+ progenitor cells. *Am J Hematol*. 1999;62(4):259–260.
31. **Choi J-H, Oh Y-H, Park I-K.** A case of pure red cell aplasia associated with angioimmunoblastic T-cell lymphoma. *Cancer Res Treat*. 2010;42(2):115.
32. **Vitorino M, Nunes F, Costa M, et al.** Case report: pure red cell aplasia due to angioimmunoblastic T-Cell lymphoma. *Case Rep Oncol*. 2020;76–78.
33. **Rovó A, Kulasekararaj A, Medinger M, et al.** Association of aplastic anaemia and lymphoma: a report from the severe aplastic anaemia working party of the European society of blood and bone marrow transplantation. *Br J Haematol*. 2017;184(2):294–298.
34. **Schwarzmeier JD, Reinisch WW, Kürkciyan IE, et al.** Interferon- $\alpha$  induces complete remission in angioimmunoblastic lymphadenopathy (AILD): late development of aplastic anaemia with cytokine abnormalities. *Br J Haematol*. 1991;79(2):336–337.
35. **Huang CT, Lee YH, Chow KC, et al.** Adult T-cell leukaemia/lymphoma can mimic other lymphomas in a non-endemic area: dilemmas in diagnosis and treatment. *Intern Med J*. 2014;44(4):374–383.
36. **Chuang S-S, Ichinohasama R, Chu J-S, et al.** Differential diagnosis of angioimmunoblastic T-cell lymphoma with seropositivity for anti-HTLV antibody from adult T-cell leukemia/lymphoma. *Int J Hematol*. 2010;91(4):687–691.
37. **Levitt LJ, Reyes GR, Moonka DK, et al.** Human T cell leukemia virus-I-associated T-suppressor cell inhibition of erythropoiesis in a patient with pure red cell aplasia and chronic T gamma-lymphoproliferative disease. *J Clin Invest*. 1988;81(2):538–548.
38. **Burdach S, Levitt L, Wahn V, et al.** Lymphokin-vermittelte Suppression der Erythropoese durch normale T-Lymphozyten und bei Retrovirus-assoziiertes lymphoproliferativer Erkrankung. *Oncol Res Treatment*. 1989;12(3):116–119.
39. **Takemori N, Kodaira J, Toyoshima N, et al.** Successful treatment of immunoblastic lymphadenopathy-like T-cell lymphoma with cyclosporin A. *Leuk Lymphoma*. 1999;35(3-4):389–395.
40. **Advani R, Horwitz S, Zelenetz A, et al.** Angioimmunoblastic T cell lymphoma: treatment experience with cyclosporine. *Leuk Lymphoma*. 2007;48(3):521–525.
41. **Kobayashi T, Kuroda J, Uchiyama H, et al.** Successful treatment of chemotherapy-refractory angioimmunoblastic T cell lymphoma with cyclosporin A. *Acta Haematol*. 2012;127(1):10–15.
42. **Wang X, Zhang D, Wang L, et al.** Cyclosporine treatment of angioimmunoblastic T-cell lymphoma relapsed after an autologous hematopoietic stem cell transplant. *Exp Clin Transplant*. 2015;13(2):203–205.

Submitted March 30, 2020; accepted September 1, 2020.

Declaration of Interest: The author reports no conflict of interest

Corresponding author. Jonathan Kopel, Texas Tech University Health Sciences Center Oncology, 4202 16th Street, Apartment 601, Lubbock, Texas 79416, United States (E-mail: jonathan.kopel@ttuhsc.edu).