



# Bronchial Washing Cytology of Pulmonary Langerhans Cell Histiocytosis: A Case Report

Taeyoung Kim · Hyeong Ju Kwon · Minseob Eom · Sang Wook Kim · Min Hi Sin · Soon-Hee Jung

Department of Pathology, Yonsei University Wonju College of Medicine, Wonju, Korea

Pulmonary Langerhans cell histiocytosis (PLCH) is a rare histiocytic interstitial lung disease, characterized by abnormal infiltration of Langerhans cells (LCs) with lung parenchyma destruction. PLCH can occur at any age, but is reported mainly in adults (between 20 and 40 years), especially those with a history of cigarette smoking. The clinical presentation can vary from no symptoms to severe respiratory symptoms.<sup>1</sup> PLCH is regarded as a reactive lesion rather than a neoplastic process, even though the proliferation of LCs is found in the lesion.<sup>2</sup>

PLCH is normally diagnosed from resected lung specimens. Cytological diagnostic methods such as bronchial washing or bronchoalveolar lavage (BAL) are used as a less invasive technique through bronchoscopy.<sup>3</sup> Reports have indicated that BAL cytology can be helpful for diagnosing PLCH.<sup>4</sup> However, the diagnosis of PLCH by bronchial washing cytology has not yet been reported. Herein, we present a case of PLCH diagnosed through bronchial washing cytology.

## CASE REPORT

The 41-year-old male patient visited our hospital due to a cough that had persisted for 7 months. He had a history of 20 pack-year smoking and diabetes mellitus. Physical examination of the chest revealed fine crackle of both upper lung fields. There was no skin rash or palpable lymph node. The chest computed tomography (CT) showed multiple, irregularly-shaped cysts and

centrilobular nodules of variable sizes in both lungs (Fig. 1).

Bronchial washing cytology, BAL, and wedge resection of the lung were performed. The BAL slides revealed a fraction rate of 59.6% monocytes and 9.4% eosinophils with about 6.5% LCs. The bronchial washing slides showed scattered non-cohesive large cells with abundant, granular, and eosinophilic cytoplasm. These cells had grooved or convoluted nuclei with fine chromatin, delicate nuclear membranes, and prominent nucleoli. Immunohistochemical staining for CD1a was positive in these cells (Fig. 2).

The cut surface of the wedge-resected lung specimen revealed numerous cystic spaces with whitish gray stellate fibrous scars. Microscopic examination indicated multiple cystic spaces of variable sizes with diffuse alveolar wall thickening, cellular infiltration, and fibrosis. The infiltrated cells had eosinophilic cytoplasm and grooved or infolded nuclei. These cells were proven to be LCs based on immunohistochemical staining, showing strong positive reaction for CD1a and S-100 protein (Fig. 3).

Bronchial washing cytology was performed again during follow-up. Some cells with the features described above were detected on the bronchial washing cytology. Therefore, we used the same approach to determine that the PLCH was still present.

## DISCUSSION

When patients with ongoing PLCH present at a hospital, non- or less-invasive pulmonological approaches, such as chest CT, pulmonary function test, and fiberoptic bronchoscopy, are usually performed. The cytological specimens obtained from fiberoptic bronchoscopy are then sent to the pathology department, and these cytological specimens can be challenging for pathologists to diagnose. The cytological diagnosis of PLCH with bronchial washing can be difficult because it is a rare disease with unfamiliar

### Corresponding Author

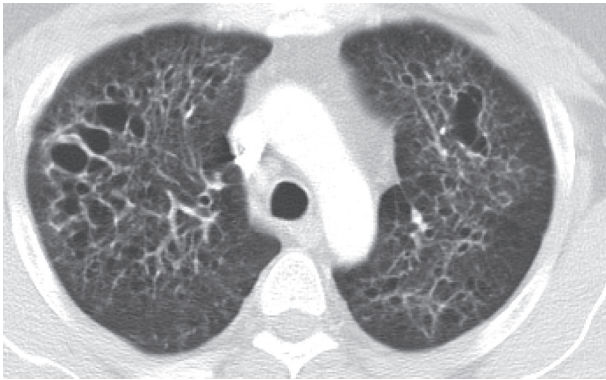
Soon-Hee Jung, MD, PhD  
Department of Pathology, Yonsei University Wonju College of Medicine, 20 Ilsan-ro, Wonju 26426, Korea  
Tel: +82-33-741-1551, Fax: +82-33-731-6590, E-mail: soonheej@yonsei.ac.kr

Received: September 2, 2016 Revised: February 3, 2017

Accepted: February 15, 2017

features. Therefore, in this report, we focused on bronchial washing cytology findings of PLCH.

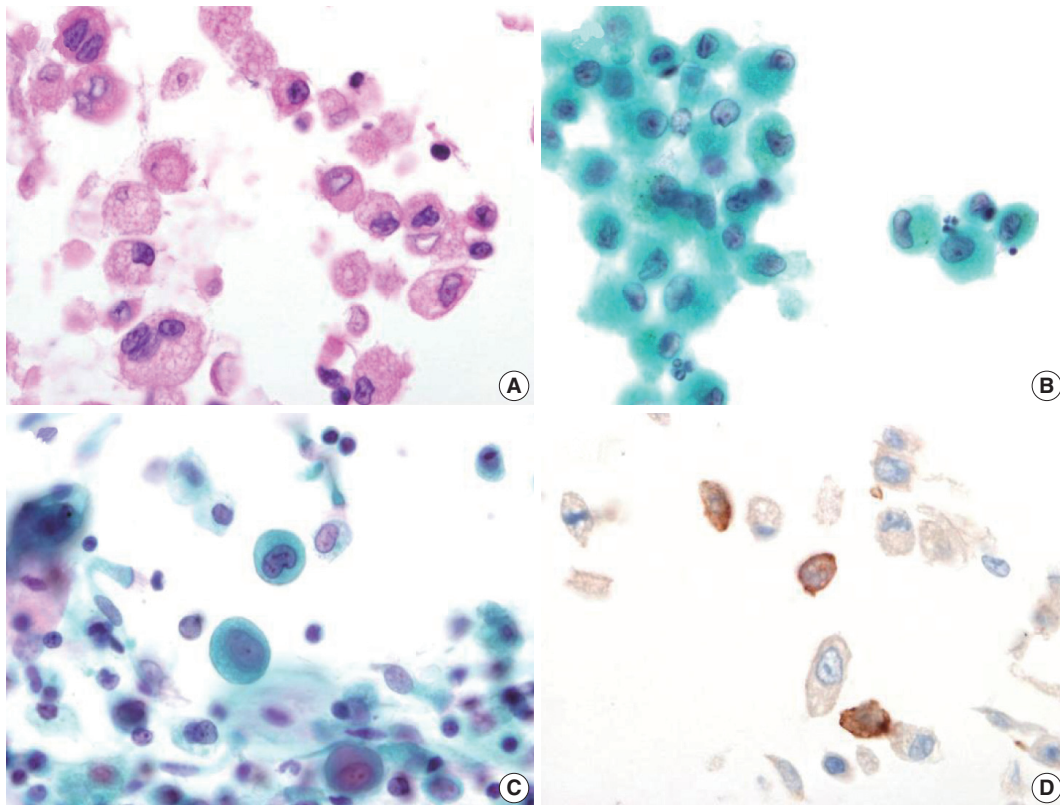
Some reports have presented cytological findings of Langerhans cell histiocytosis (LCH) that have arisen in various organs. Lee *et al.*<sup>5</sup> reported a case of LCH in the mandible diagnosed with fine needle aspiration cytology and indicated that the smear revealed



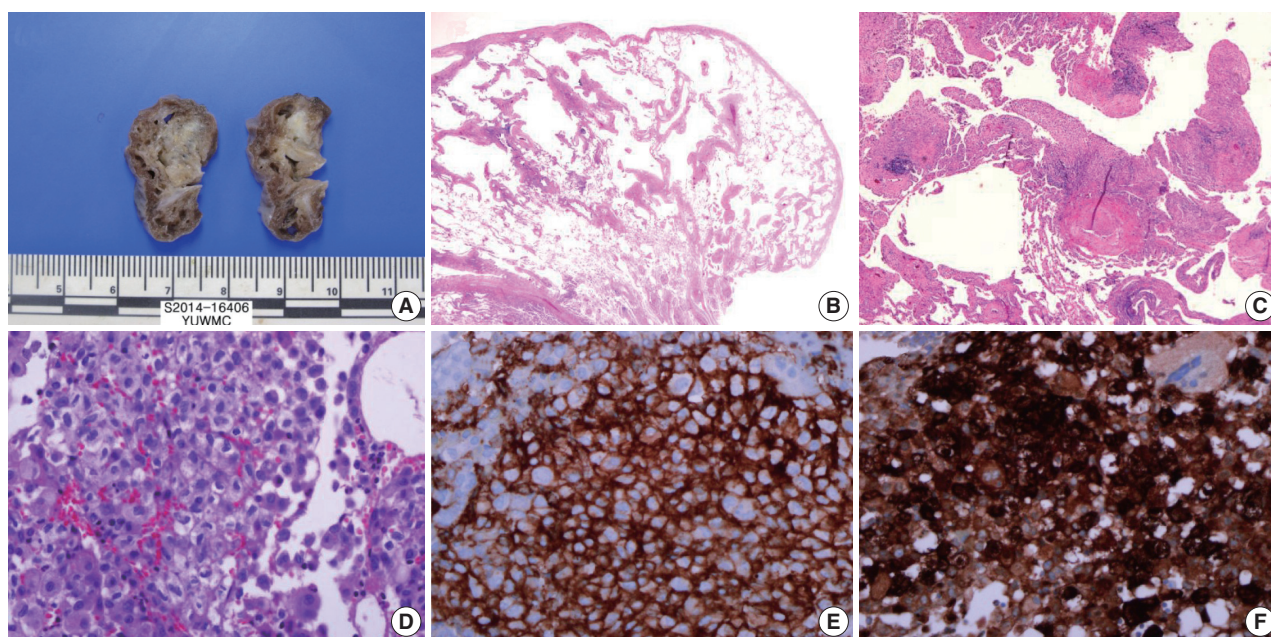
**Fig. 1.** Chest computed tomography findings. There are multiple, variable-sized, irregularly-shaped cysts and centrilobular nodules in both lungs.

high cellularity, and that the LCs had abundant vacuolated cytoplasm with round or occasionally folded nuclei. The LC nuclei showed a fine granular chromatin pattern with prominent nucleoli. Ha *et al.*<sup>6</sup> reported a case of LCH in lymph nodes using aspiration cytology similar to the case reported by Lee *et al.*<sup>5</sup> In their study, the LCs had wrinkled or grooved nuclei with thin nuclear membranes and a delicate chromatin pattern. Multinucleated cells were also identified. In another report that applied fine needle aspiration LCH cytology, many of the cytological findings were similar, but the nucleoli were absent.<sup>7</sup>

Another cytological method applied fiberoptic bronchoscopy for diagnosing PLCH is BAL fluid analysis. Takizawa *et al.*<sup>3</sup> conducted BAL fluid analysis in PLCH and found a high mean cell fraction rate for macrophages (75.2%) and a variable eosinophil fraction rate (1% to 16%). The LCs revealed chromatin-poor nuclei with well-developed nucleoli. Previously described cytological findings with quantitative analysis of PLCH in BAL fluid are summarized in Table 1. In two studies with CD1a-positive cells in PLCH, BAL fluid obtained from patients with PLCH revealed more than 5% CD1a-positive cells.<sup>8,9</sup> In the present case, BAL



**Fig. 2.** Bronchial washing cytology. Bronchial washing cytology reveals many Langerhans cells. (A–C) The cells have abundant pale granular cytoplasm with a convoluted irregular nucleus and fine chromatin pattern (A, cell block; B, Thin prep; C, conventional smear). (D) Immunohistochemical staining for CD1a is positive in the Langerhans cells.



**Fig. 3.** Wedge resected lung via video-assisted thoracoscopic surgery. (A) The cut surface of the wedge-resected lung shows multiple numerous cystic spaces with white gray stellate fibrous scars. (B, C) There are multiple cystic spaces with diffuse thickening, cellular infiltration, and fibrous tissue. (D) The infiltrated cells have pale eosinophilic cytoplasm with grooved or infolded nuclei. (E, F) Immunohistochemical staining for CD1a and S-100 protein is positive in the proliferating cells.

**Table 1.** Summary of previously reported cytological findings of pulmonary Langerhans cell histiocytosis in bronchoalveolar lavage fluid

Study	Cytological finding	Langerhans cells (%)
Takizawa et al. <sup>3</sup>	Clear and velvety cytoplasm	8.0 ± 1.3
	Oval or kidney-shaped, vesicular nuclei with irregular shapes	
	Nucleoli	
	Frequent groove and indentations	
Sharma and Dey <sup>4</sup>	Nuclear grooving	16.5 (CD1a-positive cells)
	Bi-nucleation	
	Multinucleation	
This case	Pale and granular cytoplasm	6.5
	Indistinct cell border	
	Occasional binucleation or multinucleation	
	Grooved or convoluted nuclei	
	Prominent nucleoli	

fluid cytology showed similar fraction rates and cytological features. The percentage of LCs was about 6.5%. Based on these results, the 5% cut-off value of CD1a-positive cells or LCs could be postulated in BAL fluid cytology to make a PLCH diagnosis.

In this report, we described bronchial washing cytology findings of PLCH. These findings are similar to other studies describing aspiration cytology and BAL. A common finding in all of the previous reports indicates that grooved or infolded nuclei with abundant cytoplasm could be used as diagnostic features for LCs.

The difference in the present case compared with other reports could be that prominent nucleoli were observed only in some cells. The Birbeck granules are known as diagnostic LCH structures on electron microscopy (EM). However, EM study requires additional time and costs. We did not perform EM to detect Birbeck granules since other authors have suggested that it is not essential for diagnosing LCH.<sup>10</sup>

In conclusion, the possibility of LCH can be considered when bronchial washing cytology is mainly composed of Langerhans cells and eosinophils. In addition, more than 5% CD1a-positive cells in BAL fluid could be helpful for diagnosing PLCH. However, to date, there is no quantitative guideline for diagnosing PLCH. Therefore, additional cytological studies of PLCH, including quantitative analysis, are required to further identify and improve diagnostic approaches.

### Conflicts of Interest

No potential conflict of interest relevant to this article was reported.

### REFERENCES

1. Tazi A. Adult pulmonary Langerhans' cell histiocytosis. *Eur Respir J* 2006; 27: 1272-85.



2. Yousem SA, Colby TV, Chen YY, Chen WG, Weiss LM. Pulmonary Langerhans' cell histiocytosis: molecular analysis of clonality. *Am J Surg Pathol* 2001; 25: 630-6.
3. Takizawa Y, Taniuchi N, Ghazizadeh M, *et al.* Bronchoalveolar lavage fluid analysis provides diagnostic information on pulmonary Langerhans cell histiocytosis. *J Nippon Med Sch* 2009; 76: 84-92.
4. Sharma S, Dey P. Childhood pulmonary langerhans cell histiocytosis in bronchoalveolar lavage: a case report along with review of literature. *Diagn Cytopathol* 2016; 44: 1102-6.
5. Lee SR, Suh JH, Cha HJ, Kim YM, Choi HJ. Fine needle aspiration cytology of Langerhans cell histiocytosis of mandible: a case report. *Korean J Pathol* 2010; 44: 106-9.
6. Ha SY, Kim MJ, Kim GY, Cho HY, Chung DH, Kim NR. Fine needle aspiration cytology of Langerhans cell histiocytosis in a lymph node: a case report. *Korean J Cytopathol* 2007; 18: 87-91.
7. Kumar N, Sayed S, Vinayak S. Diagnosis of Langerhans cell histiocytosis on fine needle aspiration cytology: a case report and review of the cytology literature. *Patholog Res Int* 2011; 2011: 439518.
8. Auerswald U, Barth J, Magnussen H. Value of CD-1-positive cells in bronchoalveolar lavage fluid for the diagnosis of pulmonary histiocytosis X. *Lung* 1991; 169: 305-9.
9. Refabert L, Rambaud C, Mamou-Mani T, Scheinmann P, de Blic J. Cd1a-positive cells in bronchoalveolar lavage samples from children with Langerhans cell histiocytosis. *J Pediatr* 1996; 129: 913-5.
10. Kilpatrick SE. Fine needle aspiration biopsy of Langerhans cell histiocytosis of bone: are ancillary studies necessary for a "definitive diagnosis"? *Acta Cytol* 1998; 42: 820-3.