

Case Report

Paraneoplastic syndrome associate with solitary fibrous tumor of pleura

Apurwa Karki, John Yang¹, Sudheer Chauhan¹

Departments of Pulmonology and ¹Internal Medicine, Jamaica Hospital Medical Center, Jamaica, NY 11418, USA

ABSTRACT

Solitary fibrous tumor (SFT) is a rare mesenchymal tumor and several paraneoplastic syndromes have been related to it. We report the case of a 60-year-old male initially admitted to rule out cerebral vascular accident with the final diagnosis of SFT associated with paraneoplastic cerebellar degeneration and hypoglycemia. The diagnosis was confirmed by computed tomography-guided lung biopsy.

KEY WORDS: Biopsy, paraneoplastic syndrome, solitary fibrous tumor of pleura

Address for correspondence: Dr. Apurwa Karki, 140-50 Burden Crescent, Apt 5h, Jamaica, NY 11435, USA. E-mail: apurwa.karki@gmail.com

INTRODUCTION

Paraneoplastic syndromes are a constellation of symptoms and signs that are mediated by substance excreted by tumor cells or by an immune response against the tumor that cross-react with other normal cells. Solitary fibrous tumor (SFT) is associated with multiple paraneoplastic syndromes, including refractory hypoglycemia, hypertrophic pulmonary osteoarthropathy, and elevated beta human chorionic gonadotropin.^[1,2] This is a case of SFT associated with hypoglycemia, neurologic disorder, and possible hypertrophic pulmonary osteoarthropathy.

CASE REPORT

A 60-year-old male with hypertension presented with slurred speech. As per family, the patient was last seen normal 4 days back. He was found in bed covered in feces and urine and was unable to talk properly; he was admitted for the possible cerebral vascular accident. His physical examination was only remarkable for reduced air entry on the left lower lobe and clubbing of the fingers. Neurological examination was notable for staccato speech, intention

tremor, unsteady wide-based gait, and dysdiadochokinesia with normal cognition.

On investigation, magnetic resonance imaging brain was negative for acute stroke and did not show any other finding (such as cerebellar degeneration), chest X-ray displayed marked elevation of the left hemidiaphragm. Computed tomography (CT) chest scan with contrast showed a large 21 cm × 16.5 cm × 16.7 cm complex heterogeneous, partly necrotic mass that compressed and displaced the left lower lobe [Figure 1]. Biochemical workup was all within normal range except fasting blood glucose level was always <60 mg/dl during hospitalization. A paraneoplastic syndrome was suspected because of persistent hypoglycemia.

The patient underwent CT-guided lung biopsy, and pathology was reported to show rounded and spindle cells arranged in a variable background containing circumferentially hyalinized vessels [Figure 2]. Immunohistochemistry staining was positive for STAT6, a specific marker for SFT. The findings were consistent with the SFT. Further test showed low level of c-peptide, insulin,

This is an open access journal, and articles are distributed under the terms of the Creative Commons Attribution-NonCommercial-ShareAlike 4.0 License, which allows others to remix, tweak, and build upon the work non-commercially, as long as appropriate credit is given and the new creations are licensed under the identical terms.

For reprints contact: reprints@medknow.com

How to cite this article: Karki A, Yang J, Chauhan S. Paraneoplastic syndrome associate with solitary fibrous tumor of pleura. Lung India 2018;35:245-7.

Access this article online	
Quick Response Code: 	Website: www.lungindia.com
	DOI: 10.4103/lungindia.lungindia_118_17

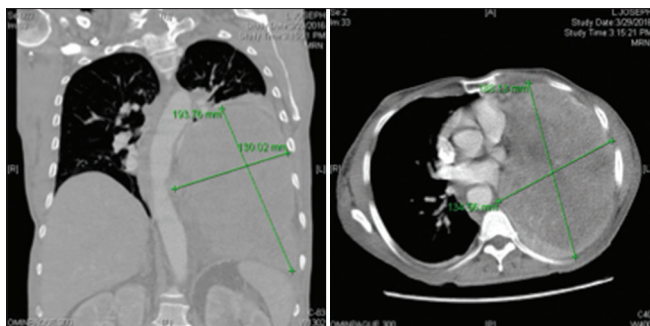


Figure 1: Large 21 cm × 16.5 cm × 16.7 cm complex heterogeneous partly necrotic mass is noted in the left hemithorax highly suspicious for malignancy. Significant atelectasis posterior segment of the left upper lobe, lingula segment, and left lower lobe is noted. Left lower lung lobes compressed and displaced by this huge mass

insulin-like growth factor (IGF)-BP3, IGF-1 with IGF-2 level 200 (normal range-267-660) [Table 1]. Blood sugar was stabilized with octreotide subcutaneous injection and dextrose oral gel. Paraneoplastic cerebellar degeneration was suspected and antibodies were sent; anti-Hu, anti-Yo, and anti-Ri were negative. After a lengthy discussion with the patient, the patient was transferred to the rehab facility to improve his functional status before surgery.

DISCUSSION

SFT is a rare mesenchymal tumor. The standardized incidence rate is estimated to be 1.4 per million and the malignancy rate is estimated to be 13%–37%.^[3,4] Malignant SFP showed high cellular pleomorphism, high mitotic activity, increased cellularity, necrosis, and hemorrhage.^[5] Our case was likely a malignant tumor based on size and the presence of necrosis. It is difficult to diagnose SFT on radiological imaging, and the sensitivity of CT is low.^[1] The diagnosis is confirmed by histopathology with immunohistochemistry staining. STAT6, a very sensitive and specific marker for SFT, was used for diagnosis in this case.^[1,6]

Paraneoplastic syndromes such as refractory hypoglycemia (Doege–Potter syndrome [DPS]) and hypertrophic pulmonary osteoarthropathy such as clubbing have been reported with SFT.^[1,2] DPS was first described in 1930 with an estimated incidence of 3%–4%.^[1,7] Large tumor size and high mitotic rate are often related to hypoglycemia.^[8] Meng *et al.* reported an equal incidence of benign and malignant SFT associated with hypoglycemia; however, tumor larger than 10 cm had a higher incidence of hypoglycemia.^[9] It has been reported that in a patient with SFT, there is an increase in the prohormone to IGF2 which acts to regulate normal glucose concentration in the serum.^[10] Since this is not measured in the routine laboratory test, a surrogate to this rise in this prohormone (also known as the big-IGF2) is the increase in the ratio of IGF2 to IGF1.^[10,11] This is likely the mechanism of hypoglycemia in our case. Other causes include hepatic or adrenal cancerous destruction.

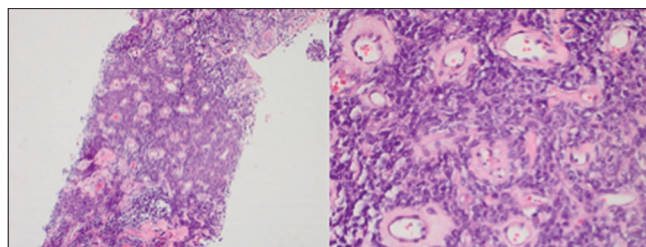


Figure 2: Rounded and spindle cells arranged in a variably hyalinized background containing circumferentially hyalinized vessels

Table 1: Hypoglycemia workup

Parameter	Value	Ref. range
Glucose, mg/dl	<60	74-106
Insulin uU/L	<1.0	2.0-19.6
C-peptide, ng/mL	0.11	0.80-3.85
IGF BP3, mg/L	1.5	3.4-6.9
IGF1, ng/mL	26	41-279
IGF2, ng/mL	200	267-616
GH, ng/mL	<0.1	≤7.1
ACTH, pg/mL	11	6-50
HbA1C, %	5	4.30-6.10
Cortisol at 3 PM, ug/dL	7	1.70-14.1

The resolution of hypoglycemia usually occurs after tumor resection. Intravenous glucose administration, glucagon infusion, glucocorticoids, growth hormone, or octreotide can be tried before surgery.^[12] Although Perros *et al.* reported persistent hypoglycemia despite maximal doses of octreotide treatment,^[13] our case showed improved glucose levels after octreotide subcutaneous injection.

The onset of neurological symptoms often precedes the identification of the tumor and the recognition of a paraneoplastic syndrome should lead to an immediate search for cancer.^[14,15] In our case, the patient had chronic fasting hypoglycemia which symptoms can mimic a stroke. Paraneoplastic Syndrome is caused by autoimmune process and several antibodies have been used to facilitate the diagnosis.^[16] Some patients have no identifiable antibodies in their serum as our patient. However, the absence of antibodies cannot rule out the diagnosis. Unlike DPS which symptoms resolve after tumor resection, cerebellar symptoms usually partial or complete remission after treating primary cancer.

CONCLUSION

SFT is rare cancer and is sometimes associated with multiple paraneoplastic syndromes. It is associated with multiple paraneoplastic syndromes. This is the first case that presented with neurological disorder and hypoglycemia. Further research is needed to determine the treatment option in the future.

Declaration of patient consent

The authors certify that they have obtained all appropriate patient consent forms. In the form the patient(s) has/have given his/her/their consent for his/her/their images and other clinical information to be reported in the journal.

The patients understand that their names and initials will not be published and due efforts will be made to conceal their identity, but anonymity cannot be guaranteed.

Financial support and sponsorship

Nil.

Conflicts of interest

There are no conflicts of interest.

REFERENCES

1. Robinson LA. Solitary fibrous tumor of the pleura. *Cancer Control* 2006;13:264-9.
2. Kugasia IR, Alkayem M, Patel JB. A rare case of β -hCG production by a solitary fibrous tumor of the pleura. *Am J Case Rep* 2014;15:518-22.
3. Thorgeirsson T, Isaksson HJ, Hardardottir H, Alfredsson H, Gudbjartsson T. Solitary fibrous tumors of the pleura: An estimation of population incidence. *Chest* 2010;137:1005-6.
4. Ardisson F. Thoracic malignant solitary fibrous tumors: Prognostic factors and long-term survival. *J Thorac Dis* 2011;3:84-5.
5. England DM, Hochholzer L, McCarthy MJ. Localized benign and malignant fibrous tumors of the pleura. A clinicopathologic review of 223 cases. *Am J Surg Pathol* 1989;13:640-58.
6. Thway K, Ng W, Noujaim J, Jones RL, Fisher C. The current status of solitary fibrous tumor: Diagnostic features, variants, and genetics. *Int J Surg Pathol* 2016;24:281-92.
7. Doege KW. Fibro-sarcoma of the mediastinum. *Ann Surg* 1930;92:955-60.
8. Li Z, Wang J, Zhu Q, Li H, Chen Y, Chen L, *et al.* Huge solitary fibrous tumor of the pleura with hypoglycemia and hypokalemia: A case report. *Ann Thorac Cardiovasc Surg* 2014;20:165-8.
9. Meng W, Zhu HH, Li H, Wang G, Wei D, Feng X, *et al.* Solitary fibrous tumors of the pleura with Doege-Potter syndrome: A case report and three-decade review of the literature. *BMC Res Notes* 2014;7:515.
10. Fung EC, Crook MA. Doege-potter syndrome and 'big-IGF2': A rare cause of hypoglycaemia. *Ann Clin Biochem* 2011;48:95-6.
11. Jones JI, Clemmons DR. Insulin-like growth factors and their binding proteins: Biological actions. *Endocr Rev* 1995;16:3-34.
12. Hoff AO, Vassilopoulou-Sellin R. The role of glucagon administration in the diagnosis and treatment of patients with tumor hypoglycemia. *Cancer* 1998;82:1585-92.
13. Perros P, Simpson J, Innes JA, Teale JD, McKnight JA. Non-islet cell tumour-associated hypoglycaemia: ¹¹¹In-octreotide imaging and efficacy of octreotide, growth hormone and glucocorticosteroids. *Clin Endocrinol (Oxf)* 1996;44:727-31.
14. Graus F, Delattre JY, Antoine JC, Dalmau J, Giometto B, Grisold W, *et al.* Recommended diagnostic criteria for paraneoplastic neurological syndromes. *J Neurol Neurosurg Psychiatry* 2004;75:1135-40.
15. Storstein A, Vedeler CA. Paraneoplastic neurological syndromes and onconeural antibodies: Clinical and immunological aspects. *Adv Clin Chem* 2007;44:143-85.
16. Marak CP, Dorokhova O, Guddati AK. Solitary fibrous tumor of the pleura. *Med Oncol* 2013;30:573.