

## Case Report

# Multiple non-branching dissecting aneurysms of the mid-basilar trunk presenting with sequential subarachnoid hemorrhages

Archie Defillo, Eric S. Nussbaum, Andrea Zelensky, Leslie Nussbaum

Department of Neurosurgery, National Brain Aneurysm Center, Health East St. Joseph's Hospital, St. Paul, MN 55102, USA

E-mail: \*Archie Defillo - [adefillo@healtheast.org](mailto:adefillo@healtheast.org); Eric S. Nussbaum - [lnussbaum@comcast.net](mailto:lnussbaum@comcast.net); Andrea Zelensky - [amzelensky@healtheast.org](mailto:amzelensky@healtheast.org);  
Leslie Nussbaum - [lnussbaum@comcast.net](mailto:lnussbaum@comcast.net)

\*Corresponding author

Received: 29 July 11

Accepted: 22 August 11

Published: 17 September 11

### This article may be cited as:

Defillo A, Nussbaum ES, Zelensky A, Nussbaum L. Multiple non-branching dissecting aneurysms of the mid-basilar trunk presenting with sequential subarachnoid hemorrhages. *Surg Neurol Int* 2011;2:127.

Available FREE in open access from: <http://www.surgicalneurologyint.com/text.asp?2011/2/1/127/85059>

Copyright: © 2011 Defillo A. This is an open-access article distributed under the terms of the Creative Commons Attribution License, which permits unrestricted use, distribution, and reproduction in any medium, provided the original author and source are credited.

## Abstract

**Objective:** We describe a rare case of a patient with subarachnoid hemorrhage (SAH) due to a ventral dissecting mid-basilar aneurysm that was treated surgically. One week after surgery, the patient experienced sudden deterioration due to a new SAH caused by the development of a new aneurysm of the basilar trunk distinct from the previously clipped aneurysm.

**Case Description:** A 54-year-old woman with acute subarachnoid hemorrhage was found to have a small, broad-based aneurysm arising from the ventral aspect of the mid-basilar artery. This complicated lesion was treated with a microsurgical clipping via a translabyrinthine pre-sigmoidal sub-temporal approach. One week postoperatively, the patient suffered a new SAH and was found to have developed a distinct basilar artery aneurysm. The patient was returned to the Operating Room for microsurgical clipping via the previous craniotomy. After surgery, the patient made a slow, but steady, recovery. She underwent repeated angiographic imaging, demonstrating a stable appearance. Two years post surgery, the patient had returned to work and had no obvious neurological deficit, with the exception of unilateral iatrogenic hearing loss.

**Conclusion:** We describe a rare case of multiple aneurysms originating in relation to a mid-basilar dissection, resulting in multiple episodes of SAH. These are difficult and dangerous lesions that can be treated with open microsurgical reconstruction or possibly via an endovascular approach. The intricate location of the lesions poses a particular challenge to neurosurgeons attempting to directly treat mid-basilar lesions.

**Key Words:** Aneurysm, basilar trunk, dissecting aneurysm, subarachnoid hemorrhage

### Access this article online

**Website:**

[www.surgicalneurologyint.com](http://www.surgicalneurologyint.com)

**DOI:**

10.4103/2152-7806.85059

**Quick Response Code:**



## INTRODUCTION

Mid-basilar trunk dissecting aneurysms are uncommon and potentially dangerous lesions. The natural history of this entity has not been well-documented because of its

rarity.<sup>[1,5]</sup> The location of the dissection can occur anywhere along the basilar trunk, most commonly between the superior cerebellar (SCA) and anterior inferior cerebellar arteries (AICA).<sup>[30]</sup> Clinical presentation can result from SAH, brainstem compression, or brainstem ischemia,

caused by a thromboembolic event.<sup>[9,15,16,25,28,30]</sup> Recurrent SAH has been described in this setting as well.<sup>[2,16,22,28,30,32]</sup> Surgical management of these lesions is particularly challenging because of the difficult surgical access to this area. Current endovascular techniques used to treat these lesions include coil, stent, and pipeline embolization devices.<sup>[4,8,19,21]</sup>

We describe a rare case of a patient who presented with SAH due to a ventral dissecting, mid-basilar aneurysm that was treated surgically via a combined translabyrinthine subtemporal approach. One week after an apparently successful surgery, the patient experienced sudden deterioration due to a new SAH caused by the development of a new aneurysm on the lateral wall of the basilar trunk, distinct from the previously clipped aneurysm.

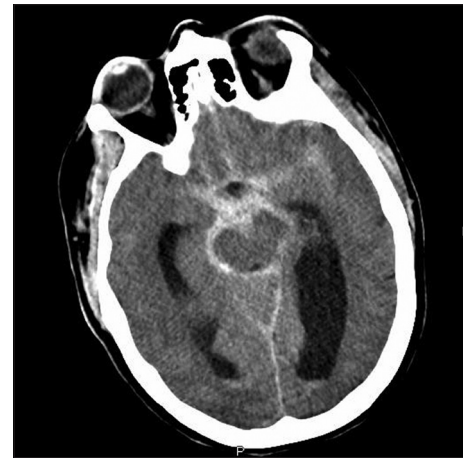## CASE REPORT

A 54-year-old female woke up with a severe headache and described it as the, 'worst headache of her life'. She went to work as usual, but was later sent home because of lack of improvement in her pain. At home, she was found unresponsive by a family member. Paramedics were summoned, and on arrival she was intubated and ventilated with sonorous respirations in the field. The only contributing medical factors were a history of smoking and a brother who had experienced aneurysmal SAH at the age of 21.

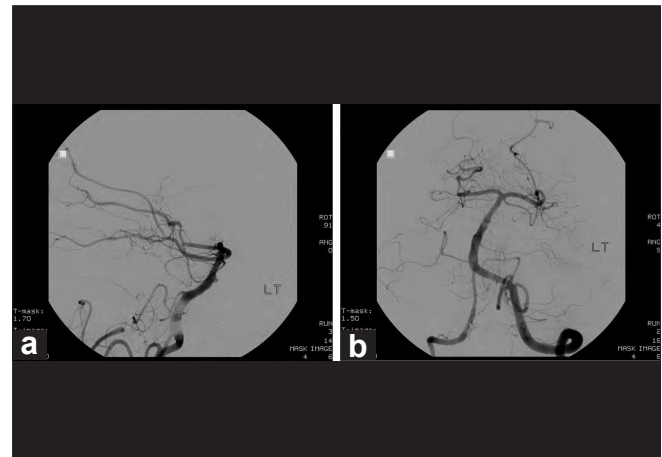
On arrival to the National Brain Aneurysm Center she presented with decerebrating posturing and pupil dilatation. Her initial CT-scan revealed a severe SAH (thick basal SAH with intraventricular extension) [Figure 1]. After CT-scan, she underwent emergency craniotomy and ventriculostomy. The admitting angiogram showed a 2.7 mm x 1.8 mm x 1.3 mm aneurysm originating from the ventral aspect of the mid-basilar artery. The aneurysm in the neck measured 2.7 mm in maximum dimension [Figures 2a and b]. Two-dimensional images of this aneurysm did not reveal any vessel associated with the aneurysm origin, and three-dimensional pictures confirmed the non-branching location. Post craniotomy the patient demonstrated neurological improvement to the point where she was withdrawing to pain. As the aneurysm was small and broad-based, a decision was made to proceed with the microsurgical clipping of this complicated basilar trunk aneurysm via a translabyrinthine, pre-sigmoidal, sub-temporal approach.

### Intraoperative findings

Under high power magnification, the cerebellopontine angle region was accessed. A significant amount of subarachnoid clot was removed from above and below the seventh to eighth cranial nerve complex. The fifth cranial nerve was identified laterally; an additional clot



**Figure 1:** Admission axial CT showing extensive thick basal SAH along the interpeduncular, quadrigeminal, and carotid chiasmatic cisterns, with intraventricular extension and early hydrocephalus



**Figures 2:** (a, b) Admission lateral and AP angiographic images demonstrating a broad-based 2.7 mm x 2.5 mm x 1.8 mm aneurysm arising from the ventral aspect of the midbasilar trunk. The right vertebral artery seems to be small and slightly irregular. There is no laterally directed aneurysm that is noticeable

was removed from between the fifth cranial nerve and the seventh to eighth cranial nerve complex, allowing exposure of the lateral aspect of the basilar trunk. Dissection continued between the fourth and fifth cranial nerves. The aneurysm's proximal neck was identified just above the fourth cranial nerve. A temporary clip was placed on the basilar artery between the fourth and fifth cranial nerves, which was followed by the safe placement of a long bayoneted clip across the aneurysm in the neck. Intraoperative angiography confirmed obliteration of the aneurysm and preservation of flow through the basilar artery.

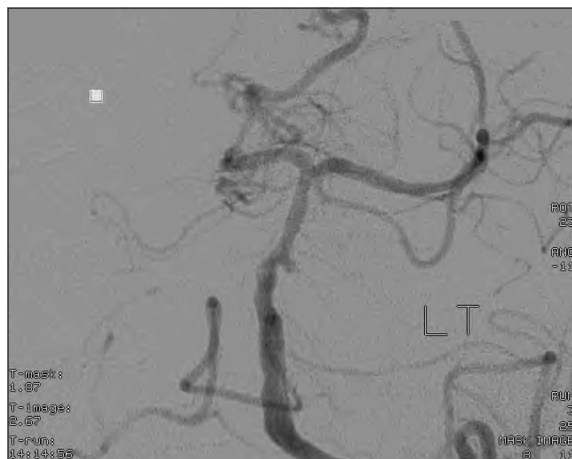
### Postoperative course

Postoperatively the patient continued to improve, until one week later when a change in her clinical status was

noted. Further radiological evaluation revealed a new SAH. An emergency angiogram demonstrated the growth of a distinct, laterally directed, sidewall aneurysm, arising from the basilar artery, approximately midway between the AICA and SCA [Figure 3]. This aneurysm was close to, but not contiguous with the previously clipped ventral lesion. Given the pattern and distribution of the hemorrhage on the new CT scan, it was felt that this aneurysm was probably responsible for the second SAH. On account of the small size, with an overall diameter measuring less than 2 mm and a relatively broad neck, it was considered not amenable to primary coil embolization. Endovascular stenting was considered, but in the face of the recent major surgery we were concerned by the potential need for plavix, to limit the risk of in-stent thrombosis.

The patient was therefore returned to the Operating Room, and the previous craniotomy was re-opened. Once again the fourth cranial nerve was identified; the basilar artery was widely exposed from the posterior fossa below the fourth and fifth cranial nerves, all the way to its bifurcation. In order to allow for clipping of the second lesion, the previously placed clip at the neck of the ventrally located aneurysm was removed. On doing so, it was noticed that this aneurysm was already thrombosed.

The new aneurysm was identified, but during dissection began to bleed. To gain control of the situation a temporary clip was placed on the basilar artery below the fourth cranial nerve. On visual inspection the sidewall aneurysm was sessile, thin-walled, and broad-based. The basilar artery itself, at this point, appeared to be very thin. Bleeding control was achieved by placing a heavily curved clip across the front of the basilar artery, which gently tensioned the neck of the aneurysm, allowing reconstruction of the sidewall of the basilar artery. A



**Figure 3: Angiography showing a laterally directed, 1.5 mm newly formed sidewall aneurysm, arising from the basilar artery, approximately midway between the AICA and SCA. This aneurysm was inferior to the ventrally located and clipped aneurysm of the week before**

second clip was repositioned across the ventral basilar aneurysm that had been previously clipped.

## Outcome

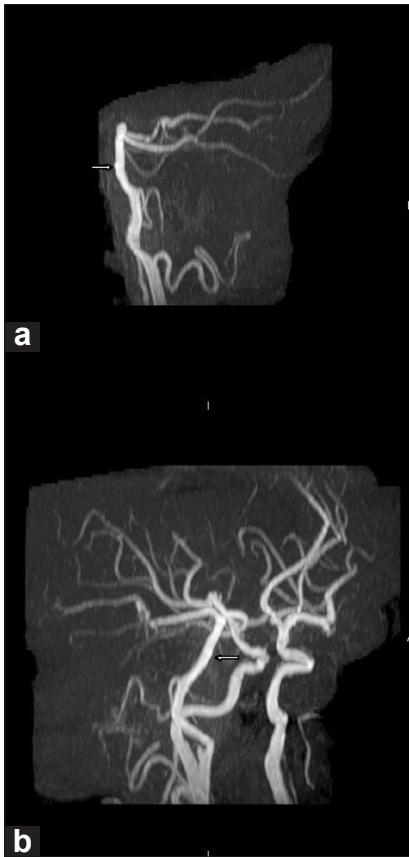
The patient made a subsequent, slow, but steady recovery. She underwent repeated angiographic imaging demonstrating a stable appearance at two weeks, three months, and 18 months. At the time of her two-year follow-up, the patient had returned to work and had no obvious neurological deficit, with the exception of unilateral hearing loss from her surgery.

## DISCUSSION

Dissecting aneurysms involving the mid-basilar artery are rare and complicated lesions.<sup>[1,5]</sup> The occurrence of metachronous SAHs from two aneurysms developing along the mid-basilar artery weeks apart is particularly uncommon. We suspect that the two aneurysms originated from the dissection of the artery, which resulted in local arterial thinning and eventual repeated bleeding.

Posterior circulation dissections most commonly originate and extend into the vertebrobasilar complex from the distal vertebral arteries.<sup>[23]</sup> Acute basilar artery dissection seems to be associated with a more ominous course and prognosis, in comparison to a dissection limited to the vertebral artery.<sup>[14,19,20,28,35]</sup> Clinical symptoms related to mid-basilar artery dissecting aneurysm include brainstem or cerebellar stroke, cranial nerve compression, and less commonly SAH.<sup>[9,15,16,25,28,30]</sup> In general, it has been postulated that dissecting aneurysms are often associated with underlying arteriopathies such as fibromuscular dysplasia, Ehlers-Danlos and Marfan syndromes or cystic medial necrosis, causing structural weakening of the arterial wall and predisposing it to arterial dissection.<sup>[12,24]</sup> Cigarette smoking associated with antitrypsin deficiency has been linked to structural wall weakening as well.<sup>[7,29]</sup> In our case report, apart from a family history of cerebral aneurysm and current smoking, there have been no other associated co-morbidities.

The acute enlargement of the side wall dissecting aneurysm in this case may be related to an unstable arterial dissection and persistent hemodynamic stress despite the initial surgical procedure. It is possible that the second aneurysm was caused by the fragile basilar artery having been injured by angiography, but the proximity of the second aneurysm to the original lesion seems more in keeping with a second area of dilation related to the same underlying dissection process [Figures 4a and b]. As both lesions were extremely thin-walled, the possibility also exists that the second lesion was actually the point of SAH originally, but was thrombosed on the original angiogram and then recanalized and rebelled. Nevertheless, at the time of the



**Figure 4: (a, b) Preoperative MRA images demonstrating a double density along the ventral aspect of the midbasilar trunk (arrow), suggesting the presence of a small sessile aneurysm**

original surgery, the first aneurysm clearly appeared to have been the site of hemorrhage.

Several studies have demonstrated that cerebral aneurysms at non-branching sites and saccular aneurysms at branching sites can occur under the same etiological conditions, with the non-branching site formation possibly related to hemodynamic stress.<sup>[18]</sup> Under normal conditions, cerebral arteries manifest thin arterial media, lack of external elastic lamina, and a dehiscent adventitia, as compared to the extra-cranial vessels.<sup>[26,27]</sup> These changes play a key role in protecting the cerebral arteries from fluctuations in blood pressure and flow.<sup>[10,34]</sup> The main structural support in the cerebral arteries is provided by the arterial media and internal elastic lamina. Described changes in human non-branching aneurysm walls include overexpression of matrix metalloproteinases 1, 2, and 9, aneurysm walls composed of alpha-SMA-positive and calponin / desmin-negative spindle cells, absent internal elastic lamina, and internal elastic lamina, which is completely disrupted at the neck of the aneurysm.<sup>[33]</sup> When comparing the non-branching aneurysmal segment to the parent artery, the latter shows thickening of both the intima and media, with preservation of the internal elastic lamina.<sup>[33]</sup> These

previously described structural findings support the intraoperative visual observation of a thin basilar artery associated with a sidewall aneurysm that is sessile and thin-walled.

Unfortunately, the difficult location of these lesions in regard to surgical access provides a particular challenge to neurosurgeons. The basilar artery trunk is located in the 'depth of the valley'.<sup>[13]</sup> Surgical access to this area is hindered by multiple cranial nerves, perforating arteries, and important venous drainage to the brain stem. Surgical management of this type of lesion is best handled by an experienced neurovascular surgeon with extensive knowledge and experience in skull base surgical approaches including transpetrosal, subtemporal presigmoid, suboccipital, and translabyrinthine approaches.<sup>[6,11,17,31]</sup> In our experience, an acceptable option would be wrapping the affected segment rather than simply clipping the dilated aneurysmal portion, and endovascular stenting has emerged as a reasonable alternative, which attempts to stabilize similar intracranial dissections.<sup>[3]</sup>

## CONCLUSION

We describe a rare case of multiple aneurysms arising in relation to a mid-basilar dissection resulting in multiple episodes of SAH. These are difficult and dangerous lesions that can be treated endovascularly or with open microsurgical reconstruction. The intricate location of the lesions poses a particular challenge to neurosurgeons attempting to directly treat mid-basilar lesions.

## REFERENCES

1. Ali MJ, Bendok BR, Tella MN, Chandler JP, Getch CC, Batjer HH. Arterial reconstruction by direct surgical clipping of the basilar artery dissecting aneurysm after failed vertebral artery occlusion: Technical case report and literature review. *Neurosurgery* 2003;52:1475-81.
2. Amin-Hanjani S, Ogilvy CS, Buonanno FS, Choi IS, Metz LN. Treatment of dissecting basilar artery aneurysm by flow reversal. *Acta Neurochir (Wien)* 1997;139:44-51.
3. Ansari SA, Lassig JP, Nicol E, Thompson G, Gemmete JJ, Gandhi D. Thrombosis of a fusiform intracranial aneurysm induced by overlapping neuroform stents. *Neurosurgery* 2007;60:950-1.
4. Patroclo CB, Puglia P Jr, Leite Cda C, Yamamoto FI, Ciriaco JG, Scaff M, et al. Endovascular treatment of a basilar artery dissecting aneurysm. *Arq Neuropsiquiatr* 2007;65:1012-4.
5. Caplan LR. *Caplan's stroke: A clinical approach*. 3<sup>rd</sup> ed. Woburn, MA: Butterworth-Heinemann; 2000. p. 295-342.
6. Drake CG. The surgical treatment of aneurysms of the basilar artery. *J Neurosurg* 1968;29:436-46.
7. Ellamushi HE, Grieve JP, Jager HR, Kitchen ND. Risk factors for the formation of multiple intracranial aneurysms. *J Neurosurg* 2001;94:728-32.
8. Fiorella D, Kelly ME, Alburquerque FC, Nelson PK. Curative reconstruction of a giant midbasilar trunk aneurysm with a pipeline embolization device. *Neurosurgery* 2009;64:212-7.
9. Friedman AH, Drake CG. Subarachnoid hemorrhage from intracranial dissecting aneurysm. *J Neurosurg* 1984;60:325-34.
10. Glynn LE. Medial defects in the circle of Willis and their relation to aneurysm formation. *J Path Bacteriol* 1940;51:213-22.

11. Hammon WM, Kempe LG. The posterior fossa approach to aneurysms of the vertebral and basilar arteries. *J Neurosurg* 1972;37:339-47.
12. Han Z, Leung TW, Lam W, Soo Y, Wong KS. Spontaneous basilar artery dissection. *Hong Kong Med J* 2007;13:144-6.
13. Higa T, Ujiie H, Kato K, Kamiyama H, Hori T. Basilar trunk saccular aneurysms: Morphological characteristics and management. *Neurosurg Rev* 2009;32:181-91.
14. Hosoda K, Fujita S, Kawaguchi T, Shose Y, Yonozawa K, Shirakuni T, et al. Spontaneous dissecting aneurysm of the basilar artery presenting with subarachnoid hemorrhage. Report of two cases. *J Neurosurg* 1991;75:628-33.
15. Hosoya T, Adachi M, Yamaguchi K, Haku T, Kayama T, Kato T. Clinical and neuroradiological features of intracranial vertebrobasilar artery dissection. *Stroke* 1999;30:1083-90.
16. Kai Y, Hamada J, Motohiro M, Yano S, Hamasaki K, Ushio Y. Successful treatment of a ruptured dissecting basilar artery aneurysm. *J Neurosurg* 2004;100:1072-5.
17. Kawase T, Toya S, Shiobara R, Mine T. Transpetrosal approach for aneurysm of the lower basilar artery. *J Neurosurg* 1985;63:857-61.
18. Kondo S, Hashimoto N, Kikuchi H, Hazama F, Nagata I, Kataoka MT. Cerebral aneurysms arising at nonbranching sites. *Stroke* 1997;28:398-404.
19. Liu L, Jiang C, He H, Li Y, Wu Z. Delayed thrombosis of the basilar artery after stenting for a basilar trunk dissection aneurysm. A case report and review of the literature. *Interv Neuroradiol* 2010;16:77-82.
20. Masson C, Krespy Y, Masson M, Colombani JM. Magnetic resonance imaging in basilar artery dissection. *Stroke* 1993;24:1264-6.
21. Matsubara S, Satoh K, Satomi J, Miyamoto T, Uno M, Nagahiro S. Guglielmi detachable coil embolization for ruptured lower-midbasilar trunk aneurysms: A report of five cases. *Neuroradiology* 2001;43:884-90.
22. Mizutani T. A fatal, chronologically growing basilar artery: A new type of dissecting aneurysm. *J Neurosurg* 1996;84:962-71.
23. Mokri B, Houser OW, Sandok BA, Piepgras DG. Spontaneous dissection of the vertebral arteries. *Neurology* 1988;38:880-5.
24. Mokri B, Sundt TM Jr, Houser OW, Piepgras DG. Spontaneous dissection of the cervical internal carotid artery. *Ann Neurol* 1986;19:126-38.
25. Nakahara T, Satoh H, Mizoue T, Kawamoto H, Kohmo Y, Kurisu K. Dissecting aneurysm of the basilar artery presenting with recurrent subarachnoid hemorrhage. *Neurosurg Rev* 1999;22:155-8.
26. Oneda G. Pathology of cerebral hemorrhage. *Nitibyokaisi* 1970;59:27-56.
27. Osawa H, Fukui K, Otsuka G, Hattori K, Satake T, Miyazaki M. De novo cerebral aneurysm manifesting as repeated subarachnoid hemorrhage and cerebral ischemic stroke. Case report. *Neurol Med Chir (Tokyo)* 2002;42:391-5.
28. Pozzati E, Andreoli A, Padovani R, Nuzzo G. Dissecting aneurysm of the basilar artery: Clinical study. *Neurosurgery* 1995;36:254-8.
29. Qureshi AI, Suarez JL, Parekh P, Sung G, Geocadin R, Bhardwaj A, et al. Risk factors for multiple intracranial aneurysms. *Neurosurgery* 1998;43:22-7.
30. Ruecker M, Furtner M, Knoflach M, Werner P, Gotwald T, Chemelli A, et al. Basilar artery dissection: Series of 12 consecutive cases and review of the literature. *Cerebrovasc Dis* 2010;30:267-76.
31. Seifert V, Raabe A, Zimmerman M. Conservative (labyrinth-preserving) transpetrosal approach to the clivus and petroclival region—indications, complications, results and lessons learned. *Acta Neurochir (Wien)* 2003;145:631-42.
32. Takagi M, Hirata K, Fujitsu K, Yamamoto I. Unusual angiographic changes in a dissecting aneurysm of the basilar artery: Case report. *Neurosurgery* 1994;34:356-8.
33. Takemura Y, Hirata Y, Sakata N, Nabeshima K, Takeshita M, Inoue T. Histopathologic characteristics of saccular aneurysm arising in the non-branching segment of the distal middle cerebral artery. *Pathol Res Pract* 2010;206:391-6.
34. Yamamoto K, Yoshida Y. Pathology of subarachnoid hemorrhage, with special reference to the morphogenesis of berry aneurysms of cerebral arteries and mechanism of their rupture. *Myakkangaku* 1977;17:183-95.
35. Yoshimoto Y, Hoya K, Tanaka Y, Uchida T. Basilar artery dissection. *J Neurosurg* 2005;102:476-81.