



Case Report

De novo dural arteriovenous fistula after mechanical thrombectomy for cerebral venous thrombosis: A case report

Satoru Kida¹, Hiroaki Neki¹, Hisaya Hiramatsu², Yoshinobu Kamio¹, Ippei Makita¹, Yuki Shiraishi¹, Kazuhiko Kurozumi¹

¹Department of Neurosurgery, Hamamatsu University School of Medicine, ²Department of Neurosurgery, Hamamatsu Medical Center, Hamamatsu, Japan.

E-mail: Satoru Kida - kidakida@hama-med.ac.jp; *Hiroaki Neki - neki04@hama-med.ac.jp; Hisaya Hiramatsu - hhira@hmedc.or.jp; Yoshinobu Kamio - ykamio@hama-med.ac.jp; Ippei Makita - i.makita325@gmail.com; Yuki Shiraishi - s02171005@outlook.jp; Kazuhiko Kurozumi - kurozu20@hama-med.ac.jp

*Corresponding author:

Hiroaki Neki,
Department of Neurosurgery,
Hamamatsu University School
of Medicine, Hamamatsu,
Japan.

neki04@hama-med.ac.jp

Received : 13 July 2022
Accepted : 21 August 2022
Published : 09 September 2022

DOI
10.25259/SNI_625_2022

Quick Response Code:



ABSTRACT

Background: Although the relationship between dural arteriovenous fistula (dAVF) and cerebral venous thrombosis (CVT) has been reported, the etiology has not been clarified. Here, we report a case of *de novo* dAVF after mechanical thrombectomy for CVT and discuss the underlying mechanism.

Case Description: A 61-year-old woman presented with a gradually worsening headache and was diagnosed with severe CVT. Mechanical thrombectomy was performed for the CVT because of progressive neurological deterioration despite anticoagulation therapy. Two years after the initial treatment, angiography revealed a *de novo* dAVF with a direct shunt of the left convexity cortical vein. Transarterial embolization with Onyx was performed and the shunt was completely obliterated.

Conclusion: In this report, we describe a case of *de novo* dAVF with CVT that was treated with mechanical thrombectomy. Even if CVT improves with mechanical thrombectomy, we must be aware of the occurrence of *de novo* dAVF.

Keywords: Cerebral venous thrombosis, Dural arteriovenous fistula, Mechanical thrombectomy

INTRODUCTION

Dural arteriovenous fistulas (dAVF) are acquired following cerebral venous thrombosis (CVT), trauma, or surgery.^[1,11] The relationship between CVT and dAVF was first reported in 1979,^[7] and although venous hypertension and angiogenesis have been implicated in dAVF formation, the exact etiology remains unclear to date.^[2] The previous studies have shown that dAVF developed in 1.5–2.4% of CVT patients.^[10,12] However, *de novo* dAVF after mechanical thrombectomy for CVT is unknown. We present a case of *de novo* dAVF that required treatment after mechanical thrombectomy for severe CVT and discuss the etiology of dAVF following the CVT.

CASE DESCRIPTION

A 61-year-old woman presented with a history of idiopathic thrombocytopenic purpura. She presented with gradually worsening headache, visual disturbance, and disorientation

for approximately 3 weeks. Neurological examination revealed confused consciousness and headache worsening in the recumbent position. Diffusion-weighted images demonstrated multiple infarctions in the right temporal and cerebellar hemispheres. T2*-weighted images revealed an extensive thrombus affecting the superior sagittal sinus (SSS) to the right sigmoid sinus (SS) [Figures 1a and b]. Coagulopathy was ruled out by hematological examination without any recognized thrombocytopenia. Intravenous anticoagulation therapy with heparin was administered for the CVT. Two days after the introduction of anticoagulation therapy, decreased consciousness and left hemiplegia developed. Fluid-attenuated inversion recovery images revealed a new venous infarction in the right frontal lobe [Figures 1c and d]. Angiography showed venous congestion with an extensive contrast defect from the SSS to the right SS with venous congestion in the venous phase. No dAVF was detected [Figures 2a-c]. Mechanical thrombectomy was performed for venous sinus thrombus. Under local anesthesia, a long guiding sheath of 6 French was inserted into the right jugular vein through the femoral vein. An aspiration catheter with a large bore was advanced into the right SS to the SSS. A large dark-red thrombus was aspirated and spontaneous blood flow was confirmed. Final angiography showed partial recanalization of the SSS and transverse sinus (TS) with a residual thrombus [Figure 2d]. Her level of consciousness and left hemiplegia

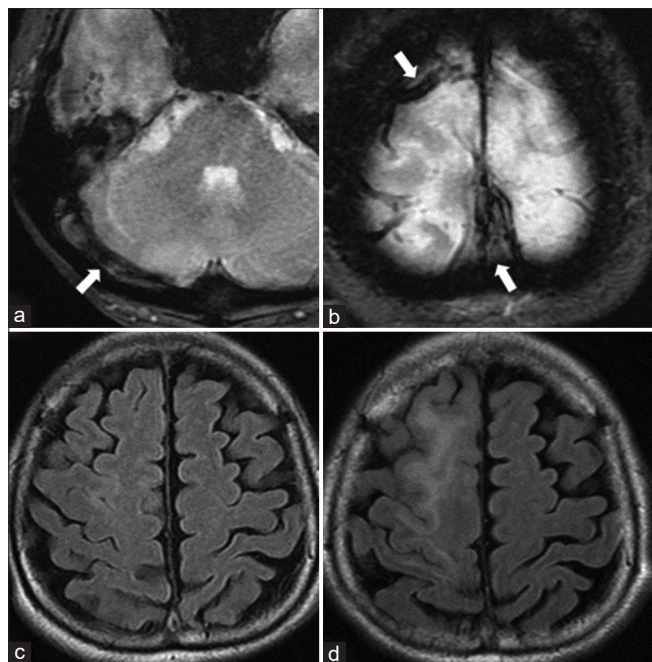


Figure 1: (a and b) Magnetic resonance images showing extensive thrombus (arrows) in sigmoid sinus, superior sagittal sinus, and right cortical vein. (c) Fluid-attenuated inversion recovery (FLAIR) image on admission. (d) FLAIR image on neurological deterioration.

markedly improved and she was discharged without any neurological deficits. Oral anticoagulation therapy was then continued. She was readmitted with secondary generalized seizures at our hospital 1 month after discharge. Computed tomography revealed a hematoma with edema in the left frontal cortex. T2*-weighted images revealed a thrombus in the focal cortical vein near the hematoma [Figure 3]. The patient was diagnosed with hemorrhagic infarction due to venous thrombus recurrence. Intravenous anticoagulation therapy with heparin was reintroduced and the thrombus subsequently dissolved on magnetic resonance

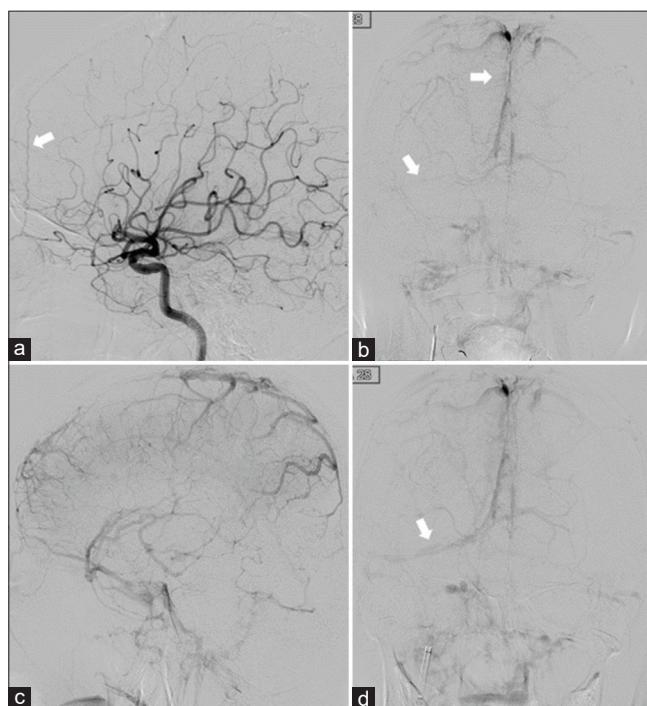


Figure 2: (a) Preinterventional angiograms. No apparent dural arteriovenous fistulas were detected, but the anterior falcine artery was slightly obvious (arrow). (b and c) Arrows indicate extensive thrombus in the sinuses. (d) Partial recanalization of dural sinuses was obtained (arrow).

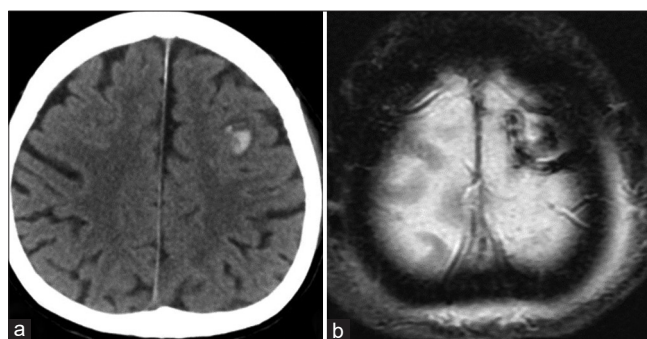


Figure 3: (a) Computed tomograms showing left frontal lobar hemorrhage 1 cm in diameter. (b) T2*-weighted images revealed a new thrombus in the left cortical vein.

imaging (MRI) examination. The patient was discharged uneventfully using warfarin. During the follow-up period, the residual thrombus in the SSS and TS gradually dissolved on MRI examination. However, a high-signal spot arose in the left frontal cortex on arterial spin labeling images, and angiography was performed 2 years after the initial treatment, even though it was asymptomatic. Angiography revealed *de novo* dAVF that was fed from the anterior falcine and middle meningeal artery and directly drained into the left cortical vein, classified as high-grade dAVF of Borden Type III and Cognard Type III [Figures 4a and b]. Transarterial embolization with Onyx was performed with complete obliteration without a shunt [Figures 4c and d].

DISCUSSION

The previous studies have reported that dAVFs are acquired due to CVT, trauma, surgery, coagulopathy, and infection.^[1,3,15] It is also known that congenital factors are implicated in dAVF formation, resulting in dAVF in infants.^[8] However, among these, CVT is considered to be the most explainable cause of dAVF, since the association between dAVF and CVT has been widely reported.^[7,11]

In a previous study investigating the characteristics and risk factors of dAVF with CVT in a large multicenter cohort of patients with CVT, dAVF patients with CVT had multiple dAVFs in 50% of them, and SS and TS were involved in approximately 70% each. Regarding the Cognard type, IIa+b was the most common, followed by IIa and III. Compared

to CVT-only patients, they were older (median age 53 years), more often male, had a more chronic CVT course (>30 days), and more often had thrombosis in the SS, but with fewer parenchymal brain lesions.^[10] Comparing our case to the aforementioned case, there was no correspondence except for the patient's age.

The mechanism of acquired dAVF after CVT is generally suspected to be caused by increased venous pressure due to CVT and not by the venous thrombus itself. Venous hypertension due to steno-occlusive lesions in the venous sinus dilates the venules and can result in arteriovenous shunt formation.^[5] It has been demonstrated that venous hypertension induces dAVF formation in a rat model.^[6,9] In our case, mechanical thrombectomy for CVT improved angiographically venous outflow, which could result in a decrease in venous pressure. However, *de novo* dAVF developed despite partial recanalization of the dural sinuses.

The first cause of *de novo* dAVF is insufficient venous pressure reduction. Due to partial recanalization of the dural sinuses, venous pressure decreased to some extent. However, venous congestion persisted despite mechanical thrombectomy due to the high thrombus volume. Consequently, the remaining venous hypertension persisted, resulting in dAVF formation. Moreover, the fact that the anterior falcine artery was slightly prominent on the first angiography could be a sign that *de novo* dAVF formation had already begun to develop due to initial venous hypertension. Second, cortical vein rethrombosis could be involved in dAVF formation. Although the overall venous pressure was decreased by mechanical thrombectomy, local venous hypertension could occur due to partial venous stagnation induced by thrombus in the cortical vein, which caused the dAVF. Regarding the nonsupportive point for this hypothesis, there was no dAVF resulting from cortical vein thrombosis in the aforementioned study.^[10] Third, a large-bore aspiration catheter could have been the cause. In animal studies and validation of human venous sinus specimens from patients with dAVF, the expression of angiogenic factors such as vascular endothelial growth factor and basic fibroblast growth factor was clarified, and these factors were predicted to be involved in the pathogenesis of dAVF formation.^[13,14] In addition, other animal studies have reported that vascular endothelial injury promotes angiogenesis.^[4] Therefore, it is possible that the large-bore aspiration catheter caused mild mechanical injury to the venous endothelial cells, which promoted angiogenic factors and was involved in dAVF formation. While this *de novo* dAVF could be explained mainly by these three mechanisms, the fact that some venous congestion remained after mechanical thrombectomy would most likely support the first mechanism of insufficient venous pressure reduction.

In summary, we encountered a rare case of *de novo* dAVF after mechanical thrombectomy for severe CVT. Although neurological disorders caused by CVT were improved by

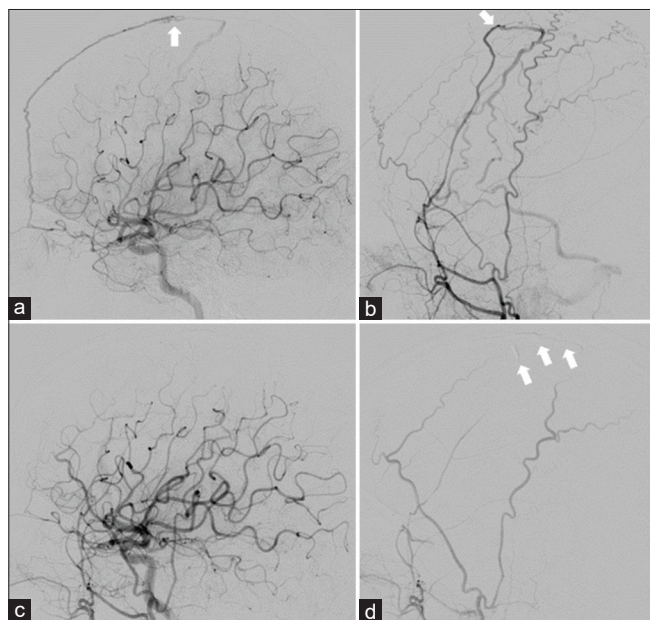


Figure 4: (a and b) Left internal and external carotid angiograms showed high-grade dural arteriovenous fistulas directly draining into the left cortical vein (arrows). (c and d) The shunt was completely occluded. Arrows indicate Onyx cast.

mechanical thrombectomy, multiple factors were present that could cause *de novo* dAVF, such as insufficient venous pressure reduction, cortical venous re-thrombosis, and large-bore catheter treatment. In this case, early diagnosis and intervention could have prevented intracranial hemorrhage and nonhemorrhagic aggressive symptoms due to dAVF. We must be aware that even if venous pressure reduction appears to be achieved for CVT patients, high-grade dAVF could still occur following CVT. Therefore, careful follow-up is warranted.

CONCLUSION

We present a rare case of *de novo* dAVF after mechanical thrombectomy for severe CVT. Even if CVT improves by mechanical thrombectomy, there is a need to keep in mind the occurrence of *de novo* dAVF.

Declaration of patient consent

Institutional Review Board (IRB) permission obtained for the study.

Financial support and sponsorship

Nil.

Conflicts of interest

There are no conflicts of interest.

REFERENCES

1. Baharvahdat H, Ooi YC, Kim WJ, Mowla A, Coon AL, Colby GP. Updates in the management of cranial dural arteriovenous fistula. *Stroke Vasc Neurol* 2020;5:50-8.
2. Chen L, Mao Y, Zhou LF. Local chronic hypoperfusion secondary to sinus high pressure seems to be mainly responsible for the formation of intracranial dural arteriovenous fistula. *Neurosurgery* 2009;64:973-83; discussion 983.
3. Demartini Z Jr, Gatto LA, de Oliveira TV, Guimaraes RM, Francisco AN, Koppe GL. Dural arteriovenous fistula associated with dental implant. *World Neurosurg* 2020;141:69-71.
4. Edelman ER, Nugent MA, Smith LT, Karnovsky MJ. Basic fibroblast growth factor enhances the coupling of intimal hyperplasia and proliferation of vasa vasorum in injured rat arteries. *J Clin Invest* 1992;89:465-73.
5. Hamada Y, Goto K, Inoue T, Iwaki T, Matsuno H, Suzuki S, *et al.* Histopathological aspects of dural arteriovenous fistulas in the transverse-sigmoid sinus region in nine patients. *Neurosurgery* 1997;40:452-56; discussion 456-8.
6. Herman JM, Spetzler RF, Bederson JB, Kurbat JM, Zabramski JM. Genesis of a dural arteriovenous malformation in a rat model. *J Neurosurg* 1995;83:539-45.
7. Houser OW, Campbell JK, Campbell RJ, Sundt TM Jr. Arteriovenous malformation affecting the transverse dural venous sinus--an acquired lesion. *Mayo Clin Proc* 1979;54:651-61.
8. Lasjaunias P, Maguifis G, Goulao A, Piske R, Suthipongchai S, Rodesch R, *et al.* Anatomoclinical aspects of dural arteriovenous shunts in children. Review of 29 cases. *Interv Neuroradiol* 1996;2:179-91.
9. Lawton MT, Jacobowitz R, Spetzler RF. Redefined role of angiogenesis in the pathogenesis of dural arteriovenous malformations. *J Neurosurg* 1997;87:267-74.
10. Lindgren E, Rentzos A, Hiltunen S, Serrano F, Heldner MR, Zuurbier SM, *et al.* Dural arteriovenous fistulas in cerebral venous thrombosis: Data from the international cerebral venous thrombosis consortium: Data from the international cerebral venous thrombosis consortium. *Eur J Neurol* 2022;29:761-70.
11. Mironov A. Pathogenetical consideration of spontaneous dural arteriovenous fistulas (DAVFs). *Acta Neurochir (Wien)* 1994;131:45-58.
12. Piippo A, Niemelä M, van Popta J, Kangasniemi M, Rinne J, Jääskeläinen JE, *et al.* Characteristics and long-term outcome of 251 patients with dural arteriovenous fistulas in a defined population. *J Neurosurg* 2013;118:923-34.
13. Shin Y, Nakase H, Nakamura M, Shimada K, Konishi N, Sakaki T. Expression of angiogenic growth factor in the rat DAVF model. *Neurol Res* 2007;29:727-33.
14. Terada T, Tsuura M, Komai N, Higashida RT, Halbach VV, Dowd CE, *et al.* The role of angiogenic factor bFGF in the development of dural AVFs. *Acta neurochir (Wien)* 1996;138:877-83.
15. Van Dijk JM, TerBrugge KG, Van der Meer FJ, Wallace MC, Rosendaal FR. Thrombophilic factors and the formation of dural arteriovenous fistulas. *J Neurosurg* 2007;107:56-9.

How to cite this article: Kida S, Neki H, Hiramatsu H, Kamio Y, Makita I, Shiraishi Y, *et al.* *De novo* dural arteriovenous fistula after mechanical thrombectomy for cerebral venous thrombosis: A case report. *Surg Neurol Int* 2022;13:411.