

Case Report

Late Onset of Cardiac Metastasis of a Melanoma following Nivolumab Immunotherapy

Kenta Nakamura Hiroshi Koga Yuko Takazawa Toshikazu Omodaka
Yukiko Kiniwa Ryuhei Okuyama

Department of Dermatology, Shinshu University School of Medicine, Matsumoto, Japan

Keywords

Melanoma · Metastatic cardiac tumor · Dacarbazine

Abstract

In this report, we present a case of cardiac metastasis of a malignant melanoma originating from the nasal cavity and presenting with cardiac tamponade detected during immunotherapy. The patient was a 66-year-old man diagnosed with malignant melanoma of the right nasal cavity 4 years ago. Two years ago, the size of the melanoma increased making it unresectable; therefore, he was treated thrice with a combination therapy of nivolumab and ipilimumab. Subsequently, the treatment was changed to single-agent nivolumab therapy, which was continuously administered for one and a half years. Imaging evaluation conducted every 3 months showed no distant metastasis. General malaise occurred, and the patient visited our department. He was diagnosed to have cardiac tamponade using echocardiography and was admitted to the emergency department of our hospital. He underwent pericardiocentesis. Computed tomography revealed an irregular mass extending from the right atrium to the inferior vena cava, and malignant melanoma metastasis was diagnosed through catheter biopsy and histology. As the tumor was unresectable, radiotherapy (30 Gy/10 fractions) and dacarbazine administration were performed on the right atrial mass, and pericardial effusion improved.

© 2022 The Author(s).

Published by S. Karger AG, Basel

Introduction

Cardiac metastasis of malignant melanoma is relatively common as part of systemic metastases. However, it mostly occurs in the form of multiple-organ metastasis, and metastatic cases with only cardiac metastasis are extremely rare. Here, we present a case of cardiac metastasis of a malignant melanoma originating from the right nasal cavity presenting with cardiac tamponade detected during treatment with immune checkpoint inhibitors.

Case Report/Case Presentation

The patient was a 66-year-old man diagnosed with malignant melanoma originating from the right nasal cavity 4 years ago. There was no BRAF mutation. The patient was treated with DAV (dacarbazine 120 mg/m², nimustine 60 mg/m², and vincristine 0.6 mg/m²) chemotherapy three times monthly and adjuvant radiotherapy using heavy particle beam (64 Gy/16 fractions) radiation. However, 2 years ago, local recurrence and size of the malignant melanoma in the right nasal cavity increased making it unresectable; therefore, he was thrice treated with a combination therapy of nivolumab 1 mg/kg and ipilimumab 3 mg/kg. Grade 3 colitis, an immune-related adverse reaction, occurred; therefore, the treatment was changed to single-agent nivolumab therapy, and nivolumab was continuously administered for one and a half years. Imaging evaluation using computed tomography (CT) scan conducted every 3 months showed no distant metastasis. General malaise appeared, and the patient visited our department. Chest X-ray revealed cardiomegaly (shown in Fig. 1a), and the patient was diagnosed with cardiac tamponade using echocardiography. He was admitted to the emergency department of our hospital and underwent pericardiocentesis. The CT scan revealed an irregular mass extending from the right atrium to the inferior vena cava (shown in Fig. 1b). A catheter biopsy was performed, and the melanoma cells were stained positively with SOX-10, Melan-A, and HMB-45. The cells were found to proliferate in

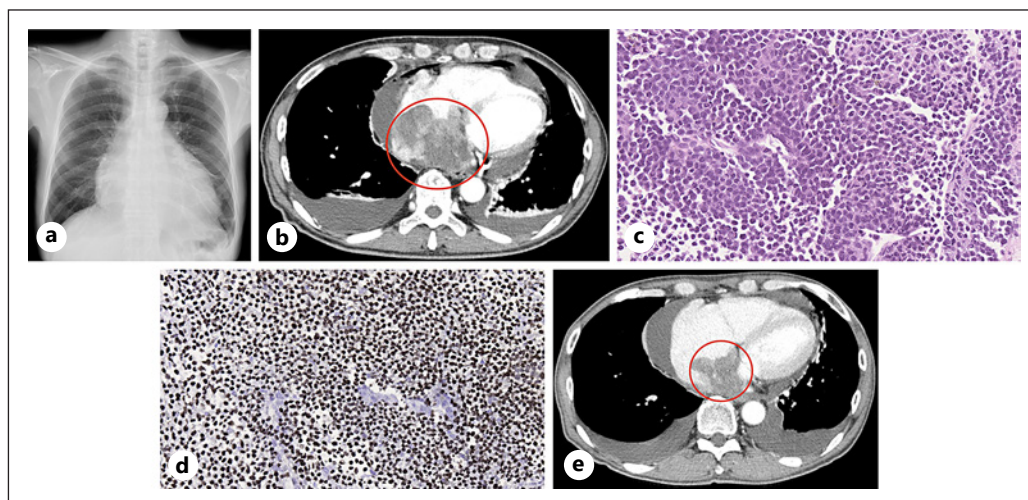


Fig. 1. Examination findings. **a** Chest X-ray on admission: cardiomegaly was observed with a cardiothoracic ratio of 64%. **b** CT images (after drain placement): pericardial effusion and an irregular mass extending from the right atrium to the inferior vena cava were observed. **c, d** Histopathological images of the right atrial mass ($\times 200$). **c** Hematoxylin-eosin staining showing solid proliferating melanoma cells with prominent nucleoli and scattered melanin granules. **d** SOX10 immunopositive melanoma cells. **e** CT images after 3 months: cardiac metastasis had shrunk by 40% in 3 months.

a sheet form, and malignant melanoma metastasis was diagnosed (shown in Fig. 1c, d). As the tumor was unresectable, radiotherapy (30 Gy/10 fractions) was given, and dacarbazine was administered for a total of three times (administration of 1,000 mg/m² at 3-week intervals) on the right atrial metastasis. CT scan performed 3 months later revealed 40% shrinkage in the size of the right atrial mass (shown in Fig. 1e). Pericardial effusion and pleural effusion remained, but the patient was able to perform his daily activities. The patient desired to go home; therefore, he was offered the best supportive care and was discharged.

The protocol for this human study was approved by the Ethics Committee of the Shinshu University Graduate School of Medicine, Matsumoto, Japan (Approval number: 597) and was carried out according to the Helsinki Declaration of 1975, which was revised in 1983. All the methods were performed in accordance with the relevant guidelines and regulations. The patient provided his written informed consent.

Discussion/Conclusion

Metastatic cardiac tumors are 20–40 times more common than malignant tumors originating from the heart [1]. Cardiac metastasis of malignant melanoma is frequent, and analyses of autopsy cases have reported that >50% tumors metastasize to the heart [1, 2]. However, cardiac metastasis is asymptomatic until they reach advanced stage, and only approximately 30% of all patients are diagnosed before death [2]. The common routes of cardiac metastasis of malignant tumors are hematogenous spread, lymphatic spread, and direct infiltration [3]. In the case of malignant melanoma, cases of its spread to the heart intravenously via the right ventricular inflow tract from the lungs, colon, and liver have been reported [3, 4].

A systematic review of 33 malignant melanoma cases with cardiac metastasis showed that the commonest symptom of the cases at the point of detection of the metastasis was dyspnea (36.4%), and the commonest clinical examination finding was tachycardia (24.2%) [5]. Also, the review revealed that the left ventricle (41.9%) was the most common site of cardiac metastasis, followed by the right atrium (35.5%). Furthermore, most common transthoracic echocardiography finding was right ventricular inflow obstruction (27.6%) and valvular dysfunction (24.1%) [5]. In the current case, the patient had no symptom beyond malaise, and imaging findings revealed both the presence of cardiac tamponade and the mass being located at the right atrium extending to the inferior vena cava. Moreover, in this case, imaging showed no metastasis to multiple organs, but metastases to the heart could have occurred through hematogenous spread.

Cases of cardiac metastasis alone without multiple-organ metastasis before death, like in this case, are considered rare. However, there have been reports of cases with symptoms due to cardiac metastasis as the first manifestation, without findings of a primary lesion or metastasis of malignant melanoma. Therefore, even in the absence of a history of malignant melanoma, it should be noted as a cause of cardiac metastasis [6]. Clinical findings that may develop during cardiac metastasis of malignant melanoma include signs of heart failure (dyspnea, lower leg edema, and coughing), various arrhythmias, and chest pain [7]. In reality, the condition is often asymptomatic until it progresses extensively, and by then, it is often at the terminal stage; therefore, relatively few cases are diagnosed with metastases to the heart before death.

Regarding treatment for cardiac metastasis, it has been suggested that surgical removal of tumors to the maximum possible extent may alleviate dyspnea and heart failure [8, 9]. When surgical removal is challenging, the use of immune checkpoint inhibitors, such as ipilimumab and nivolumab, and molecular target drugs, in the presence of BRAF gene mutation, is also considered. In this case, there was no BRAF gene mutation, and there was a history of severe immune-related adverse reactions caused by immune checkpoint inhibitors; therefore, anticancer drugs were selected. Patients with advanced melanoma have been treated with paclitaxel plus carboplatin as

second-line agents with major tumor reduction benefits [10]. Furthermore, the effects of melanoma treatment using a combination of Ankaferd hemostat (ABS) and etoposide have been reported [11]. Newer chemotherapeutic agent for melanoma such as ABS which consists of plant extracts and is ordinarily a hemostatic agent has been shown to suppress the proliferation of melanoma cells [11]. ABS achieves this effect by making some melanoma cell lines such as A2058 more sensitive toward etoposide by altering the basal expression level of genes involved in oxidative phosphorylation pathway and electron transport chain, making it a potential chemotherapeutic agent for malignant melanoma in the future [11]. As these anticancer drugs did not have insurance adaptation in Japan, we used dacarbazine in this case.

Additionally, in this case, radiotherapy was administered in combination with anticancer chemotherapy. The tumor shrank, and the symptoms caused by cardiac tamponade improved. To the best of our knowledge, radiotherapy has been performed for cardiac metastasis of malignant melanoma in only two cases. In one case, normal external radiation (a total of 45 Gy) was used [12], whereas in the other case, stereotactic radiotherapy (30 Gy/5 fractions) was performed, and tumor shrinkage was maintained for 6 months [13]. Malignant melanoma tends to demonstrate a lower sensitivity to radiation than common epithelial cancers [14]. Moreover, metastatic lesions are often less reactive to radiotherapy than primary lesions [14]. However, it has been reported that increasing the exposure dose per fraction enhances the effect of radiotherapy on malignant melanoma [14].

In this case, an anticancer agent (dacarbazine) and radiotherapy were used in combination to treat the cardiac metastasis. To the best of our knowledge, there has been no report on the combination of dacarbazine and radiotherapy to manage cardiac metastasis of malignant melanoma. It has been reported that the simultaneous combination of dacarbazine and radiotherapy does not increase adverse events significantly [15]. In cases where immune checkpoint inhibitors cannot be used because of immune-related adverse reactions, the combination therapy of dacarbazine and radiotherapy could serve as a viable therapeutic option for cardiac metastasis.

In conclusion, it is believed that advancements in immunotherapy will extend the survival time and increase the frequency of detecting cardiac metastasis before death. Even regular CT scan assessment may not be able to detect cardiac tumors early; therefore, detailed examinations using positron emission tomography – CT scan, transthoracic and transesophageal echocardiography, and cardiac magnetic resonance imaging are considered necessary for evaluating cardiac tumors.

Acknowledgement

We thank Crimson Interactive Pvt. Ltd. (Ulatas) – www.ulatus.jp for their assistance in manuscript translation and editing.

Statement of Ethics

The protocol for this human study was approved by the Ethics Committee of the Shinshu University Graduate School of Medicine, Matsumoto, Japan (Approval number: 597), as per the Helsinki Declaration of 1975, which was revised in 1983. Written informed consent was obtained from the patient for the publication of this case report and the accompanying images.

Conflict of Interest Statement

The authors have no conflict of interest to declare.

Funding Sources

This research did not receive any specific grant from funding agencies in the public, commercial, or not-for-profit sectors.

Author Contributions

Kenta Nakamura conceived and designed the study, performed the experiments, analyzed the data, and wrote the paper. Hiroshi Koga, Yuko Takazawa, Toshikazu Omodaka, Yukiko Kiniwa, and Ryuhei Okuyama conceived and designed the experiments and wrote the paper. All the authors have read and approved the final manuscript.

Data Availability Statement

All data that support the findings of this study are included in this article. Further inquiries can be directed to the corresponding author.

References

- 1 Grebenc ML, Rosado de Christenson ML, Burke AP, Green CE, Galvin JR. Primary cardiac and pericardial neoplasms: radiologic-pathologic correlation. *Radiographics*. 2000 Jul;20(4):1073–103.
- 2 Parissis H, Al-Alao BS, Young VK. Case report and literature review: surgical treatment of a right atrial metastatic melanoma from a previously resected “advanced” primary site with regional lymph nodes involvement. *Gen Thorac Cardiovasc Surg*. 2012 Oct;60(10):655–60.
- 3 Emmot WW, Vacek JL, Agee K, Moran J, Dunn MI. Metastatic malignant melanoma presenting clinically as obstruction of the right ventricular inflow and outflow tracts: characterization by magnetic resonance imaging. *Chest*. 1987 Aug;92(2):362–4.
- 4 Ellis CJ, Dennison EM, Simpson IA. Imaging of cardiac metastatic melanoma: trans-oesophageal echocardiography or magnetic resonance imaging? *Int J Cardiol*. 1993 Sep;41(2):176–9.
- 5 Balinski AM, Kerndt CC, Parry NP, Rehman RA, Yeow RY, Hayek SS. Metastatic melanoma of the heart: a systematic review. *J Clin Oncol*. 2020 May;38:e22017.
- 6 Safa H, Glitza Oliva IC. Cardiac metastases in melanoma. *N Engl J Med*. 2019 Feb 28;380(9):858.
- 7 Gulati G, Sharma S, Kothari SS, Juneja R, Saxena A, Talwar KK. Comparison of echo and MRI in the imaging evaluation of intracardiac masses. *Cardiovasc Interv Radiol*. 2004 Jun;27(5):459–69.
- 8 Kontozis L, Soteriou M, Papamichael D, Economides C, Bagdades E, Christou C, et al. Isolated right atrial metastasis of malignant melanoma mimicking a myxoma. *Hellenic J Cardiol*. 2011 Jul;52(3):281–4.
- 9 Gibbs P, Cebon JS, Calafiore P, Robinson WA. Cardiac metastasis from malignant melanoma. *Cancer*. 1999 Nov;85(1):78–84.
- 10 Tomić K, Tica SI, BeriĆ JG, Marijanović I, Lukić B, Miletić D, et al. Complete response of metastatic melanoma to second line chemotherapy with paclitaxel and carboplatin: case report. *Acta Med Acad*. 2018;47(1):82–7.
- 11 Ghasemi M, Okay M, Malkan UY, Turk S, Jabbar J, Hoccoğlu H, et al. Ankaferd hemostat affects etoposide resistance of the malignant melanoma cells. *UHOD*. 2020 Mar;30(1):43–53.
- 12 Magnuson WJ, Halligan JB. Successful treatment of melanoma metastatic to the left atrium using external beam radiation therapy. *Oncology*. 2010 Jun;24(7):650.
- 13 Bonomo P, Cipressi S, Desideri I, Masi L, Doro R, Iermano C, et al. Stereotactic body radiotherapy with CyberKnife for cardiac malignancies. *Tumori*. 2015 Apr;101(3):294–7.
- 14 Carella RJ, Gelber R, Hendrickson F, Berry HC, Cooper JS, RTOG. Value of radiation therapy in the management of patient with cerebral metastases from malignant melanoma: brain metastases study I & II. *Cancer*. 1980 Feb;45(4):679–83.
- 15 Couty E, Vallard A, Sotton S, Ouni S, Garcia MA, Espenel S, et al. Safety assessment of anticancer drugs in association with radiotherapy in metastatic malignant melanoma: a real-life report: radiation/systemic drug combo in metastatic melanoma. *Cancer Chemother Pharmacol*. 2019 Feb;83(5):881–92.