

Received: 2020.04.26

Accepted: 2020.08.10

Available online: 2020.08.21

Published: 2020.10.02

# Isolated Superior Mesenteric Artery Dissection Mimicking Impending Rupture of Abdominal Aortic Aneurysm

## Authors' Contribution:

Study Design A  
Data Collection B  
Statistical Analysis C  
Data Interpretation D  
Manuscript Preparation E  
Literature Search F  
Funds Collection G

ABCDEF 1 **Teiko Kawahigashi**  
BCD 1 **Takashi Kawabe**  
BCDE 2 **Hirokazu Iijima**  
BCDE 2 **Mutsuo Takagi**  
BCD 2 **Tomohiro Noda**  
AE 2 **Kazunao Watanabe**

1 Department of Emergency Medicine, Tokyo Nishi Tokushukai Hospital, Tokyo, Japan

2 Department of Surgery, Tokyo Nishi Tokushukai Hospital, Tokyo, Japan

**Corresponding Author:** Teiko Kawahigashi, e-mail: [teikokawahigashi@gmail.com](mailto:teikokawahigashi@gmail.com)

**Conflict of interest:** None declared

**Patient:** Male, 66-year-old  
**Final Diagnosis:** Isolated superior mesenteric artery dissection  
**Symptoms:** Abdominal and back pain  
**Medication:** —  
**Clinical Procedure:** —  
**Specialty:** Surgery

**Objective:** Unusual clinical course

**Background:** Isolated superior mesenteric artery dissection (SMAD) is a rare vascular disease that is difficult to diagnose. We report a case of SMAD in a patient with an abdominal aortic aneurysm (AAA) that mimicked an impending rupture of the AAA. In addition, we describe several clinical biases that contributed to the delayed diagnosis.

**Case Report:** A 66-year-old man presented with a 3-day history of abdominal pain, without a history of trauma, that worsened gradually and caused him to visit our hospital. The patient's medical history included an AAA under observation. The patient was well oriented and initially remained hemodynamically stable, and the abdomen was soft and non-tender on palpation. An emergency contrast-enhanced computed tomography (CT) scan confirmed a 44-mm AAA without any leakage, but with an isolated SMAD. His previous physician confirmed there was no change in the AAA size since 3 months prior to hospital admission. Thus, the symptoms were caused by the isolated SMAD. The patient showed improvement with pain-relieving and antihypertensive management, without anticoagulation therapy or revascularization, and was discharged on day 25 of admission without any complications.

**Conclusions:** The misdiagnosis in this case was attributable to several clinical biases, including search satisfaction, Sutton's slip, and anchoring bias. Physicians should guard against presumptive diagnoses based on patient symptoms or initial plausible findings and instead pursue a thorough workup to reach a definitive diagnosis.

**MeSH Keywords:** Aortic Aneurysm, Abdominal • Diagnostic Errors • Emergency Medicine • Mesenteric Artery, Superior

**Full-text PDF:** <https://www.amjcaserep.com/abstract/index/idArt/925464>



1006



2



6



## Background

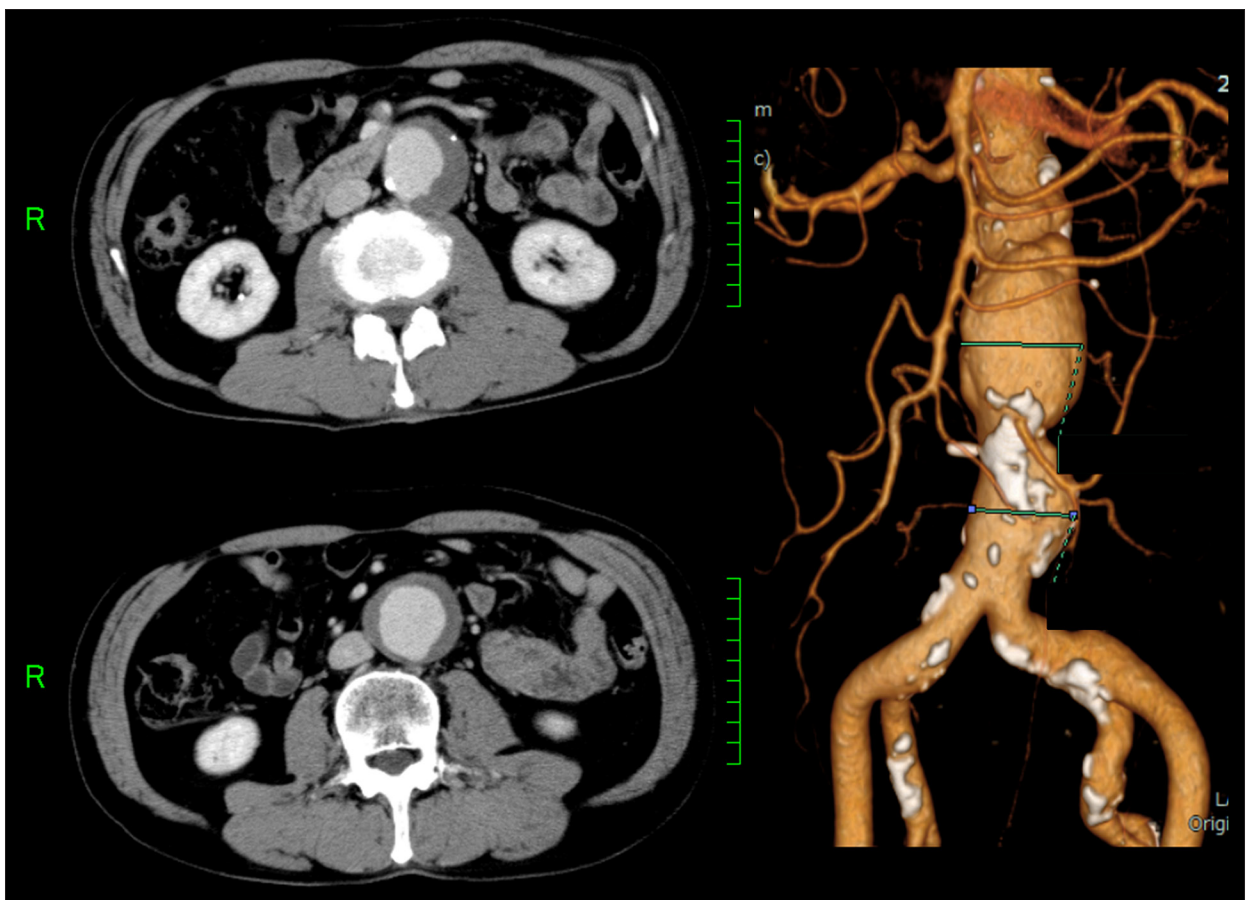
Isolated superior mesenteric artery dissection (SMAD) is a difficult to diagnose and rare vascular disease. This case of SMAD with abdominal aortic aneurysm (AAA) mimicked an impending rupture of AAA. Physicians should guard against presumptive diagnoses based on patient symptoms or initial plausible findings and instead pursue a thorough workup until a definitive diagnosis can be made.

## Case Report

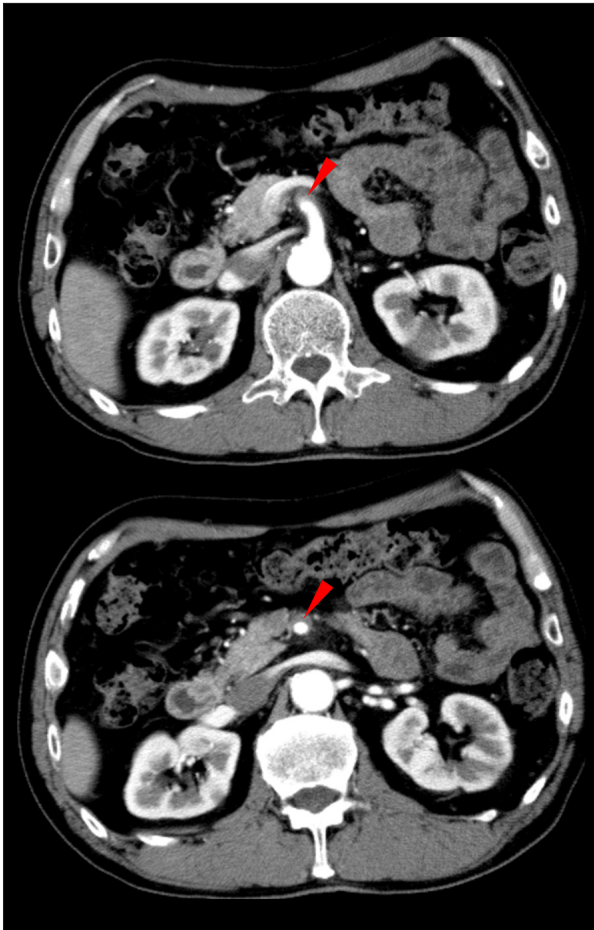A 66-year-old Japanese man presented to the emergency department with a 3-day history of back pain localized to the small of the back that was followed by mild abdominal pain, which worsened gradually and led to his hospital visit. There was no history of trauma. The pain was continuous, without associated fever, nausea, vomiting, or other bowel symptoms. The patient's medical history included hypertension, tobacco use, including as an active and ex-smoker with  $\geq 10$  pack-years of cigarette smoking, and an AAA, which was under observation.

On examination, the patient appeared well oriented and initially remained hemodynamically stable (blood pressure, 156/101 mmHg; heart rate, 72 beats per min). The abdomen was soft, and a palpable, pulsatile abdominal mass was noted. The back pain was localized to the T12–L1 region, but there was no detectable tenderness. Routine laboratory tests were not specific for any findings. Emergency contrast-enhanced computed tomography (CT) scanning was undertaken for the assessment of a suspected AAA rupture. The scan revealed a 44-mm AAA without any leakage (Figure 1).

Since there was no evidence of a rupture, the patient was initially diagnosed with impending rupture of an AAA. A surgical consultation was ordered, and the surgeon indicated a SMAD on the CT images (Figure 2, red arrow). To verify the possibility of AAA rupture, we obtained the patient's previous medical record and confirmed there was no change in the AAA size from that measured 3 months earlier by a CT scan without contrast (the last contrast-enhanced CT scan had been performed in 2011). Therefore, his symptoms were inferred to have been caused by the isolated SMAD.



**Figure 1.** Contrast-enhanced CT scanning revealed an abdominal aortic aneurysm (AAA). The maximum short-axis diameter of the AAA is 44 mm. No evidence of rupture is seen.



**Figure 2.** Contrast-enhanced CT scanning showed an superior mesenteric artery dissection (SMAD) without evidence of aortic involvement.

The patient was admitted to the intensive care unit and treated conservatively with bowel rest, fluid resuscitation, and analgesic and antihypertensive medication. The back pain improved gradually. On day 3 of admission, ultrasonographic assessment confirmed the blood flow of the SMA, without signs of progressive true lumen narrowing, and the patient was transferred to the general ward. On day 10 of admission, the patient underwent another contrast-enhanced CT scan, which showed maintenance of true lumen patency of the SMA. The patient remained stable and recovered without any complications. He was discharged on day 25 of admission.

## Discussion

Isolated SMAD is a relatively rare vascular disease that presents as a case of acute abdominal pain and can have significant clinical outcomes, such as bowel ischemia [1–4]. In recent years, an increasing number of SMAD diagnoses have been reported, which is possibly attributable to advances in imaging

technology and the increasing use of diagnostic imaging studies for the assessment of patients who present with abdominal pain [1,2,4]. The clinical presentation of SMAD ranges from asymptomatic incidental diagnosis to acute bowel ischemia to fatal SMA aneurysmal rupture. In all of these cases, acute or chronic epigastric and upper left quadrant pain are common symptoms [3].

Herein, we present a case of SMAD that was initially misdiagnosed as a ruptured AAA and subsequently diagnosed as a SMAD. We also present the outcome of clinical management. Delay in treatment can lead to poor prognosis in patients with SMAD. A previous study reported a very poor prognosis (100% mortality rate) of SMAD prior to 1972; however, the prognosis has improved significantly since 1975, with the survival of all reported patients [5]. One of the reasons for this improvement in prognosis could be early diagnosis with CT and ultrasonographic imaging [5]. Although the diagnosis of SMAD is often challenging because of its rarity, this case was especially complicated because of the patient's history of an AAA under observation. There are several types of clinician biases that likely led to a delay of his proper diagnosis [6]. Because of search satisfaction, we stopped our investigation into other findings once we discovered an initial plausible explanation, the AAA. We missed the SMAD which was the more critical and actual origin of his symptoms. There was also evidence of Sutton's slip, as we linked his symptoms to an obvious problem (the AAA) and did not consider other possible causes in his differential diagnosis. We determined a diagnosis of an impending AAA rupture despite the poor evidence. Furthermore, there was decidedly some anchoring bias, as we could not dismiss the AAA being the primary cause of his presenting complaint. AAA rupture being one of the most fatal surgical emergencies made it more difficult for us to discard AAA as the cause of his acute illness. Fortunately, the patient was treated appropriately when the surgeon arrived at the true diagnosis. However, our misdiagnosis could have had serious consequences because a delayed diagnosis of SMAD is known to lead to a poor prognosis, as mentioned above. Radiological imaging, such as ultrasonography and contrast-enhanced CT scanning, plays a key role in diagnosis, and diagnosticians should pay considerable attention to abnormalities of the SMA during radiological assessment because it is often missed, as seen in the present case.

There are no clear guidelines for the treatment of patients with SMAD. The available therapeutic options include conservative therapy, anticoagulants, and surgical intervention [1–3]. We chose conservative therapy without anticoagulation in this patient because there was no evidence of bowel infarction, and the treatment was successful.

## Conclusions

Optimal management of SMAD needs to be elucidated in further research. Preexisting and documented large-vessel aneurysms induce the possibility of misdiagnosis of other arterial dissections. There is a demonstrated need for doctors to consciously eschew clinical biases that could prevent early diagnosis of an actual cause and provision of appropriate treatment.

## References:

1. Yun WS, Kim YW, Park KB et al: Clinical and angiographic follow-up of spontaneous isolated superior mesenteric artery dissection. *Eur J Vasc Endovasc Surg*, 2009; 37(5): 572–77
2. Zerbib P, Perot C, Lambert M et al: Management of isolated spontaneous dissection of superior mesenteric artery. *Langenbecks Arch Surg*, 2010; 395(4): 437–43
3. Daoud H, Abugroun A, Subahi A, Khalaf H: Isolated superior mesenteric artery dissection: A case report and literature review. *Gastroenterology Res*, 2018; 11(5): 374–78
4. Cho BS, Lee MS, Lee MK et al: Treatment guidelines for isolated dissection of the superior mesenteric artery based on follow-up CT findings. *Eur J Vasc Endovasc Surg*, 2011; 41: 780–85
5. Suzuki S, Furui S, Kohtake H et al: Isolated dissection of the superior mesenteric artery: CT findings in six cases. *Abdom Imaging*, 2004; 29(2): 153–57
6. Wellberg C: Flaws in clinical reasoning: A common cause of diagnostic error. *Am Fam Physician*, 2011; 84: 1042–48

## Acknowledgements

We would like to thank Editage ([www.editage.jp](http://www.editage.jp)) for English language editing.

## Department and Institution where work was done

Departments of Emergency Medicine and Surgery, Tokyo Nishi Tokushukai Hospital, Tokyo, Japan.

## Conflicts of interest

None.