



Published in final edited form as:

*Interdiscip Neurosurg.* 2020 June ; 20: . doi:10.1016/j.inat.2020.100689.

## Concurrent presentation of brain arteriovenous malformation, peripheral arteriovenous malformation, and cerebellar astrocytoma: Case report

Ayushi Gautam<sup>a</sup>, Zhengda Sun<sup>b</sup>, Ethan Winkler<sup>f</sup>, Hua Su<sup>b</sup>, Timothy H. McCalmont<sup>c</sup>, Helen Kim<sup>b</sup>, Tarik Tihan<sup>c</sup>, William Y. Hoffman<sup>d</sup>, Chris F. Dowd<sup>a</sup>, Ilona J. Frieden<sup>e</sup>, Daniel L. Cooke<sup>a,\*</sup>

<sup>a</sup>Department of Radiology and Biomedical Imaging, Division of Neurointerventional Radiology, University of California, San Francisco School of Medicine, San Francisco, CA, United States

<sup>b</sup>Center for Cerebrovascular Research, Department of Anesthesia and Perioperative Care, University of California, San Francisco, San Francisco, CA, United States

<sup>c</sup>Department of Pathology, University of California, San Francisco, San Francisco, CA, United States

<sup>d</sup>Department of Plastic and Reconstructive Surgery, University of California, San Francisco, San Francisco, CA, United States

<sup>e</sup>Department of Dermatology, University of California, San Francisco, CA, United States

<sup>f</sup>Department of Neurological Surgery, University of California, San Francisco, CA, United States

### Abstract

**Background:** We report a rare case of a 19-year-old female progressively affected by a peripheral arteriovenous malformation (pAVM), a midline cerebellar astrocytoma, and a brain arteriovenous malformation (bAVM).

**Case description:** She presented with a pulsatile mass on her left cheek, which was classified as a pAVM through angiography. Following treatment with embolization and surgical resection, she returned with enlargement of the mass and imaging incidentally identified a cerebellar astrocytoma. Suboccipital craniotomy, C1 laminectomy, and endoscopic third ventriculostomy were subsequently performed. She was later treated again for growth of her pAVM, and angiography revealed the presence of a left temporal bAVM, which was resected via a pterional craniotomy.

**Conclusions:** Pathological staining identified activation of mTOR and RAS/MAPK pathway in the patient's pAVM and bAVM tissue samples. Furthermore, genetic sequencing demonstrated an

---

This is an open access article under the CC BY-NC-ND license (<http://creativecommons.org/licenses/by-nc-nd/4.0/>).

\*Corresponding author at: Department of Radiology and Biomedical Imaging, University of California, San Francisco, 505 Parnassus Ave., San Francisco, CA 94143, United States. Daniel.Cooke@ucsf.edu (D.L. Cooke).

Declaration of Competing Interest

The authors declare that they have no known competing financial interests or personal relationships that could have appeared to influence the work reported in this paper.

activating MAPK21 (K57N) mutation in the pAVM and a gain of distal chromosome 7q in the pilocytic astrocytoma. No germline mutation was identified to explain all pathologies. This case demonstrates the need for continued development and further integration of multi-disciplinary genetic, radiological, and neurological treatment teams to effectively care for such complex presentations.

## Keywords

Arteriovenous malformations; Cerebellar tumors; RAS/MAPK

---

## 1. Introduction

Arteriovenous malformations (AVM) are characterized by arteriovenous shunts between arteries and veins without intervening capillary systems. Such shunting may result in high-flow related arteriopathy (e.g. aneurysm) and supra-physiologic venous pressures, both states that may contribute to regional tissue compromise resulting in hemorrhage and/or ischemia. In the setting of brain AVMs (bAVM), these vascular malformations occur in 10–18 per 100,000 adults, and account for a third of intracerebral hemorrhage seen in young adults. As AVMs can occur at various locations in the body, they may be categorized as either arising within the central nervous system (most often in the brain, bAVM) or outside the CNS (peripheral, pAVMs).

Many studies and case reports have shed light on the divergent characteristics of both AVM types. For example, the largest differences include higher rates of hemorrhage within bAVMs and local ischemia in pAVMs. Additionally, bAVMs are more often primarily treated with surgical resection given their greater tendency to be discrete and non-infiltrative into the surrounding tissue while pAVMs are palliated using embolization [6]. As such studies focused on either bAVMs or pAVMs, few explored possible similarities between both AVM types, beyond their shared morphological and histological features. However, advances in molecular and genetic characterization of AVMs can help shed light on potential common pathways involved in AVM development and targets for future therapy. To illustrate this concept, we describe a rare co-occurrence of bAVM and pAVM, as well as a cerebellar tumor, in a single patient, and report the results of immunohistochemistry and sequencing studies on the patients' multiple lesions.

## 2. Case report

### 2.1. History

A 19-year-old female presented with a pulsatile mass on her left cheek, present since childhood, though had considerably grown more recently prompting evaluation. Diagnostic angiography demonstrated a high-flow facial AVM fed by the superior division of transverse facial and draining into the internal jugular vein (Fig. 1). Two embolization procedures were performed to treat the AVM and she subsequently underwent surgical excision of the mass. Though pulsation remained in her masseter muscle, due to concerns for facial nerve function, it was not pursued during the excision.

After five years, the patient presented with regrowth of the pAVM to its original size over the zygomatic arch, accompanied by symptoms of pain while chewing and light-headedness in a semi-recumbent position. MR imaging revealed a recurrence of the lesion primarily in the left masseter muscle extending over the zygomatic arch. Imaging also incidentally revealed a cerebellar mass, which was identified to be a midline cerebellar pilocytic astrocytoma, WHO grade 1 (Fig. 2). Suboccipital craniotomy and C1 laminectomy were performed without complications, and resulted in complete resection of the midline mass. However, post-operative imaging revealed hydrocephalus of the patient's lateral and third ventricles, which was then treated with an endoscopic third ventriculostomy.

Three years later, the patient returned with enlargement of the left facial AVM. Again she underwent angiography, embolization, and surgical resection without complications and with preservation of her facial nerve. Of note, however, was the presence of a left temporal polar AVM, that, in retrospect, was present on her original angiogram (Fig. 3). She consequently underwent a left pterional craniotomy without complications.

At the patient's last point of follow-up one year ago, she was doing well and without major complications from her tumor, pAVM or bAVM.

## 2.2. Pathological findings

AVM tissue samples were analyzed using immunohistochemistry. Paraffin and frozen AVM tissue sample blocks were stained with CD31 antibody, p-S6 and pERK1/2 rabbit monoclonal antibodies. H&E staining was also applied to check tissue morphology. Sections were reviewed in a blinded fashion as to their anatomic location. Staining revealed that both samples were positive for pERK1/2, which are markers of mTOR and RAS/MAPK pathway activation (Fig. 4).

## 2.3. Genomic sequencing findings

In addition to pathological analysis, targeted sequencing of bulk tissue DNA was performed using the UCSF 500 Cancer Gene Panel, which tests for the coding regions of approximately 480 cancer genes as well as select intronic areas. The pilocytic astrocytoma displayed a gain of distal chromosome 7q which contains the *BRAF* locus, but there was no evidence of *BRAF* fusion or point mutation. No pathogenic alterations were identified in bAVM tissue, while an activating MAP2K1 (K57N) mutation was identified in the pAVM (Table 1).

## 3. Discussion

We present a rare case of co-occurring sporadic brain and peripheral AVMs, in addition to a cerebellar pilocytic astrocytoma. Few studies have reported such a set of sporadic malformations in a single patient. Our clinical, pathological and genetic analysis of this unique case offers the field the following key insights into the study and treatment of such sporadic vascular malformations:

1. Heightened understanding of the molecular pathways involved in sporadic vascular malformation pathogenesis.

2. Implications for the application of precision medicine to vascular anomalies treatments.
3. Value of interdisciplinary methodology in the study of such rare presentations.

### 3.1. Heightened understanding of molecular pathways involved in sporadic malformation pathogenesis

**3.1.1. Previous multisite AVM presentations**—Synchronous multisite AVM and tumoral presentation is more commonly associated with certain genetic disorders such as Hereditary Hemorrhagic Telangiectasia (HHT) (e.g. brain and pulmonary AVM), or RASA1 (e.g. skin and brain AVM), or PTEN (e.g. peripheral AVM and hemangiomas) syndromes. For example, HHT disorder, linked to germline mutations in ENG1, SMAD4, and ACVRL1 genes, presents in the form of multiple peripheral AVMs in pulmonary and hepatic areas, telangiectasia, epistaxis, and brain AVMs. Moreover, patients with capillary malformation-arteriovenous malformation syndrome (CM-AVM) present with germline mutations in RASA1 (CM-AVM1) and EPHB4 (CM-AVM2), small multifocal CMs and an increased risk of developing AVMs in the brain, spinal cord, face, neck and extremities. In contrast to patients with HHT and CM-AVM, our patient did not present with symptoms indicative of such genetic disorders, and was affected by sporadic, not germline, AVMs.

**3.1.2. Current understanding of sporadic AVM pathology**—Unlike germline AVMs, sporadic AVMs do not arise due to germline mutations and the molecular mechanisms are still poorly understood. Studies have suggested a pathogenic role of mutations in VEGF, Tie/Angiopoietin, matrix metalloproteinases, and integrin, as well as other single-nucleotide polymorphisms in ALK1 and ENG1. Increased mTOR and RAS-MAPK pathway expression has been identified as a characteristic of AVMs, specifically of brain AVMs [2,3,5,8]. Additional studies have suggested that mutations in the RAS-MAPK pathway, including KRAS, NRAS, BRAF, MAP2K1 and RASA1 mutations, are involved in pathogenesis of bAVMs [2,5,8]. Somatic MAP2K1 mutations have also been implicated in development of extracranial AVMs [3]. While studies have not shown mutations that cause concurrent presentation of sporadic pAVM and bAVM lesions, patients with HHT, caused by mutations in ENG, SMAD4 or ACVRL1 genes, may present with both lesions. Previous case reports have documented the co-occurrence of bAVM and astrocytoma, but the pathogenesis of such co-occurring lesions is unclear [7].

**3.1.3. Takeaways from genetic and pathological analysis of the Patient's lesions**—As the molecular pathophysiology of AVMs has slowly emerged, findings from recent studies mirror our identification of sporadic mutations in the patient's pAVM and bAVM, as well as cerebellar tumor. Through pathological staining and genomic sequencing, we identified that all three of the patient's sporadic lesions demonstrate mutations that target the RAS/MAPK pathway. Pathological staining revealed that both the pAVM and bAVM tested positive for markers of mTOR and RAS/MAPK pathway activation. In addition, genomic sequencing identified an activating MAP2K1 (K57N) mutation in the pAVM, and a copy gain of BRAF in the pilocytic astrocytoma. It is important to note that BRAF mutations have been widely used as diagnostic markers for pilocytic astrocytomas, and have been implicated in the development of these tumors [4].

No potential germline alterations were detected in genomic testing of the patient's tumor, and we understand the possibility that all three lesions may coincidentally activate RAS/MAPK pathways. However, it is important to acknowledge a limitation in the extent of pathways covered by our germline testing. Our genomic sequencing tested for germline mutations in the exons of 500 genes, but this panel did not cover variant AVM germline pathways, such as TEK, GLMN, EPHB4, KRIT1, CAMTA1, FOS and GNA14. Thus, we cannot exclude potential germline mutations in these genes within the patient's samples.

Nonetheless, the findings from our analysis, as well as recent literature, suggest that mutations in the RAS/MAPK pathway and heightened RAS/MAPK activity play a role in the sporadic development. Moreover, the detection of increased mTOR and RAS/MAPK activity in both pAVM and bAVM samples suggests a potential common molecular feature across both AVM types.

### **3.2. Implications for the application of precision medicine paradigm to vascular anomalies treatment**

The findings from our study can inform the use of precision medicine paradigms for vascular anomalies, such as AVMs. Precision medicine has become well-established in the field of cancer treatment, and our study highlights the great potential for this model to be applied to AVM treatment.

Presently, treatment guidelines remain applicable to brain and peripheral AVMs regardless of genetic status and include embolization, sclerotherapy, stereotactic surgery, surgical resection or a combination thereof [6]. However, it is commonly known that these treatments are not always effective or durable, as evidenced by the repeated growth of this patient's pAVM after several procedures. Such lesions can be more responsive to molecular therapies that target molecular pathways ranging from RAS/MAPK to PI3K/mTOR cascades.

A given molecular therapy may effectively treat one patient's lesion while not significantly affecting another patient's lesion, as these AVMs can arise from different mutations. Therefore, matching genetics to treatments is crucial. The precision medicine paradigm rests on this tenet of tailoring treatments to a patient's genetic status. Genotyping tissue samples from a lesion can reveal a specific mutation, and then molecular therapies targeting that particular pathway can be administered to the patient. While this approach is promising, acquiring tissue samples of lesions inside the CNS can present significant risks and complications to patient. As a result, difficulties associated with genotyping intracranial and spinal lesions poses a challenge to such an application of precision medicine.

Our study offers a solution that supports the integration of genetics into peripheral and brain AVM treatment. Through our genetic analysis, we identified that both the patient's pAVM and bAVM demonstrated altered RAS/MAPK pathway activation. Given this similarity between the peripheral and brain AVMs, our findings suggest that AVMs outside of the CNS may be representative of their intracranial counterparts. This provides clinicians with the opportunity to utilize peripheral tissue for genotyping and treatment decisions for CNS-related lesions. This approach circumvents the significant risks associated with genotyping CNS-related tissue, while supporting the integration of genetics into treatment.

Moreover, our analysis underscores the potential for RAS/MAPK and PI3K/mTOR pathways to be targets of molecular therapies involved in the treatment of both AVM types. While our study and recent literature have implicated these pathways in the pathogenesis of sporadic AVMs, the field has also previously identified RAS/MAPK and PI3K/mTOR pathways as key regulators of vascular growth and organization. Since then, MEK inhibitors and mTOR inhibitors have begun to be used to treat AVMs [1,2,8]. Specifically, studies have shown that delivery of MEK inhibitors to AVM endothelial cells led to reduced ERK activity and decreased vessel abnormalities [2,8]. Delivery of rapamycin, an mTOR inhibitor, in prospective clinical trials also shows positive effects on patients with pAVMs [1]. In patients with MAP2K1 mutations, which lead to increased MEK1 activity, MEK inhibitors (e.g. Trame-tinib) have been reported to have better success in treatment of pAVM than the use of anti-angiogenic drugs (e.g. Sirolimus) that target the mTOR pathway.

### 3.3. The value of interdisciplinary approaches in the study of such rare presentations

In order to understand this patient's presentation of multiple AVMs and cerebellar tumor, we called upon approaches from multiple disciplines, including genetics, pathology, neurology and interventional radiology, among others. The involvement of multiple specialties in this study reflects the course of this patient's clinical care at our Birth Marks and Vascular Anomalies Clinic. Given the variable locations of vascular anomalies, ranging from a patient's left cheek to temporal lobe, treatment of such presentations requires patients to consult with several different specialists. At this clinic, a group of dermatologists, plastic surgeons, interventional radiologists and otolaryngologists work together to create interdisciplinary treatment plans and research vascular anomalies.

Whether in the clinic or in this study, findings from each specialty significantly contribute to developing a thorough understanding of patients' vascular anomalies. As evidenced by our study, pathological and genetic analyses provide physicians and researchers with nuanced insights into the pathogenesis of AVMs and the diagnosis of hereditary disorders. Even more so, uncovering key mutations and pathways involved a patient's vascular anomalies can help guide the development of novel medical therapies, such as MEK and mTOR inhibitors, and influence the treatment of such lesions. In addition, fields such as radiology, neurology and plastic surgery provide key clinical findings relevant to patients' diagnosis and treatment.

Throughout our study, we found that the intersection of treatment and research teams from these specialties can have significant benefits for both patients and the field as a whole. Integrating a diverse range of specialists in a clinical setting can provide patients with more specialized treatment plans, involving a combination of medical therapies based on genetic analysis and surgical procedures stemming from clinical insights. Moreover, incorporating methods from these different fields into studies such as our case report can help the field understand and learn from rare case presentations.

## 4. Conclusion

Our study revealed the activation of mTOR and RAS/MAPK pathways in the patient's bAVM and pAVM, as well as an activating MAPK21 mutation in the pAVM and gain of distal chromosome 7q in the cerebellar tumor. Although no germline mutations were

identified, it is important that we learn from this rare presentation of both bAVM and pAVM. From the patient's course of clinical care to our pathological and genomic analyses, this study highlights the promising application of precision medicine to vascular anomalies treatment, as well as the intersection between the genetic, radiological, and neurological treatment teams to care for such clinical presentations.

## Funding sources

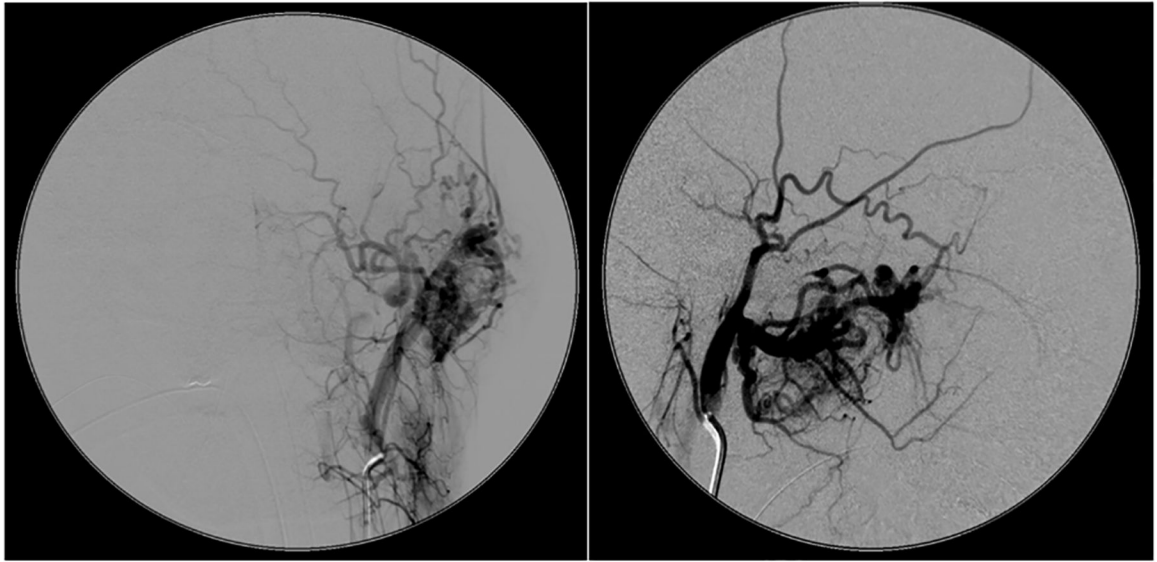
This work was funded by the UCSF Department of Radiology and Biomedical Imaging.

## Abbreviations:

<b>AVM</b>	arteriovenous malformation
<b>bAVM</b>	brain arteriovenous malformation
<b>CM-AVM</b>	capillary malformation-arteriovenous malformation syndrome
<b>HHT</b>	hereditary hemorrhagic telangiectasia
<b>pAVM</b>	peripheral arteriovenous malformation

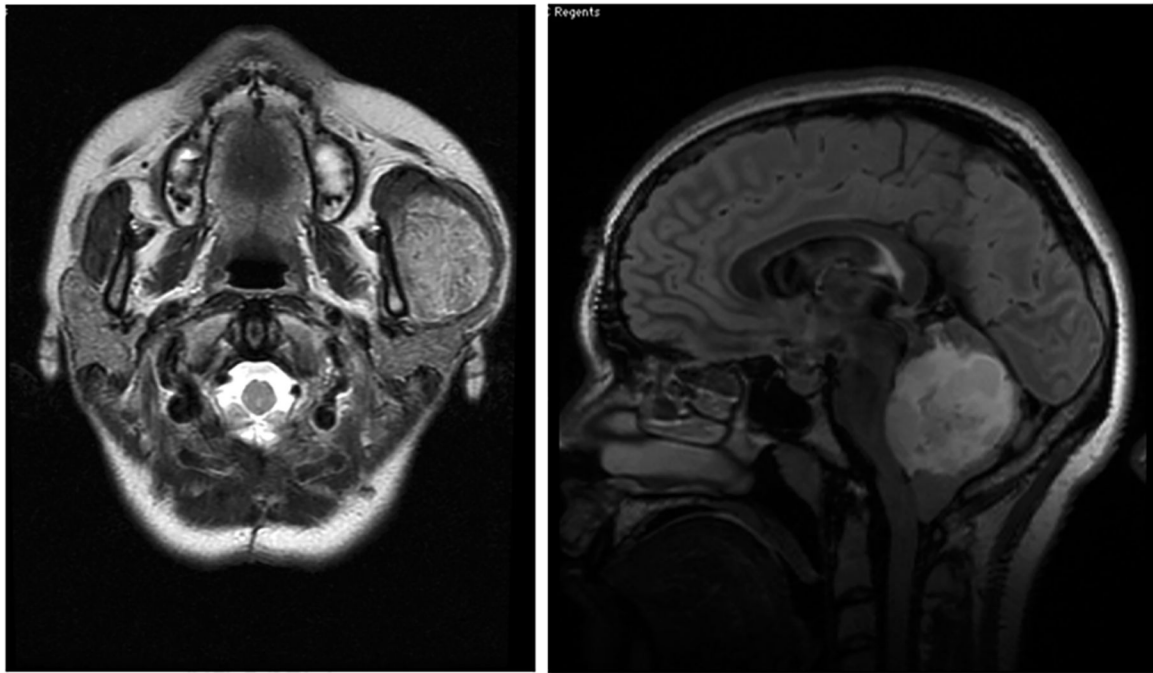## References

- [1]. Adams DM, Trenor CC III, Hammill AM, Vinks AA, Patel MN, Chaudry G, et al., Efficacy and safety of sirolimus in the treatment of complicated vascular anomalies, *Pediatrics* 137 (2016) 1–10.
- [2]. Al-Olabi L, Polubothu S, Dowsett K, Andrews KA, Stadnik P, Joseph AP, et al., Mosaic RAS/ MAPK variants cause sporadic vascular malformations which respond to targeted therapy, *J. Clin. Investig* 4 (2018) 1496–1508.
- [3]. Cuoto JA, Huang AY, Konczyk DJ, Goss JA, Fishman SJ, Mullikan JB, et al., Somatic MAPK21 mutations are associated with extracranial arteriovenous malformation, *Am. J. Hum. Genet* 100 (2017) 546–554. [PubMed: 28190454]
- [4]. Faulkner C, Ellis H, Shaw A, Penman C, Palmer A, Wragg C, et al., BRAF fusion analysis in pilocytic astrocytomas: KIAA1549-BRAF 15–9 fusions are more frequent in the midline than within the cerebellum, *J. Neuropathol. Exp. Neurol* 74 (2015) 867–872. [PubMed: 26222501]
- [5]. Hong T, Yan Y, Li J, Radovanovic I, Ma X, Shao YW, et al., High prevalence of KRAS/BRAF somatic mutations in brain and spinal cord arteriovenous malformations, *Brain* 142 (2019) 23–34. [PubMed: 30544177]
- [6]. Hyodoh H, Hori M, Akiba H, Tamakawa M, Hyodoh K, Hareyama M, Peripheral vascular malformations: imaging, treatment approaches, and therapeutic issues, *Radiographics* 25 (2005) 159–171.
- [7]. Naga ska E, Matyja E, Pucko E, Zabek M, The coexistence of pleomorphic xan-thoastrocytoma and arteriovenous malformation A case report, *Folia Neuropathol.* 51 (2013) 269–274. [PubMed: 24114645]
- [8]. Nikolaev SI, Vetiska S, Bonilla X, Boudreau E, Jahuiainen S, Jahromi B, et al., Somatic activating KRAS mutations in arteriovenous malformations of the brain, *N Engl. J. Med* 378 (2018) 250–261. [PubMed: 29298116]

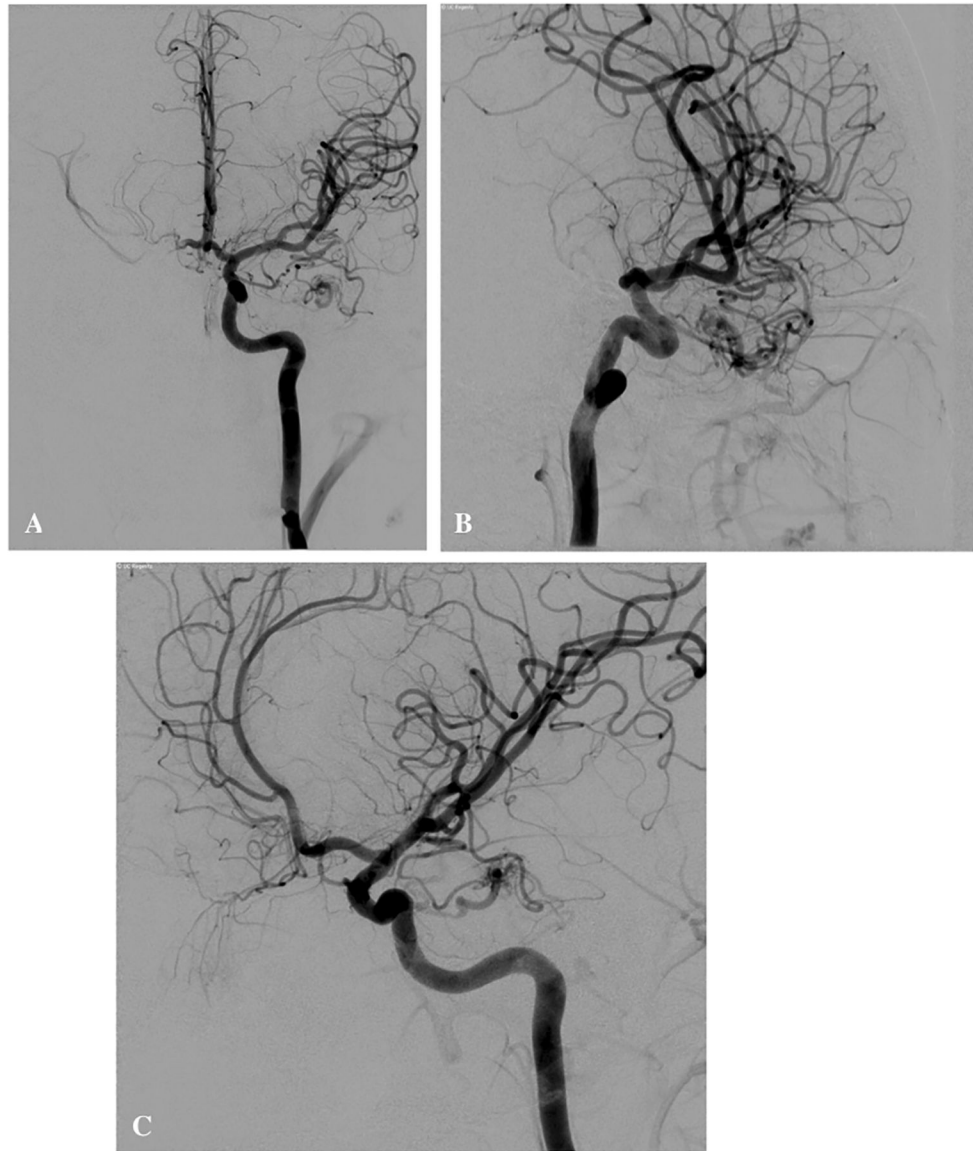


**Fig. 1.** Peripheral AVM Angiography. Both images depict angiographic imaging of the patient's left facial pAVM.

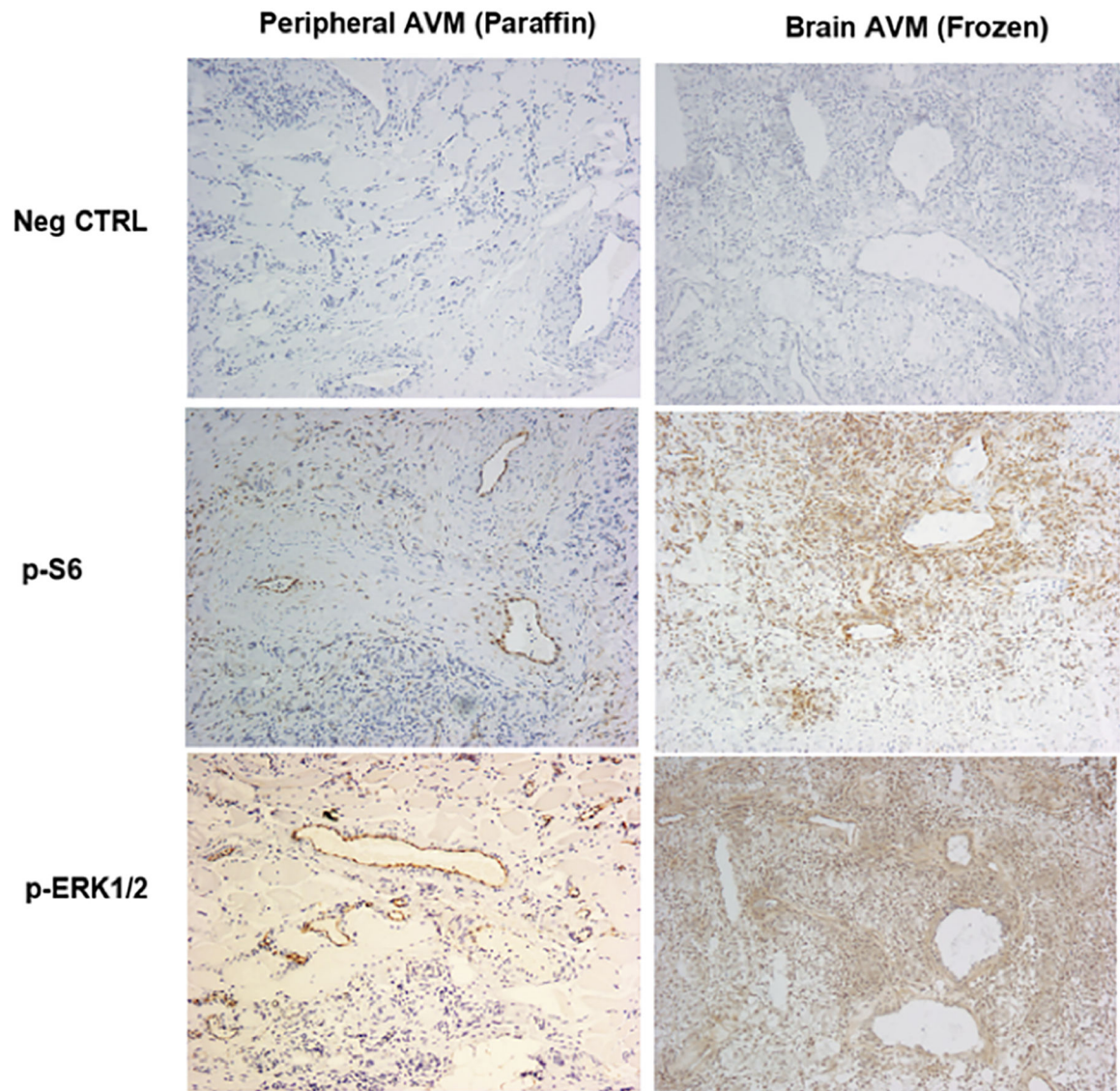




**Fig. 2.** MR Images of Patient's Peripheral AVM and Cerebellar Lesions. On the left, patient's left facial pAVM is visualized with MR imaging. On the right, patient's cerebellar pilocytic astrocytoma is depicted.



**Fig. 3.** Brain AVM Angiography. *A*, *B*, and *C* depict angiographic imaging of the patient’s brain AVM.



**Fig. 4.** Immunohistochemistry staining analysis of patient's peripheral and brain AVM tissues. Both peripheral and brain AVM tissue samples showed positive staining for Ps6 and pERK1/2 markers, which suggests that both lesions had increased levels of mTOR and RAS-MAPK pathway expression.

**Table 1**

Pathological and Genetic Analysis of Patient's Lesions. Pilocytic astrocytoma displayed gain of BRAF mutation and pAVM displayed activating MAP22K1: K72N mutation, while bAVM showed no pathogenic alterations.

Lesion	Location	Pathological Staining	Genomic Sequencing
Pilocytic astrocytoma	Cerebellum	–	Gain of distal chromosome 7q, but no V600E mutation or fusion, no detectable FGFR1 alterations and no NF1 alterations.
bAVM	Left temporal lobe	Positive for markers of mTOR and RAS/MAPK pathway activation	No pathogenic mutations identified.
pAVM	Left masseter muscle	Positive for markers of mTOR and RAS/MAPK pathway activation	Activating MAP2K1: K57N mutation.