

## Novel three-dimensional position analysis of the mandibular foramen in patients with skeletal class III mandibular prognathism

Sang-Hoon Kang<sup>1,2,\*</sup>, Yeon-Ho Kim<sup>1</sup>, Yu-Jin Won<sup>1</sup>, Moon-Key Kim<sup>1,2</sup>

<sup>1</sup>Department of Oral and Maxillofacial Surgery, National Health Insurance Service Ilsan Hospital, Goyang, Korea

<sup>2</sup>Department of Oral and Maxillofacial Surgery, College of Dentistry, Yonsei University, Seoul, Korea

### ABSTRACT

**Purpose:** To analyze the relative position of the mandibular foramina (MnFs) in patients diagnosed with skeletal class III malocclusion.

**Materials and Methods:** Computed tomography (CT) images were collected from 85 patients. The vertical lengths of each anatomic point from the five horizontal planes passing through the MnF were measured at the coronoid process, sigmoid notch, condyle, and the gonion. The distance from the anterior ramus point to the posterior ramus point on the five horizontal planes was designated the anteroposterior horizontal distance of the ramus for each plane. The perpendicular distance from each anterior ramus point to each vertical plane through the MnF was designated the horizontal distance from the anterior ramus to the MnF. The horizontal and vertical positions were examined by regression analysis.

**Results:** Regression analysis showed the heights of the coronoid process, sigmoid notch, and condyle for the five horizontal planes were significantly related to the height of the MnF, with the highest significance associated with the MnF-mandibular plane (coefficients of determination ( $R^2$ ): 0.424, 0.597, and 0.604, respectively). The horizontal anteroposterior length of the ramus and the distance from the anterior ramus point to the MnF were significant by regression analysis.

**Conclusion:** The relative position of the MnF was significantly related to the vertical heights of the sigmoid notch, coronoid process, and condyle as well as to the horizontal anteroposterior length of the ascending ramus. These findings should be clinically useful for patients with skeletal class III mandibular prognathism. (*Imaging Sci Dent* 2016; 46: 77-85)

**KEY WORDS:** Mandibular Nerve; Mandibular Osteotomy; Imaging, Three-Dimensional; Surgery, Computer-Assisted

### Introduction

Three-dimensional (3D) image analysis of the mandible is possible due to the wide availability of computed tomography (CT) imaging technology. Accordingly, there have been several anatomical analyses of the mandibular foramen (MnF),<sup>1-4</sup> most involving distance-only measure-

ment methods. Such measurement methods have limitations, even when 3D CT images are used. Moreover, the analytical data for the mandible are limited with respect to their relationship with skeletal malocclusion, the size of the mandible, and the measurement planes and reference points for locating the position of the MnF.

The position of the MnF has been studied for mandibular treatment (i.e. ramal surgery, including osteotomy; inferior alveolar nerve block).<sup>5,6</sup> The present study used 3D images of the mandibles of patients diagnosed with skeletal class III malocclusion, and analyzed the position of the MnF (i.e. its proportional position in the mandible) using measurement planes and anatomical reference points. These data can be used in clinical cases, particularly for

\*This research was supported by the Basic Science Research Program through the National Research Foundation of Korea (NRF), funded by the Ministry of Education (2013R1A1A2009251).

Received December 17, 2015; Revised January 21, 2016; Accepted February 6, 2016  
\*Correspondence to : Dr. Sang-Hoon Kang

Department of Oral and Maxillofacial Surgery, National Health Insurance Service Ilsan Hospital, 100 Ilsan-ro, Ilsan-donggu, Goyang, Gyeonggi-do 10444, Korea  
(Tel) 82-31-900-0267, (Fax) 82-303-3448-7138, (E-mail) omfs1ksh@daum.net

ramus surgery. The purpose of this study was to produce a useful guide of MnF positions in patients diagnosed with skeletal class III malocclusion.

### Materials and Methods

This retrospective study was approved by our institutional review board. This study analyzed CT images of patients who underwent orthognathic surgery. Specifically, the study used CT images of mandibles that were taken during preoperative diagnosis work-ups. All patients were diagnosed preoperatively with skeletal class III malocclusion. The CT images were taken with a Siemens Sensation 64 system (1.0 mm slice thickness, Siemens Sensation 64 CT scanner; Siemens AG, Erlangen, Germany) using a pixel size of 0.4375 mm and a field-of-view of 22.40 cm. We excluded CT data from facial asymmetry patients with a mandibular shift greater than 5 mm (considered more than a moderate state of asymmetry).<sup>7</sup> The CT data were collected for a total of 85 patients, and both right and left MnF images were analyzed.

#### Points, lines, and planes for measurements

Simplant version 14.0 (Materialise Dental, Leuven, Belgium) was used to reconstruct the CT images into 3D images. The anatomical reference points, lines, and planes were then set onto the image of the mandible. The 3D position of the MnF was measured based on the es-

tablished reference points and planes. This process was intended to help the surgical team locate the MnF during mandibular ramus osteotomy. The anatomic points, lines, and planes that were used, as well as the measurements, are described below.

The MnF, coronoid process, sigmoid notch, condyle, gonion, antegonial notch, menton, mesiobuccal cusp of the mandibular first molar, and the most superior incisal contact point of the lower central incisor were identified in the images. In addition, the points of the anterior and posterior ramus were defined (Table 1). The anatomic lines used for defining the reference planes in this study are shown in Table 2. Three vertical lines were constructed: one connecting the sigmoid notch points and antegonial notch points, termed the SN-AGN line; another connecting a sigmoid notch point and gonion point, termed the SN-Gn line; and the other connecting a condyle point and a gonion point, termed the Cond-Gn line. In addition, five horizontal lines were constructed that connected each of the anterior ramus points and each of the posterior ramus points. The occlusal plane, mandibular plane, and five reference horizontal planes were defined (Table 3, Fig. 1A). Five vertical coronal planes were also defined, as shown in Table 3 and Figure 1B.

The vertical heights of anatomic points and horizontal length of the ramus

The vertical heights of the anatomic points were mea-

**Table 1.** Descriptions of the anatomic points used for the measurements in this study


Name	Description
MnF	Mandibular foramen
Gonion (Gn)	The most inferior, posterior, and lateral point on the external angle of the mandible
Menton	The lowest point on the mandibular symphysis
Antegonial notch (AGN)	The highest point of the concavity of the lower border of the ramus joining the mandible body
Coronoid process (Cor Pr)	The tip of the coronoid process
Sigmoid notch (SN)	The lowest point of the sigmoid notch
Condyle (Cond)	The most superior point of the condyle head
#31-#41	The midpoint between the mesial incisal tips of both mandibular central incisors
#36MBC	The mesiobuccal cusp tip of the left mandibular first molar
#46MBC	The mesiobuccal cusp tip of the right mandibular first molar
Anterior ramus of the MnF-mandibular Pl	The most anterior point of the ramus on the MnF-mandibular plane
Posterior ramus of the MnF-mandibular Pl	The most posterior point of the ramus on the MnF-mandibular plane
Anterior ramus of the MnF-occlusal Pl	The most anterior point of the ramus on the MnF-occlusal plane
Posterior ramus of the MnF-occlusal Pl	The most posterior point of the ramus on the MnF-occlusal plane
Anterior ramus of the MnF-SN/AGN p Pl	The most anterior point of the ramus on the MnF-SN/AGN p plane
Posterior ramus of the MnF-SN/AGN p Pl	The most posterior point of the ramus on the MnF-SN/AGN p plane
Anterior ramus of the MnF-SN/Gn p Pl	The most anterior point of the ramus on the MnF-SN/Gn p plane
Posterior ramus of the MnF-SN/Gn p Pl	The most posterior point of the ramus on the MnF-SN/Gn p plane
Anterior ramus of the MnF-Cond/Gn p Pl	The most anterior point of the ramus on the MnF-Cond/Gn p plane
Posterior ramus of the MnF-Cond/Gn p Pl	The most posterior point of the ramus on the MnF-Cond/Gn p plane

**Table 2.** Descriptions of the anatomic lines used for the measurements in this study

	Name	Description
Vertical lines	SN-Gn	Line between the Sigmoid notch point and the Gonion point
	SN-AGN	Line between the Sigmoid notch point and the Antegonial notch point
	Cond-Gn	Line between the Condyle point and the Gonion point
Horizontal lines	APramus-mandibular PI	Line between the Anterior ramus point on the MnF-mandibular PI and the Posterior ramus point on the MnF-mandibular PI
	APramus-occlusal PI	Line between the Anterior ramus point on the MnF-occlusal PI and the Posterior ramus point on the MnF-occlusal PI
	APramus-SN/AGN p PI	Line between the Anterior ramus point on the MnF-SN/AGN p PI and the Posterior ramus point on the MnF-SN/AGN p PI
	APramus-SN/Gn p PI	Line between the Anterior ramus point on the MnF-SN/Gn p PI and the Posterior ramus point on the MnF-SN/Gn p PI
	APramus-Cond/Gn p PI	Line between the Anterior ramus point on the MnF-Cond/Gn p PI and the Posterior ramus point on the MnF-Cond/Gn p PI

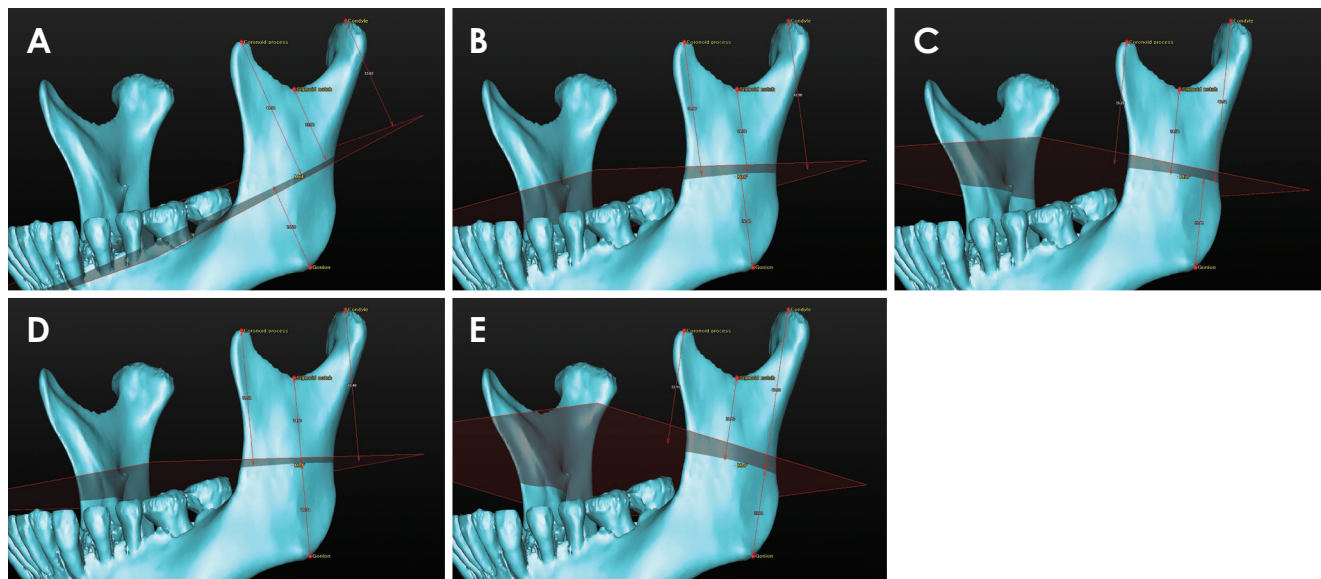
**Table 3.** Descriptions of the anatomic planes used for the measurements in this study

	Name	Description
Horizontal planes	Occlusal plane	Plane defined by the #31-#41 point, the #36MBC point, and the #46MBC point
	Mandibular plane	Plane defined by the Menton point, the right Gonion point, and the left Gonion point
	MnF-occlusal plane	Plane through the MnF point and parallel to the Occlusal plane
	MnF-mandibular plane	Plane through the MnF point and parallel to the Mandibular plane
	MnF-SN/Gn p plane	Plane through the MnF point and normal to the SN-Gn line
	MnF-Cond/Gn p plane	Plane through the MnF point and normal to the Condyle-Gn line
Vertical planes	MnF-SN/AGN p plane	Plane through the MnF point and normal to the SN-AGN line
	Normal MnF-MnPI plane	Plane through the MnF point and normal to the APramus-mandibular PI line
	Normal MnF-OccPI plane	Plane through the MnF point and normal to the APramus-occlusal PI line
	SN/AGN plane	Plane through the MnF point and normal to the APramus-SN/AGN p PI line
	SN/Gn plane	Plane through the MnF point and normal to the APramus-SN/Gn p PI line
Cond/Gn plane	Plane through the MnF point and normal to the APramus-Cond/Gn p PI line	

**Fig. 1.** Reference planes. A. Five horizontal planes are defined that pass through the mandibular foramen (MnF). B. Five vertical planes are defined that pass through the MnF.

sured according to each of the five horizontal planes (Fig. 2). The vertical distances from the coronoid process, sigmoid notch, and condyle to each horizontal plane were added to the vertical distances from the gonion to each horizontal plane, and these distances were set as the vertical heights of the coronoid process, sigmoid notch, and

condyle in the mandible for each horizontal plane (Table 4). The vertical distances from the gonion to the horizontal planes were set as the heights of the MnF in the mandible, according to each horizontal plane. Based on each of the five horizontal planes that pass through the MnF, the distance on each plane from the anterior ramus point



**Fig. 2.** Five horizontal planes are used as reference planes for measuring the vertical height of the mandible: A. the MnF-mandibular plane; B. the MnF-occlusal plane; C. the MnF-SN/AGN p plane; D. the MnF-SN/Gn p plane; and E. the MnF-Cond/Gn p plane.

**Table 4.** Descriptions of the measurements performed in this study

	Name	Descriptions
Vertical measurements	Cor Pr - [5 horizontal planes]	Distance between the Coronoid process point and each plane [5 horizontal planes]
	SN - [5 horizontal planes]	Distance between the Sigmoid notch point and each plane [5 horizontal planes]
	Cond - [5 horizontal planes]	Distance between the Condyle point and each plane [5 horizontal planes]
	MnF height - [5 horizontal planes]	Distance between the Gonion point and each plane [5 horizontal planes]
	Coronoid process height - [5 horizontal planes]	Sum of the MnF height - [5 horizontal planes] and Cor Pr - [5 horizontal planes]
	Sigmoid notch height - [5 horizontal planes]	Sum of the MnF height - [5 horizontal planes] and SN - [5 horizontal planes]
	Condyle height - [5 horizontal planes]	Sum of the MnF height - [5 horizontal planes] and Cond - [5 horizontal planes]
Horizontal measurements	AnteriorRamus to MnF on MnF-Mn PI	Distance between Anterior ramus point on the MnF-mandibular PI and plane Normal MnF-MnPI plane
	AnteriorRamus to MnF on MnF-Occ PI	Distance between Anterior ramus point on the MnF-occlusal PI and the Normal MnF-OccPI plane
	AnteriorRamus to MnF on MnF-SN/AGN p PI	Distance between the Anterior ramus point on the MnF-SN/AGN p PI and the SN/AGN plane
	AnteriorRamus to MnF on MnF-SN/Gn p PI	Distance between Anterior ramus point on the MnF-SN/Gn p PI and the SN/Gn plane
	AnteriorRamus to MnF on MnF-Cond/Gn p PI	Distance between Anterior ramus point on the MnF-Cond/Gn p PI and the Cond/Gn plane
	AP length of Ramus of [5 horizontal lines]	Length of each line [5 horizontal lines]

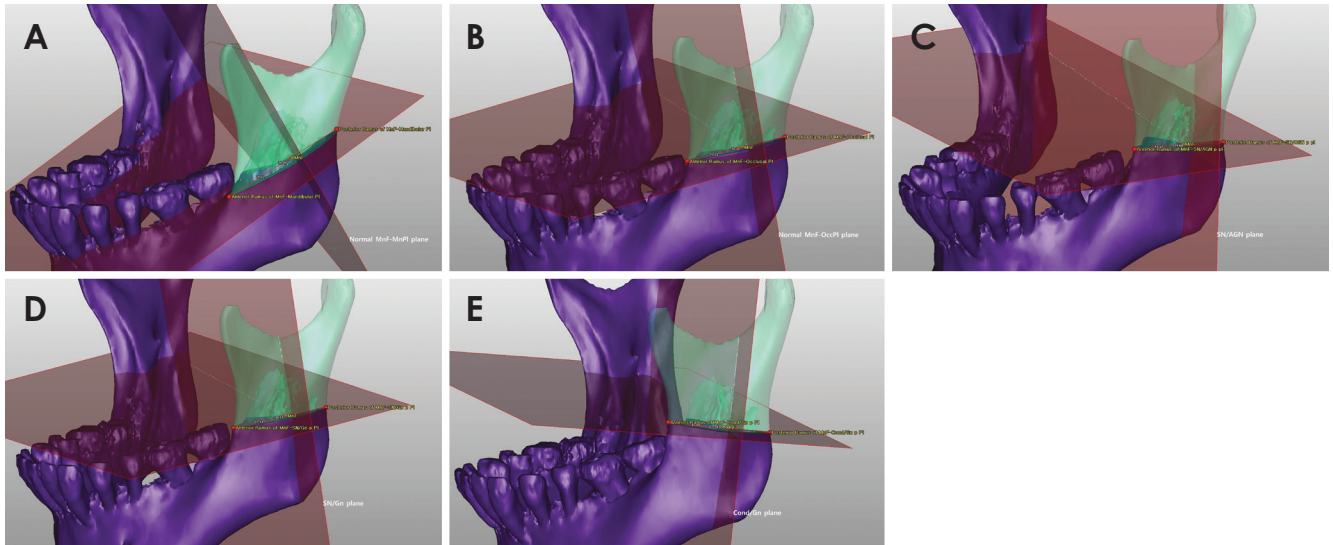
[5 horizontal planes] refers to the MnF-occlusal plane, the MnF-mandibular plane, the MnF-SN/Gn p plane, the MnF-Cond/Gn p plane, and the MnF-SN/AGN p plane. [5 horizontal lines] refers to the following lines: APramus-mandibular PI, APramus-occlusal PI, APramus-SN/AGN p PI, APramus-SN/Gn p PI, and APramus-Cond/Gn p PI

to the posterior ramus point was designated the antero-posterior horizontal distance of the ramus (Table 4). The perpendicular distance from each anterior ramus point to each vertical plane was designated the horizontal distance from the anterior ramus to the MnF (Fig. 3).

#### Analysis of the measurement values

To investigate the positional relationship of the MnF in the mandible, regression analysis was used to examine the rational relationships between the vertical heights of the coronoid process, sigmoid notch, and condyle points





**Fig. 3.** Five vertical planes are used as reference planes for measuring the horizontal distance from the anterior ramus to the mandibular foramen (MnF). A. the normal MnF-MnPI plane; B. the normal MnF-OccPI plane; C. the SN/AGN plane; D. the SN/Gn plane; and E. the Cond/Gn plane.

and the vertical height of the MnF. Regression analysis was also used to determine the rational relationship between the anteroposterior horizontal distance of the ramus from each of the five horizontal planes passing through the MnF and the horizontal distance from the anterior ramus point to the MnF. The study data were analyzed with IBM SPSS Statistics version 21 (IBM Corp., Armonk, NY, USA), and statistical significance was established at  $p < 0.05$ . The intra-observer error for anatomic point determination was calculated via repeated measurement (10 measurements) of the MnF. All measurement data are reported as mean  $\pm$  SD unless otherwise indicated.

## Results

The sex ratio and age of the 85 patients with skeletal class III mandibular prognathism were 46 : 39 (men : women) and  $22.2 \pm 5.5$  years. The condyle height relative to the MnF-mandibular plane was the smallest ( $53.45 \pm 6.45$  mm). The heights of the coronoid process and the MnF were the greatest when measured relative to the MnF-mandibular plane ( $60.09 \pm 5.96$  mm and  $21.31 \pm 3.83$  mm, respectively). The height of the sigmoid notch was the greatest when based on the MnF-SN/Gn p plane ( $43.89 \pm 5.02$  mm). The height of the condyle was the greatest when based on the MnF-Cond/Gn p plane ( $63.80 \pm 5.79$  mm). The heights of the MnF, coronoid process, and sigmoid notch were the smallest when based on the MnF-Cond/Gn p plane ( $18.60 \pm 4.56$  mm,  $50.08 \pm 6.89$

mm, and  $40.50 \pm 5.45$  mm, respectively). The anteroposterior length of the ramus and the distance from the anterior ramus point to the MnF were the longest when they were based on the MnF-mandibular plane ( $42.98 \pm 5.17$  mm and  $27.60 \pm 4.22$  mm, respectively; Table 5). The intra-observer error for the MnF area was  $0.60 \pm 0.24$  mm.

### Vertical position of the MnF

The heights of the coronoid process, sigmoid notch, and condylar head on the five horizontal planes were all significantly associated with the height of the MnF according to the regression analysis. The regression relationship was the strongest for the coronoid process, sigmoid notch, and condylar head when the measurements were based on the MnF-mandibular plane (coefficients of determination ( $R^2$ ) of 0.424, 0.597, and 0.604 respectively).

The heights of the coronoid process and the MnF were significantly associated according to the regression analysis (Table 6). The non-standardized regression coefficients were significant for the relationships between the heights of the coronoid process and the MnF based on all the horizontal reference planes. The highest coefficients, based on the MnF-mandibular plane, were a standardized regression coefficient of 0.654 and determination coefficient ( $R^2$ ) of 0.424.

The heights of the sigmoid notch and the MnF were significantly associated in the regression analysis (Table 7). The non-standardized regression coefficients for the relationships between the heights of the sigmoid notch

**Table 5.** Vertical and horizontal measurements (in mm) using the indicated horizontal planes as reference planes

		MnF-mandibular plane	MnF-occlusal plane	MnF-SN/AGN p plane	MnF-SN/Gn p plane	MnF-Cond/Gn p plane
Vertical measurements	MnF height	21.31 ± 3.83	20.41 ± 4.18	18.59 ± 4.44	21.20 ± 4.05	18.60 ± 4.56
	Coronoid process height	60.09 ± 5.96	56.18 ± 6.87	51.38 ± 6.54	59.23 ± 6.13	50.08 ± 6.89
	Sigmoid notch height	42.84 ± 4.77	42.94 ± 5.24	41.16 ± 5.19	43.89 ± 5.02	40.50 ± 5.45
	Condyle height	53.45 ± 6.45	61.60 ± 5.85	63.40 ± 5.67	58.82 ± 6.27	63.80 ± 5.79
Horizontal measurements	AP length of the ramus	42.98 ± 5.17	34.96 ± 3.54	33.65 ± 3.52	37.94 ± 5.39	33.66 ± 3.51
	Anterior ramus to MnF	27.60 ± 4.22	21.15 ± 2.59	20.05 ± 2.68	23.66 ± 4.35	20.07 ± 2.69

Measurements are reported as mean ± SD

**Table 6.** Regression analysis of the relationships of the mandibular foramen (MnF) height and the coronoid process height based on the indicated horizontal planes

MnF height - [5 horizontal planes]	A	P value <sup>†</sup>	B	P value <sup>‡</sup>	β	R <sup>2</sup>	P value <sup>§</sup>
MnF height - MnF-mandibular plane	0.42	<0.001	-3.951	0.083	0.654	0.424	<0.001
MnF height - MnF-occlusal plane	0.341	<0.001	1.241	0.574	0.561	0.31	<0.001
MnF height - MnF-SN/AGN p plane	0.378	<0.001	-0.82	0.716	0.557	0.306	<0.001
MnF height - MnF-SN/Gn p plane	0.41	<0.001	-3.106	0.193	0.622	0.383	<0.001
MnF height - MnF-Cond/Gn p plane	0.405	<0.001	-1.709	0.403	0.613	0.372	<0.001

A: non-standardized regression coefficient, B: regression constant, β: standardized regression coefficient, R<sup>2</sup>: coefficient of determination, P value<sup>†</sup>: significance of the non-standardized regression coefficient, P value<sup>‡</sup>: significance of the regression constant, P value<sup>§</sup>: significance of the regression analysis

**Table 7.** Regression analysis of the relationships of the mandibular foramen (MnF) height and the sigmoid notch height based on the indicated horizontal planes

MnF height - [5 horizontal planes]	A	P value <sup>†</sup>	B	P value <sup>‡</sup>	β	R <sup>2</sup>	P value <sup>§</sup>
MnF height - MnF-mandibular plane	0.621	<0.001	-5.318	0.002	0.774	0.597	<0.001
MnF height - MnF-occlusal plane	0.521	<0.001	-1.973	0.33	6.653	0.423	<0.001
MnF height - MnF-SN/AGN p plane	0.514	<0.001	-2.558	0.244	0.601	0.357	<0.001
MnF height - MnF-SN/Gn p plane	0.543	<0.001	-2.625	0.199	0.673	0.45	<0.001
MnF height - MnF-Cond/Gn p plane	0.539	<0.001	-3.217	0.112	0.645	0.412	<0.001

A: non-standardized regression coefficient, B: regression constant, β: standardized regression coefficient, R<sup>2</sup>: coefficient of determination, P value<sup>†</sup>: significance of the non-standardized regression coefficient, P value<sup>‡</sup>: significance of the regression constant, P value<sup>§</sup>: significance of the regression analysis

and the MnF were significant for all the horizontal reference planes. The regression constant was highly significant when it was based on the MnF-mandibular plane (p=0.002). The highest coefficients were a standardized regression coefficient of 0.774 and determination coefficient of 0.597, and these were based on the MnF-mandibular plane.

The heights of the condylar head and the MnF were significantly related in the regression analysis (Table 8). For all the horizontal reference planes, the non-standardized regression coefficients for the relationships between the heights of the condylar head and the MnF were significant. The regression constant was significant when it was based on all of the horizontal planes, except for the MnF-SN/Gn p plane. The highest coefficients were a standardized regression coefficient of 0.779 and a determination

coefficient of 0.604, and were based on the MnF-mandibular plane.

#### Horizontal position of the MnF

Using the five horizontal planes as references, the anteroposterior length of the ramus and the distance from the anterior ramus point to the MnF were significantly associated according to the regression analysis (Table 9). For all the horizontal reference planes, the non-standardized regression coefficients were significant for the relationships of the anteroposterior length of the ramus and the distance from the anterior ramus point to the MnF. The regression constants were significant when the MnF-mandibular plane and MnF-SN/Gn p plane were used as references.

The standardized regression coefficients for all five hor-

**Table 8.** Regression analysis of the relationships of the mandibular foramen (MnF) height and the condyle height based on the indicated horizontal planes

MnF height - [5 horizontal planes]	A	<i>P</i> value <sup>†</sup>	B	<i>P</i> value <sup>‡</sup>	β	R <sup>2</sup>	<i>P</i> value <sup>§</sup>
MnF height - MnF-mandibular plane	0.462	<0.001	- 3.401	0.029	0.779	0.604	<0.001
MnF height - MnF-occlusal plane	0.445	<0.001	- 6.99	0.01	0.622	0.384	<0.001
MnF height - MnF-SN/AGN p plane	0.44	<0.001	- 9.278	0.004	0.561	0.311	<0.001
MnF height - MnF-SN/Gn p plane	0.4	<0.001	- 2.314	0.319	0.619	0.38	<0.001
MnF height - MnF-Cond/Gn p plane	0.451	<0.001	- 10.207	0.002	0.573	0.324	<0.001

A: non-standardized regression coefficient, B: regression constant, β: standardized regression coefficient, R<sup>2</sup>: coefficient of determination, *P* value<sup>†</sup>: significance of the non-standardized regression coefficient, *P* value<sup>‡</sup>: significance of the regression constant, *P* value<sup>§</sup>: significance of the regression analysis

**Table 9.** Regression analysis of the distance from the anterior ramus to the mandibular foramen (MnF) according to the anteroposterior ramus length on the horizontal plane

Anterior ramus to the MnF - [5 horizontal planes]	A	<i>P</i> value <sup>†</sup>	B	<i>P</i> value <sup>‡</sup>	β	R <sup>2</sup>	<i>P</i> value <sup>§</sup>
Anterior ramus to MnF - MnF-mandibular plane (n = 117)	0.716	<0.001	- 3.148	0.05	0.877	0.766	<0.001
Anterior ramus to MnF - MnF-occlusal plane (n = 170)	0.549	<0.001	1.963	0.135	0.751	0.562	<0.001
Anterior ramus to MnF - MnF-SN/AGN p plane (n = 170)	0.561	<0.001	1.184	0.378	0.738	0.542	<0.001
Anterior ramus to MnF - MnF-SN/Gn p plane (n = 167)	0.728	<0.001	- 3.948	<0.001	0.901	0.811	<0.001
Anterior ramus to MnF - MnF-Cond/Gn p plane (n = 170)	0.567	<0.001	0.987	0.464	0.74	0.546	<0.001

A: non-standardized regression coefficient, B: regression constant, β: standardized regression coefficient, R<sup>2</sup>: coefficient of determination, *P* value<sup>†</sup>: significance of the non-standardized regression coefficient, *P* value<sup>‡</sup>: significance of the regression constant, *P* value<sup>§</sup>: significance of the regression analysis

horizontal planes used as references were greater than 0.73, and the coefficient was 0.877 using the MnF-mandibular plane and 0.901 using the MnF-SN/Gn p plane. The determination coefficient was 0.766 using the MnF-mandibular plane and 0.811 using the MnF-SN/Gn p plane. Notably, there were 53 missing values for measurements using the MnF-mandibular plane and 3 missing values for the MnF-SN/Gn p plane. For the MnF-mandibular plane, which is parallel to the MnF, there were missing values when the anterior part of the plane sloped downward, thus leading directly to the mandibular body instead of the anterior ramus. Similarly, there were missing values for the MnF-SN/Gn p plane, although there were fewer than for the MnF-mandibular plane.

## Discussion

The size of the human mandible varies greatly according to age, ethnicity, and sex.<sup>2</sup> Accordingly, the present study investigated the relative position of the MnF rather than simply measuring its position within the surrounding anatomical structures. Using specific anatomic planes as references, we measured the position of the MnF in patients diagnosed with skeletal class III malocclusion to determine the 3D position in the mandible. We determined the position of the MnF was related vertically to the heights of the mandibular condyle, sigmoid notch,

and coronoid process and horizontally to the anteroposterior length of the mandibular ramus. Further, we found that the mandibular plane was best for determining the relationships of the heights of the mandibular condyle, sigmoid notch, and coronoid process with the height of the MnF. This suggests that the mandibular plane can be utilized in clinical cases, not only for analyzing maxillofacial malformations but also for tracing the position of the MnF.

During mandibular prognathism surgery, the vertical position of the MnF can be estimated using the exposed sigmoid notch area. With reference to the mandibular plane, the height (in millimeters) of the MnF can be estimated with the following equation:  $0.621 \times (\text{the height of the sigmoid notch}) - 5.318$ . As an alternative to the mandibular plane, one can use the horizontal plane perpendicular to the SN-Gn line that connects the sigmoid notch and gonion; this plane (the MnF-SN/Gn p plane) is second to the mandibular plane in terms of usefulness for estimating the height of the MnF. When using the condyle height, the occlusal plane can be a useful alternative for estimating the height of the MnF.

Vertical ramus osteotomy is a surgical procedure that can be used for patients with mandibular prognathism when the mandibular ramus posterior to the MnF is cut. The relationship between the anteroposterior length of the mandibular ramus and the position of the MnF was best

shown when the horizontal MnF-SN/Gn p and MnF-mandibular planes were used as references. The mandibular ramus area at the MnF level is exposed during mandibular prognathism surgery. Therefore, the relationship of the horizontal position of the MnF with the anteroposterior length of the ramus was investigated. Using the MnF-SN/Gn p plane as a reference, the horizontal length (in mm) from the anterior ramus to the MnF can be estimated with the following equation:  $0.728 \times (\text{the anteroposterior distance of the mandibular ramus}) - 3.948$ . Using the MnF-mandibular plane as the reference, the horizontal length (in millimeters) from the anterior ramus to the MnF can be estimated with the following equation:  $0.716 \times (\text{the anteroposterior distance of the ascending ramus}) - 3.148$ .

However, there are cases in which the mandibular plane leans in the anteroinferior direction, and the MnF-mandibular plane cannot pass through the anterior ascending ramus area. In the present study, there were 53 missing values for the anterior ramus point when using the MnF-mandibular plane as the reference, and there were 3 missing values when using the MnF-SN/Gn p plane. Missing values may limit the usefulness of these calculations since they may occur in actual clinical cases. If this happens, it is recommended that the MnF-SN/Gn p plane be used, and the use of the occlusal plane may be more helpful for determining the horizontal position of the MnF when the anterior ramus point cannot be defined using the MnF-mandibular plane. The vertical height of the MnF from the gonion ranged from 18 mm to 21 mm, and the anteroposterior length of the ramus was about 33 mm to 42 mm. The horizontal distance from the anterior ramus point to the MnF was about 20 mm to 27 mm. This shows that the MnF is positioned posterior to the mandibular ramus.

The wide availability of CT scans has resulted in useful 3D images of the mandible. In a study that analyzed the 3D position of the MnF using cone-beam CT, the average distance from the gonion to the MnF was about 24 mm and the average distance from the anterior ramus to the MnF in the axial plane was about 15 mm.<sup>2</sup> The difference between the results of that study versus the present study is likely due to the use of the axial and sagittal planes of the CT images in the former. In another study that analyzed the 3D position of the MnF using multiple detector CT, the average height from the gonion to the MnF relative to the occlusal plane was about 18 mm, the average anteroposterior length of the ascending ramus was 37 mm, and the average distance from the anterior ramus to the MnF on a horizontal plane (parallel to the occlusal plane

that passes through the MnF) was about 22 mm.<sup>8</sup> These results are similar to those of the present study, although there are minor differences because the present study only examined mandibles with skeletal III class malocclusion, and the horizontal length from the anterior ramus to the MnF was measured as the perpendicular distance projected onto each vertical plane that passed through the MnF.

Simply measuring the vertical and horizontal distances may not be that beneficial in actual clinical cases because human mandibles vary in size. However, assessing the positional relationships using 3D planes can be useful clinically, as this shows the objective relationship with respect to the reference planes used in the analyses. Image-assisted surgical techniques are increasingly used for maxillofacial operations; accordingly, the present study is valuable in that it provides 3D image data that can be utilized in such surgical procedures. This study's research methods and results, with respect to the positional 3D analysis of the MnF, will be useful for computer-assisted surgical methods, such as surgical simulation, navigation, augmented reality models, and robotic surgery. Moreover, these data can be applied for treating mandible-related issues. The data can also be used to compare the mandibles of different ethnic groups.

Previous studies of the mandible were performed on cadavers,<sup>9,10</sup> and often just a few distances were measured in 3D reconstructed images even though CT images were examined.<sup>2-4</sup> Importantly, previous studies performed quantitative analyses without considering the different sizes of the mandibles. Moreover, even when 3D reconstruction images were used, few studies performed vertical and horizontal assessments using 3D reference planes.

The present study found that the position of the MnF was related to the vertical heights of the sigmoid notch, coronoid process, and condyle and to the horizontal anteroposterior length of the ascending ramus. These findings indicate that the MnF, at least to some extent, maintains its relative position with the growth of the rami. In addition, the results indicate that the MnF is posterior to the ascending ramus. We expect that future studies will contribute further knowledge about the position of the MnF in the mandible via 3D image analysis of mandibles with skeletal class II malocclusion for ramus surgery.

In conclusion, the 3D mandibular image analysis data reported in this study will be useful for defining and describing the position of the MnF in mandibles of different sizes and shapes and in different ethnic groups. The present study showed that the proportional position of the MnF was significantly related to the vertical heights



of the sigmoid notch, coronoid process, and condyle and to the horizontal anteroposterior length of the ascending ramus. Furthermore, the methods used here and the positional 3D analyses of the MnF can be used clinically for computer-assisted surgical methods, especially for ramal surgery in patients with skeletal class III mandibular prognathism.

## References

1. Sekerci AE, Cantekin K, Aydinbelge M. Cone beam computed tomographic analysis of the shape, height, and location of the mandibular lingula in a population of children. *Biomed Res Int* 2013; 2013: 825453.
2. Findik Y, Yildirim D, Baykul T. Three-dimensional anatomic analysis of the lingula and mandibular foramen: a cone beam computed tomography study. *J Craniofac Surg* 2014; 25: 607-10.
3. Park KR, Kim SY, Kim GJ, Park HS, Jung YS. Anatomic study to determine a safe surgical reference point for mandibular ramus osteotomy. *J Craniomaxillofac Surg* 2014; 42: 22-7.
4. Sekerci AE, Sisman Y. Cone-beam computed tomography analysis of the shape, height, and location of the mandibular lingula. *Surg Radiol Anat* 2014; 36: 155-62.
5. Alves N, Deana NF. Morphometric study of mandibular foramen in macerated skulls to contribute to the development of sagittal split ramus osteotomy (SSRO) technique. *Surg Radiol Anat* 2014; 36: 839-45.
6. Yu IH, Wong YK. Evaluation of mandibular anatomy related to sagittal split ramus osteotomy using 3-dimensional computed tomography scan images. *Int J Oral Maxillofac Surg* 2008; 37: 521-8.
7. Kim MS, Lee EJ, Song IJ, Lee JS, Kang BC, Yoon SJ. The location of midfacial landmarks according to the method of establishing the midsagittal reference plane in three-dimensional computed tomography analysis of facial asymmetry. *Imaging Sci Dent* 2015; 45: 227-32.
8. Kang SH, Byun IY, Kim JH, Park HK, Kim MK. Three-dimensional anatomic analysis of mandibular foramen with mandibular anatomic landmarks for inferior alveolar nerve block anesthesia. *Oral Surg Oral Med Oral Pathol Oral Radiol* 2013; 115: e17-23.
9. Kositbowornchai S, Siritapetawee M, Damrongrungruang T, Khongkankong W, Chatrchaiwiwatana S, Khamanarong K, et al. Shape of the lingula and its localization by panoramic radiograph versus dry mandibular measurement. *Surg Radiol Anat* 2007; 29: 689-94.
10. Monnazzi MS, Passeri LA, Gabrielli MF, Bolini PD, de Carvalho WR, da Costa Machado H. Anatomic study of the mandibular foramen, lingula and antilingula in dry mandibles, and its statistical relationship between the true lingula and the antilingula. *Int J Oral Maxillofac Surg* 2012; 41: 74-8.