



Remission of a long-lasting sarcoidosis after allogeneic hematopoietic stem cell transplantation for acute myeloid leukemia

Emmanuelle Ginoux, MD,^a Diane Kottler, MD,^a Bruno Anglaret, MD,^b Brigitte Balme, MD,^c Claude-Eric Bulabois, MD,^d and François Skowron, MD^a
Valence, Pierre Bénite, and Grenoble, France

Key words: allograft; cutaneous sarcoidosis; remission; stem cell transplantation; treatment.

INTRODUCTION

Sarcoidosis is a systemic nonnecrotizing granulomatous disease, the etiology of which is suspected to be immune mediated.¹ Hematopoietic stem cell transplantation (HSCT) is effective in cases of immune diseases because of a beneficial graft-versus-autoimmune (GVA) reaction similar to the graft-versus-leukemia reaction.²⁻⁴ We report the case of a long-lasting corticosteroid-dependent sarcoidosis complicated by acute myeloid leukemia (AML) treated with allogeneic HSCT. After this treatment, sarcoidosis resolved with no relapse after a long follow-up period.

CASE REPORT

A 55-year-old woman was referred to our unit for arthritis and cutaneous eruption. She had a 2-year history of joint pain in her knees, wrists, and ankles with morning stiffness and had several episodes of anterior uveitis. Examination found metacarpophalangeal arthritis and multiple tiny infiltrated papules on her back, arms, and legs (Fig 1). Cutaneous biopsy found a disperse inflammatory infiltrate composed of mononuclear cells and small nonnecrotizing circumscribed granulomas with epithelioid cells in the papillary dermis (Fig 2). Infection was ruled out by negative results of special staining, bacterial skin culture, and negative intradermal tuberculin test. A visceral evaluation excluded hepatic and pulmonary involvement.

Abbreviations used:

AML:	acute myeloid leukemia
GVA:	graft versus autoimmune
GvHD:	graft-versus-host disease
HSCT:	hematopoietic stem cell transplantation
Th1:	helper T cell 1

Blood cell count, calcium levels, and plasmatic level of angiotensin-converting enzyme were within normal ranges. Based on the physical exam and laboratory findings, we diagnosed lichenoid sarcoidosis. Antimalarial medications, methotrexate, cyclines, and thalidomide were successively tried with limited improvement. Systemic corticosteroids induced remission but were associated with relapses after dose reduction. Finally, low doses of corticosteroids (7 mg/d) combined with methotrexate (15 mg/wk) helped achieve remission but these doses could not be reduced. Eight years after the diagnosis, blood investigations found pancytopenia with blastic cells in peripheral blood. Bone marrow biopsy found an excess of blasts with precursor cells increasing, trisomy 8, and loss of 17p/TP53 on cytogenetic analysis, leading to the diagnosis of primitive myelofibrosis progressing to AML. Umbilical cord blood HSCT after nonablative regimen with fludarabine (40 mg/m²) and cyclophosphamide (50 mg/kg) were given. On completion of treatment, the patient was asymptomatic, and full remission was obtained for

From the Departments of Dermatology^a and Hematology,^b Centre Hospitalier de Valence; the Department of Dermatopathology, CHU Lyon sud^c; and the Department of Hematology, CHU de Grenoble.^d

Funding sources: None.

Conflicts of interest: None declared.

Correspondence to: François Skowron, MD, Service de Dermatologie, Centre Hospitalier de Valence, 179 Bd Maréchal JUIN, 26000 Valence, France. E-mail: francois.skowron@orange.fr.

JAAD Case Reports 2016;2:408-10.
2352-5126

© 2016 by the American Academy of Dermatology, Inc. Published by Elsevier, Inc. This is an open access article under the CC BY-NC-ND license (<http://creativecommons.org/licenses/by-nc-nd/4.0/>).

<http://dx.doi.org/10.1016/j.jdc.2016.08.012>

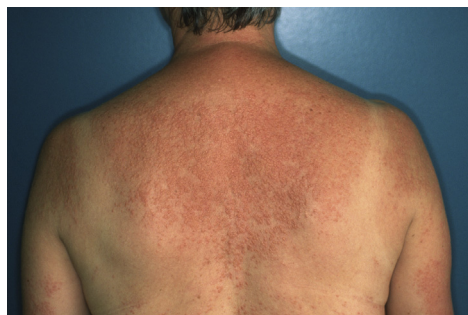

Fig 1. Clinical presentation of the cutaneous sarcoidosis shows lichenoid eruption on back and arms.

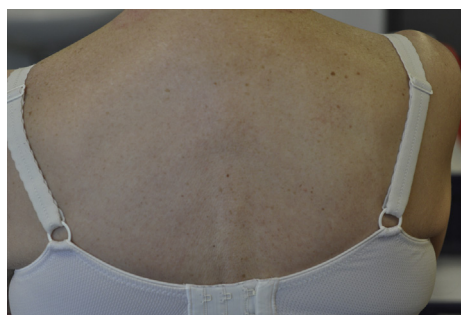


Fig 3. Clinical remission of the sarcoidosis after allogeneic HSCT.

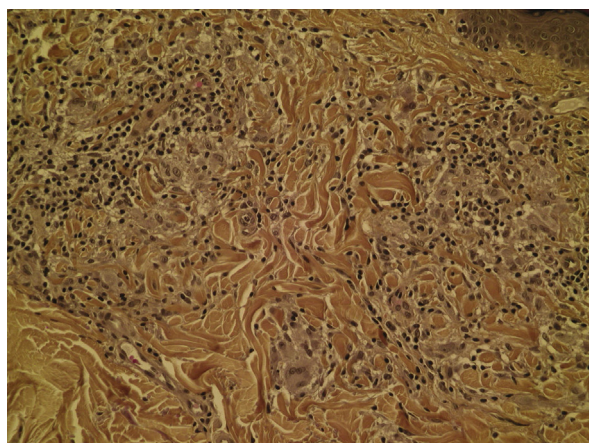


Fig 2. Pathologic changes on skin biopsy show a granulomatous dermatitis with epithelioid cells in the dermis and a moderate lymphomatous infiltrate. (Hematoxylin-eosin stain; original magnification: $\times 20$.)

both AML and sarcoidosis. Two months after HSCT, she presented with cutaneous graft-versus-host disease (GvHD), which was well controlled using mycophenolate mofetil and everolimus for 3 months. Five months after allogeneic HSCT, all immunosuppressive drugs were stopped without any recurrence of sarcoidosis, which, after 4 years of follow-up, remains asymptomatic (Fig 3).

DISCUSSION

Sarcoidosis has no well-defined diagnostic criteria, and a reliable diagnosis is difficult when the lungs are spared.¹ Our patient had a granulomatous dermatitis, which could have been granuloma annulare with a histological sarcoidal pattern. However, the lack of necrobiosis or mucin on skin biopsy and the associated with anterior uveitis and arthritis are likely in favor of lichenoid sarcoidosis.

Studies suggest that sarcoidosis is caused by excessive helper T cell 1 (Th1)-like host response to an unidentified constant antigen.^{1,5} Overstimulated macrophages and CD4⁺ T cells induce an

exaggerated local production of Th1 mediators leading to granulomatous formation. Moreover, the reduced activity of regulatory lymphocytes allows this inflammatory amplified Th1 immune response to persist.⁵ This way, sarcoidosis is seen as an immune-mediated disease. Cutaneous sarcoidosis is usually managed with antimalarial drugs. Additional therapies such as corticosteroids, methotrexate, and cyclines could also be required.⁶ Despite the use of these therapies, sarcoidosis was not controlled.

In our case, allogeneic HSCT treated the AML successfully and induced an unexpected complete remission of the sarcoidosis. This favorable outcome after the AML treatment could be explained by (1) the GvHD treatment (everolimus and mycophenolate mofetil), (2) the pretransplant conditioning (cyclophosphamide and fludarabine), or (3) the GVA reaction.

Mycophenolate mofetil, used in the GvHD treatment, is reported to be a second-line treatment of sarcoidosis although with relapses after cessation and absence of lasting effect.⁷ Chronologically, our patient experienced remission of the sarcoidosis before the GvHD appeared. Thus, the role of the GvHD treatment appeared less likely to explain the sarcoidosis remission. The immunosuppressive effect of the pretransplant conditioning could have had a beneficial role on the sarcoidosis. However, no case of sarcoidosis successfully treated with fludarabine is reported in the literature. Cyclophosphamide has been used to treat neurologic or cardiac sarcoidosis, but the results are heterogeneous, and relapses are frequent.⁸ In addition, sarcoidosis occurring after organ transplant has been reported, highlighting the fact that an ablative regimen is not unequivocally efficient to prevent or treat sarcoidosis. As a result, the pretransplant conditioning alone seems to be insufficient in explaining the long-lasting remission of the sarcoidosis in our case. Efficacy of HSCT for treating immune-mediated diseases was reported since the late 1990s.^{2,9} These positive effects could

be analogous to the graft-versus-leukemia reaction. Allogeneic HSCT is based on the immune reset similar to autologous HSCT and on an additional correction of genetic predisposition to disease.² This way, allograft could confer a GVA reaction due to the apoptosis or modulation of autoreactive lymphocytes by the nondisease donor lymphocytes. Allograft could also correct a genetic predisposition to immune-mediated diseases.^{2-4,9} Herein, we suggest that this GVA effect was the main mechanism explaining the long-lasting sarcoidosis remission after replacement of the Th1 such as CD4⁺ T cells of the patient by the non-disease-prone hematopoietic stem cells from the normal donor. This hypothesis is highlighted by a case of sarcoidosis remission after donor lymphocytes infusions.⁴

Despite their potential for curing, allogeneic HSCTs are usually associated with mortality because of the conditioning regimen and GvHD, and should only be considered in selected cases of refractory sarcoidosis. Sarcoidosis after HSCT has been reported in 10 cases.¹⁰ More studies are needed to determine whether these cases were caused by a transmission from the donor or also to an abnormal immunologic response.¹⁰

We report herein a unique case of sarcoidosis remission after allogeneic HSCT, suggesting a beneficial GVA effect on sarcoidosis. Although this

report leads to more questions than answers, we suggest that T lymphocyte therapies could be a treatment for refractory sarcoidosis in selected cases.

REFERENCES

1. Valeyre D, Prasse A, Nunes H, Uzunhan Y, Brillet P-Y, Müller-Quernheim J. Sarcoidosis. *Lancet Lond Engl*. 2014; 383(9923):1155-1167.
2. Burt RK, Traynor AE. Hematopoietic stem cell transplantation: a new therapy for autoimmune disease. *Stem Cells Dayt Ohio*. 1999;17(6):366-372.
3. Marmont AM, Gualandi F, Van Lint MT, Bacigalupo A. Refractory Evans' syndrome treated with allogeneic SCT followed by DLI. Demonstration of a graft-versus-autoimmunity effect. *Bone Marrow Transplant*. 2003;31(5):399-402.
4. Tauro S, Mahendra P. Resolution of sarcoidosis after allogeneic bone marrow transplantation with donor lymphocyte infusions. *Bone Marrow Transplant*. 2001;27(7):757-759.
5. Grunewald J, Eklund A. Role of CD4+ T cells in sarcoidosis. *Proc Am Thorac Soc*. 2007;4(5):461-464.
6. Judson MA. Advances in the diagnosis and treatment of sarcoidosis. *F1000prime Rep*. 2014;6:89.
7. Brill A-K, Ott SR, Geiser T. Effect and safety of mycophenolate mofetil in chronic pulmonary sarcoidosis: a retrospective study. *Respir Int Rev Thorac Dis*. 2013;86(5):376-383.
8. Korsten P, Mirsaeidi M, Sweiss NJ. Nonsteroidal therapy of sarcoidosis. *Curr Opin Pulm Med*. 2013;19(5):516-523.
9. Burt RK, Loh Y, Pearce W, et al. Clinical applications of blood-derived and marrow-derived stem cells for nonmalignant diseases. *JAMA*. 2008;299(8):925-936.
10. Kushima H, Ishii H, Ikewaki J, Takano K, Ogata M, Kadota J-I. Sarcoidosis in donor-derived tissues after haematopoietic stem cell transplantation. *Eur Respir J*. 2013;41(6):1452-1453.