



Retinal Vein Occlusion Following Two Doses of mRNA-1237 (Moderna) Immunization for SARS-Cov-2: A Case Report

Riccardo Sacconi · Filippo Simona · Paolo Forte · Giuseppe Querques 

Received: November 1, 2021 / Accepted: November 26, 2021 / Published online: December 9, 2021
© The Author(s) 2021

ABSTRACT

Introduction: Published data on possible ocular adverse events potentially associated with vaccination with the SARS-Cov-2 mRNA-1237 vaccine are scarce. In this report, we describe the case of a patient who had a hemispheric retinal vein occlusion potentially associated with being vaccinated with the second dose of the SARS-Cov-2 mRNA-1237 vaccine.

Methods: Case report including a discussion on multimodal imaging.

Results: A 74-year-old woman presented with painless vision loss in the right eye experienced 48 hours after receiving a second dose of the mRNA-1237 vaccine. The patient was receiving oral anticoagulant therapy for atrial fibrillation. Her best-corrected visual acuity (VA) was 20/32,

and fundus examination showed venous congestion and widespread blot haemorrhages in the inferior quadrants. Based on multimodal imaging evaluation, the diagnosis of hemispheric retinal vein occlusion was made. Due to the development of cystoid macular oedema with intraretinal fluid and the decline in VA, the patient was treated with two injections of intravitreal ranibizumab, leading to functional improvement and regression of oedema.

Conclusions: We report a case with retinal vein occlusion 48 hours after vaccination with the SARS-Cov-2 mRNA-1237 vaccine; however, the relationship between these two events remains unclear. Further research is warranted to better understand the potential link between retinal thrombotic events and vaccination.

Keywords: COVID; Retinal vein occlusion; RVO; Vaccination

R. Sacconi · P. Forte · G. Querques
School of Medicine, Vita-Salute San Raffaele
University, Milan, Italy

R. Sacconi · P. Forte · G. Querques
Ophthalmology Unit, Division of Head and Neck,
IRCCS San Raffaele Scientific Institute, Milan, Italy

F. Simona
Pax Eye Center, Via Stazione 9, 6600 Locarno,
Switzerland

G. Querques (✉)
Department of Ophthalmology, University Vita-
Salute, IRCCS Ospedale San Raffaele, Via Olgettina
60, 20132 Milan, Italy
e-mail: giuseppe.querques@hotmail.it

Key Summary Points

We detail the case of a patient who had a hemispheric retinal vein occlusion 48 hours after receiving a second dose of the mRNA-1237 vaccine.

Published data on possible ocular adverse events potentially associated with SARS-Cov-2 mRNA-1237 vaccination are scarce.

SARS-Cov-2 mRNA-1237 vaccination should be considered to be the most likely explanation for the hemispheric retinal vein occlusion in our patient.

INTRODUCTION

Numerous case reports and studies on severe acute respiratory syndrome coronavirus 2 (SARS-CoV-2) infection have revealed the retinal manifestations of the disease, which include arterial and venous thrombosis associated with macular edema (ME), haemorrhages, microvascular alterations and acute macular neuroretinopathy [1–5]. In addition, SARS-CoV-2 viral particles were reported to be present in human retina specimens from deceased patients infected with the disease [6, 7]. However, it is unclear whether the reported findings are incidental, the result of systemic action of the virus or from direct retinal toxicity [8].

The introduction of liposome-encapsulated recombinant mRNA encoding the SARS-CoV-2 spike protein, i.e. the mRNA-1273 vaccine, has opened the way for primary prevention of the disease [9]. The remarkable efficacy of the vaccines based on these principles has been proven by the rarity of life-threatening adverse events and excellent safety profile.

Here, in the context of documenting all possible adverse events associated with SARS-CoV-2 vaccination, we present the case of unilateral hemispheric retinal vein occlusion potentially associated with vaccination with the second dose of the SARS-Cov-2 mRNA-1237

vaccine [10], in a patient receiving oral anticoagulant therapy for atrial fibrillation.

The study protocol complied with the tenets of the Declaration of Helsinki of 1964 and its later amendments. Informed consent was obtained from the patient for her case to be presented and discussed.

OBSERVATIONS

A 74-year-old woman presented with a painless vision loss in the right eye experienced 48 hours after receiving the second dose of the mRNA-1237 vaccine. Additional systemic symptoms included severe arthralgia, chills and swelling.

The patient denied any previous history of SARS-CoV2 infection, diabetes mellitus or poor glycemic control, blood hypertension and glaucoma. Past medical history was remarkable for breast cancer successfully treated with surgery and postoperative locoregional radiotherapy in 2017 achieving complete remission, and for current atrial fibrillation (AF) with a ventricular rate of 90 beats per minute (NYHA class II) that was managed with metoprolol 50 mg per day and oral anticoagulation with rivaroxaban 20 mg per day. The patient is a non-smoker, and the body mass index was within normal limits. The patient received the first vaccine dose without noteworthy side effects and completed the vaccination schedule after 4 weeks.

At presentation, the best-corrected visual acuity (BCVA) was 20/32 in the right eye. Ophthalmic examination, including fundus examination and structural optical coherence tomography (OCT), was performed. Ultra-wide field multicolour examination showed venous congestion and widespread blot haemorrhages in the inferior quadrants (Fig. 1a). Structural OCT revealed thickening of the occluded area (Fig. 1b). Based on these findings, the diagnosis of hemispheric retinal vein occlusion (RVO) was made. The fellow-eye was unremarkable. Intraocular pressure (IOP) and blood pressure (BP) were within normal range. No additional antithrombotic medication was administered since the patient was already receiving oral anticoagulation therapy. No additional

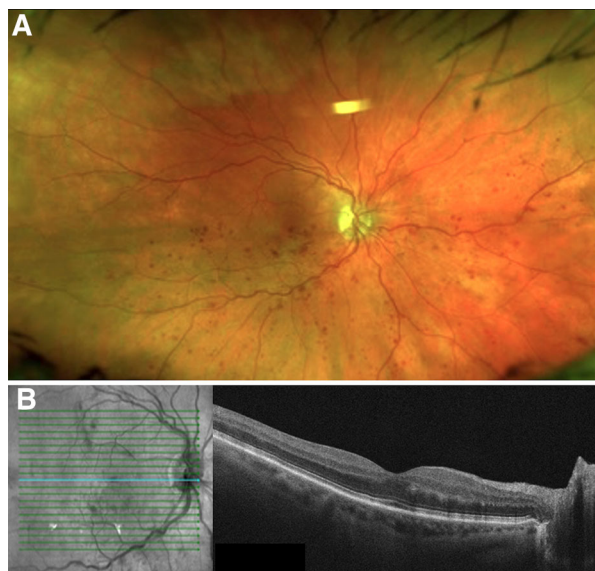


Fig. 1 Baseline ultra-wide field multicolour image and structural optical coherence tomography (OCT) of the right eye. **a** Ultra-wide field multicolour examination showing venous congestion and widespread blot haemorrhages in the inferior quadrants. **b** Infrared reflectance and horizontal structural OCT passing through the fovea showing thickening of retinal layers nasally to the fovea

laboratory/functional tests were performed at this point because the patient was under frequent supervision by her physician.

At the 3-week follow-up, BCVA declined to 20/40 and structural OCT revealed the presence of cystoid ME with intraretinal fluid. No treatment was performed and fluorescein angiography (FA) was planned. At the 5-week examination, FA was performed, showing delayed vein filling, masking effect from intraretinal haemorrhages and vascular leakage in the inferior quadrants (Fig. 2). Structural OCT examination showed the extension of ME involving a large serous retinal detachment with intraretinal cysts (Fig. 2). This examination revealed disturbance in the platelet count, with a platelet count of $144 \times 10^9/L$. The patient was treated with two injections of intravitreal ranibizumab, which led to functional improvement of BCVA to 20/32 and regression of ME.

DISCUSSION

Retinal vein occlusion is commonly associated with hypercoagulable states, hypertension, open-angle glaucoma, diabetes mellitus and a history of cardiovascular disease [11, 12]. The treatment of ME secondary to RVO is mainly based on repeated injections of intravitreal anti-vascular endothelial growth factor (anti-VEGF) injections [13–15].

Here we report a case of retinal vein occlusion potentially associated with receiving the second dose of the mRNA-1237 vaccine, noting that our patient was currently receiving anti-coagulant therapy for AF. Although a causal connection between the two events cannot be proven definitely, it should be noted that this was the first thrombotic episode experienced by our patient. Clinical assessment was not suggestive of alternative triggering causes for venous occlusion or underlying disease exhibiting thrombogenicity [16]. It was not possible to obtain a rivaroxaban-calibrated drug level, which is not performed routinely, but the patient claimed to adhere diligently to the prescribed therapeutic regimen.

Retinal vein occlusion has been reported earlier in a patient who received the BNT162b2 BioNTech/Pfizer vaccine [17] and has been declared an adverse event for mRNA vaccines on 37 occasions, as registered in the Global Database for Individual Case Safety Reports (VigiBase), an open-label databank provided by World Health Organization.

It has been well elucidated how vein thrombosis in unusual sites and thrombocytopenia may be adverse events associated with adenoviral vector vaccines [18]. Vaccine-induced thrombotic thrombocytopenia mediated by platelet-activating antibodies against platelet factor 4 (PF4) has been put forward to explain the pathogenesis of this condition [19]. These findings although anecdotal would provide an explanation of the possible—albeit extremely low—incidence associated with mRNA vaccines, namely PF4 antibodies can also occur after mRNA vaccination but are of minor clinical relevance in this group [20, 21].

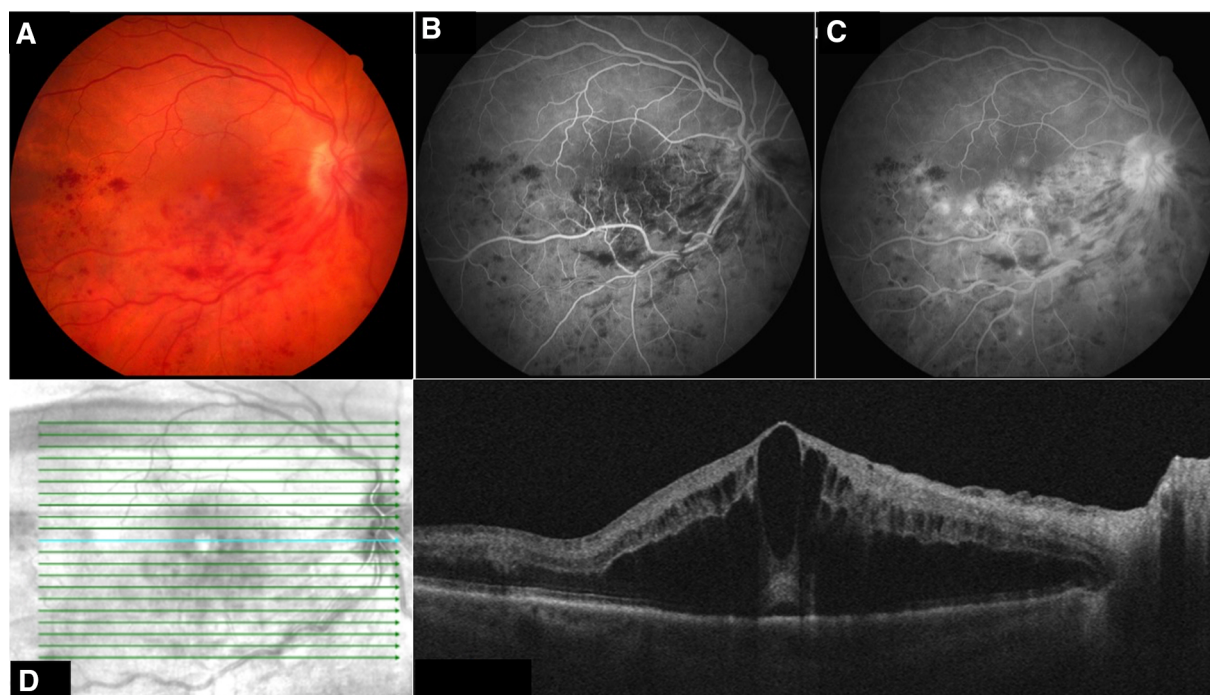


Fig. 2 Baseline ultra-wide field multicolor image and structural OCT of the right eye. **a** Fundus photography showing the persistence of venous congestion and widespread blot haemorrhages in the inferior quadrants. **b, c** Early (36 s) and late (5 min and 10 s) phases of fluorescein angiography showing delayed vein filling,

masking effect from intraretinal haemorrhages and vascular leakage in the inferior quadrants. **d** Infrared reflectance horizontal structural OCT passing through the fovea showing the presence of macular edema involving the fovea with a subfoveal neuroretinal detachment

In our case, we were not able to record a platelet count in the acute setting and, consequently, to determine the eventual timing of platelet nadir and recovery. However, a mild thrombocytopenia (i.e. $144 \times 10^9/L$) was observed 9 weeks after the vaccination. This finding is consistent with previous reports [22]. Additionally, differentiating between a vaccine-induced or coincidental thrombocytopenia in these patients can be challenging [22].

In conclusion, we report a case of retinal vein occlusion 48 hours after vaccination with the SARS-Cov-2 mRNA-1237 vaccine, but note that the relationship between these two events is unclear. In light of the global promotion of the third dose of mRNA-based vaccinations, further research is warranted to better document and understand the potential pathogenic link between retinal vascular events and vaccination. Finally, we speculate that patients with cardiovascular diseases (i.e. high-risk group)

should be investigated in more detail before being vaccinated with SARS-Cov-2 vaccines.

ACKNOWLEDGEMENTS

Funding. No funding or sponsorship was received for this study or publication of this article.

Authorship. All named authors meet the International Committee of Medical Journal Editors (ICMJE) criteria for authorship for this article, take responsibility for the integrity of the work as a whole, and have given their approval for this version to be published.

Author Contributions. Riccardo Sacconi, Filippo Simona: concept and design, drafting of the manuscript. Paolo Forte,

Giuseppe Querques: concept and design and critical revision of the paper.

Disclosures. Riccardo Sacconi is a consultant for Allergan Inc., Carl Zeiss Meditec and Novartis. Filippo Simona and Paolo Forte have nothing to disclose. Giuseppe Querques is a consultant for Alimera Sciences, Allergan Inc., Amgen, KBH, LEH Pharma, Lumithera, Novartis, Bayer Shering-Pharma, Sandoz, Sifi, Soof-Fidia and Zeiss.

Compliance with Ethics Guidelines. The study protocol complied with the tenets of the Declaration of Helsinki of 1964 and its later amendments. Informed consent was obtained from the patient for her case to be presented and discussed.

Data Availability. Data sharing is not applicable to this article as no datasets were generated or analysed during the current study.

Open Access. This article is licensed under a Creative Commons Attribution-NonCommercial 4.0 International License, which permits any non-commercial use, sharing, adaptation, distribution and reproduction in any medium or format, as long as you give appropriate credit to the original author(s) and the source, provide a link to the Creative Commons licence, and indicate if changes were made. The images or other third party material in this article are included in the article's Creative Commons licence, unless indicated otherwise in a credit line to the material. If material is not included in the article's Creative Commons licence and your intended use is not permitted by statutory regulation or exceeds the permitted use, you will need to obtain permission directly from the copyright holder. To view a copy of this licence, visit <http://creativecommons.org/licenses/by-nc/4.0/>.

REFERENCES

- Sen S, Kannan NB, Kumar J, et al. Retinal manifestations in patients with SARS-CoV-2 infection and pathogenetic implications: a systematic review. *Int Ophthalmol.* 2021. <https://doi.org/10.1007/s10792-021-01996-7>.
- Aidar MN, Gomes TM, de Almeida MZH, et al. Low visual acuity due to acute macular neuroretinopathy associated with COVID-19: a case report. *Am J Case Rep.* 2021;22: e931169.
- Virgo J, Mohamed M. Paracentral acute middle maculopathy and acute macular neuroretinopathy following SARS-CoV-2 infection. *Eye.* 2020;34(12): 2352–3.
- Invernizzi A, Torre A, Parrulli S, et al. Retinal findings in patients with COVID-19: results from the SERPICO-19 study. *EClinicalMedicine.* 2020;27: 100550.
- Yahalomi T, Pikkel J, Arnon R, Pessach Y. Central retinal vein occlusion in a young healthy COVID-19 patient: a case report. *Am J Ophthalmol Case Rep.* 2020;20:100992.
- Araujo-Silva CA, Marcos AAA, Marinho PM, et al. Presumed SARS-CoV-2 viral particles in the human retina of patients with COVID-19. *JAMA Ophthalmol.* 2021;139(9):1015–21.
- Casagrande M, Fitzek A, Püschel K, et al. Detection of SARS-CoV-2 in human retinal biopsies of deceased COVID-19 patients. *Ocul Immunol Inflamm.* 2020;28(5):721–5.
- Jampol LM, Tauscher R, Schwarz HP. COVID-19, COVID-19 vaccinations, and subsequent abnormalities in the retina: causation or coincidence? *JAMA Ophthalmol.* 2021;139(10):1135–36. <https://doi.org/10.1001/jamaophthalmol.2021.3483>.
- Baden LR, El Sahly HM, Essink B, et al. Efficacy and safety of the mRNA-1273 SARS-CoV-2 vaccine. *N Engl J Med.* 2021;384(5):403–16.
- US Food and Drug Administration. FDA briefing document Moderna COVID-19 vaccine. 2020. <https://www.fda.gov/media/144434/download>. Accessed 10 Oct 2021.
- Querques G, Triolo G, Casalino G, et al. Retinal venous occlusions: diagnosis and choice of treatments. *Ophthalmic Res.* 2013;49(4):215–22.
- Jaulim A, Ahmed B, Khanam T, Chatziralli IP. Branch retinal vein occlusion: epidemiology, pathogenesis, risk factors, clinical features, diagnosis, and complications. An update of the literature. *Retina.* 2013;33(5):901–10.
- Ho M, Liu DT, Lam DS, Jonas JB. Retinal vein occlusions, from basics to the latest treatment. *Retina.* 2016;36(3):432–48.

14. Coscas G, Loewenstein A, Augustin A, et al. Management of retinal vein occlusion—consensus document. *Ophthalmologica*. 2011;226(1):4–28.
15. Querques G, Sacconi R, Borrelli E, Bandello F. Management of patients with macular oedema secondary to central retinal vein occlusion: new findings from SCORE2 and LEAVO studies. *Eye*. 2020;34(2):215–6.
16. Schulman S. How I treat recurrent venous thromboembolism in patients receiving anticoagulant therapy. *Blood*. 2017;129(25):3285–93.
17. Bialasiewicz AA, Farah-Diab MS, Mebarki HT. Central retinal vein occlusion occurring immediately after 2nd dose of mRNA SARS-CoV-2 vaccine. *Int Ophthalmol*. 2021;41(12):3889–92.
18. See I, Su JR, Lale A, et al. US case reports of cerebral venous sinus thrombosis with thrombocytopenia after Ad26.COV2.S vaccination. *JAMA*. 2021;325(24):2448–56.
19. Greinacher A, Thiele T, Warkentin TE, Weisser K, Kyrle PA, Eichinger S. Thrombotic thrombocytopenia after ChAdOx1 nCov-19 vaccination. *N Engl J Med*. 2021;384(22):2092–101.
20. Thiele T, Ulm L, Holtfreter S, et al. Frequency of positive anti-PF4/polyanion antibody tests after COVID-19 vaccination with ChAdOx1 nCoV-19 and BNT162b2. *Blood*. 2021;138(4):299–303.
21. Abbattista M, Martinelli I, Peyvandi F. Comparison of adverse drug reactions among four COVID-19 vaccines in Europe using the EudraVigilance database: thrombosis at unusual sites. *J Thromb Haemost*. 2021;19(10):2554–58. <https://doi.org/10.1111/jth.15493>.
22. Lee EJ, Cines DB, Gernsheimer T, et al. Thrombocytopenia following Pfizer and Moderna SARS-CoV-2 vaccination. *Am J Hematol*. 2021;96(5):534–7.