

# Ultrasound characteristics of cervical lesions in patients with radioiodine refractory differentiated thyroid cancer

## A strobe-compliant article

Luying Gao, MD<sup>a</sup>, Yansong Lin, MD<sup>b</sup>, Yuxin Jiang, MD<sup>a</sup>, Hui Li, MB<sup>b</sup>, Qiong Gao, MB<sup>a</sup>, Xuehua Xi, MB<sup>a</sup>, Ying Wang, MD<sup>a</sup>, Xiao Yang, MD<sup>a</sup>, Xingjian Lai, MD<sup>a</sup>, Shenling Zhu, MB<sup>a</sup>, Xiaoyan Zhang, MD<sup>a</sup>, Ruina Zhao, MD<sup>a</sup>, Bo Zhang, MD<sup>a,c,\*</sup>

### Abstract

Radioiodine refractory (RAIR) is the major cause of thyroid cancer-related death. In order to avoid needless Radioiodine (RAI) therapy, recognizing the RAIR cases in time is important for the patients to obtain more time for the effective therapy.

Evaluate the ultrasound features of cervical metastatic lymph node in patients with RAIR differentiated thyroid cancer (DTC).

Seventeen adult patients with histologically confirmed locally advanced or metastatic RAIR-DTC were prospectively enrolled. The ultrasound (US) characteristics of cervical lesions in patients with the RAIR-DTC were compared with cervical lymph node metastasis from 59 non RAIR-DTC cases.

Among the 17 patients, cervical lymph node metastasis was found in 15 patients (88.3%). The cervical lesions of RAIR-DTC (mean size, 2.0cm) were larger than that in non RAIR-DTC group (mean size, 1.30cm). More multiple lesions and more lesions with visible flow were found in the RAIR Group, while fewer hyperechogenic punctuations were found in RAIR group ( $P < .05$ ). The distant metastasis rates showed that RAIR-DTC led to a poorer prognosis than those of patients in the non RAIR Group ( $P < .01$ ).

Ultrasound can help distinguish metastasized cervical lymph nodes of RAIR-DTC patients from non RAIR-DTC patients. For RAIR-DTC patients, a long-term US evaluation should be performed.

**Abbreviations:** CT = computed tomography, DTC = differentiated thyroid cancer, FNAB = fine needle aspiration biopsy, LNs = lymph nodes, MRI = magnetic resonance imaging, PDC = poorly differentiated carcinoma, PET = F-fluorodeoxyglucose positron emission tomography, PTC = papillary thyroid cancer, RAI = radioiodine, RAIR = radioiodine refractory, SD = standard deviation, Tg = thyroglobulin, TSH = thyroid stimulating hormone, US = ultrasound.

**Keywords:** cervical metastatic lymph node, differentiated thyroid carcinoma, radioiodine refractory differentiated thyroid cancer, thyroid cancer, ultrasound

## 1. Introduction

Thyroid nodules are a very common medical problem with a prevalence of 19% to 68% in the general population.<sup>[1,2]</sup> Approximately 7% to 15% of thyroid nodules are thyroid

cancer, and it has been estimated that 96% of all new endocrine organ cancers originate from the thyroid gland.<sup>[3,4]</sup> Despite the generally favorable course of thyroid cancer, up to 10% to 30% of patients with differentiated thyroid cancer (DTC) may have recurrence, including local recurrence and distant metastases. For these patients, there are multiple therapeutic options, such as surgery, radioactive iodine (RAI) therapy, and radiotherapy.<sup>[5]</sup> However, only about 30% of these patients had a complete response (according to response evaluation criteria in solid tumors 1.1, RECIST 1.1). The remaining patients will become RAI-refractory (RAIR), and it can be fatal if recurrent lesions are progressive.<sup>[6-12]</sup> RAIR is the major cause of thyroid cancer-related death, which is also a challenge in the current management of the thyroid nodules.

In order to avoid needless RAI therapy, recognizing the RAIR cases in time is important for the patients to obtain more time for the effective therapy. Ultrasound (US) is useful for discriminating between benign and malignant lesions and is used as guidance for fine-needle aspiration biopsy (FNAB).<sup>[13-15]</sup> Previous studies demonstrated the good diagnostic efficacy of US for cervical lymph node metastasis.<sup>[16]</sup> Moreover, US is the preferred screening modality for postoperative follow-up and can help identify cervical lesions that are likely to be malignant.<sup>[17-22]</sup> However, to our knowledge, the ultrasound characteristics of these cervical lesions of RAIR patients have not been reported. We reviewed the clinical, US and prognostic characteristics of

Editor: Neeraj Lalwani.

This work was supported by National Natural Science Foundation of China (No. 81571714 and 81771875)

The authors declare no competing interests.

<sup>a</sup> Department of Ultrasound, <sup>b</sup> Department of Nuclear Medicine, Chinese Academy of Medical Sciences & Peking Union Medical College Hospital, <sup>c</sup> Department of Ultrasound, China-Japan Friendship Hospital, Beijing, China.

\* Correspondence: Bo Zhang, Peking Union Medical College Hospital, Beijing 100730, China (e-mail: thyroldus@163.com).

Copyright © 2019 the Author(s). Published by Wolters Kluwer Health, Inc. This is an open access article distributed under the terms of the Creative Commons Attribution-Non Commercial License 4.0 (CCBY-NC), where it is permissible to download, share, remix, transform, and buildup the work provided it is properly cited. The work cannot be used commercially without permission from the journal.

How to cite this article: Gao L, Lin Y, Jiang Y, Li H, Gao Q, Xi X, Wang Y, Yang X, Lai X, Zhu S, Zhang X, Zhao R, Zhang B. Ultrasound characteristics of cervical lesions in patients with radioiodine refractory differentiated thyroid cancer- a strobe-compliant article. *Medicine* 2019;98:45(e17876).

Received: 24 April 2019 / Received in final form: 23 September 2019 / Accepted: 10 October 2019

<http://dx.doi.org/10.1097/MD.00000000000017876>

patients with locally advanced or metastatic RAI-DTC. In order to help distinguish metastasized cervical lymph nodes of RAI-DTC patients from non RAI-DTC patients.

## 2. Patients and methods

Institutional review board approval of our center ethics review committee was obtained for this study ethics review committee was obtained for this study, and the informed consents were obtained from all patients before enrollment. This study was conducted in accordance with the Declaration of Helsinki. This study is registered with Clinical Trials.gov (No. NCT02731352).

### 2.1. Patients and study design

Patients aged 18 years or older with histologically confirmed locally advanced or metastatic RAI-DTC were prospectively recruited in this study. The inclusion criteria included at least 1 progressive lesion according to the RECIST (version 1.1); and meet the following definition of RAI-DTC.

Patients were classified as RAI-DTC if they met 1 of the following criteria:

1. had at least 1 measurable lesion without iodine uptake on 131I scan,
2. had 1 measurable lesion that had progressed within the past 12 months even it could take up radioiodine, or
3. received cumulative activity of 131I over 600 mCi.

Seventeen patients with histologically confirmed locally advanced or metastatic RAI-DTC were enrolled

Follow-up evaluations included measurement of thyroglobulin (Tg), anti-Tg antibody, and thyroid stimulating hormone (TSH) levels and periodic neck ultrasonography. Whole-body scans, computed tomography (CT), magnetic resonance imaging (MRI), or F-fluorodeoxyglucose positron emission tomography (PET) were performed for all patients with suspicion of recurrence.

Among the 17 patients, 15 patients had cervical lymph node metastasis, and 2 other patients had RAI-DTC with visible pulmonary lesions on CT. The 15 patients with cervical lymph node metastasis were defined as the RAI-DTC group in the study. The US characteristics of the RAI-DTC Group before RAI treatment were obtained. The clinical and US characteristics of the RAI-DTC Group before RAI treatment were compared with cases of non RAI-DTC cervical lymph node metastasis (Control Group). Patients who met the following criteria were included in the control group:

1. thyroidectomy performed during the first surgery due to pathologically confirmed DTC; and
2. recurrent or persistent metastatic cervical lymph nodes (LNs) derived from DTC were histologically confirmed during postoperative RAI therapy.

A gender- and age-matched control group comprising 59 patients was randomly selected.

### 2.2. Thyroid US examination and evaluation

All US examinations were performed with Phillips IU 22 (Philips Healthcare, Eindhoven, Netherlands), GE Logiq 9 (GE Healthcare, Milwaukee, WI, USA) devices equipped with 5 to 12 MHz linear-array transducer (TIS=0.1, MI=0.06). The patients were positioned in a supine position with dorsal flexion of the head.

The dynamic range, gain, depth, and focal zone were adjusted to optimize image quality during the examination. The maximum size of lesions was examined by US at the same site on each patient. The size, location, cystic appearance, hyperechogenic punctuations, hyperechogenic hilum, and vascularity were evaluated by US. US images were evaluated by 2 radiologists who were experienced in thyroid US and were blinded to the patients' clinical data and pathological results. In cases of a discrepancy between the 2 readers, a consensus was reached after a discussion.

### 2.3. Statistical analysis

Quantitative data are presented as the mean  $\pm$  standard deviation (SD). Qualitative data are presented as frequencies. The Shapiro–Wilk test was used to determine the presence of a normal distribution. For parametric data, an unpaired *t* test was used to evaluate differences between the 2 groups. For nonparametric data, differences between groups were analyzed using a Mann–Whitney *U* test. The Chi-Squared test with Yates correction and Fisher exact test were used to compare categorical variables. The study analyzed distant metastasis rates using the Kaplan–Meier method and log-rank testing. A value of  $P < .05$  was considered statistically significant. Statistical analyses were performed with SPSS software (Version 19.0, SPSS Chicago, IL, USA).

## 3. Results

### 3.1. Clinical characteristics of RAI patients of different pathological types

Of the 17 patients included in our study, the postoperative pathological results revealed that 15 patients had PTC (papillary thyroid cancer), and 2 patients had poorly differentiated carcinoma (PDC). The characteristics of the 17 patients according to their pathological types are shown in Table 1. The patients included 11 (64.7%) females and 6 (35.2%) males with a median age of 52.4 years. The median interval between

**Table 1**  
Clinical characteristics of 17 patients according to pathological type.

	PTC	PDC
Patients (No.)	15	2
Age, y (median,range)	57.0 (33.0–78.0)	46.0 (39.0–53.0)
Sex (female/male)	10/5	1/1
Initial Surgery		
Lobectomy	5	0
Near-total thyroidectomy	3	2
Total thyroidectomy	7	0
Tg level during follow-up		
Elevated	4	0
Negative	11	2
Distant metastasis	15	2
Time interval between initial surgery and onset of illness (months, range)	34 (1.0–264.0)	1 (1.0–1.0)
Time interval between RAI and onset of illness (years, range)	10.4 (2.0–33.0)	4.5 (2.0–7.0)
Other treatments before RAI		
131I-therapy	6	1
No	9	1

PDC=poorly differentiated carcinoma, Tg=thyroglobulin.

diagnosis of RAIR and onset of illness (in terms of time frame from first diagnosis) was 9.6 years (range, 2 years~33 years). The median interval between initial surgery and onset of illness was 29.9 months (range, 1 months~264 months). Cervical lymph node metastasis was found in 15 patients (88.3%). The initial surgical procedures included lobectomy (5 patients, 23.5%), near-total thyroidectomy (5 patients, 29.4%), total thyroidectomy (7 patients, 41.1%) (Table 2).

### 3.2. US characteristics and differences between RAIR Group and Control Group

Among the 17 patients, cervical lymph node metastasis was found in 15 patients (88.3%). Of these lesions, 6 (40.0%) cases were found at central neck levels, 3 (20.0%) cases were found at lateral neck levels, and 6 (40.0%) cases were found at both central and lateral neck levels (Fig. 1).

We compared the US features of metastasized cervical LNs of RAIR patients with 59 lesions of metastasized cervical LNs from non RAI-DTC patients (Control Group). The sizes of the lymph nodes in the RAIR Group and Control Group were  $2.0 \pm 0.9$  cm

and  $1.3 \pm 0.7$  cm, respectively ( $P = .03$ ). The incidence of hyperechogenic punctuations was significantly higher ( $P = .004$ ) in the Control Group than that in the RAIR Group. More lesions with visible flow were found in the RAIR Group ( $P = .04$ ). More multiple lesions were found in the RAIR Group than that in the Control Group. Regarding the T staging of the thyroid nodules, more nodules with T1 were in the Control Group than that in the RAIR Group. The median serum Tg levels of the RAIR Group and Control Group were 459.2 IU/ml (3.9–2628.0 IU/ml) and 6.1 IU/ml (range 1.1–15.3 IU/ml), respectively ( $P = .03$ ). Hyperechogenic hilum was absent in the majority of patients in both groups, but no statistical significance was detected between the 2 groups regarding hyperechogenic hilum (Table 2).

### 3.3. Clinical courses for RAIR-DTC patients

All 17 patients included in our study were followed-up. The median follow-up period after onset of illness was 179 months. At the time of initial thyroid surgery, none of the patients showed distant metastasis. 17 (100.0%) patients developed distant metastasis (17 in the lung, 5 in bone tissue and 1 in the brain) during follow-up.

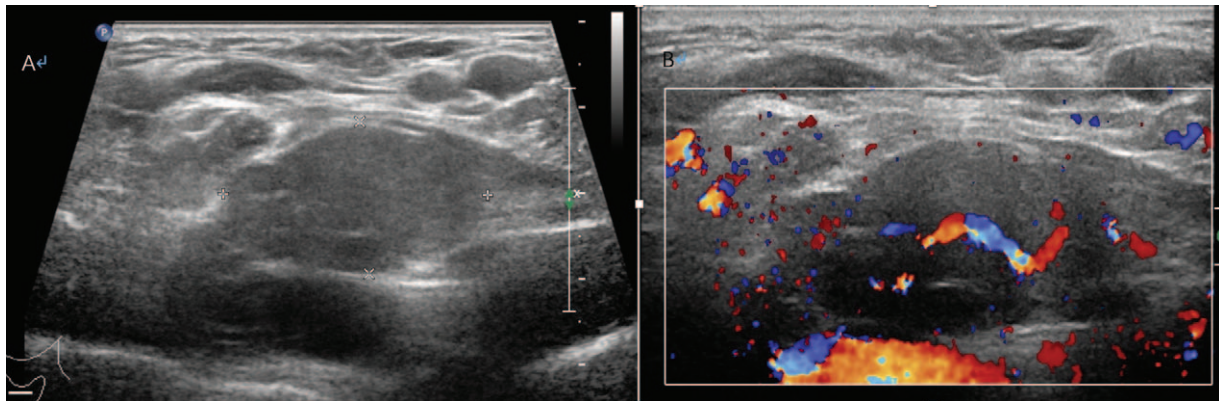
**Table 2**  
US characteristics of patients with different pathologic types in the RAIR Group and Control Group.

	RAIR Group (N = 15)		Control Group (N = 59)	P value (RAIR vs Control)
	PTC (N = 13)	PDC (N = 2)		
Age, y (median, range)	55.0 (33.0–78.0)	46.0 (39.0–53.0)	42.5 (18.0–63.0)	.48
Sex (female/male)	9/4	1/1	47/12	.21
Size, cm (median, range)	1.9 (0.6–4.4)	2.7 (2.5–2.9)	1.3 (0.4–4.4)	.03
Location				.01
Central nodal compartments	6	0	32	
Lateral nodal compartments	2	1	27	
Both central and lateral nodal compartments	5	1	0	
Hyperechogenic hilum				.28
Present	1	0	13	
Absent	12	2	46	
Cystic appearance				.62
No	12	1	54	
Yes	1	1	5	
Hyperechogenic punctuations				.004
Present	3	0	37	
Absent	10	2	22	
Lesions				.02
Multiple	10	1	38	
Single	3	1	21	
Vascularity*				.04
No visible flow	2	0	19	
Internal flow	4	1	18	
Peripheral ring of flow	1	0	9	
Internal flow with a peripheral ring	6	1	7	
TNM staging**				.001
T1	0	0	20	
T2	1	1	7	
T3	2	0	4	
T4	7	0	8	
T5	3	1	0	
Serum Tg at recurrence, IU/ml (median, range)*	494.2 (3.9–2628.0)	3.9	6.1 (1.1–15.3)	.03
Serum Tg-Ab at recurrence, IU/ml (median, range)*	19.8 (10.1–50.2)	20.4	80.1 (10.9–418.9)	.28

\* Some of information could not be obtained.

\*\* Based on the tumor node metastasis (TNM) staging system described in the Cancer Staging Manual of the American Joint Committee on Cancer (AJCC; 6th edition, 2002); Some of TNM information could be obtained.

Ab = antibody, PDC = poorly differentiated carcinoma, RAIR = radioiodine refractory, Tg = thyroglobulin.



**Figure 1.** Scans from a 32-year-old woman with a left recurrence lesion. A. Grayscale sonography showed the lesion measuring 4.1 cm with clear boundary. B. The blood flow was rich on CDU.

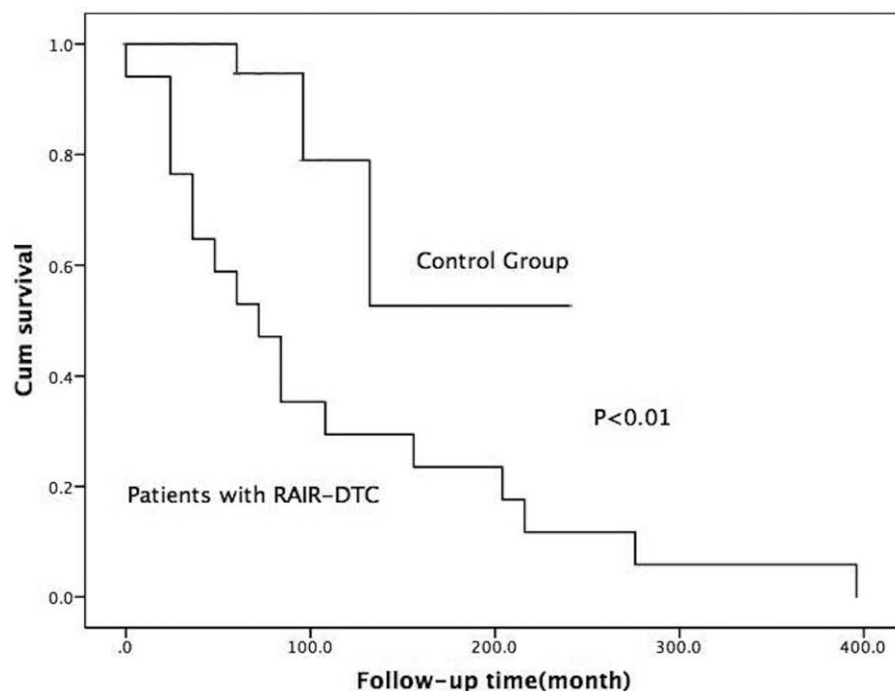
Moreover, the distant metastasis rates of 17 patients were compared with 59 patients in the Control Group. The median follow-up periods after recurrence were 179 months and 109 months in the Group with RAIR and the Control Group, respectively. In the Control Group with lymph node metastasis, 3 (5.1%) patients developed distant metastasis (3 in lung tissue). The prognosis of DTC patients with RAIR-DTC were significantly worse than those of patients in Control Group ( $P = .001$ ) (Fig. 2).

#### 4. Discussion

An earlier identification of RAIR is highly necessary, which help timely prevent the patients from ineffective RAI therapy. In previous study, Smoking, tumor type (follicular thyroid cancer),

extrathyroid extension, lymph node metastasis, and pN stage were highly correlated with the prevalence of RAIR DTC.<sup>[23]</sup> It may help obtain more time for the effective therapeutic options, such as tyrosine kinase inhibitor. Ultrasound (US) shows a high accuracy in cervical lymph node recurrence and diagnosing soft tissue lesions such as musculoskeletal disorders.<sup>[24–26]</sup> In 1 study with 76 postoperative PTC patients, the results showed that US showed higher diagnostic accuracy, sensitivity and specificity in diagnosing cervical lymph node recurrence with PTC, compared with those of PET (71.1%, 71.7%, and 69.6% vs 55.3%, 56.6%, and 52.2%). PET added diagnostic information in a limited number of patients with negative results on neck US.<sup>[27]</sup>

Thus, we explored the difference in sonographic features between metastasized cervical LNs of RAIR-DTC patients and of



**Figure 2.** Clinical courses for RAIR-DTC patients.

non RAIR-DTC patients. Cervical lymph node metastasis was found in 88.3% of RAIR-DTC patients. Our result showed that LN size was a predictor, and the size of LN in RAIR-DTC patients (mean size, 2.0cm) was larger than that in non RAIR-DTC patients (mean size, 1.30 cm), and more multiple lesions and more nodules with visible flow were found in the RAIR-DTC Group. Less hyperechogenic punctuations were found in RAIR-DTC group. While, regarding the T staging of the nodules more patients with T1 staging were in the Control Group than that in the RAIR Group.

Distant metastasis rates for RAIR-DTC patients showed that the prognosis of these patients was significantly worse than those of patients with metastatic LNs alone in the Control Group ( $P < .01$ ). Additionally, Moreover, none of the 17 patients died of RAIR-DTC during follow-up.

There are several limitations of our study. The main limitations of this study were the relatively small number of patients and the short follow-up period. Future studies with larger sample sizes and long-term follow-up are necessary to verify these results. Second, it may have been affected by selection bias as only patients who underwent both ultrasound and surgery were enrolled in the study.

In conclusion, RAIR patients had poorer prognosis than those with non-RAIR metastasis LNs alone. Cervical LN metastasis was found in most of RAIR-DTC patients. Ultrasound may help distinguish metastasized cervical LNs of RAIR patients. To minimize risk of RAIR, a long-term postoperative US evaluation should be completed.

## Author contributions

**Conceptualization:** Yansong Lin, Bo Zhang.

**Data curation:** Luying Gao, Hui Li, Qiong Gao, Xuehua Xi, Ying Wang, Xiao Yang, Xiaoyan Zhang, Ruina Zhao.

**Formal analysis:** Luying Gao, Xuehua Xi, Bo Zhang.

**Funding acquisition:** Yuxin Jiang, Bo Zhang.

**Methodology:** Luying Gao.

**Resources:** Shenling Zhu, Bo Zhang.

**Supervision:** Yuxin Jiang, Xingjian Lai, Bo Zhang.

**Writing – original draft:** Luying Gao.

**Writing – review & editing:** Yansong Lin, Xiao Yang, Xingjian Lai, Bo Zhang.

## References

- Tan GH, Gharib H. Thyroid incidentalomas: management approaches to nonpalpable nodules discovered incidentally on thyroid imaging. *Ann Intern Med* 1997;126:226–31.
- Guth S, Theune U, Aberle J, et al. Very high prevalence of thyroid nodules detected by high frequency (13MHz) ultrasound examination. *Eur J Clin Invest* 2009;39:699–706.
- Hegedüs L. The thyroid nodule. *NEJM* 2004;351:1764–71.
- Leenhardt L, Erdogan MF, Hegedus L, et al. European thyroid association guidelines for cervical ultrasound scan and ultrasound-guided techniques in the postoperative management of patients with thyroid cancer. *Eur Thyroid J* 2013;2:147–59.
- Haugen BR, Alexander EK, Bible KC, et al. American Thyroid Association management guidelines for adult patients with thyroid nodules and differentiated thyroid cancer: the American Thyroid Association guidelines task force on thyroid nodules and differentiated thyroid cancer. *Thyroid* 2015;26:1–33.
- Ito Y, Kudo T, Kihara M, et al. Improvement of lymph node recurrence rate, but not distant recurrence and carcinoma death rates, in patients with papillary thyroid carcinoma after disease-free survival for 5 years. *Endocr J* 2012;59:895–901.
- Smith VA, Sessions RB, Lentsch EJ. Cervical lymph node metastasis and papillary thyroid carcinoma: does the compartment involved affect survival? Experience from the SEER database. *J Surg Oncol* 2012;106:357–62.
- Liu FH, Kuo SF, Hsueh C, et al. Postoperative recurrence of papillary thyroid carcinoma with lymph node metastasis. *J Surg Oncol* 2015;112:149–54.
- Uchida H, Imai T, Kikumori T, et al. Long-term results of surgery for papillary thyroid carcinoma with local recurrence. *Surg Today* 2013;43:848–53.
- Cooper DS, Doherty GM, Haugen BR, et al. American Thyroid Association (ATA) Guidelines Taskforce on Thyroid Nodules and Differentiated Thyroid Cancer Revised American Thyroid Association management guidelines for patients with thyroid nodules and differentiated thyroid cancer. *Thyroid Off J Am Thyroid Assoc* 2009;19:1167–214.
- Schlumberger M, Brose M, Elisei R, et al. Definition and management of radioactive iodine-refractory differentiated thyroid cancer. *Lancet Diabetes Endocrinol* 2014;2:356–8.
- Durante C, Haddy N, Baudin E, et al. Long-term outcome of 444 patients with distant metastases from papillary and follicular thyroid carcinoma: benefits and limits of radioiodine therapy. *J Clin Endocrinol Metab* 2006;91:2892–9.
- Gao L, Xi X, Jiang J, et al. Comparison among TIRADS (ACR TI-RADS and KWAK- TI-RADS) and 2015 ATA Guidelines in the diagnostic efficiency of thyroid nodules. *Endocrine* 2019;64:90–6.
- Larsen PR. New guidelines for patients with thyroid nodules and differentiated thyroid cancer. *Nat Clin Practice Endocrinol Metab* 2006;2:297.
- Lu R, Xiao Y, Liu M, et al. Ultrasound elastography in the differential diagnosis of benign and malignant cervical lesions. *J Ultrasound Med* 2014;33:667–71.
- Zhao H, Li H. Meta-analysis of ultrasound for cervical lymph nodes in papillary thyroid cancer: diagnosis of central and lateral compartment nodal metastases. *Eur J Radiol* 2019;112:14–21.
- Takahashi R, Iwahori Y, Kajita Y, et al. Clinical results and complications of shoulder manipulation under ultrasound-guided cervical nerve root block for frozen shoulder: a retrospective observational study. *Pain Ther* 2019;8:111–20.
- Gao Z, Wu S, Liu Z, et al. Learning the implicit strain reconstruction in ultrasound elastography using privileged information. *Med Image Anal* 2019;19:101534.
- Gao Z, Li Y, Sun Y, et al. Motion tracking of the carotid artery wall from ultrasound image sequences: a nonlinear state-space approach. *IEEE Trans Med Imaging* 2018;37:273–83.
- Gao Z, Liu X, Qi S, et al. Automatic segmentation of coronary tree in CT angiography images. *Int J Adapt Control Signal Process* 2017;33:1239–47.
- Gao Z, Xiong H, Liu X, et al. Robust estimation of carotid artery wall motion using the elasticity-based state-space approach. *Med Image Anal* 2017;37:1–21.
- Gao L, Wang Y, Jiang Y, et al. Cervical soft tissue recurrence of differentiated thyroid carcinoma after thyroidectomy indicates a poor prognosis-cross sectional study. *Int J Surg* 2017;48:254–9.
- Li G, Lei J, Song L, et al. Radioiodine refractoriness score: a multivariable prediction model for postoperative radioiodine-refractory differentiated thyroid carcinomas. *Cancer Med* 2018;7:5448–56.
- Chang KV, Wu WT, Huang KC, et al. Limb muscle quality and quantity in elderly adults with dynapenia but not sarcopenia: an ultrasound imaging study. *Exp Gerontol* 2018;15:54–61.
- Chang KV, Wu WT, Han DS, et al. Static and dynamic shoulder imaging to predict initial effectiveness and recurrence after ultrasound-guided subacromial corticosteroid injections. *Arch Phys Med Rehabil* 2017;98:1984–94.
- Wang JC, Chang KV, Wu WT, et al. Ultrasound-guided standard vs dual-target subacromial corticosteroid injections for shoulder impingement syndrome: a randomized controlled trial. *Arch Phys Med Rehabil* 2019;29: pii: S0003-9993(19)30381-8.
- Choi JW, Lee JH, Baek JH, et al. Diagnostic accuracy of ultrasound and 18-F-FDG PET or PET/CT for patients with suspected recurrent papillary thyroid carcinoma. *Ultrasound Med Biol* 2010;36:1608.