



Contents lists available at ScienceDirect

International Journal of Surgery Case Reports

journal homepage: www.casereports.com

Intracranial fat migration: A newly described complication of autologous fat repair of a cerebrospinal fluid leak following supracerebellar infratentorial approach



Cassie A. Ludwig, Parvir Aujla, Mario Moreno, Anand Veeravagu*, Gordon Li

Stanford University School of Medicine, Department of Neurosurgery, Edwards, R229 Stanford, CA 94305-5327, USA

ARTICLE INFO

Article history:

Received 19 September 2014

Received in revised form 7 November 2014

Accepted 6 December 2014

Available online 16 December 2014

Keywords:

Autologous fat graft

Cerebrospinal fluid leak

Graft migration

Posterior fossa

Supracerebellar infratentorial approach

Pineal cyst

ABSTRACT

INTRODUCTION: Intracranial fat migration following autologous fat graft and placement of a lumbar drain for cerebrospinal fluid leak after pineal cyst resection surgery has not been previously reported.

CASE PRESENTATION: The authors present a case of a 39-year-old male with a history of headaches who presented for removal of a pineal cyst from the pineal region. He subsequently experienced cerebrospinal fluid leak and postoperative *Escherichia coli* (*E. Coli*) wound infection, and meningitis, which were treated initially with wound washout and antibiotics in addition to bone removal and primary repair with primary suture-closure of the durotomy. A lumbar drain was left in place. The cerebrospinal fluid leak returned two weeks following removal of the lumbar drain; therefore, autologous fat graft repair and lumbar drain placement were performed. Three days later, the patient began experiencing right homonymous hemianopia and was found via computed tomography and magnetic resonance imaging to have autologous fat in the infra- and supratentorial space, including intraparenchymal and subarachnoid spread. Symptoms began to resolve with supportive care over 48 hours and had almost fully resolved within one week.

DISCUSSION: This is the first known report of a patient with an autologous fat graft entering the subarachnoid space, intraparenchymal space, and ventricles following fat graft and lumbar drainage.

CONCLUSION: This case highlights the importance of monitoring for complications of lumbar drain placement.

© 2015 The Authors. Published by Elsevier Ltd. on behalf of Surgical Associates Ltd. This is an open access article under the CC BY-NC-ND license (<http://creativecommons.org/licenses/by-nc-nd/4.0/>).

1. Introduction

We present a novel complication of intracranial fat migration following placement of a lumbar drain and fat graft due to a cerebrospinal fluid (CSF) leak in a patient who had undergone pineal cyst removal. Pineal cysts typically are asymptomatic and are often discovered incidentally on imaging [1,2]. Manifestations of pineal cysts are usually secondary to mass effect on nearby structures and can include non-specific symptoms such as headaches, nausea, and vomiting [3,4]. Pineal cysts can be removed with radical surgical resection and the procedure is often curative [5].

Complications following surgery include CSF leakage (5.7%), aseptic meningitis (1.9%), and superficial wound infection (1.9%) [6]. Our patient demonstrated postoperative wound infection and CSF leak that eventually required use of an autologous fat graft

and lumbar drain. Complications following placement of lumbar drains include subdural or subarachnoid hemorrhage (1.7%), low-pressure headache (1.7%), and local infection (.8%) [7]. While early CSF leaks can be treated with lumbar drain alone, delayed CSF leaks often require surgery [8]. CSF leaks can be repaired with autologous fat grafts, which have been associated with few complications and have proven to be an effective method of controlling CSF leaks [8]. The use of autologous fat grafts presents 1% complication rates, which include fat necrosis, CSF leakage, and lipoid meningitis [9]. There are currently no case reports in the literature that present a patient with an autologous fat graft entering the subarachnoid and intraparenchymal space theoretically due to reduced pressure from lumbar drainage.

2. Case presentation

Patient P.S. is a 39-year-old male with a history of headaches dating back to 2000. He was diagnosed with a small pineal cyst at that time, and routine follow-up was recommended. In 2010, his headaches worsened, and he began having daily left eye pain and double vision on upward and left lateral gaze. His gait was normal with mild unsteadiness on heel-to-toe tandem walking. Magnetic

Abbreviations: CSF, cerebrospinal fluid; CT, computed tomography; MRI, magnetic resonance imaging.

* Corresponding author. Tel.: +1 650 796 6407; fax: +1 650 723 7813.

E-mail addresses: caludwig@stanford.edu (C.A. Ludwig), aujla.parvir@gmail.com (P. Aujla), mmoreno@stanford.edu (M. Moreno), anand.veeravagu@stanford.edu (A. Veeravagu), gordonli@stanford.edu (G. Li).

<http://dx.doi.org/10.1016/j.ijscr.2014.12.008>

2210-2612/© 2015 The Authors. Published by Elsevier Ltd. on behalf of Surgical Associates Ltd. This is an open access article under the CC BY-NC-ND license (<http://creativecommons.org/licenses/by-nc-nd/4.0/>).

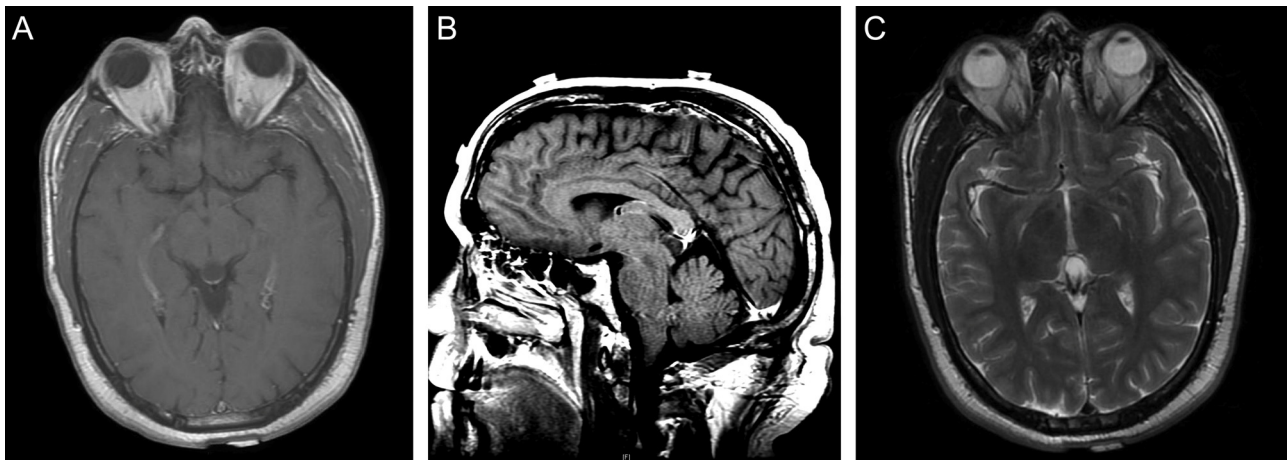


Fig. 1. Preoperative magnetic resonance imaging demonstrated a pineal cyst in the quadrigeminal cistern. (A) T1 axial post-contrast; (B) T1 sagittal post-contrast; (C) T2 axial.

resonance imaging (MRI) demonstrated an approximately 1.5 cm diameter pineal cyst in the quadrigeminal cistern causing significant compression of the underlying superior colliculus and inferior colliculus of the midbrain (Fig. 1). This had been slowly enlarging. A stereotactic-guided supracerebellar infratentorial approach was used for resection of the pineal cyst. The incision was made from slightly above theinion at the midline to the level of C2. A standard midline scalp and muscle dissection was performed and a standard suboccipital craniotomy was performed. The superior portion of the craniotomy allowed for visualization of the lower half of the transverse sinus but did not extend above the transverse sinus. The dura was opened in a Y-shaped fashion and care was taken to gently retract the cerebellum inferiorly while coagulating and cutting the

veins between the tentorium and the cerebellum. The arachnoid overlying the quadrigeminal plate cistern was opened. The precentral cerebellar vein was coagulated and divided before the pineal cyst came into view. After exposing the pineal cyst, the cyst was drained. Then the entire cyst was meticulously dissected from the surrounding cistern and from the tectal plate of the midbrain. The tentorium was not incised at any point during the case. There were no immediate postoperative complications and he was ambulating and stable at the time of discharge.

On the afternoon of his discharge, he started to have a severe headache that he described as the worst headache of his life. He, therefore, called the ambulance to bring him back to the hospital. A head computed tomography (CT) scan was obtained that showed

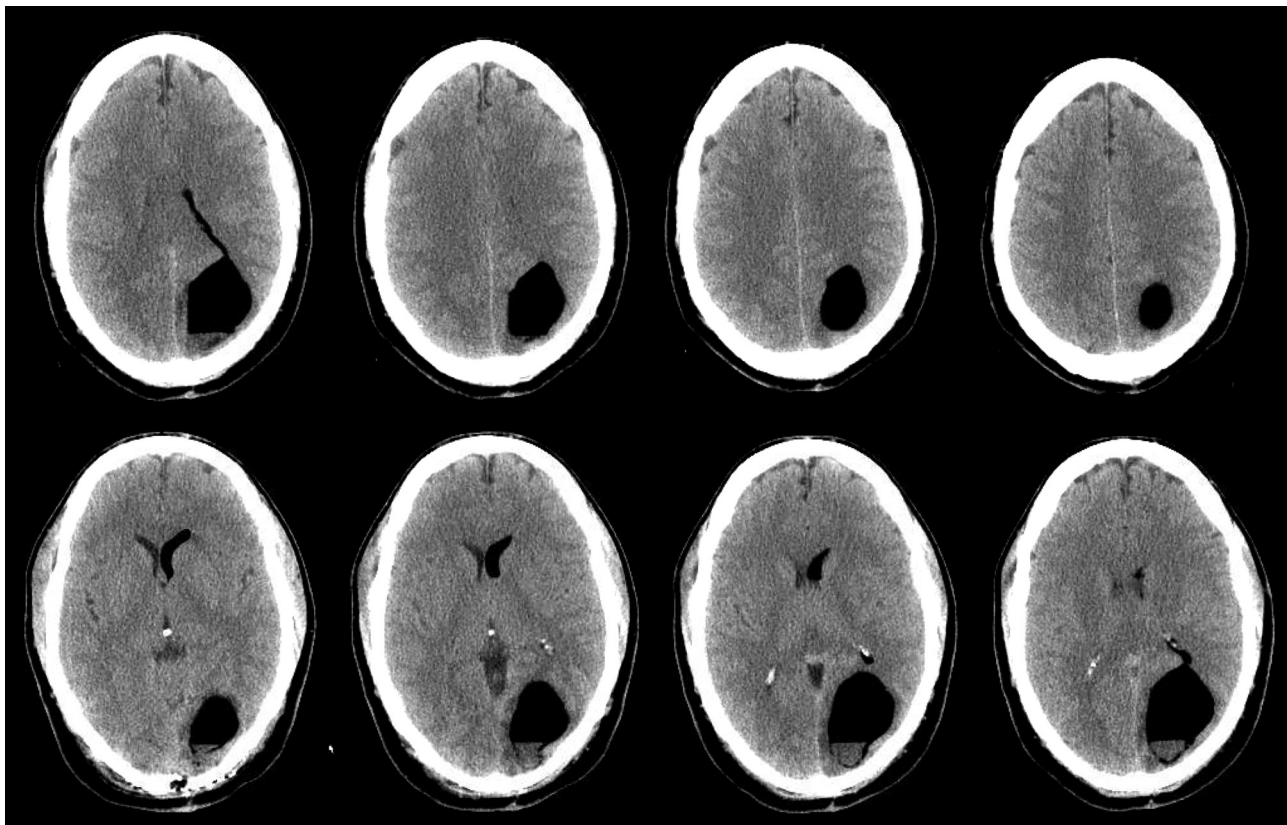


Fig. 2. Postoperative axial computed tomography scan following autologous adipose tissue graft repair, demonstrates fat in the intraparenchymal space of the occipital lobe as well as in the ventricular system.

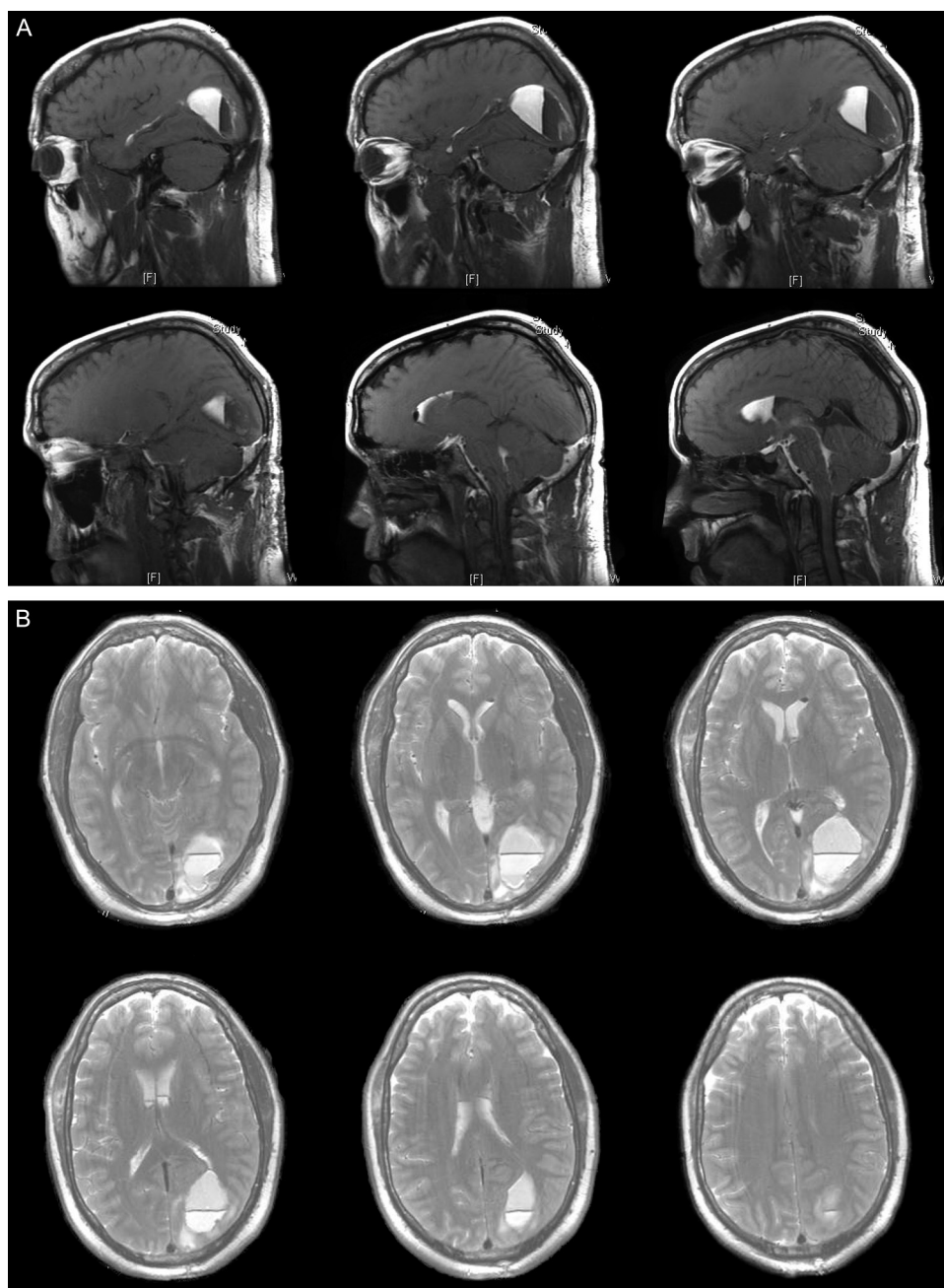


Fig. 3. Magnetic resonance imaging of postoperative autologous adipose tissue graft repair. (A) T1 sagittal and (B) T2 axial demonstrate the epidural fat inside the subarachnoid and the intraparenchymal space of the occipital lobe, extending into the basal cistern, prepontine cistern, and ventricle.

no signs of intracranial hemorrhage. He was admitted for pain control and further workup. Over the next 24 hours, he had serosanguinous drainage from the incision site, that then changed to a large amount of purulent drainage. He was immediately brought back to the operating room for wound washout and lumbar drain placement. The superficial abscess was washed out and the bone was removed. There were two areas of CSF leaking from the dura, and these were primarily closed using 4–0 neurilon sutures as well as placement of surgical adjuvants over the repair including Duragen and duraseal. The muscle and fascia were then closed with 0–vicryl sutures in multiple layers and the galea closed using 3–0 interrupted inverted vicryl sutures. The skin was closed using a running 3–0 nylon suture. A lumbar drain was placed to help with CSF diversion at a rate of 10 cc per hour. Wound and CSF cultures grew out *Escherichia coli* (*E. Coli*) that was treated with Ceftriaxone, Vancomycin and Metronidazole. Following the return of the

sensitivities, he was then narrowed to Ceftriaxone alone for a total antibiotics course of six weeks.

Over the subsequent days, the patient began to show signs of improvement with reduced leukocytosis and pain control. The lumbar drain was removed after no signs of CSF leak and the patient was discharged on antibiotics. However, CSF began leaking again two weeks after initial repair. He was therefore brought back to the operating room for a repair of his leak using autologous adipose tissue graft and lumbar drain placement. Approximately, five pieces of autologous adipose tissue were placed over the dura inferior to the transverse sinus and used to seal the dural closure completely. Another layer of closure was performed with Duraseal. Then, a titanium mesh plate was used to hold the adipose graft firmly against the dural closure. This resulted in the following layers of closure: dura, Duragen, duraseal, adipose graft, additional duraseal, titanium mesh plate, scalp. The patient continued to improve

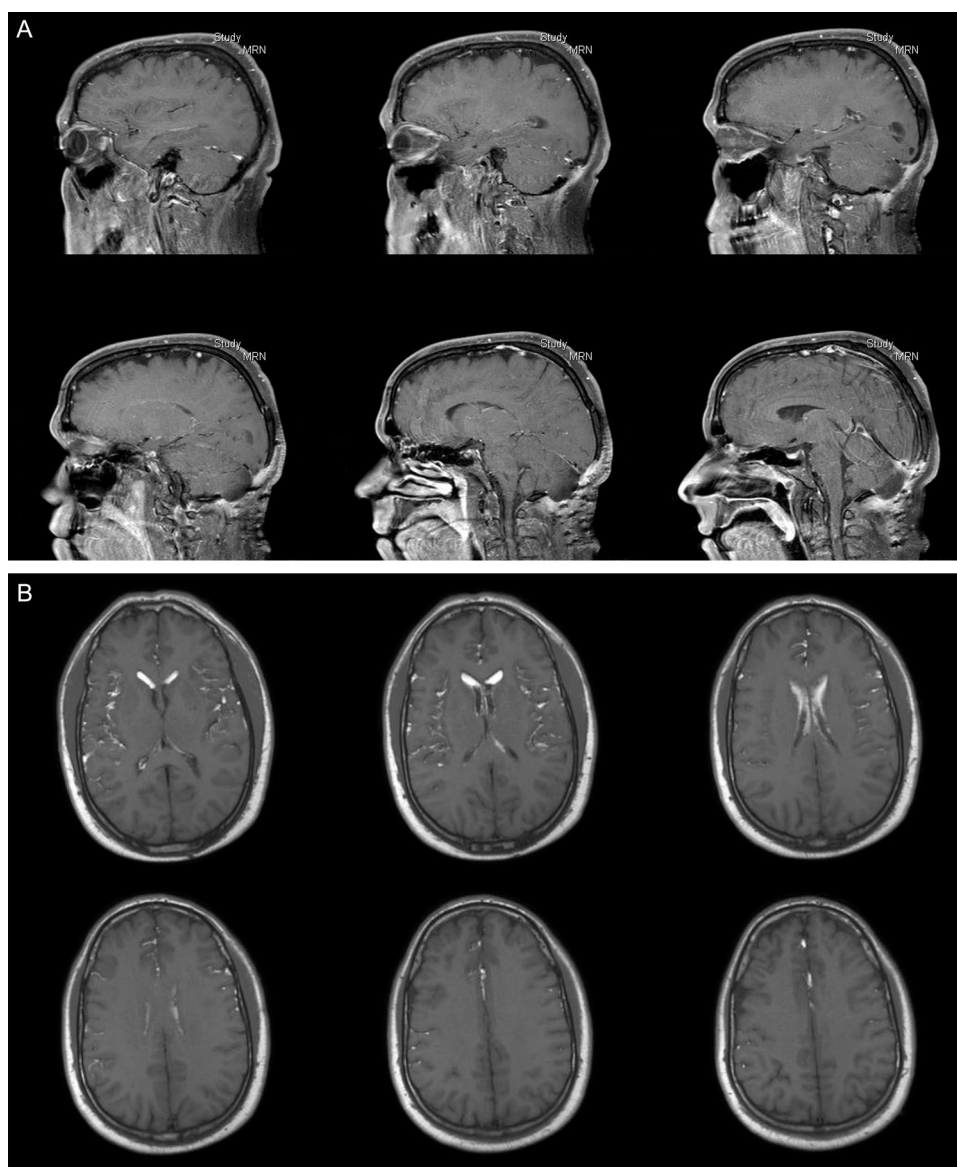


Fig. 4. Six-month follow-up magnetic resonance imaging. (A) T1 sagittal post-contrast and (B) T1 axial demonstrating a significant decrease in the amount of intracranial fat.

neurologically with lumbar drain management draining approximately 10 cc per hour. Three days following the autologous adipose tissue graft, the patient complained of new right homonymous hemianopia. A CT scan (Fig. 2) and MRI (Fig. 3) were done and showed no acute stroke, infection, or hemorrhage. However, our theory is that due to the pressure change with the lumbar drain, the epidural fat was sucked into the subarachnoid and intraparenchymal space of the occipital lobe, extending into the basal cistern, prepontine cistern, left lateral ventricle, third ventricle, and fourth ventricle, which caused transient right visual field cut disturbance. The lumbar drain was immediately clamped and later removed. His symptoms rapidly improved over the next 48 hours and were nearly resolved at the time of discharge.

After Patient P.S. had his lumbar drain removed, he continued to do well with no further leaking from his incision. He was monitored for hydrocephalus for one week but did not exhibit any new symptoms. He was deemed stable for discharge home one week following the graft. The patient was discharged with a peripherally inserted central catheter on IV Vancomycin, IV Ceftriaxone and Metronidazole until sensitivities returned. He was then narrowed to Ceftriaxone alone following the return of sensitivities for a total

of six weeks. He was instructed to call the physician for worsening neurological symptoms, fever, increased pain, or signs of infection. Follow-up at two and three months showed no recurrence of his pineal cyst. Follow-up at six months revealed continued resolution of his symptoms. His CT and MRI (Fig. 4) from early April 2011 demonstrated near resolution of the fat migration.

3. Discussion

This is the first report of a patient with an autologous fat graft entering the subarachnoid space, intraparenchymal space, and ventricles following fat graft and lumbar drainage. It demonstrates the importance of monitoring post-lumbar drain complications. Lumbar drainage is, in general, a very effective and safe procedure. Studies demonstrate between a 68.8% and 87% success rate for repair of CSF leaks with lumbar drainage [10,11]. In a study of 412 patients who underwent posterior cranial fossa surgery by the retrosigmoid approach for a variety of diseases, 32 had CSF leaks, 10 of which were treated conservatively, 12 with lumbar drains, and 10 requiring surgical repair [10]. Notably, use of a fascia lata graft is

another alternative for treatment of CSF leakage in the presence of infection as it is associated with minimal to no complications [12].

Autologous fat graft migration has been described following retroauricular craniotomy, with some cases leading to brain stem compression [13–16]. Additionally, adipose migration has been described following lumbar surgery leading to complications of cauda equina syndrome, recurrent sciatica, and root compression [17–22].

As this is the first report of an autologous fat graft entering the subarachnoid space and ventricles, there is no consensus on a method for management of intracranial fat migration. In this case, the patient's new right homonymous hemianopia resolved with supportive care alone within 48 hours. Scans six months later demonstrated significant decrease in the amount of intracranial fat with supportive management alone. There has been no comparison for outcomes with supportive vs. surgical treatment and removal of autologous fat graft.

4. Conclusion

This case demonstrates a new complication of CSF leak repair with autologous fat grafts following supracerebellar infratentorial approach. It highlights the importance of monitoring post-repair signs and symptoms for changes that may demonstrate fat graft migration. Physicians should be aware of this complication when explaining the procedure to patients and consider supportive care when it occurs.

Conflict of interest

All authors have made substantial, direct intellectual contributions to the work. We have no financial disclosures, and have no commercial or other associations that pose a conflict of interest. We have no extramural source of funding for this endeavor.

Funding

Nothing to declare.

Author contribution

Cassie A. Ludwig: background research and preparation of text within the manuscript.

Parvir Aujila: preparation and editing text within the manuscript, editing and acquisition of appropriate images for figures.

Mario Moreno: background research and preparation of text within the manuscript.

Anand Veeravagu: case report design, editing and acquisition of appropriate images for figures.

Gordon Li: case report design, editing and acquisition of appropriate images for figures.

Consent

Consent was not needed for this study as it is not a study performed on patients or volunteers.

Acknowledgement

We would like to thank Cheryl Christensen for her editorial assistance on this manuscript.

References

- [1] W.N. Al-Holou, S.W. Terman, C. Kilburg, H.J. Garton, K.M. Muraszko, W.F. Chandler, M. Ibrahim, C.O. Maher, Prevalence and natural history of pineal cysts in adults, *J. Neurosurg.* 115 (2011) 1106–1114.
- [2] A. Oprisan, B.O. Popescu, Intracranial cysts: an imagery diagnostic challenge, *Sci. World J.* 2013 (2013) 1–9.
- [3] P. Klein, L.J. Rubinstein, Benign symptomatic glial cysts of the pineal gland: a report of seven cases and review of the literature, *J. Neurol. Neurosurg. Psychiatry* 52 (1989) 991–995.
- [4] A.S. Fang, S.P. Meyers, Magnetic resonance imaging of pineal region tumors, *Insights Imaging* 4 (2013) 369–382.
- [5] I. Radovanovic, K. Dizdarevic, N. de Tribolet, T. Masic, S. Muminagic, Pineal region tumors – neurosurgical review, *Med. Arh.* 63 (2009) 171–173.
- [6] D.A. Silverman, G.B. Hughes, S.E. Kinney, J.H. Lee, Technical modifications of suboccipital craniectomy for prevention of postoperative headache, *Skull Base: Off. J. North Am. Skull Base Soc. [et al]* 14 (2004) 77–84.
- [7] L.S. Governale, N. Fein, J. Logsdon, P.M. Black, Techniques and complications of external lumbar drainage for normal pressure hydrocephalus, *Neurosurgery* 63 (2008) 379–384.
- [8] P. Black, Cerebrospinal fluid leaks following spinal surgery: use of fat grafts for prevention and repair, *J. Neurosurg. (Spine)* 96 (2002) 250–252.
- [9] A.N. Taha, R. Almefty, S. Pravdenkova, O. Al-Mefty, Sequelae of autologous fat graft used for reconstruction in skull base surgery, *World Neurosurg.* 75 (2011) 692–695.
- [10] Y.A. Bayazit, F. Celenk, M. Duzlu, N. Goksu, Management of cerebrospinal fluid leak following retrosigmoid posterior cranial fossa surgery, *ORL, J. Oto-Rhino-Laryngol. Relat. Spec.* 71 (2009) 329–333.
- [11] A.J. Fishman, R.A. Hoffman, J.T. Roland Jr., R.A. Lebowitz, N.L. Cohen, Cerebrospinal fluid drainage in the management of CSF leak following acoustic neuroma surgery, *Laryngoscope* 106 (1996) 1002–1004.
- [12] K.V. Thammavaram, E.C. Benzel, L. Kesterson, Fascia lata graft as a dural substitute in neurosurgery, *South. Med. J.* 83 (1990) 634–636.
- [13] J. Ray, A.R. D'Souza, S.V. Chavda, A.R. Walsh, R.M. Irving, Dissemination of fat in CSF: a common finding following translabyrinthine acoustic neuroma surgery, *Clin. Otolaryngol.* 30 (5) (2005) 405–408.
- [14] U.R. Krause-Titz, A.K. Petridis, A. Doukas, H. Barth, H.M. Mehdorn, Fat graft displacement after retroauricular surgery of a petrous meningioma, *Clin. Neuroradiol.* 21 (2011) 249–250.
- [15] A. Spallone, A. Rizzo, Brain stem compression secondary to adipose graft prolapse after transpetrosal approach: case report, *Surg. Neurol.* 48 (1997) 80–83.
- [16] T.C. Chen, D.R. Maceri, M.L. Levy, S.L. Giannotta, Brain stem compression secondary to adipose graft prolapse after translabyrinthine craniotomy: case report, *Neurosurgery* 35 (1994) 521–523.
- [17] R. Kansal, S. Nama, A. Mahore, N. Dange, S. Kukreja, Fat graft migration causing recurrent cervical cord compression, *Turk. Neurosurg.* 22 (4) (2012) 502–505.
- [18] J.M. Cabezedo, A. Lopez, F. Bacci, Symptomatic root compression by a free fat transplant after hemilaminectomy. Case report, *J. Neurosurg.* 63 (1985) 633–635.
- [19] T.Y. Chuang, W.J. Chen, L.H. Chen, C.C. Niu, C.H. Shih, Acute postoperative aggravation of radiculopathy as a complication of free fat transplantation in lumbar disc surgery: case report, *Changeng Yi Xue Za Zhi* 22 (1999) 498–502.
- [20] A. Deburge, F. Bitan, B. Lassale, G. Vaquin, Cauda equina syndrome caused by migration of a fat graft after laminarthrectomy, *Rev. Chir. Orthop. Reparatrice Appar. Mot.* 74 (1988) 677–678.
- [21] A. Trigo Cabral, P. Lima, E. Paiva, A. Pinto, A case of recurrent sciatica following a free adipose tissue graft, *Rev. Chir. Orthop. Reparatrice Appar. Mot.* 75 (1989) 412–414.
- [22] P. Urvoy, S. Perlinski, M. Berger, E. Butin, H. Mestdagh, Cauda equina syndrome due to early postoperative migration of an adipose tissue flap following laminectomy, *Acta. Orthop. Belg.* 56 (1990) 513–516.

Open Access

This article is published Open Access at sciendo.com. It is distributed under the [IJSCR Supplemental terms and conditions](#), which permits unrestricted non commercial use, distribution, and reproduction in any medium, provided the original authors and source are credited.