

Case Report

Duodenal rupture secondary to blunt trauma from a football

Alison Luther*, Christopher Mann, Colin Hart and Khalil Khalil

General Surgical Department, Northampton General Hospital, Northampton, UK

*Correspondence address. General Surgical Department, Northampton General Hospital, Northampton NN1 5BD, UK. Tel: +07-79-310-7473; E-mail: alison_luther@hotmail.com

Received 21 October 2012; accepted 23 November 2012

Duodenal rupture secondary to blunt trauma is a relatively uncommon event and is usually a result of a road traffic accident. As the duodenum is a retroperitoneal organ, delays in diagnosis can occur, as the patient may present with vague abdominal symptoms and other non-specific signs. Computed tomographic scanning is therefore a useful tool in the diagnosis of this condition. We present a 19-year-old girl who was hit in the abdomen with a football and subsequently had a duodenal rupture.

INTRODUCTION

Blunt trauma to the abdomen is an uncommon cause of duodenal rupture. We report the case of a 19-year-old female football spectator who suffered a duodenal rupture as a result of being hit in the abdomen by a football.

CASE REPORT

A 19-year-old girl presented to the Emergency Department at 1 am after having a football kicked from a distance of 5–10 m into her abdomen 7 h previously whilst watching a game. She complained of worsening diffuse abdominal pain and vomiting. Her observations were stable; however, on examination, her abdomen was diffusely tender and there was evidence of generalized peritonism. She had a white cell count of $18.8 \times 10^9/l$, but the rest of her blood tests, including amylase, was normal. Her chest radiograph did not show any evidence of free air under the diaphragm. A computed tomographic (CT) scan of her abdomen and pelvis was arranged, which showed abnormal areas of low attenuation and multiple pockets of air in the right flank, surrounding the right kidney and in the right sub-hepatic space, consistent with a perforation of either the ascending colon or the duodenum (Fig. 1). A laparotomy was performed and a 0.5 cm perforation was seen in the antero-lateral border of the duodenum at the junction of the first and second parts of the duodenum following Kocherization. The perforation was oversewn and repaired with an omental patch. She recovered well from the operation and was discharged 4 days later.

DISCUSSION

The duodenum is a 'C'-shaped organ primarily situated in the retroperitoneum and is anatomically divided into four sections (D1–D4). It is vulnerable to damage by shearing or compression forces, as D1 and D4 are relatively mobile in comparison with D2 and D3, which are fixed. Commonly injuries occur at the junction between D3 and D4 and at the junction between D1 and D2, as seen in this case [1, 2]. The retroperitoneal nature of the duodenum may also result in delays in the diagnosis of duodenal rupture as patients may not present with frank peritonism initially. It is therefore important to consider both mechanism of injury and also other clinical signs such as tachycardia and raised white cell count as delays in diagnosis and subsequent management have been shown to adversely affect morbidity and mortality [1–8]. However, in this case, due to the positioning of the perforation, duodenal contents entered the peritoneal cavity directly from the point of rupture, thus causing peritoneal irritation.

Duodenal injuries secondary to blunt trauma can range in severity from an intramural haematoma to a complete transection and devascularization of the duodenum, and are graded 1–5 by the American Association for Surgery of Trauma [2, 5, 6]. CT scanning is a useful adjunct to in the diagnosis of duodenal rupture, and can aid in the differentiation between full thickness rupture that requires surgical intervention and a haematoma which can be managed conservatively. The finding of fluid in the right anterior pararenal space on a CT scan may be seen in the presence of

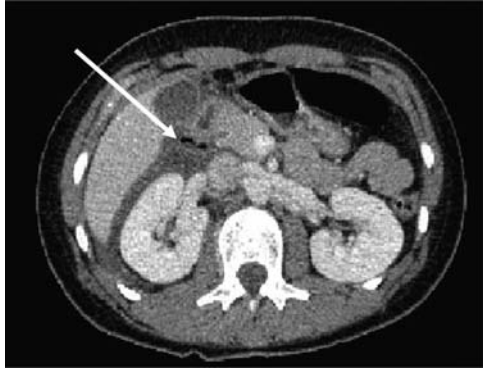


Figure 1: CT of abdomen showing free air in right para-renal space (white arrow).

a duodenal haematoma, whereas if air is seen in this area duodenal rupture is likely to have occurred [1–4, 6, 9]. In this case, CT scanning was useful in delineating the possible area where a perforation may be found, especially as the patient presented with generalized abdominal pain. There are multiple ways to repair a duodenal rupture and these are obviously dependant on the severity of the injury. The literature suggests that kocherization (mobilization) of the duodenum should be performed to allow full examination of the duodenum to rule out multiple perforations [1, 2, 4, 7, 9].

Duodenal perforations are uncommon secondary to blunt trauma, comparative to penetrating trauma. A retrospective study analysing a trauma database of 103,864 patients showed that only 0.2% (208 patients) had a duodenal injury related to blunt trauma and of these only 30 patients had full thickness duodenal rupture. The most common mechanism of injury was involvement in a road traffic accident [1, 3].

Duodenal rupture as a result of a sporting injury is very rare and there are no reports of duodenal injury from the specific mechanism described in this report [8, 10].

Duodenal rupture secondary to blunt trauma is a rare but significant event. This case demonstrates that even if the mechanism of injury seems trivial, a high level of suspicion should be maintained in the presence of suggestive clinical findings. It also shows the benefit of CT scanning in the diagnosis and management of duodenal rupture.

REFERENCES

1. Degiannis E, Boffard K. Duodenal Injuries. *Br J Surg* 2000;**87**:1473–9.
2. Carrillo EH, Richardson JD, Miller FB. Evolution in the management of duodenal injuries. *J Trauma* 1996;**40**:1037–46.
3. Ballard RB, Badellino MM, Eynon CA, Spott MA, Staz CF, Buckman RF. Blunt duodenal rupture: a 6 year statewide experience. *J Trauma* 1997;**40**:229–33.
4. Battachajee HK, Misra MC, Kumar S, Bansal VK. Duodenal perforation following blunt trauma. *J Emerg Trauma Shock* 2011;**4**:514–7.
5. Osuka A, Idoguchi K, Muguruma T, Ishikawa K, Mizushima Y, Matsuoka T. Duodenal disruption diagnosed 5 days after blunt trauma in a 2-year-old child: report of a case. *Surg Today* 2007;**37**:984–8.
6. Lisenmaier U, Wirth S, Reiser M, Körner M. Diagnosis and classification of pancreatic and duodenal injuries in emergency radiology. *Radiographics* 2008;**28**:1591–601.
7. Flint LM, McCoy M, Richardson JD, Polk HC. Duodenal trauma: analysis of common misconceptions in diagnosis and treatment. *Ann Surg* 1980;**191**:697–701.
8. Houshain S. Traumatic duodenal rupture in a soccer player. *Br J Sports Med* 2000;**34**:218–9.
9. Kunin JR, Korobkin M, Ellis JH, Francis IR, Kane NM, Siegel SE. Duodenal injuries caused by blunt trauma: value of CT in differentiating perforation from hematoma. *Am J Roentgenol* 1993;**160**:1221–3.
10. Cox MR, Eastman MC. Traumatic duodenal rupture and avulsion of the ampulla of Vater. *HPB Surg* 1994;**7**:225–9.