

Neuroimaging features of fatal high-altitude cerebral edema

Gorky Medhi, Tsella Lachungpa, Jitender Saini¹

Department of Radiology, Sikkim Manipal Institute of Medical Sciences, Gangtok, Sikkim, ¹Department of Neuroimaging and Interventional Radiology, National Institute of Mental Health and Neurosciences, Bangalore, Karnataka, India

Correspondence: Dr. Gorky Medhi, Assistant Professor, Department of Radiology, Sikkim Manipal Institute of Medical Sciences, Gangtok - 737 102, Sikkim, India. E-mail: gorkymedhi@gmail.com

Abstract

Acute high-altitude cerebral edema can occur in an unacclimatised individual on exposure to high altitudes and sometimes it can be fatal. Here we have described the neuroimaging features of a patient who suffered from fatal high altitude cerebral edema. Available literature is reviewed. Probable pathogenesis is discussed. The risk of acute mountain sickness is reported up to 25% in individuals who ascend to an altitude of 3500 meter and in more than 50% subjects at an altitude of 6000 meter. The lack of availability of advanced imaging facilities at such a higher altitude makes imaging of such condition a less described entity.

Key words: Cerebral edema; CT scan; high altitude; microhemorrhages; magnetic resonance imaging

Introduction

Acute high-altitude illness is a generic term to encompass acute mountain sickness (AMS), high-altitude pulmonary edema, and high-altitude cerebral edema (HACE), which are a spectrum of clinical findings occurring in an unacclimatized individual on exposure to high altitudes.

As more and more individuals visit such high altitudes for both work and pleasure, the risk of AMS is increasing and it is reported in up to 25% of individuals who ascend to an altitude of 3500 m (11,500 feet) and in more than 50% subjects at an altitude of 6000 m (19,700 feet).^[1-3] The lack of availability of advanced imaging facilities at such locations makes imaging of such condition a less described entity. Here, we describe the neuroimaging features in a patient who suffered fatal form of HACE with review of literature to understand the pattern of involvement and probable pathogenesis.

Case Report

A 50-year-old female tourist who lived in planes and had recently ascended to a height of 9900 feet (approximately 3000 m) without any prior acclimatization presented to our emergency department in comatose condition. She had a history of bronchial asthma for which she was on inhalers apart from which she had no other significant medical history. Apparently, the patient was unwell on the day of reaching the destination following which she had an episode of vomiting followed by loss of consciousness with one episode of seizure and was shifted to the local hospital at midnight where her condition deteriorated further and was brought to our hospital in an unconscious state in the morning. Her Glasgow Coma Scale was E₁V₁M₁ with pupils reacting to light. Hematological examination revealed normal serum Na⁺, K⁺, blood sugar, renal function, hepatic function, Hb%, platelet count, total and differential leukocyte counts. Her arterial blood gas analysis showed

This is an open access journal, and articles are distributed under the terms of the Creative Commons Attribution-NonCommercial-ShareAlike 4.0 License, which allows others to remix, tweak, and build upon the work non-commercially, as long as appropriate credit is given and the new creations are licensed under the identical terms.

For reprints contact: reprints@medknow.com

Cite this article as: Medhi G, Lachungpa T, Saini J. Neuroimaging features of fatal high-altitude cerebral edema. Indian J Radiol Imaging 2018;28:401-5.

Access this article online

Quick Response Code:



Website:
www.ijri.org

DOI:
10.4103/ijri.IJRI_296_18

pH of 7.6, pCO₂ of 30.3 mm Hg, pO₂ of 45.7 mm Hg, and HCO₃ of 20.1 mmol/L. High-resolution computed tomography (CT) thorax was clear. There was low partial pressure of oxygen secondary to hyperventilation leading to low partial pressure of CO₂ and respiratory alkalosis. Subsequently, SpO₂ was 99% with 2 L of oxygen/min, and blood pressure was 94/64 mm Hg. Her pulse rate was 70/min. The patient received a course of intravenous antibiotic and was investigated with CT and magnetic resonance imaging (MRI).

Non-contrast CT (NCCT) head performed immediately revealed multiple focal subcortical and cortical hemorrhagic foci involving right parietal, left frontal lobe, and areas of subcortical edema in the left frontal lobe [Figure 1]. Sulci were effaced. A few areas of subcortical focal hypodensities were noted. Imaging differential diagnosis after CT scan were cerebral venous sinus thrombosis, HACE, multiple hemorrhagic contusions, and hemorrhagic ADEM. Hypertensive intraparenchymal hemorrhage, subarachnoid hemorrhage, acute ischemic strokes, and so on were ruled out on CT scan.

MRI brain was performed and completed within 1 h after initial NCCT; it revealed numerous foci of microbleeds blooming on venobold images involving subcortical white matter, corpus callosum, internal capsules, and middle cerebellar peduncles [Figure 2]. However, T1W images showed only a few focal hyperintense areas in subcortical and cortical areas corresponding to intraparenchymal hemorrhages visible on NCCT. Diffuse areas of cerebral edema showing facilitated diffusion were noted involving predominantly subcortical white matter of bilateral cerebral hemispheres and corpus callosum and seen extending along bilateral internal capsules. Focal areas of restricted diffusions were noted involving splenium of corpus callosum and the right parietal lobe. Multiple small specks of restricted diffusion were seen along the subcortical areas of bilateral frontal and parietal lobes [Figure 3]. Magnetic resonance venography revealed patent cerebral venous sinuses and

magnetic resonance angiography was unremarkable. Postcontrast study was not done. In view of history, possible diagnosis of HACE was suggested. She was treated with 100 mg i.v. hydrocortisone and oxygen. However, the patient's clinical condition further deteriorated and she succumbed within a few hours due to cardiac arrest.

Discussion

The exact pathogenesis of HACE has not been fully understood, but it is described to be the end stage of AMS where there is neurological manifestation of the high-altitude illness. Two theories are described in the development of HACE, namely, cytotoxic and vasogenic edema.^[4]

Vasogenic edema is postulated to occur due to interplay of neurohormones such as vascular endothelial growth factor, nitric oxide, reactive cytokines and free radicals with hemodynamic responses leading to hypoxia-induced microvascular capillary bed leakage. This disruption of the blood–brain barrier and resultant cerebral edema lead to the development of raised intracranial pressure. Whereas cytotoxic edema, according to the “revised theory,” occurs due to free radical formation as a result of hypoxia which causes damage to the Na⁺/K⁺ ATPase pump leading to osmotic-oxidative stress, astrocyte swelling, and resultant cytotoxic edema.^[5] Disruption of the blood–brain barrier is said to be responsible for the extensive microhemorrhages which have a predilection for the corpus callosum as observed by Hackett *et al.*^[5] The reason why the corpus callosum is most affected can be explained by the nature of blood vessels supplying it. Corpus callosum is supplied by the short and very short perforating vessels that lack adrenergic tone making it vulnerable to hypoxia-induced vasodilatation and its autoregulatory failure with resultant hyperperfusion.^[6]

The partial pressure of oxygen drops to 13.3 kPa (68%) at a height of 3000 m compared to sea level (19.6 kPa).^[7] This leads to hypoxemia which is greater in HACE than AMS and hence a greater degree of hemodynamic, cellular, and biochemical response in HACE.^[7] Because of hypoxia-induced vasodilatation, there is transient failure of the autoregulation and an increase in capillary hydrostatic pressure causing extracellular (vasogenic) cerebral edema with further disruption of the blood–brain barrier. In contrast to the traditional model of overperfusion edema, revised model (redox activation) suggests that reduced cerebral PO₂ leads to free radicals which directly activate the trigeminovascular system to trigger neurovascular headache and AMS. HACE reflects the more extreme spectrum of “osmotic-oxidative stress” which results in gross barrier dysfunction and cerebral capillary “stress failure.”^[8]

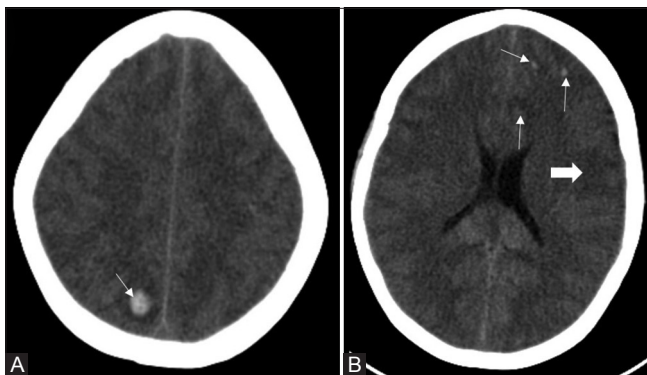


Figure 1 (A and B): NCCT brain showing multiple focal subcortical and cortical haemorrhagic foci involving right parietal (A), left frontal lobe (B) (thin arrows). Subcortical edema in left frontal lobe (Solid white arrow) (B)

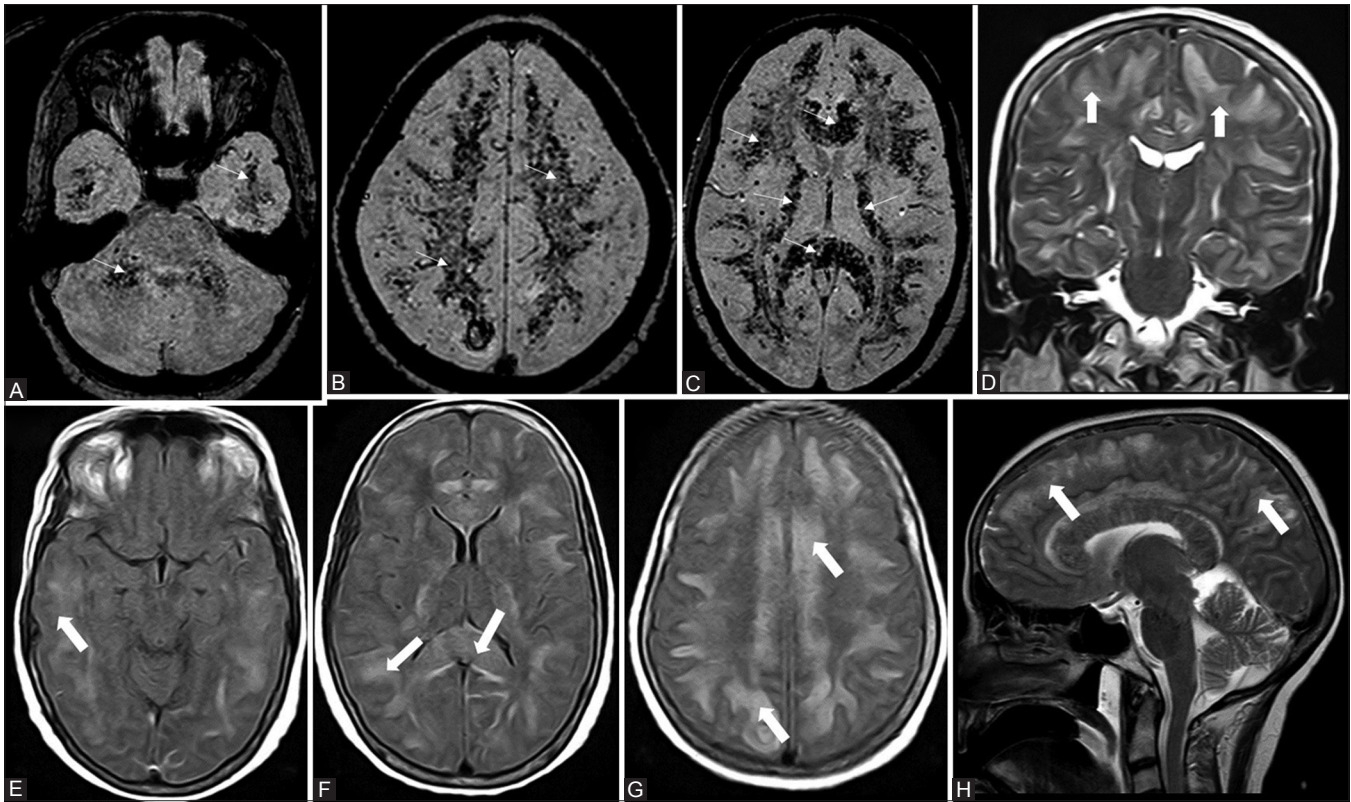


Figure 2 (A-H): (A-C)- Axial venobold images showing numerous foci of micro-bleeds (small arrows) blooming involving sub cortical white matter, genu-body, splenium of corpus callosum, along internal capsules, middle cerebellar peduncles. T2W coronal (D), sagittal (H), FLAIR axial images (E-G) showing diffuse areas of hyper intensities (solid arrows) suggestive of edema involving predominantly sub cortical white matter of bilateral cerebral hemispheres, corpus callosum, along internal capsules

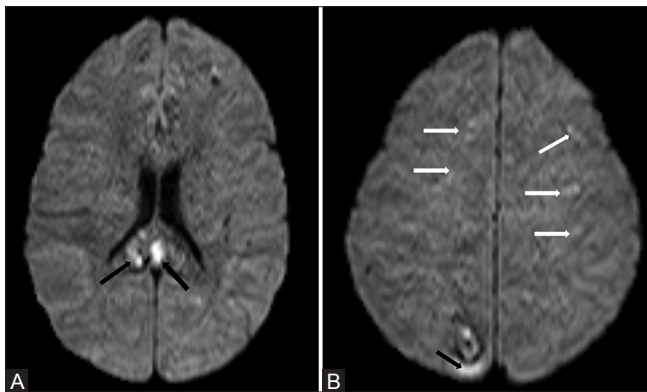


Figure 3 (A and B): Axial DW images showing focal areas of restricted diffusion involving splenium of corpus callosum (A), right parietal lobe (B) (black arrows). Multiple small specks of restricted diffusion along the subcortical areas of bilateral frontal and parietal lobes (B)

Imaging studies helps not only in diagnosis but also in understanding the course of the illness and any complication. MRI findings are seen to lag the clinical recovery making diagnosis of HACE possible even beyond recovery to explain the nature of a patient’s illness.

CT demonstrates features of cerebral edema in the form of diffuse or focal white matter hypoattenuation with associated effacement of sulci and gyri. MRI is useful for

not only detecting changes in HACE but also in ruling out other possible pathologies such as cerebral venous thrombosis. Diffuse white matter hyperintensity was seen on T2WI and areas of abnormal diffusion especially involving the splenium of corpus callosum are not pathognomonic, but in an otherwise healthy individual with a history of ascent to high altitude and appropriate clinical findings may be considered diagnostic. Hackett *et al.* in 1998 in their series of nine patients found the typical T2 findings in seven patients, especially the splenium of the corpus callosum with no grey matter involvement.^[5] A patient of their study with negative conventional MRI showed diffusion restriction thereby emphasizing the usefulness of diffusion-weighted images in patients with negative routine MRI sequences.^[5]

Schoonman *et al.* studied nine healthy students before and after 6-h exposure to isobaric hypoxia. MRI was performed with 3T MRI. Isobaric hypoxia was associated with mild vasogenic cerebral edema irrespective of the presence of AMS in most subjects and additional mild cytotoxic cerebral edema was seen in severe AMS detected on diffusion-weighted imaging and apparent diffusion coefficient map.^[9]

Vasogenic edema has a propensity to affect the white matter tract and splenium of corpus callosum, and

due to increased capillary permeability can lead to microhemorrhages as well. Extensive microhemorrhages were noted involving the corpus callosum, cerebral white matter, centrum semiovale, and middle cerebellar peduncles in the current case. Imaging studies have typically described the presence of microhemorrhages involving the corpus callosum, cerebral white matter, and centrum semiovale.^[10,11] Hefti *et al.* described microhemorrhages in the middle cerebellar peduncles.^[10] The orderly structure of the white matter of splenium and middle cerebral peduncle might be responsible for its increased involvement.^[10] In addition, supply of corpus callosum by short perforating arteries that lack the adrenergic tone may make it more susceptible to edema and microhemorrhages^[6] compared with middle cerebellar peduncles.

In comparison to the case by Hefti *et al.*, our case had more extensive microhemorrhages involving the deep white matter, corpus callosum, and middle cerebral peduncle. The patient in the case report by Hefti *et al.* underwent MRI after 2 months of the illness, whereas our patient underwent MRI during acute phase. Second, our patient had a more severe degree of illness with likely contribution from preexisting bronchial asthma resulting in more severe hypoxia-induced damage leading to extensive microbleeds to which the patient eventually succumbed.

Hackett *et al.* and Wong *et al.* have previously reported nonlethal cases of HACE where microbleeds were not reported; however, it could be underreported as susceptibility-weighted images were not used in these studies.^[6,12] Microhemorrhages are demonstrated in autopsy study in lethal HACE.^[13] Kallenberg *et al.* in their study were able to demonstrate both vasogenic and cytotoxic edema in nonlethal HACE patients with the use of conventional and newer MRI techniques.^[14] Hence, microhemorrhages are said to be one of the distinguishing features between AMS and HACE which occur likely due to disruption of the blood–brain barrier. Microhemorrhages can occur as an incidental finding in high altitude but they are not reported at sites like corpus callosum.^[15]

Initially, one of the differentials in our case was cerebral venous sinus thrombosis due to its clinical presentation and NCCT images showing juxta-cortical hemorrhage. However, it was excluded on subsequent MRI. Another differential diagnosis was anoxia-induced encephalopathy secondary to pulmonary edema, but the lack of involvement of grey matter and extensive microhemorrhages aid in the diagnosis. Chronic hypertensive encephalopathy results in microhemorrhages in deep grey matter and basal ganglia. Vasculitis-induced microhemorrhages are mainly located in the supratentorial white matter region.^[16]

The unique imaging features in our case were extensive microhemorrhages involving all subcortical white matter, corpus callosum, internal capsules, and middle cerebellar peduncles along with vasogenic cerebral edema involving these structures with sparing of cortical and deep grey matter nuclei associated with some areas of restricted diffusion. Hence in an appropriate clinical scenario, if any of these structures are involved with vasogenic edema and microhemorrhages on CT or MRI, HACE should be diagnosed promptly and the patient should be treated with utmost priority considering the fatality of the disease like in our case.

Declaration of patient consent

The authors certify that they have obtained all appropriate patient consent forms. In the form the patient(s) has/have given his/her/their consent for his/her/their images and other clinical information to be reported in the journal. The patients understand that their names and initials will not be published and due efforts will be made to conceal their identity, but anonymity cannot be guaranteed.

Financial support and sponsorship

Nil.

Conflicts of interest

There are no conflicts of interest.

References

1. Basnyat B, Murdoch DR. High-altitude illness. *Lancet* 2003;361:1967-74.
2. Netzer N, Strohl K, Faulhaber M, Gatterer H, Burtscher M. Hypoxia-related altitude illnesses. *J Travel Med* 2013;20:247-55.
3. Luks AM, Swenson ER, Bärtsch P. Acute high-altitude sickness. *Eur Respir Rev* 2017;26:160096.
4. Jensen JD, Vincent AL. Altitude Illness, Cerebral Syndromes, High Altitude Cerebral Edema (HACE) [updated 2017 Oct 9]. In: StatPearls [Internet]. Treasure Island (FL): StatPearls Publishing; 2017. Available from: <https://www.ncbi.nlm.nih.gov/books/NBK430916/>. [Last accessed on 2018 Jul 08] [Last updated on 2017 Oct 09].
5. Hackett PH, Yarnell PR, Hill R, Reynard K, Heit J, McCormick J. High altitude cerebral edema evaluated with magnetic resonance imaging: Clinical correlation and pathophysiology. *JAMA* 1998;280:1920-5.
6. Hackett PH. The cerebral etiology of high-altitude cerebral edema and acute mountain sickness. *Wilderness Environ Med* 1999;10:97-109.
7. Peacock AJ. Oxygen at high altitude. *BMJ* 1998;317:1063-6.
8. Bailey DM, Bartsch P, Knauth M, Baumgartner RW. Emerging concepts in acute mountain sickness and high-altitude cerebral edema: From the molecular to the morphological. *Cell Mol Life Sci* 2009;66:3583-94.
9. Schoonman GG, Sandor PS, Nirikko AC, Lange T, Jaermann T, Dydak U, *et al.* Hypoxia-induced acute mountain sickness is associated with intracellular cerebral edema: A 3 T magnetic resonance imaging study. *J Cerebral Blood Flow Metab* 2008;28:198-206.
10. Pichler Hefti J, Hoigne-Perret P, Kottke R. Extensive

- microhemorrhages of the cerebellar peduncles after high-altitude cerebral edema. *High Alt Med Biol* 2017;18:182-4.
11. Schommer K, Kallenberg K, Lutz K, Bärtsch P, Knauth M. Hemosiderin deposition in the brain as footprint of high-altitude cerebral edema. *Neurology* 2013;81:1776-9.
 12. Wong SH, Turner N, Birchall D, Walls TJ, English P, Schmid ML. Reversible abnormalities of DWI in high-altitude cerebral edema. *Neurology*. 2004; 62:335-6
 13. Dickinson J, Heath D, Gosney J, Williams D. Altitude-related deaths in seven trekkers in the Himalayas. *Thorax* 1983;38:646-56.
 14. Kallenberg K, Dehnert C, Dorfler A, Schellinger PD, Bailey DM, Knauth M, *et al.* Microhemorrhages in nonfatal high-altitude cerebral edema. *J Cereb Blood Flow Metab* 2008;28:1635-42.
 15. Vernooij MW, Ikram MA, Tanghe HL, Vincent AJ, Hofman A, Krestin GP, *et al.* Incidental findings on brain MRI in the general population. *N Engl J Med* 2007;357:1821-8.
 16. Blitstein MK, Tung GA. MRI of cerebral microhemorrhages. *Am J Roentgenol* 2007;189:720-5.