

sub-cutaneous and not fixed to underlying tissues [Fig 1]. This was a recurrence of a lesion that had been removed by lamellar excision in the same site 2 years back. The recurrent mass was removed this time by pentagonal full thickness lid excision with re-construction by advancement eyelid flap. Histopathological examination showed tumor with variegated appearance. The epithelial component composed of round to oval cells with large nucleoli with scanty cytoplasm and the cells were arranged in nests and acinar pattern. The coating for epithelium of the glandular elements was two layered. The intervening stroma showed fibrosis and myxoid areas. No evidence of lacrimal gland tissue was noted in multiple sections [Fig. 2].

Chondroid syringoma is a tumor arising from the sweat glands which can be apocrine (found throughout the surface of lid) or eccrine (glands of Moll in association with eyelash follicles) with a mean age of 50 years (22-73 years).^[1] Ozdal *et al.* in a study of 228 benign ocular adnexal tumors reported apocrine/eccrine hydrocystoma as very common and no case of Chondroid Syringoma was found in that series.^[3] Tyagi *et al.* in their study of 207 eyelid tumors had one case of Chondroid syringoma with an incidence of 0.48% in their series.^[4]

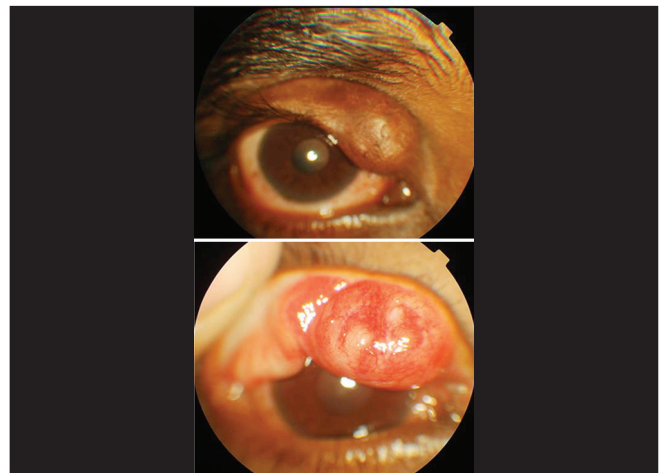


Figure 1: 1.5 cm × 1.5 cm mass involving the right upper lid

Chondroid syringoma: A rare lid tumor

Sir,
Chondroid syringoma is a rare primary skin tumor (0.01% to 0.1% of primary skin tumors).^[1] Though its very common occurrence is in head and the neck region, involvement of eyelids is extremely rare. In English literature we found 27 reported cases of chondroid syringoma involving ocular adnexa.^[1,2] We are reporting a case of recurrent chondroid syringoma of upper eyelid in a young male.

A 27-year-old male present with a slow growing painless mass in right upper lid since past 6 months duration. The mass was 1.5 cm × 1.5 cm firm, non-tender,

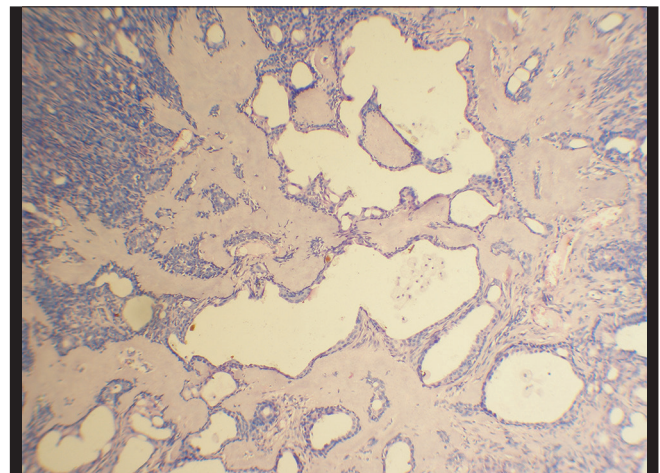


Figure 2: Histopathology showing glandular elements with two layered lining epithelium in myxoid matrix

This tumor was first described by Billroth^[5] and the term chondroid syringoma was coined by Hirsh and Helwig to characterize the origin from sweat glands^[6] though the appearance is like pleomorphic adenoma of lacrimal gland. A proper histopathological examination to rule out presence of normal lacrimal gland tissue external to the tumor capsule helps to differentiate chondroid syringoma.^[1] The case being reported had tubular and cystic branching lumina with 2 layered epithelium showing an apocrine origin.^[1]

Chondroid syringoma is a benign tumor but incomplete excision can undergo malignant transformation.^[1] Hence complete excision is advised.

This case is being reported for its rarity (this is the 28th case in literature involving ocular adnexa), its occurrence in a young patient and the need to keep this rare entity as a differential diagnosis of eyelid tumors.

***M Ashok Kumar, Krishnagopal Srikanth,
Ramraj Vathsalya***

Department of Ophthalmology, Mahatma Gandhi Medical College and Research Institute, Puducherry, India

Correspondence to: Dr. M. Ashok Kumar,
Department of Ophthalmology, Mahatma Gandhi Medical
College and Research Institute, Pillayarkupam, Puducherry, India.
E-mail: drmashok74@rediffmail.com

References

1. Gunduz K, Demirel S, Heper AO, Gunalp I. A Rare case of atypical chondroid syringoma of the lower eyelid and review of the literature. *Surv Ophthalmol* 2006;51:280-5.
2. Huerva V, Sanchez MC, Egado RM, Matías-Guiu X. Pleomorphic adenoma with extensive myoepithelial component of the lower eyelid. *Ophthal Plast Reconstr Surg* 2008;24:223-5.
3. Ozdal PC, Callejo SA, Codere F, Burnier MN Jr. Benign ocular adnexal tumours of apocrine, eccrine or hair follicle origin. *Can J Ophthalmol* 2003;38:357-63.
4. Tyagi NN, Abdi UU, Tyagi SP, Maheshwari VV, Gogi RR. Pleomorphic adenoma of skin (chondroid syringoma) involving the eyelid. *J Postgrad Med* 1996;42:125-6.
5. Billroth T. Beobachtungen uber geschwulste der speichel-drusen. *Virchows Arch Pathol Anat* 17:357-75, 1859. Cited by: Mandville JT, Roh JH, Woog JJ, Gonnering RS, Levin PS, Mazzoli RA, *et al.* Cutaneous benign mixed tumor chondroid syringoma of the eyelid: Clinical presentation and management. *Ophthal Plast Reconstr Surg* 2004;20:110-6.
6. Hirsch P, Helwig EB. Chondroid syringoma: Mixed tumor of skin, salivary gland type. *Arch Dermatol* 1961;84:835-47.

| Access this article online | |
|---|----------------------------------|
| Quick Response Code: | Website: www.ijo.in |
|  | DOI: 10.4103/0301-4738.105060 |
| | |