

Case Report

Controllable yawning expressed as focal seizures of frontal lobe epilepsy



Vibhangini S. Wasade^{a,*}, Indranil Balki^b, Susan M. Bowyer^a, Shaila Gaddam^a, Ali-reza Mohammadi-Nejad^{c,d}, Mohammad-Reza Nazem-Zadeh^c, Hamid Soltanian-Zadeh^{c,d}, Andrew Zillgitt^a, Marianna Spanaki-Varelas^a

^a Department of Neurology, Henry Ford Health System, Detroit, MI 48202, USA

^b University of Toronto, Ontario M5S 1A1, Canada

^c Department of Radiology (Image Analysis Laboratory), Henry Ford Health System, Detroit, MI 48202, USA

^d Control and Intelligent Processing Center of Excellence (CIPCE), School of Electrical and Computer Engineering, University of Tehran, Tehran 14395-515, Iran

ARTICLE INFO

Article history:

Received 15 August 2016

Accepted 18 August 2016

Available online 26 August 2016

Keywords:

Yawning

Seizure

Frontal lobe epilepsy

Ictal

VEEG

MEG-CSI

ABSTRACT

Excessive yawning was described in some neurological conditions as part of periictal or ictal manifestations of epilepsy, most commonly temporal lobe. We present the first case of controllable yawning as a primary seizure semiology with dominant frontal lobe involvement in a 20-year-old man. Video electroencephalography recorded 8 yawning episodes accompanied with right arm movement correlating with rhythmic diffuse theta range activity with left hemispheric predominance. Magnetoencephalography coherence source imaging was consistent with persistent neuronal networks with areas of high coherence reliably present over the left lateral orbitofrontal region. Epileptogenic areas may have widespread networks involving the dominant frontal lobe in unique symptomatogenic areas.

© 2016 The Authors. Published by Elsevier Inc. This is an open access article under the CC BY-NC-ND license (<http://creativecommons.org/licenses/by-nc-nd/4.0/>).

1. Introduction

Yawning is a physiological response defined by a sequence of involuntary mouth opening, deep inspiration, brief apnea, and slow expiration [1]. The James–Lange theory suggests that feedback of afferent signals from muscles and viscera integrates at the brain to create arousal, with yawning as a manifestation of bodily consciousness [2]. Certain emotional states and drowsiness are physiological events that have been shown to be associated with excessive yawning [3], as have pathological conditions such as stroke and frontal lobe/brain stem tumors [4–7]. There are only a few cases in the literature where yawning has been described as a symptom of epilepsy. While such cases are rare, they describe yawning as a periictal phenomenon or as an ictal manifestation of epilepsy, most commonly temporal lobe epilepsy (TLE) [8–13]. Based on the current review of the literature, we present the first case of controllable yawning as a primary seizure semiology due to dominant frontal lobe involvement.

2. Case report

A 20-year-old right-handed man presented with brief episodes of strange symptoms with yawning noted since age 18 years. He described

these as brief episodes of yawning lasting a few seconds, with associated lightheadedness, at times with muscle spasms over his arms or neck without loss of awareness. These usually occurred upon waking up in the morning or when sitting at a computer, also when tired or sleep-deprived. He added that he could restrain his urge to yawn.

To characterize his spells, an 8-hour video electroencephalography (VEEG) was performed with a repeat study after 6 months for follow-up. The initial 8-hour VEEG did not show any interictal epileptiform activity. However, 8 typical yawning episodes were recorded, which at times were accompanied by right arm movement and showed rhythmic diffuse theta range activity with left-hemispheric predominance lasting for up to 7 s on EEG (Fig. A.1). A follow-up study performed after 6 months recorded episodes when he restrained his yawn with no ictal correlates on EEG. Stronger yawning episodes showed similar ictal patterns as recorded in the previous study.

Magnetoencephalography (MEG) was also completed with a 148-channel neuromagnetometer system (4D Neuroimaging) with 32 channels of simultaneous digital EEG. No interictal epileptiform activity was present in the MEG for dipole analysis. Overall functional brain connectivity was imaged with MEG coherence source imaging (MEG-CSI). Results were encoded as a color spectrum for values between 1 (entirely coherent) and 0 (no coherence) and overlaid on the patient's MRI with the solutions restricted to the gray matter. The MEG-CSI exclusively lateralized high coherence to the left hemisphere, and persistent neuronal networks were most reliably present in the left lateral orbitofrontal gyrus (Fig. A.2).

* Corresponding author at: Comprehensive Epilepsy Program, Department of Neurology, K-11, Henry Ford Hospital, 2799 West Grand Boulevard, Detroit, MI 48202, USA.
E-mail address: vwasade1@hfhs.org (V.S. Wasade).

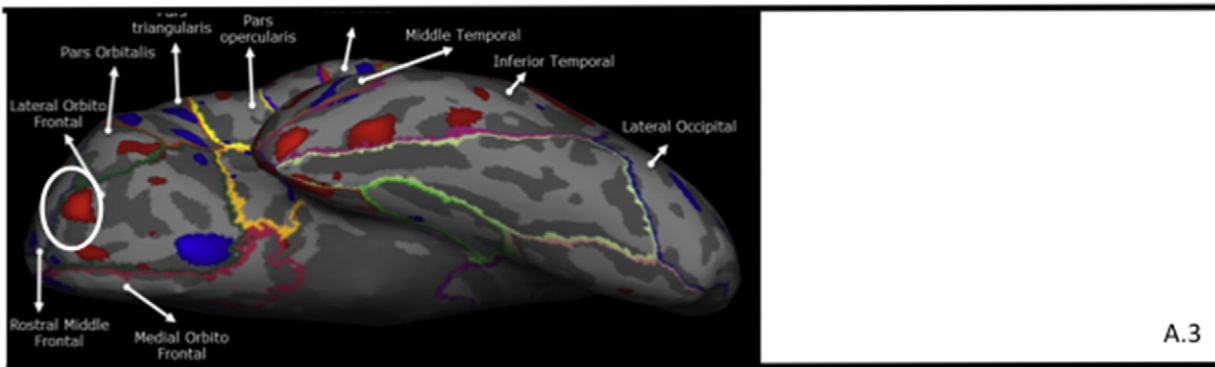
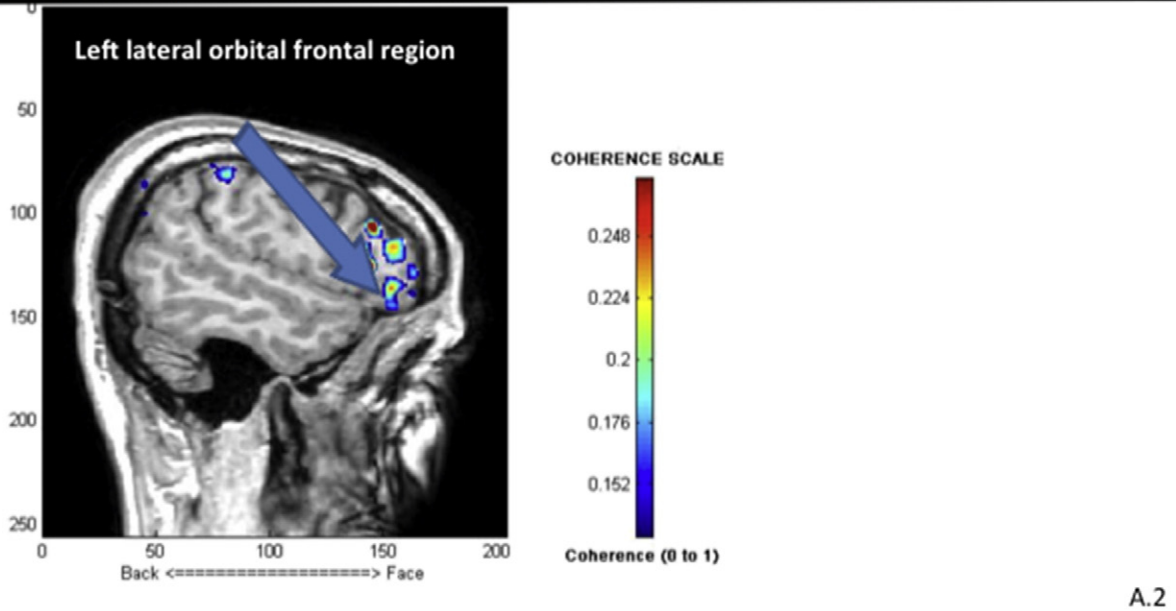
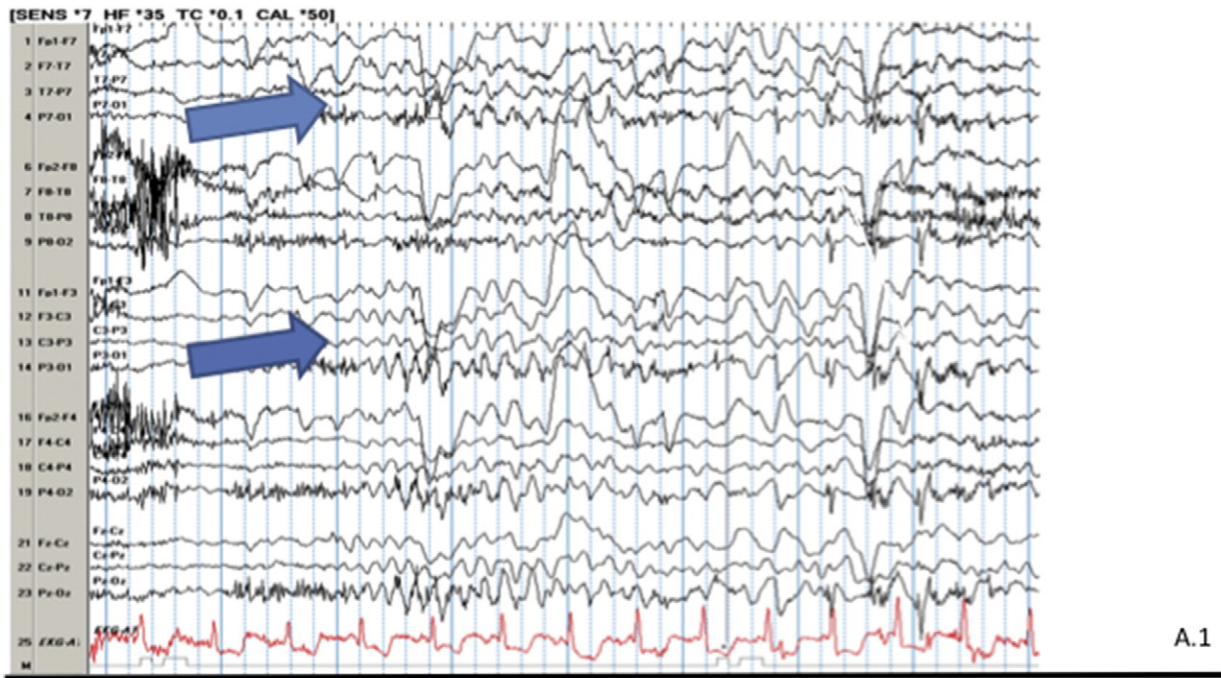


Fig. A. Diagnostic investigations included the following: (A.1) Recording from scalp EEG monitoring at the time of yawning with ictal onset over the left-hemispheric derivations [shown with arrows] (sensitivity: 75 μ V per mm; HF: 35 Hz; TC: 0.1 s; Epoch: 10 s). (A.2) MEG-CSI showing high coherence activity over the left lateral orbitofrontal region [shown with an arrow]. (A.3) MRI brain cortical analysis by FreeSurfer software showing increased gray matter thickness over the left lateral orbitofrontal region [marked red in the circle].

Cortical thickness of the brain was evaluated based on the T1-weighted magnetic resonance images (MRI), acquired on a 1.5T Philips healthcare scanner and processed using the FreeSurfer software (version 5.3.0; <http://www.surfer.nmr.mgh.harvard.edu>). The processing steps were the following. The intensities of the T1-weighted images were bias-corrected using the nonparametric nonuniform intensity normalization implemented in the N3 v1.10 package along with their default parameters. Then, skull stripping was performed using a hybrid watershed algorithm. The cortical regions of the brain were extracted, and the surface of each hemisphere was registered to the surface of the FreeSurfer's atlas. This registration generated the same number of vertices in the two hemispheres. Finally, the cortical thickness of the left hemisphere (LH) was subtracted from the cortical thickness of the right hemisphere (RH) point-by-point. The results are graphically displayed on the LH using a color-coding scheme. A smoothed version of the "LH–RH" map, spatially smoothed using a 5-mm FWHM Gaussian kernel, is also shown on the patient's LH surface, using the same thresholding and color-coding scheme. Left lateral orbitofrontal and medial orbitofrontal (marked in red color) regions showed thicker cortex (Fig. A.3).

The patient was started on lacosamide, and seizures were better controlled with dose optimization to 200 mg twice daily. In addition, he could control the progression of his seizures by consciously restraining his yawn.

3. Discussion

Our case demonstrates controllable yawning as a novel primary seizure semiology in dominant frontal lobe epilepsy as diagnosed with VEEG and MEG and supported by MRI-based cortical thickness analysis. This suggests that epileptogenic areas could also be intricate with widespread networks involving the dominant frontal lobe symptomatogenic areas.

Physiologic yawning is thought to be primarily controlled by the paraventricular nucleus of the hypothalamus, the locus coeruleus, and reticular activating system [14]. One theory proposes that nerve endings of the incertohypothalamic dopaminergic system project into oxytocinergic neurons that, in turn, connect to the hippocampus, pons, and medulla oblongata, stimulating yawning. Several neurotransmitters and neuropeptides have been shown to modulate oxytocinergic neurons [12]. It would seem that any interference in this pathway could lead to pathological yawning.

Yawning is still seldom reported in connection with epilepsy, since first described by Penfield and Jasper [15]. The majority of the literature exists in the form of case reports [14]. A review of the literature by Specchio et al. [14] found 12 patients, with associated periictal or ictal yawning: in 2 patients as preictal, in 4 patients as exclusively ictal, and in 6 patients as postictal manifestation of the seizures. Mechanisms have been proposed to explain periictal yawning, namely brainstem activation due to changes in alertness, activation due to epileptic discharge, or seizure-mediated release of neurohormonal substances [14].

Yawning as an ictal phenomenon has been reported, although rarely, as a pathological condition in the elderly originating from diencephalic/brain stem structures [2]. Three other case reports reveal ictal yawning as a manifestation of TLE [10,11,15], while others displayed either focal spike-and-waves [8] or diffuse attenuation [9] on EEG.

As a postictal phenomenon, yawning occurred in 5 of 6 patients with TLE reviewed by Specchio et al. [14], of which 4 had nondominant TLE with histopathology showing hippocampal sclerosis, ganglioglioma, cavernous angioma, and dysembryoplastic neuroepithelial tumor [13]. Another patient with postictal irresistible, forceful yawning had nondominant hemisphere epilepsy with right centroparietal discharges on EEG [12].

In contrast, our patient appears to be a rare case with yawning occurring as an ictal manifestation of dominant frontal lobe epilepsy.

Occasionally associated symptom of right arm jerk could explain contralateral frontal lobe involvement as well. A study involving slow event-related fMRI experiments in volunteers suggested that ventromedial prefrontal cortex (vmPFC) activation is associated with the urge to yawn by contagion, independently of mirror neuron network [16]. Similarly, the urge to control yawning in our patient could possibly indicate executive function being accessed from the involved frontal lobe.

In addition, it is not uncommon to encounter a paucity of interictal epileptiform discharges on EEG in frontal lobe epilepsy. After obtaining VEEG findings that correlated yawning with ictal left-hemispheric predominant slow activity, further investigation with MEG-CSI confirmed an area of high coherence within the epileptiform network over the left lateral orbitofrontal regions. Although the routine MRI of the brain was unremarkable, advanced analysis examining the cortical thickness showed increased gray matter in the same area as MEG-CSI. This is the first report showing left frontal lobe involvement in ictal yawning diagnosed with functional testing by VEEG and MEG and structural brain mapping by MRI cortical thickness analysis.

The functional differences between vmPFC and orbitofrontal regions are not yet well understood. Although the exact mechanism for our patient's seizure semiology is unclear, it is possible that neural networks within vmPFC and the lateral orbitofrontal region activated by epileptic discharges somehow trigger the reflex in brainstem leading to yawning. Although our patient appeared to be a rare case, it is possible that many cases go unreported, especially if seizures are controllable.

In conclusion, the case we described expands our view on the possibilities of localization for ictal yawning that could also be present with dominant frontal lobe epilepsy. Our understanding in such cases is still inadequate, and further studies with advanced diagnostic investigative modalities will likely help better define such epilepsies with intricate neuronal networks.

Conflict of interest

There are no competing interests of this paper.

References

- [1] Walusinski O, Deputte BL. The phylogeny, ethology and nosology of yawning. *Rev Neurol (Paris)* 2004;11:1011–21.
- [2] Nicotra A, Khalil NM, Owbridge P, Hakda M, Beitverda Y. Pathological yawning as an ictal seizure manifestation in the elderly. *BMJ Case Rep* 2012;12.
- [3] Guggisberg AG, Mathis J, Schneider A, Hess CW. Why do we yawn? *Neurosci Biobehav Rev* 2010;34:1267–76.
- [4] O'Sullivan JD, Lees AJ, Hughes AJ. Yawning in Parkinson's disease. *Neurology* 1999;52:428.
- [5] Singer OC, Humpich MC, Lanfermann H, Neumann-Haefelin T. Yawning in acute anterior circulation stroke. *J Neurol Neurosurg Psychiatry* 2007;78:1253–4.
- [6] Schiller F. Yawning? *J Hist Neurosci* 2002;11:392–401.
- [7] Williams DR. The yawning reflex: an upper motor neuron sign in amyotrophic lateral sclerosis. *Neurology* 2000;55:1592–3.
- [8] Goldie L, Green JM. Yawning and epilepsy. *J Psychosom Res* 1961;5:263–8.
- [9] Donat JF, Wright FS. Unusual variant of infantile spasms. *J Child Neurol* 1991;6:313–8.
- [10] Muchnik S, Finkielman S, Semeniuk G, de Aguirre MI. Yawning and temporal lobe epilepsy. *Medicina (B Aires)* 2003;63:137–9.
- [11] Medrano V, Selles-Galiana MF, Fernández-Izquierdo S, Mallada-Frechin J, Díaz-González F, Piqueras-Rodríguez L. Yawning and temporal lobe epilepsy. *Rev Neurol* 2005;41:63–4.
- [12] Yankovsky AE, Andermann F, Dubeau F. Post-ictal forceful yawning in a patient with nondominant hemisphere epilepsy. *Epileptic Disord* 2006;8:65–9.
- [13] Kuba R, Musilová K, Brázdil M, Rektor I. Peri-ictal yawning lateralizes the seizure onset zone to the nondominant hemisphere in patients with temporal lobe epilepsy. *Epilepsy Behav* 2010;19:311–4.
- [14] Specchio N, Carotenuto A, Trivisano M, Cappelletti S, Vigevano F, Fusco L. Ictal yawning in a patient with drug-resistant focal epilepsy: video/EEG documentation and review of literature reports. *Epilepsy Behav* 2011;22:602–5.
- [15] Penfield W, Jasper H. *Epilepsy and the functional anatomy of the human brain*, 416–8. Oxford, England: Little, Brown & Company; 1954.
- [16] Nahab FB, Hattori N, Saad ZS, Hallett M. Contagious yawning and the frontal lobe: an fMRI study. *Hum Brain Mapp* 2009;30:1744–51.