

Received: 2020.06.09

Accepted: 2020.08.28

Available online: 2020.09.25

Published: 2020.11.04

Reconstruction of a Pharyngeal Cutaneous Fistula Using a Bi-Paddled Pectoralis Major Flap for a Patient with a Possibility of Future Postoperative Radiotherapy

Authors' Contribution:

Study Design A
Data Collection B
Statistical Analysis C
Data Interpretation D
Manuscript Preparation E
Literature Search F
Funds Collection G

E 1,2 **Daiki Morita**
E 1,3 **Hitoshi Nemoto**
E 1 **Masaru Miyamoto**
E 1 **Kenta Miyabe**
E 1 **Tomoichiro Togo**
E 4 **Sei Kobayashi**

1 Department of Plastic and Reconstructive Surgery, Showa University Fujigaoka Hospital, Yokohama, Kanagawa, Japan
2 Department of Plastic and Reconstructive Surgery, Kyoto Prefectural University of Medicine, Kyoto, Japan
3 Department of Plastic and Reconstructive Surgery, Tokai University Hospital, Isehara, Kanagawa, Japan
4 Department of Otolaryngology, Showa University Fujigaoka Hospital, Yokohama, Kanagawa, Japan

Corresponding Author: Daiki Morita, e-mail: d-morita@koto.kpu-m.ac.jp
Conflict of interest: None declared

Patient: Male, 51-year-old
Final Diagnosis: Pharyngeal cutaneous fistula
Symptoms: Fistula • infection
Medication: —
Clinical Procedure: —
Specialty: Oncology • Plastic Surgery • Surgery

Objective: Unusual or unexpected effect of treatment

Background: Pharyngocutaneous fistulas are often difficult to treat because pharyngeal contents tend to leak into the cervical layer causing wound infections or abscesses. If reconstruction with free flaps is difficult, pedicled pectoralis major flaps are an option.


Case Report: A 51-year-old male patient who had undergone radiation and chemotherapy for laryngeal cancer was scheduled for total laryngectomy with combined skin resection for local tumor recurrence. Reconstruction with a left deltopectoral (DP) flap was performed. However, a pharyngocutaneous fistula constructed due to cervical soft-tissue infection required reconstruction using a right bi-paddled pectoralis major muscle. The anterior pharyngeal wall was reconstructed with the medial skin island, and the lateral skin island was folded back to reconstruct the soft tissues.

Since this was the patient's third recurrence, the possibility of subsequent local recurrences, and hence of the need for radiation therapy, were high. In such cases, the pedicle of the pectoralis major muscle flap is normally closed using a DP flap. However, in the present case, the DP flap had already been used on both sides. We therefore utilized a right bi-paddled pectoralis major flap for cervical reconstruction.

Conclusions: We successfully reconstructed the cervical skin and soft tissue thickly, and primarily-closed the donor site, by creating a second skin island from surplus areas of the existing skin island. This method is particularly useful for the reconstruction of cervical skin and soft tissues due to the possible need for future radiation therapy, when the use of free flaps and DP flap is unfeasible.

MeSH Keywords: Cervicoplasty • Head and Neck Neoplasms • Pectoralis Muscles

Full-text PDF: <https://www.amjcaserep.com/abstract/index/idArt/926689>



1835



—



3



16



Background

Pharyngeal cutaneous fistulas after head and neck reconstruction are often intractable, with neck infections and abscesses caused by swallowing pressure and leakage of saliva [1,2]. If the cervical vessels are unavailable or the skin condition is poor after radiation treatment, reconstruction with free flaps is difficult and pedicled pectoralis major flaps are one of the options.

The pectoralis major muscle flap is very useful in head and neck reconstruction because it has an abundant muscular body that is suitable for filling the dead space and covering large vessels, and is adjacent to the head and neck [3–6]. When reconstructing a pharyngeal skin fistula with such a flap, it is turned over and moved to the neck, and the pharynx is then reconstructed with chest skin. After that, a skin graft is performed to the back of the pectoralis major muscle at the neck. This method is used commonly because it provides good wound healing [7].

We performed pharyngeal reconstruction using a right bi-paddled pectoralis major muscle flap for a pharyngeal skin fistula after head and neck reconstruction, but without skin grafting on the back of the muscular body. Another skin island was created away from the chest and folded back to reconstruct the soft tissues of the neck. Here, we report on this method.

Case Report

The patient was a 51-year-old man who had undergone radiation and chemotherapy for laryngeal cancer (T2N0M0). One year later, the tumor recurred and a partial laryngectomy was performed. Two years after this, the patient had a second recurrence, and a partial laryngectomy and reconstruction with a right deltopectoral (DP) flap was performed. Three years after the initial surgery, a third recurrence was confirmed, and the patient was scheduled for a complete laryngectomy and combined skin resection. He was referred to our department for skin and soft-tissue reconstruction.

After laryngectomy and resection of the surrounding skin by an otolaryngologist, the soft tissue of the neck was reconstructed with a left DP flap. Because a low-grade fever and high inflammatory response continued from the day after the operation, a swallowing test using contrast agent was performed. Leakage of the agent was observed in the hypopharynx. Therefore, a pharyngeal skin fistula was constructed to prevent possible exacerbation of the cervical soft-tissue infection caused by saliva retention (Figure 1).

After controlling this local infection, we planned to reconstruct the fistula by using the right bi-paddled pectoralis major muscle to close the pharyngeal fistula. A skin island including the

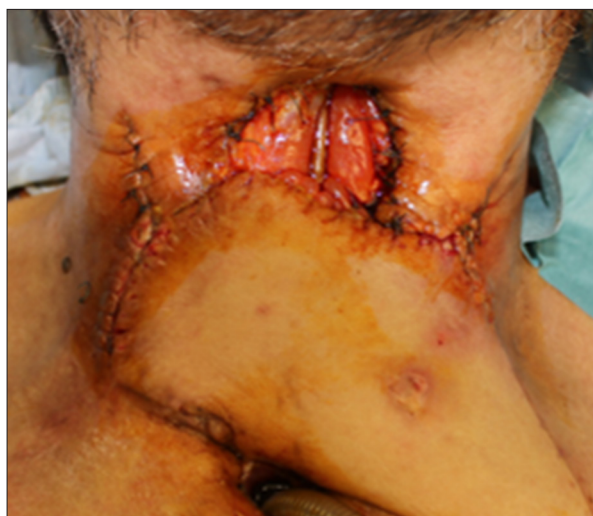

Figure 1. Preoperative view. This pharyngeal cutaneous fistula was constructed to control local infection. A bi-paddled pectoralis major flap reconstruction was planned to close the fistula.

5th and 6th intercostal artery perforators on the medial side of the chest was constructed, and another skin island on the outer cranial side was constructed (Figure 2). The pectoralis major flap was turned over and moved subcutaneously to the cervical region; the anterior pharyngeal wall was reconstructed at the medial skin island, and the lateral skin island was folded back to reconstruct the cervical soft tissue. When the flap was moved to the neck, we confirmed that the pedicle was not strongly compressed by the bleeding from the skin islands, the color tone, and refilling of the skin islands. The donor site did not require skin grafting and could be closed temporarily (Figure 3). A swallowing test with contrast agent was performed 10 days after the operation, and no leakage was observed. The flaps all survived and the patient could start to take food and liquids orally by 3 weeks after surgery.

Discussion

Pharyngeal fistulas and pharyngeal skin fistulas are often difficult to treat because the pharyngeal contents, including saliva, leak into the cervical layer and cause wound infections or abscesses [1,2]. To close such pharyngeal skin fistulas, it is important to ensure sufficient blood flow through the flap used. However, if the vascular anastomosis is unreliable because the cervical blood vessels are in poor condition from the effects of past radiation treatment or infections, it is difficult to choose a free flap. In such cases with a hinge flap using the skin around the fistula, a pectoralis major or a DP flap are frequently used. Among them, the pectoralis major muscle flap is most common because the soft tissue of the skin is thick and the muscular body can be transplanted [3–6]. When

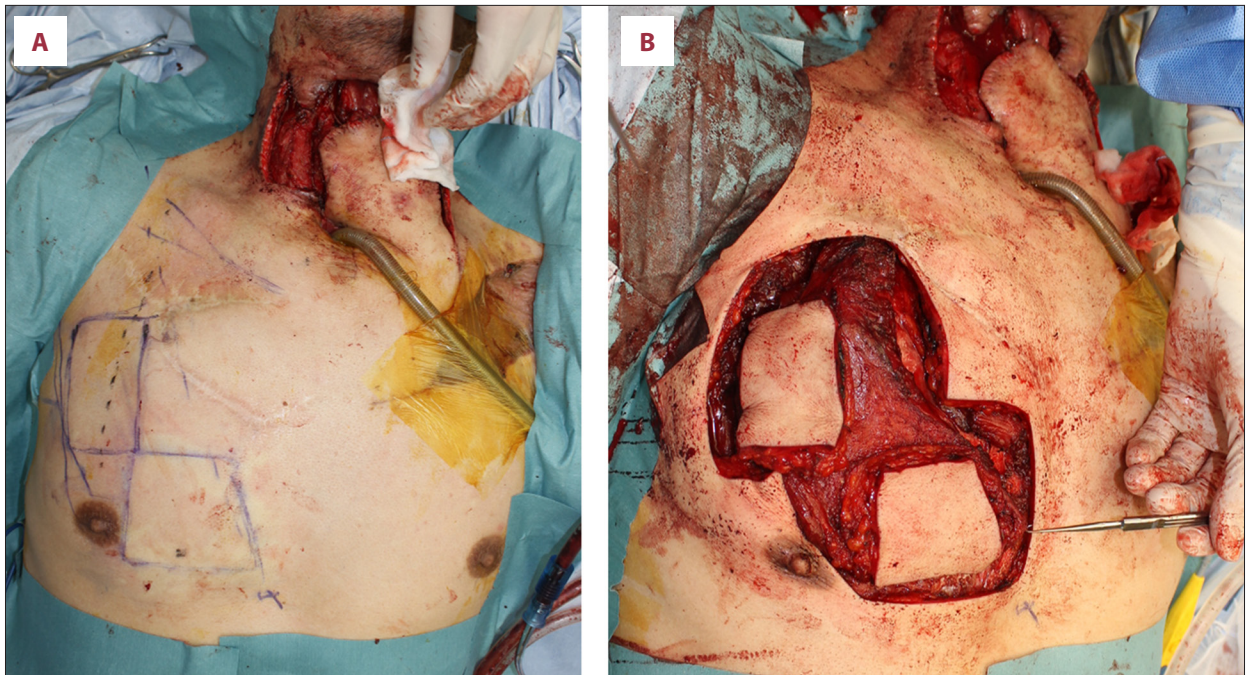


Figure 2. Operative view. (A) The design of bi-paddled pectoralis muscle flap. (B) The bi-paddled pectoralis major flap was harvested. The anterior pharyngeal wall was reconstructed at the medial skin island, and the outer skin island was folded back to reconstruct cervical soft tissue.

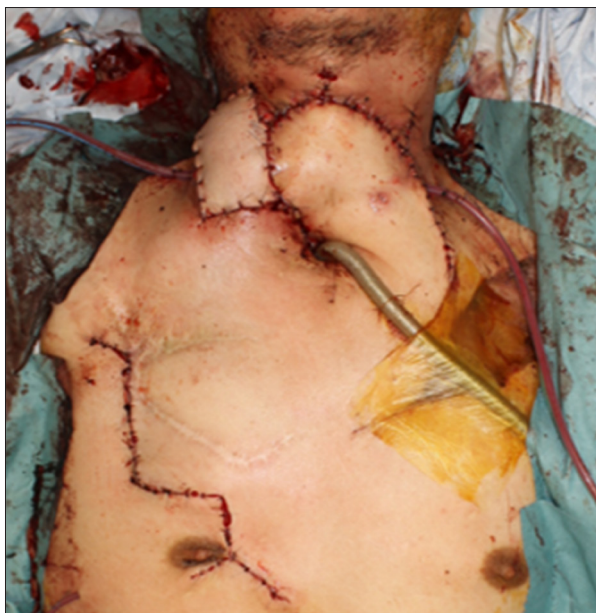

Figure 3. Postoperative view. The donor site did not require skin grafting and could be closed temporarily.

using the pectoralis major muscle flap, it is often difficult to close the pedicle with cervical skin because the pedicle is bulky with muscle. Therefore, skin grafting on the back of the inverted muscle body is usually performed [7].

Our case involved a case of tumor recurrence after irradiation. The condition of the soft tissue of the cervical skin was poor, and infectious necrotic tissue from the pharyngeal fistula was close to the large cervical blood vessels. Therefore, because these vessels were unreliable, we chose reconstruction with a pedicled pectoralis major muscle flap instead of a free flap. In addition, recurrence of the patient's cancer had occurred 3 times, and there was a possibility of further local recurrences. Therefore, we thought it was important to have the option of performing radiation therapy at a region different from the first radiation field if and when such a recurrence occurred. However, the irradiation may have palliative rather than curative implications. When skin grafting is performed on the back of the pectoralis major muscle, there is a risk that further radiation therapy will cause the skin graft to fall off, making the wound intractable, and this would affect the deeper large cervical blood vessels. In such cases, the pedicle of the pectoralis major muscle flap is normally closed using a DP flap; however, in our case, a DP flap had already been used on both sides. Therefore, we planned the reconstruction of cervical skin and soft tissue with a bi-paddled pectoralis major flap.

It has been routine practice to use such a flap as one of the methods for reconstruction of full-thickness defects after the resection of cheek tumors [8,9], as 2 skin islands are created vertically along the pectoralis major branch of the thoracoacromial artery. However, in such cases there is a problem in that the mobility of the proximal skin island is limited. Based on

previous reports evaluating the hemodynamics of the pectoralis major region, it became common practice to design 2 skin islands horizontally at the height of the areola [10–12]. It is important to ensure that the lateral-side skin island is located within the pectoralis major muscle and includes the terminal branch of the pectoral muscle's artery or the perforator of the lateral thoracic artery, and that it is not peeled away from the pectoralis major muscle [11–13]. Because these complications are not so different from those of the normal pectoralis major muscle flap, it is useful as a method for reconstructing a full-thickness cheek defect when a free flap cannot be used. As described above, there are many reports of using the pectoralis major muscle flap as a bi-paddled form, but there are few reports that such a flap has been used as in this case to reconstruct the cervical skin and soft tissues to sufficient thickness.

During surgery for this case, a skin island for reconstructing the anterior wall of the pharynx was constructed under the areola and nipple, including the 5th and 6th intercostal artery perforators. Another skin island was created on the lateral and cranial side, and the bi-paddled pectoralis major muscle flap was harvested along with the pectoral muscle branch of the thoracoacromial artery. The lateral skin island was created in a surplus area as a 'dog ear' shape when the donor site of the medial skin island was closed, and the skin island contained the terminal branch of the pectoral muscle branch or the perforator of the lateral thoracic artery. The flap survived, and the cervical skin and soft tissue could be reconstructed with sufficient thickness.

As reported by Rikimaru et al., the hemodynamics of the pectoralis major muscle are different between the cranial and caudal sides at the height of the 4th costal cartilage [14,15]. The blood supply is formed by a direct anastomosis of the pectoral muscle branch of thoracoacromial artery, and the first-to-third intercostal perforators of the internal thoracic artery on the cranial side. Caudally, the supply is formed from a vascular network of the fourth-to-sixth intercostal perforators of the internal thoracic artery and the perforators from the fourth-to-sixth anterior intercostal branches of the internal thoracic artery. In addition, the vascular network of the skin and soft tissues of the anterior chest mainly consist of the first-to-sixth intercostal perforators of the internal thoracic artery, a cutaneous branch of the seventh intercostal perforator, and cutaneous branches of the fourth-to-sixth anterior intercostal branches of perforators and a cutaneous branch of the lateral thoracic artery. In the lateral pectoralis major muscle, the

lateral thoracic artery is distributed dendritically in the lateral border, and in the subcutaneous tissue layers of the lateral thoracic region. The terminal branch of the pectoralis major branch emerges from the lateral border of the pectoralis major muscle and is anastomosed with these directly to form a subcutaneous vascular network on the outer part of the precordial region. In this way, the subcutaneous vascular network of the outer part of the precordial region is formed.

Here, a continuous blood circulation route was secured and the skin island survived because the lateral one was created on this subcutaneous vascular network and placed on the pectoralis major muscle. However, this skin island was not nourished directly by the pectoralis major muscle branch of the thoracoacromial artery, but rather had a secondary region of blood circulation control through choke vessels. If the skin island is located too far laterally, the blood flow might become unstable. As reported, it is considered safer to locate the lateral skin island within the pectoralis major muscle for survival of the skin island.

When a pectoralis major muscle flap is used, the donor site is often unable to be closed and needs grafted skin. Such grafts have poor aesthetic appearance and costal cartilages might be exposed because of graft failure, which may lead to costochondritis or intractable ulcers [16]. In our case, primary closure was enabled by utilizing the 'dog ear' part by creating a second skin island. In terms of measures against complications after harvesting the pectoralis major muscle flap, we believe that this has led to good results. In addition, because skin grafting on the back of the muscular body was avoided, the esthetic appearance of the neck (the exposed region) was also judged excellent.

Conclusions

We reconstructed a cervical pharyngeal cutaneous fistula using bi-paddled pectoralis major flaps for a patient who might need to be treated with radiotherapy in the future. We could reconstruct the cervical skin and soft tissue thickly and close the donor site primarily by creating a second skin island in the area that became surplus when the donor site of the first skin island was closed primarily. This method is useful when it is necessary to reconstruct cervical skin soft tissues thickly when free flaps cannot be used, given the possible effects of future radiation therapy.

References:

1. McLean JN, Nicholas C, Duggal P et al: Surgical management of pharyngocutaneous fistula after total laryngectomy. *Ann Plast Surg*, 2012; 68(5): 442–45
2. Hamahata A, Beppu T, Saitou T et al: The usefulness of triple layers suturing technique with frilled pectoralis major musculocutaneous flap for pharyngocutaneous fistula. *J Plast Reconstr Aesthet Surg*, 2014; 67(1): e32–33
3. Ariyan S: The pectoralis major myocutaneous flap. A versatile flap for reconstruction in the head and neck. *Plast Reconstr Surg*, 1979; 63(1): 73–81
4. Mehrhof Al Jr., Rosenstock A, Neifeld JP et al: The pectoralis major myocutaneous flap in head and neck reconstruction. Analysis of complications. *Am J Surg*, 1983; 146(4): 478–82
5. Spriano G, Pellini R, Roselli R: Pectoralis major myocutaneous flap for hypopharyngeal reconstruction. *Plast Reconstr Surg*, 2002; 110(6): 1408–13
6. Koh KS, Eom JS, Kirk I et al: Pectoralis major musculocutaneous flap in oropharyngeal reconstruction: revisited. *Plast Reconstr Surg*, 2006; 118(5): 1145–49
7. Miyamoto S, Kayano S, Fujiki M et al: Combined use of the cephalic vein and pectoralis major muscle flap for secondary esophageal reconstruction. *Microsurgery*, 2014; 34(4): 319–23
8. Ord RA, Avery BS: Side-by-side double paddle pectoralis major flap for cheek defects. *Br J Oral Maxillofac Surg*, 1989; 27(3): 177–85
9. Bhatena HM, Kavarana NM: The folded, bipaddled pectoralis major composite flap in oral cancer reconstruction. *Br J Plast Surg*, 1989; 42(4): 441–46
10. Deo SV, Purkayastha J, Das DK et al: Reconstruction of complex oral defects using bi-paddle pectoralis major flap – technical modifications and outcome in 54 cancer patients. *Indian J Otolaryngol Head Neck Surg*, 2003; 55(1): 5–9
11. Ahmad QG, Navadgi S, Agarwal R et al: Bipaddle pectoralis major myocutaneous flap in reconstructing full thickness defects of cheek: A review of 47 cases. *J Plast Reconstr Aesthet Surg*, 2006; 59(2): 166–73
12. Bholra N, Jadhav A, Borle R et al: Is there still a role for bilobed/bipaddled pectoralis major myocutaneous flap for single-stage immediate reconstruction of post ablative oncologic full-thickness defects of the cheek? *Oral Maxillofac Surg*, 2015; 19(2): 125–31
13. Miyazaki H, Igari K, Kudo T et al: Significance of the lateral thoracic artery in pectoralis major musculocutaneous flap reconstruction: Quantitative assessment of blood circulation using indocyanine green angiography. *Ann Plast Surg*, 2017; 79(5): 498–504
14. Rikimaru H, Kiyokawa K, Inoue Y et al: Three-dimensional anatomical vascular distribution in the pectoralis major myocutaneous flap. *Plast Reconstr Surg*, 2005; 115(5): 1342–52
15. Nishi Y, Rikimaru H, Kiyokawa K et al: Development of the pectoral perforator flap and the deltopectoral perforator flap pedicled with the pectoralis major muscle flap. *Ann Plast Surg*, 2013; 71(4): 365–71
16. Proulx AM, Zryd TW: Costochondritis: Diagnosis and treatment. *Am Fam Physician*, 2009; 80(6): 617–20