

Dabigatran must be used carefully: literature review and recommendations for management of adverse events

This article was published in the following Dove Press journal:
Drug Design, Development and Therapy

Shan Lin*
Yan Wang*
Lei Zhang
Wei Guan

Department of Respiratory Medicine,
Qinghai University Affiliated Hospital,
Xining 810001, People's Republic of
China

*These authors contributed equally to
this work

Abstract: Atrial fibrillation increases the risk of stroke and death. The vitamin-K antagonist warfarin is recommended for patients with atrial fibrillation, but vitamin-K antagonists are cumbersome to use. Therefore, an effective, safe and convenient new anticoagulant is needed. Dabigatran acts by inhibiting free and fibrin-bound thrombin directly. It is an oral anticoagulant that was approved by the US Food and Drug Administration. The oral anticoagulant dabigatran has been used increasingly due to its good tolerance, predictable pharmacokinetics, effective anticoagulant effects, and absence of requirement of coagulation monitoring. However, an increasing prevalence of adverse events has been reported, some of them quite serious. Therefore, we searched and reviewed the literature on dabigatran with regard to adverse events, and proposed solutions to prevent and reduce the chance of adverse events occurring.

Keywords: adverse events, dabigatran, allergic reactions, bleeding, esophageal injury

Introduction

Atrial fibrillation increases the risk of stroke and death.¹ The vitamin-K antagonist warfarin is recommended for patients with atrial fibrillation and who are at risk of stroke, which reduces the risk of stroke and death, but increases the risk of bleeding. Vitamin-K antagonists are cumbersome to use due to: interactions with multiple foods and drugs; a narrow therapeutic range; significant changes in anticoagulant response; a slow onset of action; requirement of frequent testing of laboratory parameters. Patients who receive warfarin have poor compliance and a high prevalence of treatment withdrawal due to the factors mentioned above, so many patients do not receive adequate anticoagulant therapy.² Therefore, an effective, safe and convenient new anticoagulant is needed.

Dabigatran acts by inhibiting free and fibrin-bound thrombin directly. It is an oral anticoagulant that was approved by the US Food and Drug Administration in 2010 to prevent embolic events in patients with non-valvular atrial fibrillation.³ Dabigatran has been used increasingly in clinical practice due to its good tolerance, predictable pharmacokinetics, effective anticoagulant effects, and absence of need of coagulation monitoring. Dabigatran is used as an alternative to warfarin, and it appears to be as effective as warfarin in preventing embolic events in patients with non-hemorrhagic stroke and atrial fibrillation rather than in patients with valve problems.⁴

Correspondence: Wei Guan
Department of Respiratory Medicine,
Qinghai University Affiliated Hospital,
Xining 810001, People's Republic of China
Tel +860 971 623 0883
Email weiguan110@163.com

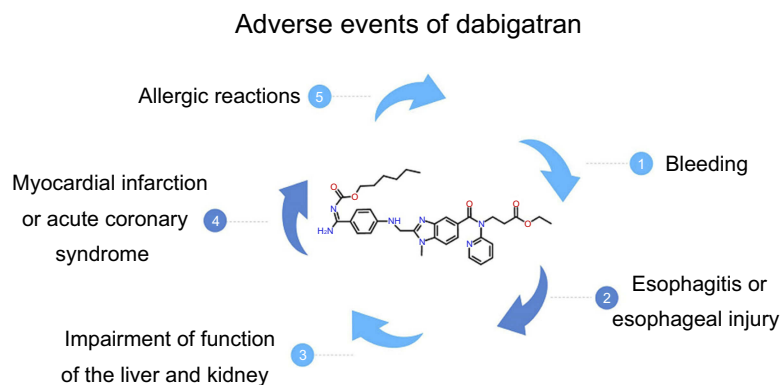


Figure 1 The adverse events of dabigatran.

Despite the many advantages of dabigatran, reports of adverse events have emerged in recent years, such as gastrointestinal discomfort and bleeding. Although patients taking dabigatran have fewer life-threatening hemorrhages, the prevalence of gastrointestinal bleeding was significantly higher than in those who used warfarin.³ An increasing prevalence of adverse events has been reported,^{5–27} some of them quite serious. Therefore, we searched and reviewed the literature on dabigatran with regard to adverse events (Figure 1).

We searched PubMed, Google scholar and the Chinese National Knowledge Infrastructure using the key words “dabigatran and adverse events”, “dabigatran and side effects” and “dabigatran and induced” from December 2010 to November 2018. Case reports were selected on the adverse events of dabigatran that they described. Twenty-three case reports were reviewed and analyzed, and the clinical features are listed in Table 1.

Adverse events of dabigatran

Bleeding

As with any anticoagulant drug, various types of hemorrhage are common adverse events. Of the cases we reviewed, seven patients developed severe hemorrhage,^{5–11} including three cases of fatal gastrointestinal hemorrhage.^{8–10} Major bleeding was reported to occur in a dose-dependent manner, and this was reported in fewer than 3% of patients during a trial comparing dabigatran with other anticoagulants.^{28,29} Similarly, Connolly et al reported that the prevalence of major bleeding was 2.71% per year in the group receiving dabigatran (110 mg, b.d.) and 3.11% per year in the group receiving dabigatran (150 mg, b.d.), and that the prevalence of life-threatening bleeding in those receiving 110 and 150 mg of dabigatran twice-daily was 1.22% and 1.45%, respectively.³

The three patients who died of gastrointestinal bleeding caused by dabigatran were old (mean age=81 years). One of them took only 150 mg of dabigatran once-daily,⁸ but this may have been related to the hip arthroplasty that she underwent. These gastrointestinal events may have been due to the dabigatran formulation, which contains granules of tartaric acid to provide an acidic environment. A lower pH is associated with dyspepsia and plays a part in the increased risk of gastrointestinal bleeding.²⁸ Spontaneous hemopericardium,⁵ spontaneous hemothorax⁶ and hemorrhagic cystitis⁷ occurred separately in three patients. Major bleeding in these anatomic areas is uncommon and has rarely been reported, but it should be documented. Other risk factors of dabigatran-induced gastrointestinal bleeding include concurrent use of ulcerogenic drugs, older age, *Helicobacter pylori* infection, and previous history of gastrointestinal bleeding. *Helicobacter pylori* infection and use of NSAIDs are independent risk factors for duodenal ulcer and gastric ulcer and related bleeding.^{30,31} Therefore, we should prevent the combined hemorrhagic effect of dabigatran and *Helicobacter pylori*, and the patient should be screened for *Helicobacter pylori* before anticoagulant therapy. In general, these findings also show that the risk of venous thromboembolism and bleeding should be considered before deciding the anticoagulation given to the patient.

Esophagitis or esophageal injury

Another adverse event that requires attention is esophagitis or esophageal injury (including esophageal ulcers) induced by dabigatran intake.^{12–19} In 1983, it was estimated that the esophageal injury caused by drugs was only 3.9 cases per 100,000 people per year.³² In 2016, Toya et al reported that dabigatran use caused ~20% of patients to suffer damage to the esophageal mucosa.³³ However, among

Table 1 Clinical features of dabigatran-induced adverse events

Ref.	Author	Age	Country	Gender	Dosage	Adverse events	Main symptoms	Treatment	Outcomes
5	Jelani Q et al.	87	United States	Male	150 mg, twice daily	Spontaneous hemopericardium	Dyspnea on exertion	Dabigatran discontinued;	Improved
6	Huang J et al.	83	China	Male	110 mg, twice daily	Spontaneous hemothorax	Chest pain and dyspnea	Pericardioentesis; Idarucizumab Dabigatran discontinued;	Improved
7	Otteno H et al.	82	United States	Female	Unknown	Hemorrhagic cystitis	Pelvic pain, dysuria, frequency, and urgency	Thoracoentesis Warfarin replaces dabigatran	Improved
8	Carter A et al.	79	United Kingdom	Female	150 mg, once daily	Gastrointestinal haemorrhage	Abdominal pain and hypotensive shock	Resuscitation	Death
9	Dumkow LE et al.	85	United States	Male	150 mg, twice daily	Gastrointestinal bleeding	Malaise and difficulty breathing	PCC and FFP	Death
10	Cano EL et al.	78	United States	Female	150 mg, twice daily	Fatal Hemorrhage	Hematochezia, nausea, vomiting, and diarrhea	PRBC, Platelet and PCC	Death
11	Wychowowski MK et al.	66	United States	Female	150 mg, twice daily	Gastrointestinal bleeding	Altered mental status	PRBC and PCC	Improved
12	Matsuura H et al.	84	Japan	Male	Unknown	Oesophagitis	Progressive dysphagia and odynophagia	Apixaban replaces dabigatran; PPI	Improved
13	Fujikawa K et al.	87	Japan	Male	220 mg, once daily	Esophageal injury	Heartburn and dysphagia	Apixaban replaces dabigatran; Fasting	Improved
14	Yoshimitsu M et al.	78	Japan	Female	Unknown	Exfoliative esophagitis	Epigastralgia	Drink a sufficient of water; Maintain an upright position	Improved
15	Shibagaki K et al.	75	Japan	Male	110 mg, twice daily	Esophageal mucosal injury	None	Warfarin replaces dabigatran	Improved
16	Izumikawa K et al.	67	Japan	Male	150 mg, twice daily	Esophageal ulcer	Heartburn	Drink a sufficient of water; Maintain an upright position	Improved
17	Zimmer V et al.	81	Japan	Female	110 mg, twice daily	Esophageal ulcer	Chest pain and upper abdominal pain.	Drink a sufficient of water; Maintain an upright position	Improved
18	Ootani A et al.	70	Germany	Female	Unknown	Exfoliative esophagitis	Chest pain and odynophagia	Dabigatran discontinued; PPI	Improved
19	Singh S et al.	69	United Kingdom	Male	110 mg, twice daily	Esophagitis	Retrosternal pain and dysphagia	Dabigatran discontinued; Rabeprazole	Improved
20	Patel S et al.	59	United States	Male	220 mg once	Oesophagogastric ulceration	Retrosternal pain and odynophagi	Dabigatran discontinued; Rabeprazole	Improved
					Unknown	Acute interstitial nephritis	Vomiting and epigastric pain	Dabigatran discontinued; PPI	Improved
							No symptoms with Abnormal laboratory test	Prednisone	Improved

(Continued)

Table 1 (Continued).

Ref.	Author	Age	Country	Gender	Dosage	Adverse events	Main symptoms	Treatment	Outcomes
21	Rochweg B et al.	71	Canada	Male	Unknown	Acute hepatitis	Progressive painless icterus, fatigue, and anorexia	Dabigatran discontinued	Improved
22	Zaleski M et al.	52	United States	Male	Unknown	Hyperkalemia	Unknown	Dabigatran discontinued	Improved
23	Stöllberger C et al.	89	Austria	Female	110 mg, twice daily	Lupus	Epistaxis	Dabigatran discontinued; Cauterization.	Improved
24	Mancano M A.	71	United States	Female	150 mg twice	Pustular eruptions	Itching on palms and feet	Dabigatran discontinued; Enoxaparin	Improved
25	Eid TJ et al.	78	Caucasus	Male	150 mg twice	Rash	Diffuse, full-body pruritic rash	Dabigatran discontinued; Diphenhydramine	Improved
26	Vega-Molpeceres S et al.	80	Spain	Female	Unknown	Exanthem	Itching	Dabigatran discontinued; H ₂ RA	Improved
27	Whitehead H et al.	20	United States	Male	150 mg, twice daily	Exanthem	Itching	Dabigatran discontinued; Prednisone	Improved

Abbreviations: H₂RA, H₂ receptor inhibitor; PPIs, proton pump inhibitors; PCC, prothrombin complex concentrate; PRBC, packed red blood cells; FFP, fresh frozen plasma.

the cases we reviewed, 10 of 25 patients developed varying degrees of esophagitis or esophageal injury after dabigatran use. Therefore, dabigatran-induced esophagitis may be overlooked in asymptomatic patients who have not undergone endoscopy. Among the 10 patients (four males and six females) we reviewed, the mean age was 77 years and there was no significant difference between the doses of dabigatran used. It has been speculated that the tartaric acid core in dabigatran not only plays a part in gastrointestinal bleeding, but is released after digestion and adheres to the esophagus to damage the esophageal mucosa, and then the damaged esophageal mucosa exfoliates after peristalsis.³⁴ In older patients, due to reduced activity (sitting or lying down for long periods) and reduced salivary secretion, if the volume of water consumed is low, the lack of a sufficient liquid bolus will increase the possibility of contact by dabigatran with the esophageal mucosa. The mean age of the patients we reviewed was 77 years, so we speculate that advanced age was an important risk factor for dabigatran-induced esophagitis. Clinicians should not ignore the possibility of esophagitis after giving patients dabigatran, especially if patients develop dysphagia, chest pain, upper abdominal pain, or heartburn.

Impairment of function of the liver and kidney

The Randomized Evaluation of Long-Term Anticoagulation Therapy (RE-LY) trial showed that impairment of liver function (an increase in the levels of aspartate aminotransferase or alanine aminotransferase by more than three times the upper limit of the normal range) caused by dabigatran did not occur more frequently than that with warfarin.³ In the literature that we reviewed, dabigatran-induced acute interstitial nephritis,²⁰ acute hepatitis²¹ and hyperkalemia²² were reported. In a phase-II dose-finding trial of dabigatran, Eriksson et al found only mild increases in transaminase levels in the dose ranges tested, but two patients had severe hepatitis (transaminase levels more than five times the upper limit of normal).³⁵ The cause of liver and kidney dysfunction caused by dabigatran may be because first-pass elimination occurs in the liver and 80% of a given dose is excreted by the kidney.³⁶ One of the patients in a study experienced hyperkalemia. Hyperkalemia is a potentially fatal side-effect that can occur in patients with altered renal function, and understanding that dabigatran can cause hyperkalemia in this patient population is crucial. Dabigatran can induce hyporenemic hypoaldosteronism in patients with impaired renal

function, which leads to hyperkalemia. Careful monitoring of renal function is recommended if physicians prescribe dabigatran for patients with renal insufficiency.

Myocardial infarction or acute coronary syndrome

A small (but significant) increased risk of myocardial infarction or acute coronary syndrome has been noted when combining safety-outcome data from multiple trials.³⁷ The RE-LY trial showed that the prevalence of myocardial infarction per year was 0.53% with warfarin, and that the prevalence per year in patients taking 110 mg of dabigatran and 150 mg of dabigatran was 0.72% and 0.74%, respectively.³ These findings were probably because warfarin provides better protection against coronary ischemic events than dabigatran.³⁸ In the literature that we reviewed, such adverse events were not reported in any patient. Nevertheless, clinicians should continue to consider the possibility of these severe, harmful cardiovascular effects after dabigatran administration.

Allergic reactions

Five patients developed allergic reactions after taking dabigatran.^{23–27} In addition, one patient developed drug-induced lupus (DIL).²³ Stöllberger and colleagues suggested that a small lipophilic molecule with a molecular weight of 472 Da may play a part in immune side-effects after dabigatran administration.²³ Furthermore, DIL is characterized by high levels of antinuclear antibodies and antihistone antibodies, with no evidence of complement consumption, and circulating immune complexes within the normal range. The RE-LY trial reported that fewer than 0.1% of patients receiving dabigatran reported drug allergies, allergic edema, allergic reactions, or anaphylactic shock.³ Even though allergic edema and allergic reactions are rare, monitoring and reporting allergic reactions in patients taking dabigatran is important.

Age

Among the patients with adverse events that we reviewed (except for a 20-year-old patient with a dabigatran-induced exanthema), the mean age was 76 (range, 52–90) years.^{5–27} Regardless of whether adverse events are associated with age, more clinical trials are needed to ascertain the relationship between age, dose, and adverse effects to better guide management.

Conclusions and recommendations

The oral anticoagulant dabigatran is used widely. Nevertheless, clinicians cannot ignore the adverse events caused by dabigatran. We recommend the management detailed below for the adverse events caused by dabigatran.

- (a) According to the patient's symptoms, signs and laboratory tests, once the diagnosis of gastrointestinal bleeding is clear, depending on the amount of bleeding, if a small amount of bleeding, in addition to observing clinical changes, the clinicians may consider adding H₂ receptor inhibitor (H₂RA), proton pump inhibitors (PPIs) and mucosal protective agent. In severe bleeding, measures include discontinuation of dabigatran immediately and administration of prothrombin complex concentrate, packed red blood cells, and fresh frozen plasma, the use of specific reversal agents such as idarucizumab for dabigatran, and emergency endoscopic management.
- (b) If heartburn, chest pain and upper abdominal pain appear shortly after dabigatran administration, drinking a sufficient volume of water (150 mL or more) and maintaining an upright position for ≥30 mins are useful strategies for relieving symptoms. If necessary, PPIs and H₂RAs can be added. If symptoms persist, dabigatran should be discontinued; apixaban, rivaroxaban and warfarin are alternatives.
- (c) If patients have dysphagia, upper abdominal pain, chest pain, retrosternal pain, vomiting, and odynophagia, and their duration is long, clinicians should be alert to the possibility of dabigatran-induced esophagitis or esophageal injury. Endoscopy should be undertaken as soon as possible. Longitudinal exfoliation of the distal esophagus is a characteristic feature of dabigatran-induced esophagitis.
- (d) If abdominal pain, anorexia, or fatigue is the main clinical manifestations of dabigatran use, hepatic lesions should be considered after excluding esophageal lesions. Monitoring indicators of liver function are particularly important. If hepatic lesions are present, dabigatran should be stopped and drugs that can protect liver function, such as bicyclol, glutathione, and magnesium isoglycyrrhizinate, should be administered.
- (e) Impairment of renal function (including acute interstitial nephritis and hyperkalemia) should be noted,

especially hyperkalemia. Discontinuation of dabigatran and laboratory tests is recommended. Hemofiltration and glucocorticoid therapy are feasible if indicated.

- (f) As an anticoagulant, dabigatran, may increase the risk of myocardial infarction or acute coronary syndrome. Clinicians should consider the possibility of these severe, harmful cardiovascular effects following use of dabigatran.
- (g) Allergic reactions such as rash are not very common and can be treated with antihistamines, and discontinue dabigatran if necessary. DIL due to dabigatran is extremely rare but, if it occurs, dabigatran should be discontinued as soon as possible and autoantibody profiles are helpful for the diagnosis.

Acknowledgments

Shan Lin's deepest gratitude goes first and foremost to Professor Wei Guan, Shan Lin's supervisor, for her constant encouragement and guidance. She guided Shan Lin along with all those who helped during the writing of this thesis. Without her consistent and illuminating instruction, this thesis could not have reached its present form. This review was funded by QingHai Department of Science and Technology, the Grant Number: 2017-wjzd-11.

Disclosure

All authors claim no conflicts of interest in this work.

References

1. Kannel WB, Wolf PA, Benjamin EJ, Levy D. Prevalence, incidence, prognosis, and predisposing conditions for atrial fibrillation: population-based estimates. *Am J Cardiol.* 1998;82(7):2N–9N.
2. Brass L, Krumholz L, Scinto J, et al. War farin use following ischemic stroke among medicare patients with atrial fibrillation. *Arch Intern Med.* 1998;158:2093–2100.
3. Connolly SJ, Ezekowitz MD, Yusuf S, et al. Dabigatran versus warfarin in patients with atrial fibrillation. *N Engl J Med.* 2009;361(12):1139–1151. doi:10.1056/NEJMoa0905561
4. Gómez-Outes A, Terleira-Fernández AI, Calvo-Rojas G, et al. Dabigatran, rivaroxaban, or apixaban versus warfarin in patients with nonvalvular atrial fibrillation: a systematic review and meta-analysis of subgroups. *Semin Thromb Hemost.* 2018.
5. Jelani Q, Gordon R, Schussheim A. Dabigatran-induced spontaneous hemopericardium and cardiac tamponade. *Tex Heart Inst J.* 2017;44(5):370–372. doi:10.14503/THIJ-16-6073
6. Huang J, Lin W, Lv D, et al. Dabigatran-induced massive spontaneous hemothorax. *Drug Saf Case Rep.* 2017;4(1):12. doi:10.1007/s40800-017-0056-x
7. Otteno H, Smith E, Huffaker RK. Dabigatran induced hemorrhagic cystitis in a patient with painful bladder syndrome. *Case Rep Urol.* 2014;2014.

8. Carter A, Sarda P, George M, et al. Hip arthroplasty fatality related to dabigatran induced gastrointestinal haemorrhage. *Ann R Coll Surg Engl*. 2014;96(1):e01–e03. doi:10.1308/003588414X13824511649779
9. Dumkow LE, Voss JR, Peters M, Jennings DL. Reversal of dabigatran-induced bleeding with a prothrombin complex concentrate and fresh frozen plasma. *Am J Health Syst Pharm*. 2012;69(19):1646–1650. doi:10.2146/ajhp120055
10. Wychowski MK, Kouides PA. Dabigatran-induced gastrointestinal bleeding in an elderly patient with moderate renal impairment. *Ann Pharmacother*. 2012;46(4):e10. doi:10.1345/aph.1Q747
11. Cano EL, Miyares MA. Clinical challenges in a patient with dabigatran-induced fatal hemorrhage. *Am J Geriatr Pharmacother*. 2012;10(2):160–163. doi:10.1016/j.amjopharm.2012.02.004
12. Matsuura H, Suto K, Yasuhara H, et al. Longitudinal sloughing mucosal casts: dabigatran-induced oesophagitis. *Eur Heart J*. 2018;39(36):3400. doi:10.1093/eurheartj/ehw180
13. Fujikawa K, Takasugi N, Goto T, et al. Very late-onset dabigatran-induced esophageal injury. *Can J Cardiol*. 2017;33(4):554.e15–554.e16. doi:10.1016/j.cjca.2016.12.017
14. Yoshimitsu M, Sawada T, Kobayashi T, Yamagishi M. Dabigatran-induced exfoliative esophagitis. *Intern Med*. 2016;55(13):1815. doi:10.2169/internalmedicine.55.6606
15. Shibagaki K, Taniguchi H, Goto D, Kobayashi K, Kinoshita Y. Dabigatran-induced asymptomatic esophageal mucosal injury. *Gastrointest Endosc*. 2016;83(2):472–474. doi:10.1016/j.gie.2015.08.028
16. Izumikawa K, Inaba T, Mizukawa S, et al. Two cases of dabigatran-induced esophageal ulcer indicating the usefulness of drug administration guidance. *Nihon Shokakibyō Gakkai zasshi*. 2014;111(6):1096–1104.
17. Zimmer V, Casper M, Lammert F. Extensive dabigatran-induced exfoliative esophagitis harboring squamous cell carcinoma. *Endoscopy*. 2014;46(S 01):E273–E274. doi:10.1055/s-0034-1365782
18. Ootani A, Hayashi Y, Miyagi Y. Dabigatran-induced esophagitis. *Clin Gastroenterol Hepatol*. 2014;12(7):e55. doi:10.1016/j.cgh.2013.09.010
19. Singh S, Savage L, Klein M, et al. Case report: severe necrotic oesophageal and gastric ulceration associated with dabigatran. *BMJ Case Rep*. 2013;2013.
20. Patel S, Hossain MA, Ajam F, et al. Dabigatran-induced acute interstitial nephritis: an important complication of newer oral anticoagulation agents. *J Clin Med Res*. 2018;10(10):791. doi:10.14740/jocmr3569w
21. Rochweg B, Xenodemetropoulos T, Crowther M, Spyropoulos A. Dabigatran-induced acute hepatitis. *Clin Appl Thromb Hemost*. 2012. doi:10.1177/1076029611435840
22. Zaleski M, Dabage N, Paixao R, Muniz J. Dabigatran-induced hyperkalemia in a renal transplant recipient: a clinical observation. *J Clin Pharmacol*. 2013;53(4):456–458. doi:10.1002/jcph.21
23. Stöllberger C, Krutisch G, Finsterer J, Wolf HM. Dabigatran-induced lupus temporarily preventing blood group determination. *Blood Coagul Fibrinolysis*. 2014;25(6):625–627. doi:10.1097/MBC.0000000000000099
24. Mancano MA. ISMP adverse drug reactions: influenza vaccine-induced Stevens-Johnson Syndrome; vilazodone-induced nightmares; dabigatran-induced pustular eruptions; neurotoxic and cardiotoxic symptoms after cannabis concentrate exposure; rosuvastatin-induced skin eruption. *Hosp Pharm*. 2018;53(1):15–17. doi:10.1177/0018578717739727
25. Eid TJ, Shah SA. Dabigatran-induced rash. *Am J Health Syst Pharm*. 2011;68(16):1489–1490. doi:10.2146/ajhp110088
26. Vega-Molpeceres S, Just SM, Escoda GM. Dabigatran induced exanthema. *Rev Clin Esp*. 2010;210(11):590.
27. Whitehead H, Boyd JM, Blais DM, et al. Drug-induced exanthem following dabigatran. *Ann Pharmacother*. 2011;45(10):e53. doi:10.1345/aph.1P572
28. Blommel ML, Blommel AL. Dabigatran etexilate: a novel oral direct thrombin inhibitor. *Am J Health Syst Pharm*. 2011;68(16):1506–1519. doi:10.2146/ajhp100348
29. Schulman S, Kearon C, Kakkar AK, et al. Dabigatran versus warfarin in the treatment of acute venous thromboembolism. *N Engl J Med*. 2009;361(24):2342–2352. doi:10.1056/NEJMoa0906598
30. Lanás-Gimeno A, Lanás A. Risk of gastrointestinal bleeding during anticoagulant treatment. *Expert Opin Drug Saf*. 2017;16(6):673–685. doi:10.1080/14740338.2017.1325870
31. Pellicano R, Ribaldone DG, Fagoonee S, et al. A 2016 panorama of *Helicobacter pylori* infection: key messages for clinicians. *Panminerva med*. 2016;58(4):304–317.
32. Friedman AC, Oyewole MA. Pill-induced esophageal injury. Case reports and review of the medical literature. *Dig Dis Sci*. 1983;28:174–182.
33. Toya Y, Nakamura S, Tomita K, et al. Dabigatran-induced esophagitis: the prevalence and endoscopic characteristics. *J Gastroenterol Hepatol*. 2016;31(3):610–614. doi:10.1111/jgh.13024
34. Bytzer P, Connolly SJ, Yang S, et al. Analysis of upper gastrointestinal adverse events among patients given dabigatran in the RE-LY trial. *Clin Gastroenterol Hepatol*. 2013;11(3):246–52. e5. doi:10.1016/j.cgh.2012.10.021
35. Eriksson B, Dahl O, Buller R, et al. A new oral direct thrombin inhibitor, dabigatran etexilate, compared with enoxaparin for prevention of thromboembolic events following total hip or knee replacement: the BISTRO II randomized trial. *J Throm Haem*. 2004;3(1):103–111. doi:10.1111/j.1538-7836.2004.01100.x
36. Stangier J. Clinical pharmacokinetics and pharmacodynamics of the oral direct thrombin inhibitor dabigatran etexilate. *Clin Pharmacokinet*. 2008;47:285–295. doi:10.2165/00003088-200847050-00001
37. Uchino K, Hernandez AV. Dabigatran association with higher risk of acute coronary events: meta-analysis of noninferiority randomized controlled trials. *Arch Intern Med*. 2012;172(5):397–402. doi:10.1001/archinternmed.2011.1666
38. Hurlen M, Abdelnoor M, Smith P, Erikssen J, Arnesen H. Warfarin, aspirin, or both after myocardial infarction. *N Engl J Med*. 2002;347(13):969–974. doi:10.1056/NEJMoa020496

Drug Design, Development and Therapy

Publish your work in this journal

Drug Design, Development and Therapy is an international, peer-reviewed open-access journal that spans the spectrum of drug design and development through to clinical applications. Clinical outcomes, patient safety, and programs for the development and effective, safe, and sustained use of medicines are a feature of the journal, which has also

been accepted for indexing on PubMed Central. The manuscript management system is completely online and includes a very quick and fair peer-review system, which is all easy to use. Visit <http://www.dovepress.com/testimonials.php> to read real quotes from published authors.

Submit your manuscript here: <https://www.dovepress.com/drug-design-development-and-therapy-journal>

Dovepress