

Andrology and fertility

Is there a role for varicocelelectomy after microdissection testicular sperm extraction? Case report and literature review

Mohannad Alharbi^{a,b}, Armand Zini^{a,*}^a Division of Urology, Department of Surgery, McGill University, Montreal, Quebec, Canada^b Department of Urology, College of Medicine, Qassim University, Qassim, Saudi Arabia

ARTICLE INFO

Keywords:

Varicocele

Non-obstructive azoospermia

MicroTESE

ABSTRACT

Men with non-obstructive azoospermia (NOA) are candidates for microdissection testicular sperm extraction (microTESE). In men with NOA and varicocele, varicocelelectomy has been associated with the appearance of sperm in the ejaculate. We report an infertile male with NOA, a solitary left testicle and a left clinical varicocele. The patient first underwent an extensive left microTESE. No spermatozoa were seen on initial microscopic evaluation but after an extensive search, spermatozoa were identified. ICSI did not result in pregnancy. Fifteen months after the microTESE, the patient underwent a left microsurgical varicocelelectomy. A semen analysis post-varicocelelectomy revealed the presence of sperm.

Introduction

It is estimated that 10–20% of infertile men present with azoospermia, obstructive and non-obstructive.¹

One of the treatment options for men with NOA is microdissection testicular sperm extraction (microTESE) coupled with ICSI (intracytoplasmic sperm injection). The reported success rate or sperm retrieval rate (SRR) of this procedure is in the range of 50%–60%.² An alternative option in men with NOA and varicocele is varicocelelectomy. It has been reported that in men with varicocele and NOA, varicocelelectomy results in appearance of sperm in the ejaculate in 22–55% of patients, with up to 10% of men having enough sperm to avoid TESE or microTESE.²

To our knowledge, there is no report on the role of varicocelelectomy after microTESE. The purpose of this case report is to discuss the value of varicocelelectomy after microTESE.

Case report

We report on the case of 30-year-old male with a 6-month history of primary infertility. His past history was significant for a right orchiectomy at age 14 for testicular torsion. Physical examination revealed an absent right testicle. The left testicle had an estimated volume of 18 ml with a slightly soft consistency, the vas deferens was palpable and a clinical grade 2 varicocele was palpable.

The patient had submitted two semen samples (3 months apart) as part of the evaluation, and both demonstrated normal volume azoospermia. The hormonal profile showed a serum follicle stimulating hormone (FSH) at 23 IU/ml, luteinizing hormone (LH) at 8 IU/ml, and a total testosterone at 13 nmol/L. Genetic testing was normal.

After a discussion regarding the possible treatment options (varicocele repair vs. microTESE), the patient elected to undergo a microTESE coupled with ICSI. The patient took daily clomiphene citrate (50 mg PO QD) in the 2 months preceding the microTESE. An extensive left microTESE was performed with a total of 27 micro-biopsies harvested from the left testis (with all areas of the testis parenchyma explored). No spermatozoa were identified by the embryologists on initial evaluation of the micro-biopsies (during the 2-h long procedure). However, after an extensive search of the biopsy specimens (3–4 hours search and shortly after completion of the microTESE), 18 spermatozoa were visualised. The cytologic assessment of the cell suspension from the micro-biopsies revealed a pattern consistent with late maturation arrest (maturation to round spermatid stage). In the end, a sufficient number of spermatozoa was found to perform intracytoplasmic sperm injection (ICSI) resulting in the development of 4 embryos. Two embryo transfers (1 fresh and 1 frozen, with 2 embryos each) were performed but, with no ensuing clinical pregnancy.

At a follow-up evaluation 10 months after the microTESE, the patient returned to clinic to inquire about possible treatment options (varicocele repair vs. repeat microTESE). He had not received any medical or

* Corresponding author. St. Mary's Hospital, 3830 Lacombe Ave., Montreal, Québec, H3T 1M5, Canada.

E-mail address: ziniarmand@yahoo.com (A. Zini).

<https://doi.org/10.1016/j.eucr.2019.100994>

Received 9 June 2019; Received in revised form 3 August 2019; Accepted 9 August 2019

Available online 10 August 2019

2214-4420/© 2019 The Authors.

Published by Elsevier Inc.

This is an open access article under the CC BY-NC-ND license

(<http://creativecommons.org/licenses/by-nc-nd/4.0/>).

surgical therapy since his microTESE. The patient elected to undergo a microsurgical varicocelectomy understanding the uncertain effect of this surgery after a prior extensive microTESE. A left sub-inguinal microsurgical varicocelectomy (see Fig. 1) was performed 15 months after the initial microTESE. A semen analysis at 6 months post-microsurgical varicocelectomy (21 months post-microTESE) revealed the appearance of sperm in ejaculate: volume: 3 ml, 0.8 millions/ml with 26% progressive motility (see Table 1).

Discussion

In this report, the finding of abnormal spermatogenesis at microTESE enabled us to establish the diagnosis of NOA. The extensive microdissection revealed very rare foci of active spermatogenesis (with mature sperm) with a predominant pattern consistent with late maturation arrest (to the round spermatid level).

The preferred approach for the management of men with NOA is to perform a testicular sperm extraction or microTESE.³ The role of varicocelectomy in the setting of azoospermia was first described by Tulloch in 1952.⁴ He performed varicocelectomy in a patient with bilateral varicocele and NOA and the patient had a return of sperm in the ejaculate and a pregnancy occurred after the surgery. Since, several reports have been published on varicocelectomy and its effect on sperm return in the ejaculate in patients with NOA.

The present case is unique in that it describes the role of varicocelectomy after microTESE in a man with NOA and clinical varicocele. To our knowledge, this sequence of surgical procedures (varicocele repair after microTESE) has not been reported previously. Based on the successful sperm retrieval and cytologic findings (late maturation arrest) at microTESE, we believed that this patient would be a good candidate for subsequent varicocelectomy, and this option was offered to him. However, we recognized that any degree of testicular scarring caused by the microTESE might potentially reduce his chances of having sperm return in the ejaculate after varicocelectomy. The fact that this patient has a solitary testicle strengthens our findings in that it excludes the possibility of a contralateral testis contribution in the post-varicocelectomy semen analysis.

Although the observations from this case report support the premise that varicocelectomy led to the appearance of sperm in the ejaculate, the nature of the study does not allow us to conclude firmly on the role of varicocelectomy after microTESE. It is certainly possible that the appearance of sperm in the ejaculate was unrelated to the varicocelectomy. However, this latter possibility is unlikely given our intra-operative findings at microTESE (the very limited identification of foci of active spermatogenesis) and the likely diminution in sperm production after an extensive microTESE. Moreover, to our knowledge, there are no studies demonstrating the appearance of motile sperm in the ejaculate after an extensive microTESE.

This case report demonstrates that varicocele repair was associated with the appearance of sperm in the ejaculate in a man with NOA and a prior history of microTESE. Our report suggests that varicocelectomy after a successful microTESE is a potentially beneficial treatment approach. Further studies are needed to validate these findings. In this patient with a solitary testicle, we should have performed the varicocelectomy prior to microTESE. But, the patient elected to have microTESE first then later accepted to undergo varicocelectomy. The sequence of surgical interventions was based on the discussion with the patient and respecting his preference but was not our recommendation.

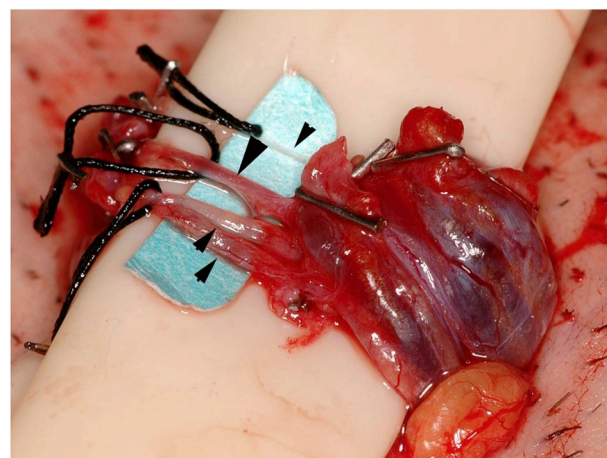


Fig. 1. Photomicrograph of spermatic cord after microsurgical varicocelectomy demonstrating complete ligation of veins and preservation of internal spermatic artery (large arrow) and lymphatics (small arrows).

Table 1

Changes of semen analysis pre and post microTESE and varicocelectomy.

	Pre microTESE	21 months post microTESE ^a	23 months post microTESE ^b	24 months post microTESE ^c
Semen volume (ml)	2.7	3	3.4	2
Concentration (million/ml)	0	0.8	0.3	0.1
Progressive motility (%)	NA	26	50	70

NA: not applicable.

^a 6 months post-microsurgical varicocelectomy.

^b 8 months post-microsurgical varicocelectomy.

^c 9 months post-microsurgical varicocelectomy.

Conflicts of interest

No conflict of interest.

Funding source

None.

Acknowledgement

none.

References

1. Jarow JP, Espeland MA, Lipshultz LI. Evaluation of the azoospermic patient. *J Urol*. 1989;142(1):62–65.
2. Wosnitzer M, Goldstein M, Hardy MP. Review of azoospermia. *Spermatogenesis*. March 2014;4(1), e28218.
3. Jarvi K, Lo K, Grober E, et al. CUA Guideline: the workup and management of azoospermic males cua guideline. *Can Urol Assoc J*. August 2015;9(7-8).
4. Tulloch WS. A consideration of sterility factors in light of subsequent pregnancies. *Edinb Med J*. 1952;59:29–34.