

Conference Case

Intradural extramedullary relapse of peripheral T-cell lymphoma, NOS

Keywords: Intradural extramedullary relapse; peripheral T cell lymphoma; romidepsin

CASE REPORT

A 73-year-old Japanese man was referred to our clinic with general malaise. He had a history of diabetes mellitus and hypertension of longer than 10 years. He presented with lymphadenopathy and liver dysfunction. Laboratory examination demonstrated a WBC count of $23.6 \times 10^9/L$ with 10% abnormal lymphocytes having basophilic irregular nuclei, aspartate aminotransferase of 124 U/L (normal range: 5–40 U/L), alanine transaminase of 166 U/L (5–35 U/L), total bilirubin of 4.1 mg/dL (1.0–0.3 mg/dL), creatinine of 1.46 mg/dL (0.6–1.1 mg/dL) and soluble interleukin-2 receptor (sIL-2R) of 15,889 U/mL (122–496 U/mL). Serological tests for HBV, HCV and HTLV-1 were all negative. The physical examination revealed bilateral cervical lymph node swelling, multiple abdominal skin pigmentation and peripheral edema. On computed tomography (CT) of the trunk, generalized multiple lymphadenopathy with mild splenomegaly was noted. Biopsy specimens of cervical lymph nodes and abdominal skin exhibited monotonous infiltration of medium to large-sized lymphocytes with a phenotype of CD3+, CD5+, CD10–, CD20–, CD79a–, CD30–, CD56–, Bcl6–, granzyme B–, CD45RO–, CCR4+ and TdT–. (Figure 1A-E) The Ki-67 labeling index was 80%. EBER *in situ* hybridization was negative. Lymphoma cells were also detected in the bone marrow. The prognostic index score for T-cell lymphoma in this case was 4, considered to be high risk.¹ The final diagnosis was PTCL, NOS, stage IVB. We treated the patient using modified CHOP therapy. After one cycle of chemotherapy, the swelled lymph node shrunk and partial response was achieved. However, on day 13 after the modified CHOP therapy, his general condition deteriorated and the WBC increased to $9.6 \times 10^9/L$ with 36% lymphoma cells. The disease progressed and we decided to use the histone deacetylase (HDAC) inhibitor romidepsin (14 mg/m² 1×/week for 3 weeks) as second-line therapy. After the first administration of romidepsin, the patient recovered rapidly. His sIL-2R levels decreased to 1,428 U/mL. When the WBC count recovered to $7.6 \times 10^9/L$ 17 days later, 8% lymphoma cells persisted in the peripheral blood and one cycle of the monoclonal antibody mogamulizumab (1 mg/kg for every 4 weeks) was added. He received a second cycle of romidepsin, and the disappearance of lymphoma cells from the peripheral blood and all lymph node swelling was confirmed. On day 7 after the second cycle of romidepsin, the

patient suddenly complained of severe lumbago with bilateral weakness of the lower limbs. Initial MRI of the entire spine detected no abnormalities. CT demonstrated complete remission of the lymphadenopathy. His sIL-2R value was stable at 1,423 U/mL. We consulted neurologists regarding paraparesis. As they suspected drug-induced neuropathy, we decided to stop the romidepsin treatment. However, muscle weakness progressed and he became fully paralyzed on day 21. Repeated MRI of the head and cervical spine revealed no lesion. Lumbar punctures were unsuccessful. On day 25, an intradural extramedullary mass was detected on thoracolumbar MRI, suggesting infiltrated lymphoma (Figure 2). His performance status deteriorated due to neurological deficit and palliative spinal cord irradiation did not improve. The patient died due to PTCL at 3 months after the initial diagnosis.

PTCL is an aggressive lymphoma with a poor prognosis and the incidence of CNS relapse was reported to be approximately 2%–4% or 8%.^{2–8} Leptomeningeal-type relapse with systemic relapse was observed in the majority of patients,^{5,6} but parenchymal disease with isolated CNS relapse has also been reported in some patients who achieved a complete response after initial treatment.⁶ CNS relapse in PTCL is difficult to predict.^{9,10} Current evidence suggests that when PTCL expresses CD56, which is a known neural cell adhesion molecule, the incidence can increase to 24%.¹¹ Increased serum lactate dehydrogenase (LDH) and involvement of the paranasal sinus are also risk factors for CNS relapse.⁶ Our patient's lymphoma cells did not express CD56, but he had increased LDH levels. Several points should be noted in our case. First, CNS relapse was identified when the lymph node lesions and peripheral lymphoma were under control by prior treatment. Second, CNS relapse developed within a short period (<2 months) after the initial diagnosis. Third, repeated MRI examinations were necessary to detect the tumor mass. Fourth, lymphoma cells in the peripheral blood (leukemic situation) at the diagnosis may underlie CNS relapse. Romidepsin was initially suspected as the cause of paraparesis due to drug-induced neuropathy, although this type of neuropathy is rare (<5%–10% of cases). A previous report described the effectiveness of romidepsin against CNS relapse in PTCL;¹² however, romidepsin was not beneficial in this case.

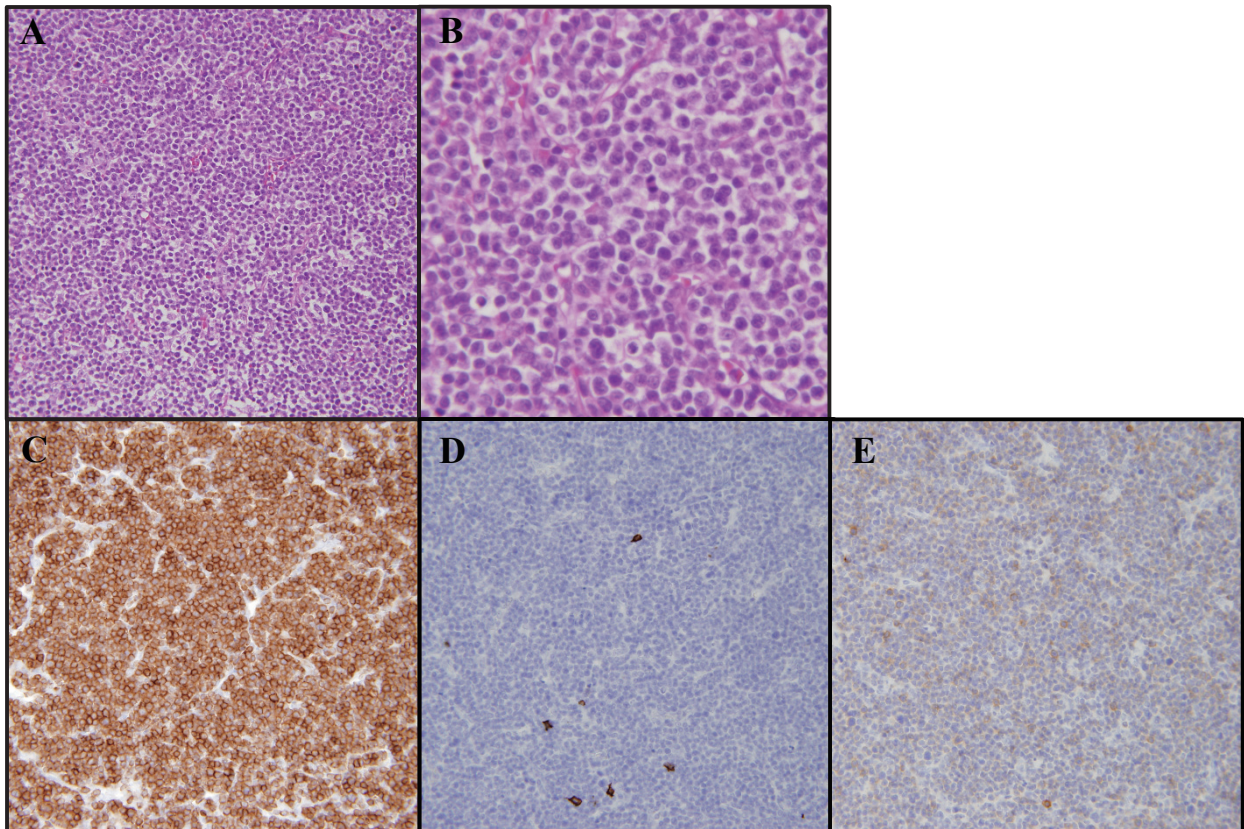


Fig. 1. Histopathology of the biopsy specimen of the right cervical lymph node. Monotonous infiltration of medium to large-sized lymphoma cells is observed (*A*, low-power field; *B*, high-power field. Hematoxylin-eosin staining). Immunohistochemistry shows that the lymphoma cells are CD3-positive (*C*), CD20-negative (*D*) and CCR4-positive (*E*).

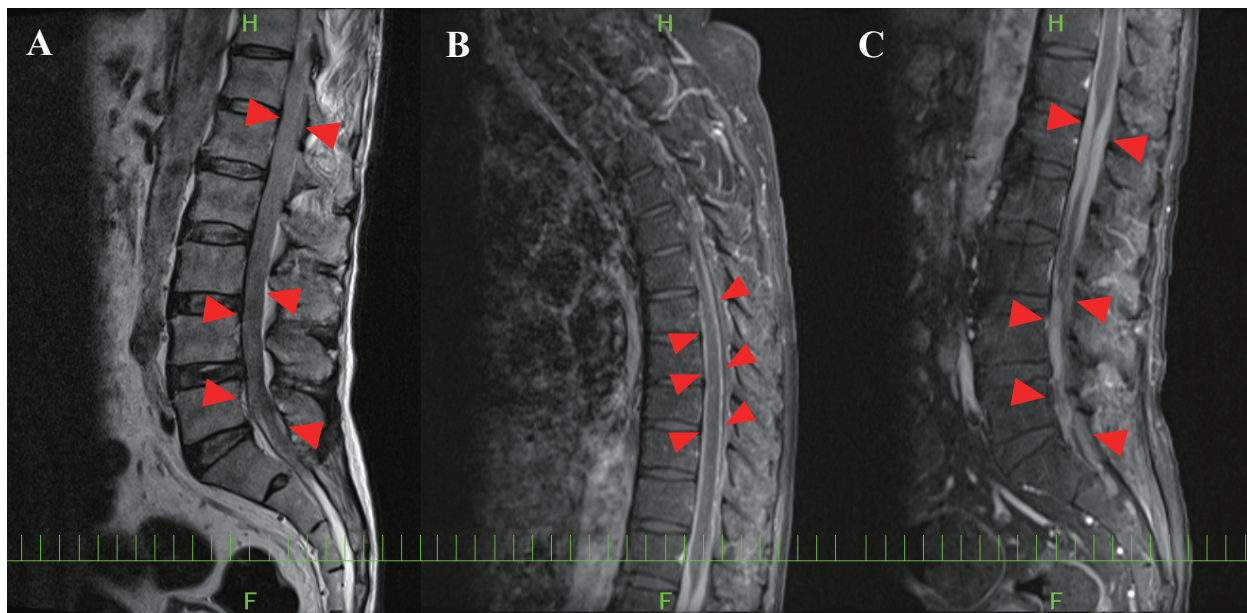

Fig. 2. Thoracolumbar MR images: T2-weighted image (*A*) and contrast-enhanced sagittal fat-saturated T1-weighted images (*B*, *C*). On the T2-weighted image, the CSF signal surrounding the conus medullaris is effaced. *Red triangles*: The leptomeningeal linear or nodular enhancement, corresponding to the intramedullary mass.

CONFLICT OF INTEREST

All procedures performed in this study involving the patient were in accordance with the ethical standards of our institutional and national research committee, and with the 1964 Helsinki declaration and its later amendments or comparable ethical standards. Informed consent was received from the patient. The authors declare no conflicts of interest in this study.

REFERENCES

- 1 Gallamini A, Stelitano C, Calvi R, *et al.*; Intergruppo Italiano Linfomi. Peripheral T-cell lymphoma unspecified (PTCL-U): a new prognostic model from a retrospective multicentric clinical study. *Blood*. 2004; 103 : 2474-2479.
- 2 Arber DA, Orazi A, Hasserjian R, *et al.* The 2016 revision to the World Health Organization classification of myeloid neoplasms and acute leukemia. *Blood*. 2016; 127 : 2391-2405.
- 3 Ellin F, Landström J, Jerkeman M, Relander T. Real-world data on prognostic factors and treatment in peripheral T-cell lymphomas: a study from the Swedish Lymphoma Registry. *Blood*. 2014; 124 : 1570-1577.
- 4 Weisenburger DD, Savage KJ, Harris NL, *et al.*; International Peripheral T-cell Lymphoma Project. Peripheral T-cell lymphoma, not otherwise specified: a report of 340 cases from the International Peripheral T-cell Lymphoma Project. *Blood*. 2011; 117 : 3402-3408.
- 5 Pro B, Perini G. Central nervous system prophylaxis in peripheral T-cell lymphoma. *Blood*. 2010; 115 : 5427.
- 6 Yi JH, Kim JH, Baek KK, *et al.* Elevated LDH and paranasal sinus involvement are risk factors for central nervous system involvement in patients with peripheral T-cell lymphoma. *Ann Oncol*. 2011; 22 : 1636-1643.
- 7 Ellin F, Landström J, Jerkeman M, Relander T. Central nervous system relapse in peripheral T-cell lymphomas: a Swedish Lymphoma Registry study. *Blood*. 2015; 126 : 36-41.
- 8 Chihara D, Fanale MA, Miranda RN, *et al.* The risk of central nervous system relapses in patients with peripheral T-cell lymphoma. *PLoS One*. 2018; 13 : e0191461.
- 9 Schmitz N, Zeynalova S, Nickelsen M, *et al.* CNS International Prognostic Index: A Risk Model for CNS Relapse in Patients With Diffuse Large B-Cell Lymphoma Treated With R-CHOP. *J Clin Oncol*. 2016; 34 : 3150-3156.
- 10 Kridel R, Dietrich PY. Prevention of CNS relapse in diffuse large B-cell lymphoma. *Lancet Oncol*. 2011; 12 : 1258-1266.
- 11 Kern WF, Spier CM, Hanneman EH, *et al.* Neural cell adhesion molecule-positive peripheral T-cell lymphoma: a rare variant with a propensity for unusual sites of involvement. *Blood*. 1992; 79 : 2432-2437.
- 12 Chan KL, van der Weyden C, Khoo C, *et al.* Durable clinical remission induced by romidepsin for chemotherapy-refractory peripheral T-cell lymphoma with central nervous system involvement. *Leuk Lymphoma*. 2017; 58 : 996-998.

Yutaka Shimazu,¹⁾ Akihiko Sakata²⁾ and Masaharu Nohgawa¹⁾

¹⁾Department of Hematology, Japanese Red Cross Wakayama Medical Center, Wakayama, Japan, ²⁾Department of Radiology, Japanese Red Cross Wakayama Medical Center, Wakayama, Japan

Corresponding author: Yutaka Shimazu, M.D., Department of Hematology, Japanese Red Cross Wakayama Medical Center, 4-20, Komatsubara-dori, Wakayama 640-8558, Japan.

E-mail: yshimazu@kuhp.kyoto-u.ac.jp

Received: July 2, 2019.


Revised: October 27, 2019.

Accepted: November 27, 2019.

Online Published: June 20, 2020

DOI:10.3960/jslr.19024

Copyright © 2020 The Japanese Society for Lymphoreticular Tissue Research

 This work is licensed under a Creative Commons Attribution-NonCommercial-ShareAlike 4.0 International License.