

# Risk factors for external root resorption of maxillary second molars associated with third molars

Jinwoo Choi <sup>1,\*</sup>

<sup>1</sup>Department of Oral and Maxillofacial Radiology, Dankook University College of Dentistry, Cheonan, Korea

## ABSTRACT

**Purpose:** This study aimed to evaluate the diagnostic performance of panoramic images compared to cone-beam computed tomography (CBCT) imaging for maxillary third molar (M3)-associated external root resorption (ERR), and to identify the risk factors of ERR on panoramic images.

**Materials and Methods:** The study population was composed of all patients who underwent panoramic imaging at Dankook University Dental Hospital from May to October 2019. In total, 397 cases of maxillary M3s in 247 patients (147 men and 100 women) were included. The diagnostic accuracy of ERR in panoramic images compared to CBCT images was evaluated using the chi-square test. To identify risk factors for ERR, dental records and panoramic findings were evaluated by logistic regression analysis.

**Results:** The diagnostic accuracy of ERR on panoramic images was 0.79 compared to CBCT images ( $P < 0.05$ ). Superimposition of M3s onto second molars (M2) was associated with an approximately 33 times higher risk of ERR than separated M3s ( $P < 0.05$ ). Impacted M3s showed a 5 times higher risk of ERR than erupted M3s ( $P < 0.05$ ).

**Conclusion:** ERR related to M3s is a common clinical condition, and superimposition of M3 onto M2 on panoramic images was the most important risk factor for ERR. It seemed that CBCT examinations for maxillary M3s might be indicated for ERR diagnosis especially if panoramic radiographs show superimposition of M3 onto M2. Impaction itself was also a risk factor, and it should be carefully examined. (*Imaging Sci Dent* 2022; 52: 289-94)

**KEY WORDS:** Root Resorption; Maxilla; Molar, Third; Radiography, Panoramic; Cone-Beam Computed Tomography

## Introduction

Third molars (M3s) are located at the end of the dentition on both the maxilla and mandible; they are the most frequently impacted teeth, and can be associated with diseases such as pericoronitis, caries, cysts, tumors, and root resorption of the second molar (M2).<sup>1</sup> Ventä et al.<sup>2</sup> studied 5665 M3s in the adult Finnish population and found that 3996 of the 5665 teeth (71%) had at least 1 sign of these diseases, of which dental caries was the most common, with a prevalence of 68% in erupted M3s.

Among the diseases associated with impacted M3s,

external root resorption (ERR) of M2 is quite common (14.3% to 52.9%).<sup>3-5</sup> ERR is a pathological process that occurs on the outer surface of the permanent tooth. ERR due to M3 significantly undermines the normal functionality and health of the adjacent M2, and might necessitate effective treatment of the affected teeth through methods such as root canal therapy, root resection, or tooth extraction, if not properly managed. ERR generally progresses asymptotically, and it is difficult to diagnose ERR until periapical inflammation or pulpitis occurs.<sup>6</sup> In severe cases of ERR of M2, removal of M2 might be considered instead of M3.<sup>7</sup> Early detection of ERR is essential to preserve M2, and radiographs are required for the diagnosis.

Panoramic imaging has been the first choice for M3 examinations, but panoramic and periapical images were found to be insufficient to predict ERR properly compared to cone-beam computed tomography (CBCT) imaging.<sup>5,8</sup> A recent study showed that 58.6% (65/111) of treatment plans based

Received April 1, 2022; Revised April 22, 2022; Accepted May 2, 2022

Published online May 13, 2022

\*Correspondence to : Prof. Jinwoo Choi

Department of Oral and Maxillofacial Radiology, Dankook University College of Dentistry, 119 Dandae-ro, Dongnam-gu, Cheonan-si, Chungcheongnam-do 31116, Korea

Tel) 82-41-550-1698, E-mail) runnachv@dankook.ac.kr

Copyright © 2022 by Korean Academy of Oral and Maxillofacial Radiology

This is an Open Access article distributed under the terms of the Creative Commons Attribution Non-Commercial License (<http://creativecommons.org/licenses/by-nc/3.0>) which permits unrestricted non-commercial use, distribution, and reproduction in any medium, provided the original work is properly cited.

Imaging Science in Dentistry · pISSN 2233-7822 eISSN 2233-7830

on panoramic images were changed after obtaining a CBCT scan, and 10.8% (12/111) of patients underwent removal of M2 instead of M3.<sup>7</sup> Oenning et al.<sup>9</sup> also reported that the prevalence of ERR in M2s was 5.31%, as detected by panoramic images, whereas it was 22.88% by CBCT in the same patient cohort.

CBCT has various advantages, including its ability to offer cross-sectional and three-dimensional views with high spatial resolution. Due to its higher radiation dose and costs for the patient, CBCT should not be used routinely; however, current guidelines do not yet give specific indications of CBCT for maxillary M3.<sup>10,11</sup> The European commission guideline<sup>10</sup> states that CBCT may be indicated when conventional radiographs suggest a direct inter-relationship between a mandibular M3 and the mandibular canal, and when a decision to perform surgical removal has been made. This guideline only addresses mandibular canals, and this recommendation is therefore not applicable to suspected ERR or impacted maxillary M3. The guideline published by the Swiss Association of Dentomaxillofacial Radiology (SADMFR)<sup>11</sup> states that when information about pathological changes or relevant to surgical removal is needed that cannot be obtained from standard radiographs, CBCT may be indicated. The SADMFR guideline is applicable to ERR and maxillary M3s, but it does not provide detailed descriptions. Furthermore, previous studies regarding M3s mainly dealt with mandibular M3s, whereas only a few studies have presented information on maxillary M3s.<sup>10</sup>

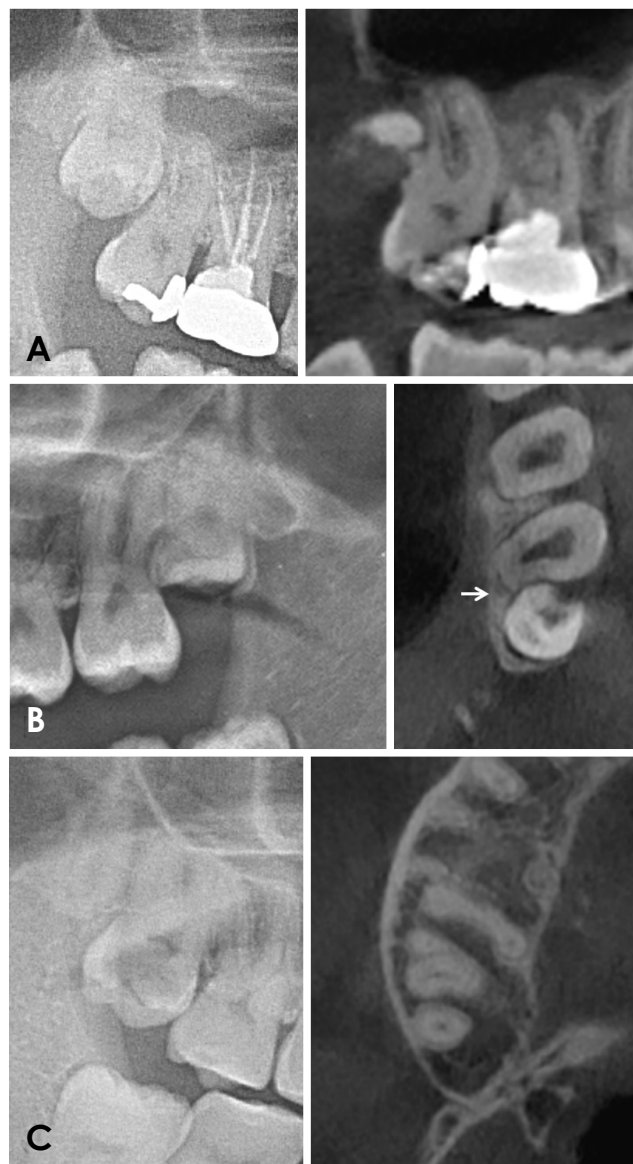
This study aimed to evaluate the diagnostic performance of panoramic images compared to CBCT imaging for ERR and to identify risk factors of ERR on panoramic images, which might need to be supplemented with CBCT images.

### Materials and Methods

The study population was composed of all patients who underwent panoramic imaging at Dankook University Dental Hospital from May to October 2019. The inclusion criteria were as follows: patients aged 25 to 40, with at least 1 maxillary M3. The exclusion criteria were as follows: M3 with cystic or tumorous lesions, M2 with periapical radiolucency, or any artifacts present in the images.

In total, 397 cases of maxillary M3s in 247 patients (147 men and 100 women) were included. Their mean age was 30.9 years (ranging from 25 to 40 years). CBCT images of 145 M3s were obtained for various diagnostic purposes, while 252 M3s were without CBCT images.

Dental records (age, sex, and symptoms) and panoramic



**Fig. 1.** Root resorption images. A. External root resorption of the second molar on panoramic and CBCT images. B. Superimposition of the third molar crown onto the root of the second molar, and a CBCT image showing external root resorption of the disto-cervical area of the second molar (white arrow). C. Superimposition between the roots of the third molar and second molar can also induce external root resorption.

image findings (the side of M3, impaction state, M3 angulation, superimposition of M3 onto M2, and the presence of ERR) were examined by an oral and maxillofacial radiologist (board-certified and with more than 15 years of experience). The patients were classified into 3 age groups (25-30, 31-35, and 36-40). The presence of any symptom (yes/no), side (right/left) and the tooth angulation of M3 (mesio-angulated or not) was recorded. Superimposition of M3 onto M2 (yes/no) was evaluated, and the impaction state (erupted

or impacted) was classified as follows: 1) erupted (cement-enamel junction mesially and distally above the alveolar crest), 2) impacted (cement-enamel junction mesially or distally under the alveolar crest). The presence of ERR (yes/no) in panoramic images was evaluated by the distal surface resorption of M2 roots. In CBCT images, the presence of ERR was also evaluated on sagittal and axial CBCT slices, which were used as a gold standard (Fig. 1). The presence of ERR was defined as a clear loss of substance on the distal surface of the root of M2 due to direct contact between the M2 and the adjacent M3.<sup>12</sup> The radiographs were re-evaluated 3 weeks after the first examination.

Statistical calculations were done using SPSS version 24 (IBM Corp., Armonk, NY, USA). In panoramic images, the prevalence of ERR according to each factor was assessed using the Pearson chi-square test, with statistical significance set at  $P < 0.05$ . The diagnostic accuracy, sensitivity, and specificity of panoramic images for ERR compared to CBCT

images were evaluated using the chi-square test, with statistical significance set at  $P < 0.05$ . To identify risk factors for ERR, dental records and panoramic findings were evaluated using binominal logistic regression analysis ( $P < 0.05$ ).

### Results

The prevalence of ERR in panoramic images was evaluated according to sex, age, and side by the chi-square test. There were no significant differences in the prevalence of ERR by sex (14% in men, 19% in women) or side (17% on the right side, 15% on the left side) (Table 1). The prevalence of ERR was 16% in the 25-30 age group, 16% in the 31-35 age group, and 13% in the 36-40 age group, and this also showed no significant differences (Table 1).

The sensitivity of panoramic images compared to the gold standard (CBCT images) was 0.49 (27/55), their specificity was 0.97 (82/83), and their diagnostic accuracy for ERR was 0.79 (114/145). The panoramic images and CBCT images showed a significant difference in diagnostic performance for the detection of ERR according to the chi-square test ( $P < 0.05$ ) (Table 2). The panoramic images showed a high specificity (0.97) and a quite low sensitivity (0.49). The positive predictive value was 0.90, and the negative predictive value was 0.76.

Based on the binomial logistic regression analysis, superimposition and the state of impaction showed statistically significant impacts on ERR of maxillary M2 (Table 3). Superimposition of M3 onto M2 was associated with an approximately 33 times higher risk for ERR than separated M3s ( $P < 0.05$ ). Impacted M3s showed a 5 times higher risk of ERR than erupted M3s ( $P < 0.05$ ). Patients' sex, age, the presence of symptoms, and mesio-angular impaction were not identified as risk factors for ERR.

**Table 1.** Prevalence of external root resorption on panoramic images according to sex, age group, and location

Factors		External root resorption	Non-external root resorption	<i>P</i> -value*
Sex	Male	35	213	>0.05
	Female	28	121	
Age	25-30	38	187	>0.05
	31-35	13	68	
	36-40	12	79	
Side	Right	33	167	>0.05
	Left	30	167	
Total		63	334	

\*Obtained using the Pearson chi-square test.

**Table 2.** Diagnostic accuracy of panoramic radiographs for the detection of external root resorption (ERR) compared to cone-beam computed tomographic (CBCT) images

	Panoramic image		Total	<i>P</i> -value*
	No-ERR	ERR		
CBCT image	No-ERR	87	90	<0.05
	ERR	28	55	
	Total	115	145	
Sensitivity, specificity, and accuracy	Sensitivity 0.49 (27/55)	Specificity 0.97 (82/83)	Accuracy 0.79 (114/145)	

\*Obtained using the Pearson chi-square test.

**Table 3.** Logistic regression analysis for external root resorption of maxillary M2

Variables	Odds ratio	P-value	95% CI
Sex	1.087	.897	0.307-3.844
Age group	.866	.724	0.389-1.928
Presence of symptoms	2.656	.361	0.326-21.607
Superimposition	33.534	.000	7.772-144.690
Mesial-angulation	.752	.724	0.154-3.660
State of impaction	5.317	.002	1.842-15.349

### Discussion

No appropriate CBCT guidelines for maxillary M3s have been provided, and the risk factors for ERR have not been clearly identified. This study aimed to evaluate the diagnostic performance of panoramic images compared to CBCT imaging for ERR, and to identify risk factors for ERR on panoramic images, which might need to be supplemented with CBCT images.

In this study, the frequency of ERR was 37.9% (55/145) in CBCT images. Previous studies with CBCT exams reported maxillary M2 ERR frequencies of 14.3%,<sup>3</sup> 21%,<sup>4</sup> and 32.6%,<sup>5</sup> and mandibular M2 ERR frequencies of 20.17%,<sup>6</sup> 31%,<sup>3</sup> and 52.9%.<sup>5</sup> ERR was more commonly observed in the mandible than in the maxilla, but the study of Keskin Tunç and Koc<sup>13</sup> reported more ERR in the maxilla than in the mandible. Li et al.<sup>5</sup> studied differences in the characteristics of ERR between the maxilla and mandible. Li et al.<sup>5</sup> reported that ERR in maxillary M2s was overall more severe than that in mandibular M2s, and for maxillary M2s, ERR mostly occurred at the apical third, whereas ERR was most frequently detected in mandibular M2s at the cervical third. Regarding the severity of ERR, another study reported that if external root resorption involved the pulp of M2, there was an almost 17 times higher risk that M2 would be removed instead of M3.<sup>7</sup>

In this study, the diagnostic accuracy of the panoramic images for ERR was 0.79, and the panoramic images showed high specificity (0.97) and a high positive predictive value (0.90). These results show a higher accuracy than the previous value (68.81%) reported by Hermann et al.<sup>8</sup> Due to their two-dimensional nature and possible image distortions, periapical or panoramic images could not adequately detect ERR and showed relatively low diagnostic accuracy.<sup>3,9</sup> For comparison, the older studies regarding ERR in M2s were based on periapical or panoramic images, and reported rates of ERR prevalence ranging from 0.3 to 24.2%.<sup>12,14-16</sup> Furthermore, much more severe ERR in M2 was detected

with CBCT than with panoramic images. Hermann et al.<sup>7</sup> reported that 58.6% (65/111) of treatment plans based on panoramic images were changed after CBCT scans were obtained, and 10.8% (12/111) of patients underwent removal of M2 instead of M3. According to this result (with a negative predictive value of 0.76), panoramic images were not reliable for diagnosing the absence of ERR in M2s.

This study assessed several factors to identify risk factors for ERR detection that could prompt a CBCT examination to be indicated, and was the first to include superimposition of M3 onto M2 as a risk factor in the maxilla. Superimposition was associated with a 33 times higher risk of ERR compared to separated M3s. In mandibular M3s, superimposition of M3 onto the mandibular canal was considered as a risk factor of close contact, and several signs of superimposition such as darkening of the root or loss of the cortical line of the canal on panoramic images were also evaluated.<sup>17-19</sup> This study revealed superimposition to be a major risk factor, underscoring the need for further research on maxillary M3s. Although previous studies did not address superimposition, a few studies revealed that direct contact of M3 with the root surface of M2 is a major risk factor for ERR.<sup>20,21</sup> Further studies can clarify the relationship between superimposition and ERR, which would be helpful for improving CBCT indication guidelines.

The angulation of impaction might affect the frequency of ERR. Keskin Tunç and Koc<sup>13</sup> reported that a mesial inclination was associated with an increased risk for ERR. The prevalence of ERR in M2s was much higher (49.43%) with mesially inclined impacted maxillary and mandibular M3s.<sup>9</sup> Mesio-angular and horizontal inclinations have been previously reported as risk factors for ERR of M2 in the maxilla and mandible.<sup>3-5,7,8</sup> Regarding the impaction depth, Li et al.<sup>5</sup> reported that a deeply impacted M3 was a risk factor for ERR in maxillary M2s. Meanwhile, 2 recent studies showed that shallow impaction of M3 was a risk factor for ERR in mandibular M2s.<sup>6,9</sup> Thus, there is still no consensus regarding the relationship between impaction depth and ERR, and Li et al.<sup>5</sup> proposed a possible explanation that for maxillary M2s, ERR mostly occurs at the apical third, while in mandibular M2s, ERR is most frequently detected at the cervical third. In the present study, impacted M3s showed a 5 times higher risk of ERR than erupted M3s. To date, studies have only included impacted M3s, whereas this study compared impacted M3s with non-impacted M3s, identified impaction itself as a risk factor for ERR, and quantified its degree of risk. However, a mesial inclination of M3 had no effect on ERR, which aligns with the results of Hermann et al.<sup>8</sup> Previous studies have been conducted

on both maxillary and mandibular M3s, but more research focused on maxillary M3s is necessary.

In this study, there was no significant difference in ERR according to sex, which corresponds to previous results.<sup>6,9</sup> However, Keskin Tunç and Koc<sup>13</sup> reported a higher rate in female patients, and some authors reported a higher risk in male patients.<sup>20,22</sup> Thus, the possibility of a sex difference in ERR remains unclear. Regarding age, Li et al.<sup>5</sup> reported that the prevalence of ERR was 18.3% in patients under age 25, and 44% in those over age 25. Wang et al.<sup>6</sup> also reported age over 35 years as an important risk factor affecting the prevalence of ERR. These results seem valid, because root resorption induced by mechanical pressure from an impacted M3 might be a progressive process over time. However, there was no significant relationship between age and ERR in this study, which also agrees with previous studies.<sup>7,13</sup> Compared to other studies, the present study included patients with a relatively narrow age range. This might explain the absence of a significant relationship between age and ERR. Interestingly, Li et al.<sup>5</sup> reported that the severity of resorption increased with aging. Whether the M3 was on the left or on the right did not affect the ERR risk, with is in accordance with the results of Wang et al.<sup>6</sup>

Although not covered in this study, it is also important to understand the relationship between M3 and the maxillary sinus in maxillary M3 extraction. When panoramic images showed superimposition of the roots and the sinus floor, expansion of the sinus to the buccal side of the root was generally observed in CBCT images.<sup>23</sup> Knowledge of the anatomical relationship between the maxillary sinus floor and maxillary M3 roots is important for removing a maxillary M3 to prevent untoward complications such as displacement of M3 or oroantral perforation. CBCT images might offer more valuable information for these purposes than panoramic images. A systematic review suggested taking CBCT images when the relationship between M3 roots and the sinus floor is unclear.<sup>24</sup>

The patients included here were strictly filtered and screened based on our inclusion and exclusion criteria to reduce the sample heterogeneity as much as possible. However, the present study was a retrospective study, with potential bias related to sample selection. Moreover, ERR was diagnosed only by radiographs, lacking validation by clinical or histological information. A study suggested an ERR classification system based on periapical images, where minimal or slight resorption was defined as loss of tooth substance up to 2 mm,<sup>7</sup> but no standard classification of ERR in CBCT images has been suggested. Further studies are required, and it would be preferable for future research to apply

the hierarchical model of Fryback and Thornbury<sup>25</sup> for evidence-based guidelines.

In conclusion, ERR related to M3 is a common clinical condition, and superimposition of M3 onto M2 on panoramic images was the most important risk factor for ERR. It seems that CBCT examinations for maxillary M3 might be indicated for the diagnosis of ERR. Impaction itself was also a risk factor and should be carefully examined.

**Conflicts of Interest:** None

## References

1. Hounsoms J, Pilkington G, Mahon J, Boland A, Beale S, Kotas E, et al. Prophylactic removal of impacted mandibular third molars: a systematic review and economic evaluation. *Health Technol Assess* 2020; 24: 1-116.
2. Ventä I, Vehkalahti MM, Huuromonen S, Suominen AL. Signs of disease occur in the majority of third molars in an adult population. *Int J Oral Maxillofac Surg* 2017; 46: 1635-40.
3. Oenning AC, Neves FS, Alencar PN, Prado RF, Groppo FC, Haiter-Neto F. External root resorption of the second molar associated with third molar impaction: comparison of panoramic radiography and cone beam computed tomography. *J Oral Maxillofac Surg* 2014; 72: 1444-55.
4. Tassoker M. What are the risk factors for external root resorption of second molars associated with impacted third molars? A cone-beam computed tomography study. *J Oral Maxillofac Surg* 2019; 77: 11-7.
5. Li D, Tao Y, Cui M, Zhang W, Zhang X, Hu X. External root resorption in maxillary and mandibular second molars associated with impacted third molars: a cone-beam computed tomographic study. *Clin Oral Investig* 2019; 23: 4195-203.
6. Wang D, He X, Wang Y, Li Z, Zhu Y, Sun C, et al. External root resorption of the second molar associated with mesially and horizontally impacted mandibular third molar: evidence from cone beam computed tomography. *Clin Oral Investig* 2017; 21: 1335-42.
7. Hermann L, Wenzel A, Schropp L, Matzen LH. Impact of CBCT on treatment decision related to surgical removal of impacted maxillary third molars: does CBCT change the surgical approach? *Dentomaxillofac Radiol* 2019; 48: 20190209.
8. Hermann L, Wenzel A, Schropp L, Matzen LH. Marginal bone loss and resorption of second molars related to maxillary third molars in panoramic images compared with CBCT. *Dentomaxillofac Radiol* 2019; 48: 20180313.
9. Oenning AC, Melo SL, Groppo FC, Haiter-Neto F. Mesial inclination of impacted third molars and its propensity to stimulate external root resorption in second molars - a cone-beam computed tomographic evaluation. *J Oral Maxillofac Surg* 2015; 73: 379-86.
10. SEDENTEXCT Guideline Development Panel. Cone beam CT for dental and maxillofacial radiology. Evidence based guidelines. Luxembourg: European Commission Directorate-General for Energy; 2012.
11. Dula K, Benic GI, Bornstein M, Dagassan-Berndt D, Filippi A,

- Hicklin S, et al. SADMFR guidelines for the use of cone-beam computed tomography/digital volume tomography. *Swiss Dent J* 2015; 125: 945-53.
12. Al-Khateeb TH, Bataineh AB. Pathology associated with impacted mandibular third molars in a group of Jordanians. *J Oral Maxillofac Surg* 2006; 64: 1598-602.
  13. Keskin Tunç S, Koc A. Evaluation of risk factors for external root resorption and dental caries of second molars associated with impacted third molars. *J Oral Maxillofac Surg* 2020; 78: 1467-77.
  14. Nemcovsky CE, Libfeld H, Zubery Y. Effect of non-erupted 3rd molars on distal roots and supporting structures of approximal teeth. A radiographic survey of 202 cases. *J Clin Periodontol* 1996; 23: 810-5.
  15. Yamaoka M, Furusawa K, Ikeda M, Hasegawa T. Root resorption of mandibular second molar teeth associated with the presence of the third molars. *Aust Dent J* 1999; 44: 112-6.
  16. Li ZB, Qu HL, Zhou LN, Tian BM, Chen FM. Influence of non-impacted third molars on pathologies of adjacent second molars: a retrospective study. *J Periodontol* 2017; 88: 450-6.
  17. Nunes WJ, Vieira AL, de Abreu Guimarães LD, Alcântara CE, Verner FS, Carvalho MF. Reliability of panoramic radiography in predicting proximity of third molars to the mandibular canal: a comparison using cone-beam computed tomography. *Imaging Sci Dent* 2021; 51: 9-16.
  18. Neves FS, Souza TC, Almeida SM, Haiter-Neto F, Freitas DQ, Bóscolo FN. Correlation of panoramic radiography and cone beam CT findings in the assessment of the relationship between impacted mandibular third molars and the mandibular canal. *Dentomaxillofac Radiol* 2012; 41: 553-7.
  19. Shahidi S, Zamiri B, Bronoosh P. Comparison of panoramic radiography with cone beam CT in predicting the relationship of the mandibular third molar roots to the alveolar canal. *Imaging Sci Dent* 2013; 43: 105-9.
  20. Nitzan D, Keren T, Marmary Y. Does an impacted tooth cause root resorption of the adjacent one? *Oral Surg Oral Med Oral Pathol* 1981; 51: 221-4.
  21. Fuss Z, Tsesis I, Lin S. Root resorption diagnosis, classification and treatment choices based on stimulation factors. *Dent Traumatol* 2003; 19: 175-82.
  22. Suter VG, Rivola M, Schriber M, Leung YY, Bornstein MM. Risk factors for root resorption of second molars associated with impacted mandibular third molars. *Int J Oral Maxillofac Surg* 2019; 48: 801-9.
  23. Jung YH, Cho BH. Assessment of maxillary third molars with panoramic radiography and cone-beam computed tomography. *Imaging Sci Dent* 2015; 45: 233-40.
  24. Lewusz-Butkiewicz K, Kaczor K, Nowicka A. Risk factors in oroantral communication while extracting the upper third molar: systematic review. *Dent Med Probl* 2018; 55: 69-74.
  25. Fryback DG, Thornbury JR. The efficacy of diagnostic imaging. *Med Decis Making* 1991; 11: 88-94.